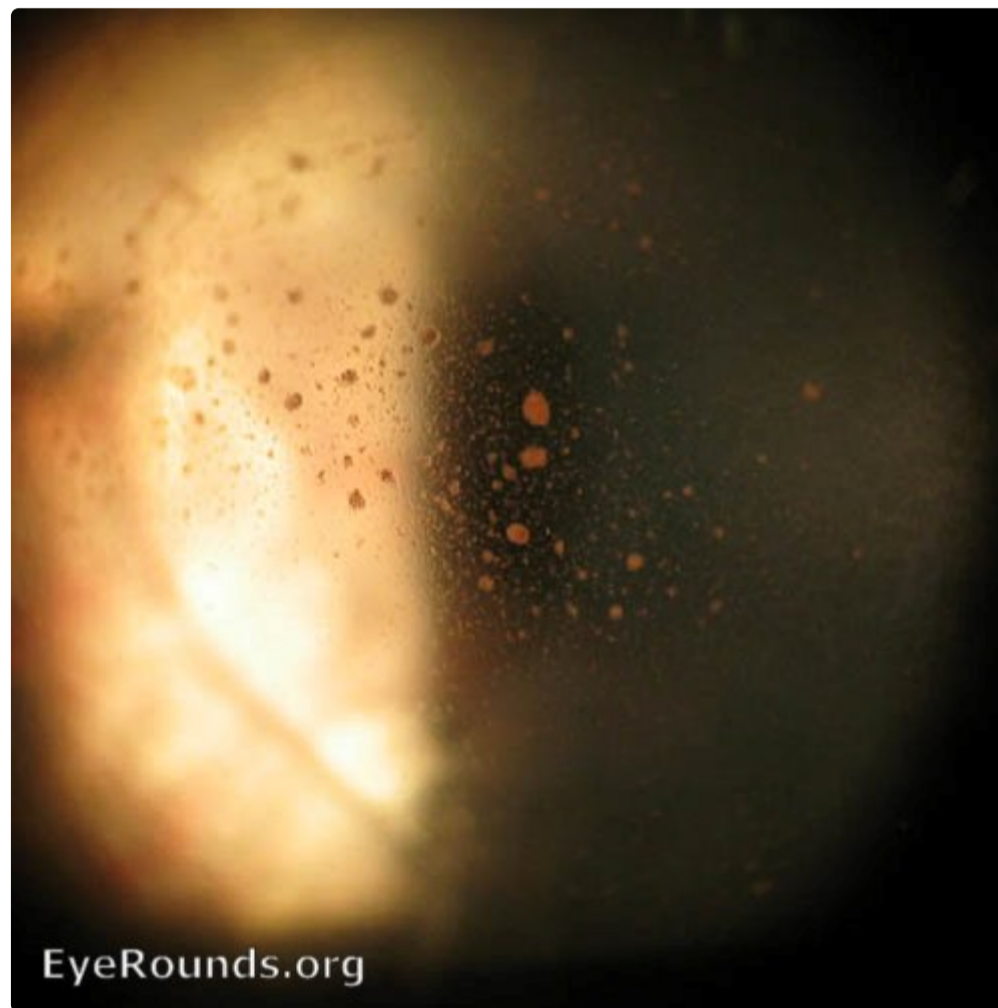


## Retinal detachment - Shafer's sign

Category(ies): [Retina](#)

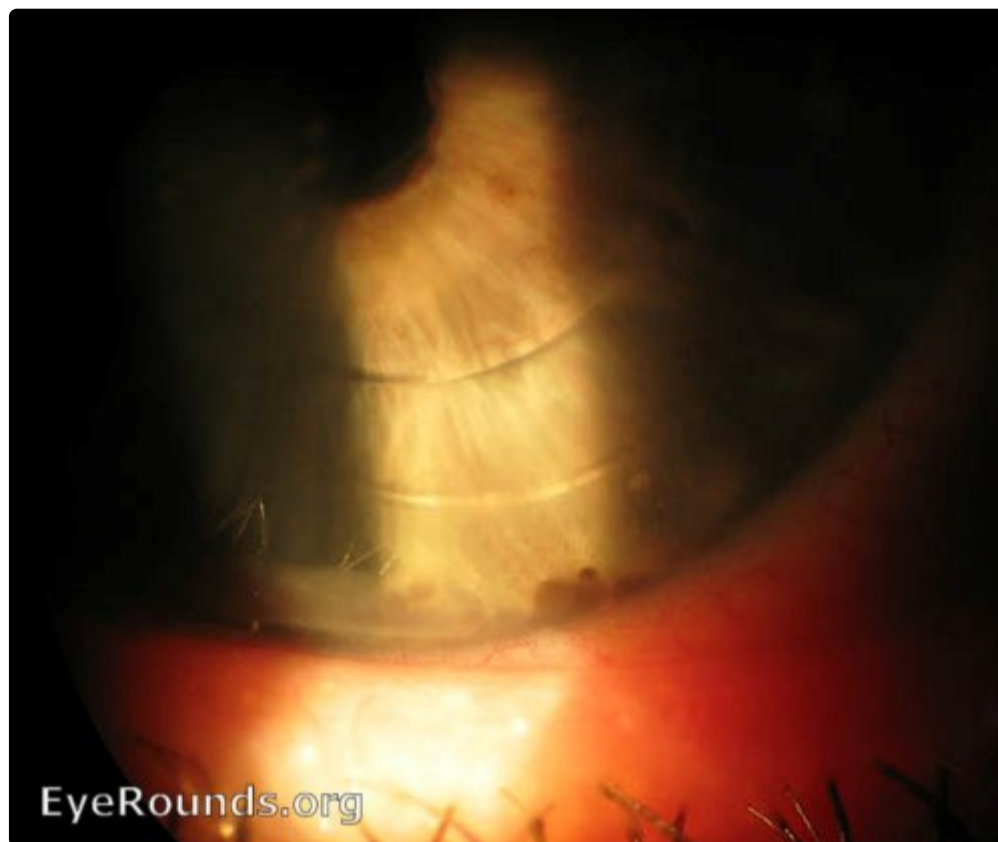Contributor: [Andrew Doan, MD, PhD](#)

Posted: February 8, 2008



Clumping of pigmented cells in anterior vitreous and on corneal endothelium. Also known as "tobacco dust".

[Enlarge](#) [Download](#)



[🔍 Enlarge](#)   [📄 Download](#)

University of Iowa  
Roy J. and Lucille A. Carver College of Medicine  
Department of Ophthalmology and Visual Sciences  
200 Hawkins Drive  
Iowa City, IA 52242

[Support Us](#)

Copyright © 2019 The University of Iowa. All Rights Reserved  
[Report an issue with this page](#)  
[Web Privacy Policy](#) | [Nondiscrimination Statement](#)

Follow



[Receive notification of new cases, sign up here](#)

[Contact Us](#)

[Submit a Suggestion](#)