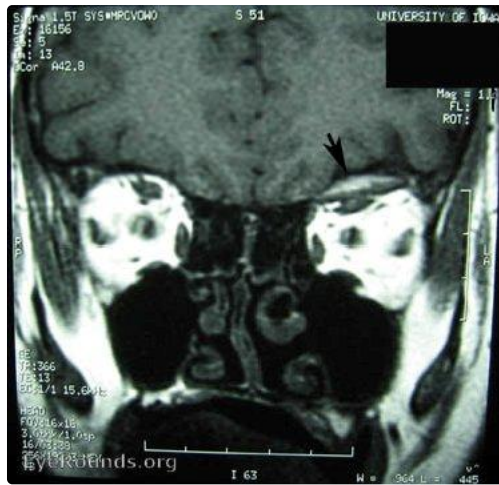


## Subperiosteal hematoma

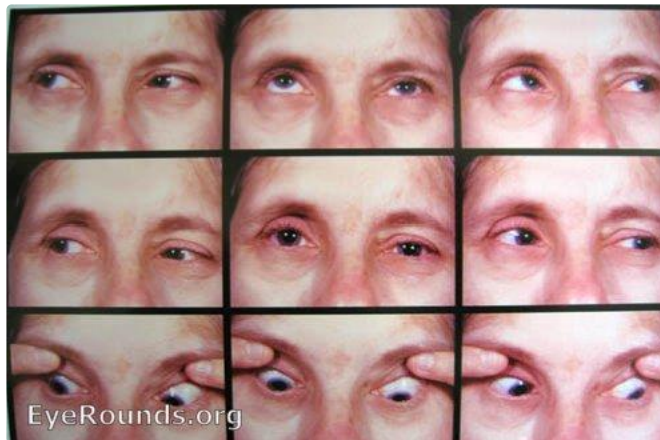Category(ies): Oculoplastics

Contributor: [Andrew Doan, MD, PhD](#)



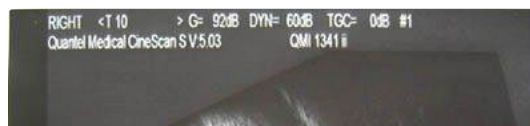1) MRI scan shows left subperiosteal hematoma (arrow)

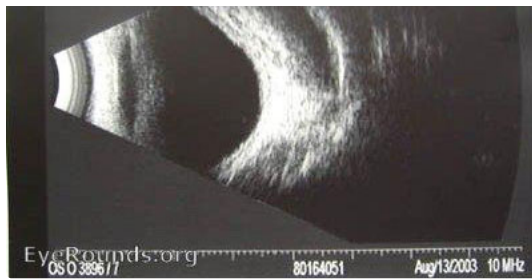
[Enlarge](#) [Download](#)



2) EOM showing restriction in upgaze OS

[Enlarge](#) [Download](#)





3) B-Scan echo showing subperiosteal hematoma

[Enlarge](#) [Download](#)

Read more at:

Doan AP, Lee SK, Chaloupka J, Nerad JA, Lee AG. [Subperiosteal hematoma of the orbit following an aneurysm coiling procedure](#). Am J Ophthalmol. 2004;138(4):680-2. PubMed PMID: 15488814.

### Image Permissions:



Ophthalmic Atlas Images by [EyeRounds.org](#), [The University of Iowa](#) are licensed under a [Creative Commons Attribution-NonCommercial-NoDerivs 3.0 Unported License](#).

### Address

University of Iowa  
Roy J. and Lucille A. Carver College  
of Medicine  
Department of Ophthalmology and  
Visual Sciences  
200 Hawkins Drive  
Iowa City, IA 52242

[Support Us](#)

### Legal

Copyright © 2019 The University of  
Iowa. All Rights Reserved  
[Report an issue with this page](#)  
[Web Privacy Policy](#) |  
[Nondiscrimination Statement](#)

### Related Links

[Cataract Surgery for Greenhorns](#)  
[EyeTransillumination](#)  
[Gonioscopy.org](#)  
[Iowa Glaucoma Curriculum](#)  
[Iowa Wet Lab](#)  
[Patient Information](#)  
[Stone Rounds](#)  
[The Best Hits Bookshelf](#)

### EyeRounds Social Media

Follow



[Receive notification of new cases,  
sign up here](#)  
[Contact Us](#)  
[Submit a Suggestion](#)