

# EyeRounds.org

## Normal fundus - adult

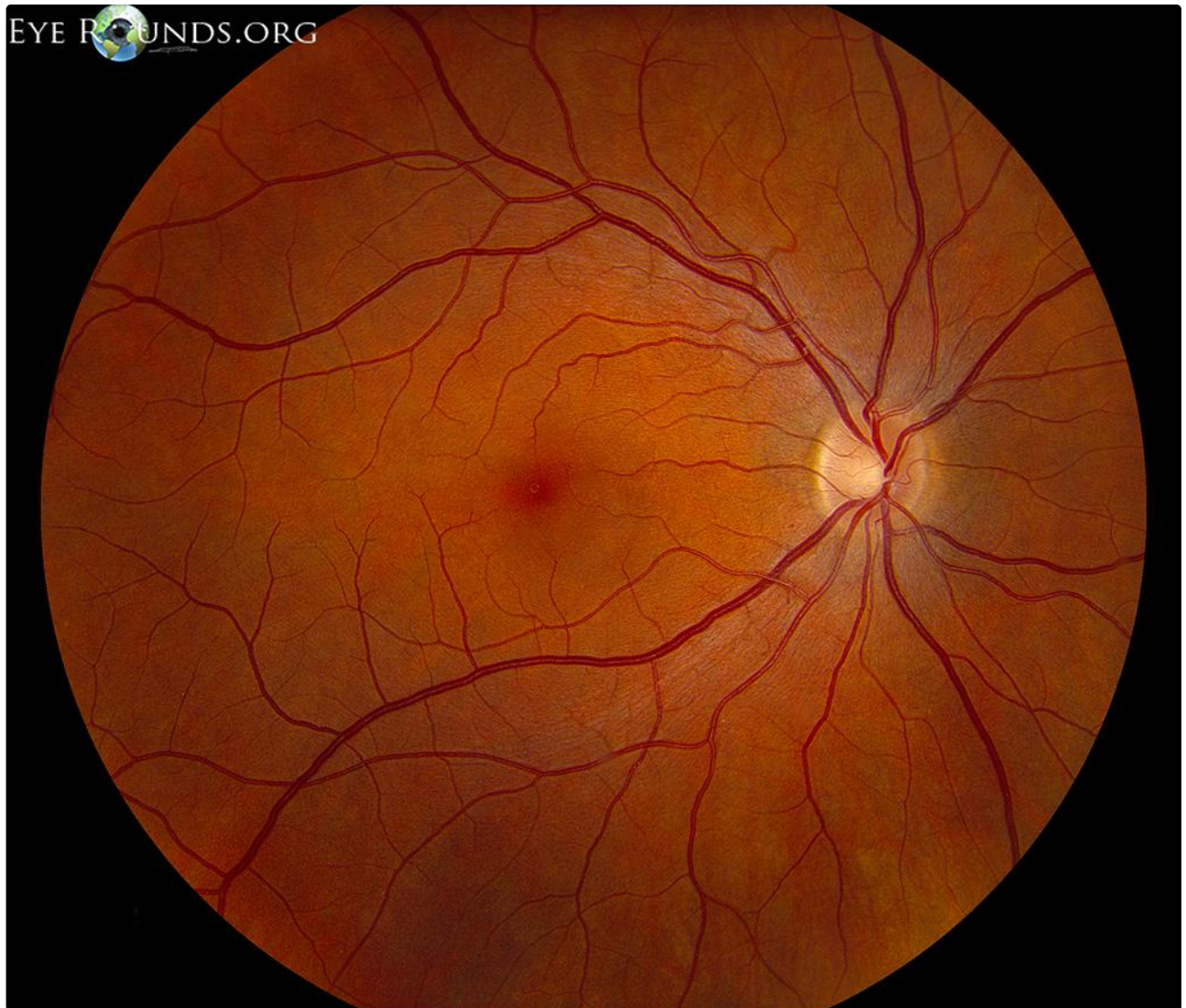
**Category(ies):** Retina

**Contributor:** [Jesse Vislisel, MD](#)

**Photographer:** Toni Venckus, CRA

This is a color fundus photograph of a 35-year-old healthy patient. The media are clear, providing a crisp view of the fundus. The optic disc appears pink with sharp margins and a cup-to-disc ratio of approximately 0.35. The vasculature is normal in course and caliber. The striated sheen radiating outward from the disc is evidence of a healthy retinal nerve fiber layer. There are no lesions, scars, or pigmentary changes in the macula or periphery. The fovea exhibits a crisp foveal light reflex.

EyeRounds.org



Normal Adult Fundus

[Enlarge](#)

[Download](#)

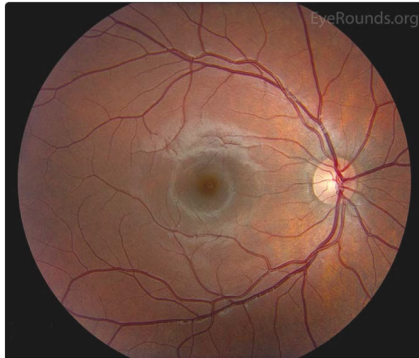
## Image Permissions:



Ophthalmic Atlas Images by [EyeRounds.org](http://EyeRounds.org), [The University of Iowa](http://The University of Iowa) are licensed under a [Creative Commons Attribution-NonCommercial-NoDerivs 3.0 Unported License](https://creativecommons.org/licenses/by-nc-nd/3.0/).



## Related Articles



[Related Atlas Entry: Normal fundus in childhood](#)

## Address

University of Iowa  
Roy J. and Lucille A. Carver College  
of Medicine  
Department of Ophthalmology and  
Visual Sciences  
200 Hawkins Drive  
Iowa City, IA 52242

[Support Us](#)

## Legal

Copyright © 2019 The University of  
Iowa. All Rights Reserved  
[Report an issue with this page](#)  
[Web Privacy Policy](#) |  
[Nondiscrimination Statement](#)

## Related Links

[Cataract Surgery for Greenhorns](#)  
[EyeTransillumination](#)  
[Gonioscopy.org](#)  
[Iowa Glaucoma Curriculum](#)  
[Iowa Wet Lab](#)  
[Patient Information](#)  
[Stone Rounds](#)  
[The Best Hits Bookshelf](#)

## EyeRounds Social Media

Follow



Receive notification of new cases,  
[sign up here](#)  
[Contact Us](#)  
[Submit a Suggestion](#)