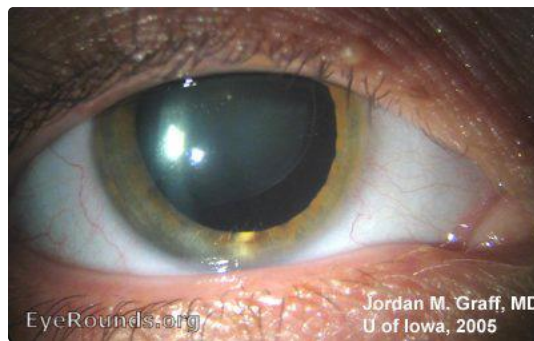


Marfan's Syndrome

Category(ies): Cataract

Contributor: [Jordan Graff, MD](#)




Lens subluxation is readily evident in this dilated view of a patient with Marfan's syndrome.


[Enlarge](#) [Download](#)



This close view of the subluxed lens allows visualization of the zonules.

[Enlarge](#) [Download](#)

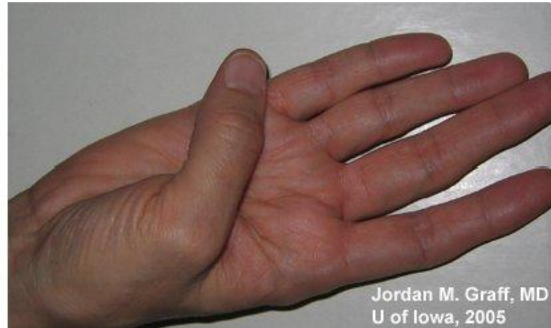
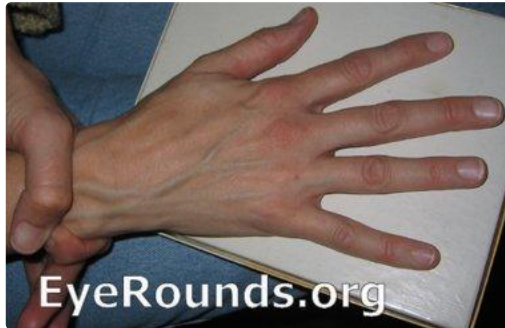


Both lenses are seen here, side by side. Supero-temporal dislocation of the lens is evident in both eyes.

[Enlarge](#)

[Download](#)



Classically long, thin fingers and "double-jointed" hands are additional hallmarks of the disease. Both lenses are seen here, side by side. Supero-temporal dislocation of the lens is evident in both eyes.

[Enlarge](#)

[Download](#)

Image Permissions:



Ophthalmic Atlas Images by [EyeRounds.org](#), [The University of Iowa](#) are licensed under a [Creative Commons Attribution-NonCommercial-NoDerivs 3.0 Unported License](#).

Address

University of Iowa
Roy J. and Lucille A. Carver College
of Medicine
Department of Ophthalmology and
Visual Sciences
200 Hawkins Drive
Iowa City, IA 52242

[Support Us](#)

Legal

Copyright © 2019 The University of
Iowa. All Rights Reserved
[Report an issue with this page](#)
[Web Privacy Policy](#) |
[Nondiscrimination Statement](#)

Related Links

[Cataract Surgery for Greenhorns](#)
[EyeTransillumination](#)
[Gonioscopy.org](#)
[Iowa Glaucoma Curriculum](#)
[Iowa Wet Lab](#)
[Patient Information](#)
[Stone Rounds](#)
[The Best Hits Bookshelf](#)

EyeRounds Social Media

Follow



Receive notification of new cases,
[sign up here](#)
[Contact Us](#)
[Submit a Suggestion](#)