

EyeRounds.org

The Best Hits Bookshelf

A Collection of Popular Cases and Tutorials



THE UNIVERSITY OF IOWA
Department of Ophthalmology and Visual Sciences
First Edition, 2018

Eye  ounds.org

The Best Hits Bookshelf

A Collection of Popular Cases and Tutorials

First Edition

March 2018



copyright 2018.

The University of Iowa
Department of Ophthalmology & Visual Sciences
Iowa City, Iowa

About this Book

This first edition book is a compilation of 50 case and tutorial articles featured on our website, EyeRounds.org. These articles have the most online “hits” and were hand-selected for their popularity and impact. They are among some of our most recent and high-yield content. Popularity will, of course, change over time so future editions will likely contain a different mixture of articles.

The content is arranged first by type (case or tutorial) and then subspecialty (Cornea and External Disease, Cataract, Glaucoma, Neuro-Ophthalmology, Oculoplastics, Pediatrics and Strabismus, Retina and Vitreous, and On-Call and Trauma.)

About EyeRounds.org

Ophthalmology Grand Rounds and EyeRounds.org is a website of the University of Iowa Department of Ophthalmology and Visual Sciences in Iowa City, Iowa. On EyeRounds.org, you will find case reports from our daily morning rounds, high-quality atlas images, videos, and online tutorials. EyeRounds.org is an ever-growing resource for students, residents, physicians, and patients. Over time, EyeRounds has gained momentum, now impacting learners all over the globe. Daily, the website receives thousands of hits from over 40 countries.

EyeRounds.org Content

The content on EyeRounds.org is produced by our physicians and is intended for medical students, residents, and physicians.

What is not in this book?

EyeRounds.org atlas images and videos, though very popular with our users, have been excluded from this compilation due to their nature. We invite you to explore the EyeRounds atlas at EyeRounds.org/atlas where you will find hundreds of pages of interesting and educational short items with images of interest. EyeRounds videos can be found at EyeRounds.org/video. Videos have been collected from a variety of sources created over the years by residents, faculty, and fellows of the University of Iowa Department of Ophthalmology & Visual Sciences.

Think before you act...

Disclaimer

Content is made available for review purposes only.

Much of the material from EyeRounds.org is gathered from Grand Rounds presentations.

The intent of Grand Rounds is to initiate discussion and stimulate thought, as a result, EyeRounds articles may contain information that is not medically proven fact and ***should not be used to guide treatment***.

Opinions expressed are not necessarily those of the University of Iowa, the Carver College of Medicine, nor the Department of Ophthalmology and Visual Sciences.

For more details, see our terms of use at EyeRounds.org/TOS.htm

Funding Support

EyeRounds.org is partially supported by unrestricted funds from The University of Iowa Department of Ophthalmology and Visual Sciences and from The Iowa Eye Association, neither of whom have influence on the content of this site.

March 8, 2018



Dedication of this Work

Patricia (Trish) Duffel has a B.S. in Pharmacy from the University of Texas, Austin (1976) and an M.A. in Library and Information Science from the University of Iowa (1991). Having earned her pharmacy degree in the days before the Pharm D degree became generally accepted, Trish is a registered pharmacist (RPh). Since 1991, she has been the solo librarian for the Department of Ophthalmology and Visual Sciences at the University of Iowa and the Executive Director and Editor of EyeRounds.org since 2007. In her almost 27 years in the department, she has held many roles including library manager, literature searcher, information chaser, newsletter writer/editor, copy editor, webmaster, and educator.

Trish goes above and beyond, working tirelessly to support and see to the success of residents, fellows, scientists and physicians in the department. Her powerful work ethic, contagious energy, can-do attitude, and unwavering devotion to those around her has made her a favorite among faculty and trainees. She is a treasure trove of knowledge, a forever learner, and a truly incredible human being. For all that she has done for education at the University of Iowa Department of Ophthalmology and Vision Sciences and EyeRounds.org, we dedicate this work to Trish.

EyeRounds Board 2017-2018

Lorraine A. Provencher, MD

Chief Medical Editor, June 2017 - present
Editorial Board Member, July 2016 - present
University of Iowa
Department of Ophthalmology and Visual Sciences
Ophthalmology Resident

Lindsay M. DeAndrade, MD

Editorial Board Member, July 2016 - present
University of Iowa
Department of Ophthalmology and Visual Sciences
Ophthalmology Resident

Benjamin J. Janson, MD

Editorial Board Member January 2018 - present
University of Iowa
Department of Ophthalmology and Visual Sciences
Ophthalmology Resident

Brittini Scruggs, MD, PhD

Editorial Board Member, July 2017 - present
University of Iowa
Department of Ophthalmology and Visual Sciences
Ophthalmology Resident

Heather A. Stiff, MD

Editorial Board Member January 2018 - present
University of Iowa
Department of Ophthalmology and Visual Sciences
Ophthalmology Resident

Daniel Terveen, MD

Editorial Board Member, July 2017 - present
University of Iowa
Department of Ophthalmology and Visual Sciences
Ophthalmology Resident

Thomas A. Oetting, MD

Editor and Co-Founder, EyeRounds.org
University of Iowa
Department of Ophthalmology and Visual Sciences
Professor of Clinical Ophthalmology

Wallace L.M. Alward, MD

Editorial Board Member
University of Iowa
Department of Ophthalmology and Visual Sciences
Professor of Ophthalmology

Mark Greiner, MD

Editorial Board Member
University of Iowa
Department of Ophthalmology and Visual Sciences
Assistant Professor of Ophthalmology

Pavlina Kemp, MD

Editorial Board Member
University of Iowa
Department of Ophthalmology and Visual Sciences
Assistant Professor of Clinical Ophthalmology

Patricia G. (Trish) Duffel, RPh, MA

Executive Director and Editor, EyeRounds.org
University of Iowa
Department of Ophthalmology and Visual Sciences
Librarian

Kelsey Hunold, BFA

Assistant Director and Editor, EyeRounds.org
University of Iowa
Department of Ophthalmology and Visual Sciences
Web and Social Media Coordinator

Advisory Members

Andrew Doan, MD, PhD

Co-Founder EyeRounds.org
Comprehensive Ophthalmology & Ocular Pathology
San Diego, California

Jordan M. Graff, MD

Editorial Board Member
Alumnus, Resident (2007), Vitreoretinal Fellow (2009)
Arizona

Matthew C. Weed, MD

Editorial Board Member
Alumnus, Resident (2014), Ophthalmic Genetics Fellow
(2015), Pediatric Ophthalmology Fellow (2016)
Pediatric Ophthalmologist
Spokane, WA

Thomas A. Weingeist, MD, PhD

Editor and Co-Founder, EyeRounds.org
University of Iowa
Department of Ophthalmology and Visual Sciences
Emeritus Head
Professor of Ophthalmology

Contents

CASE PRESENTATIONS.....	1-142
Cornea and External Disease	1-18
Salzmann’s Nodular Corneal Degeneration.....	2-8
Treatment of Epithelial Basement Membrane Dystrophy with Manual Superficial Keratectomy.....	9-13
Acute Corneal Hydrops.....	14-18
Cataract.....	19-33
Marfan Syndrome	20-23
Posterior Polar Cataract	24-28
True Exfoliation Syndrome	29-33
Glaucoma.....	34-59
Aphakic Glaucoma.....	35-39
Uveitis Glaucoma Hyphema (UGH) Syndrome	40-44
Aqueous Misdirection	45-49
Hypotony: Late hypotony from trabeculectomy & Ahmed Seton	50-55
Posner-Schlossman Syndrome (Glaucomatocyclitic Crisis)	56-59
Neuro-Ophthalmology.....	60-82
Functional Visual Loss	61-65
Ocular Tilt Reaction	66-70
Ethambutol Toxicity and Optic Neuropathy	71-76
Optic Neuritis	77-82
Oculoplastic Surgery.....	83-106
“I Can’t Open My Eyes”: A Case of Blepharospasm and Apraxia of Eyelid Opening.....	84-86
Carotid Cavernous Fistula.....	87-90
Chalazion: acute presentation and recurrence in a 4-year-old female	91-95
Bell’s Palsy Treated with Facial Nerve Decompression.....	96-102
Vertical Oscillopsia: A Case of Superior Oblique Myokymia.....	103-106
Pediatric Ophthalmology & Strabismus	107-118
Orbital Cellulitis in a Child	108-111
Congenital dacryocystocele with spontaneous resolution.....	112-114
Phlyctenular Keratoconjunctivitis: 12-year-old Female with Staphylococcal Blepharitis	115-118
Retina and Vitreous.....	119-142
Intraocular Foreign Body: A Classic Case of Metal on Metal Eye Injury	120-123
Idiopathic Juxtafoveal Telangiectasia Type II (Macular Telangiectasia type 2)	124-130
Vitreous Syneresis: An Impending Posterior Vitreous Detachment (PVD)	131-135
Fungal endophthalmitis.....	136-142

TUTORIALS	143-331
Cornea and External Disease	143-187
Corneal Imaging: An Introduction	144-155
Introduction to Corneal Transplantation	156-167
Epithelial-Stromal and Stromal Corneal Dystrophies	168-176
Ocular Surface Tumors	177-187
Cataract.....	188-193
Patient Communication during Cataract Surgery	189-191
Ten Tips to Prevent and Treat Iris Prolapse	192-193
Glaucoma.....	194-214
Medical Management of Glaucoma	195-200
MIGS: Minimally Invasive Glaucoma Surgery	201-214
Neuro-Ophthalmology.....	215-244
Visual Field Testing	216-223
Idiopathic Intracranial Hypertension (Pseudotumor Cerebri)	224-235
Nystagmus and Saccadic Oscillations	236-244
Oculoplastic Surgery.....	245-289
Benign Lesions of the External Periocular Tissues	246-253
Malignant Lesions of the External Periocular Tissues	256-261
Thyroid Eye Disease.....	262-279
Nasolacrimal Stents.....	280-286
Retrobulbar Block, Peribulbar Block, and Common Nerve Blocks Used by Ophthalmologists	287-289
Pediatric Ophthalmology & Strabismus	290-305
Pediatric Spectacle Prescription and Retinoscopy Made Simple.....	291-296
Binocular Vision.....	297-308
Retina & Vitreous	306-319
Intravitreal Injection Technique.....	307-314
Full Thickness Macular Hole.....	315-319
On-Call and Trauma	320-331
Bedside Ocular Exam.....	321-322
Ocular Ultrasound: A quick reference guide for the on-call physician	323-327
Emergent Evaluation of Eyelid Lacerations.....	328-331

EyeRounds.org

Case Presentations

Cornea and External Disease

Salzmann's Nodular Corneal Degeneration

62-year-old woman presents with 3 years of progressive decrease in vision

Joy N. Carroll, Amanda C. Maltry, MD, Anna S. Kitzmann, MD

September 9, 2013

Chief Complaint

A 62-year-old woman presents with a 3-year history of painless, progressive loss of vision in both eyes.

History of Present Illness

Over the last 3 years, there has been gradual, painless loss of vision in both eyes (right greater than left) at both distance and near. She has had 3 updates of her spectacle prescription that have not provided satisfactory vision. There is no diurnal variation in vision.

Past Ocular History

- ◆ Myopia, presbyopia, astigmatism
- ◆ Dry eye syndrome, with relief of symptoms with artificial tears
- ◆ No ocular surgeries

Medical History

- ◆ Hypertension

Medications

- ◆ No ocular medications. Systemic medications: metoprolol 50 mg twice daily

Family History

- ◆ No family history of glaucoma, macular degeneration, blindness or known ocular diseases.

Social History

- ◆ Does not use tobacco or drink alcohol.

Ocular Exam

Visual acuity (VA) with correction

- ◆ Right eye (OD): 20/200, pinhole to 20/50-1
- ◆ Left eye (OS): 20/25+2, pinhole to 20/20

Manifest Refraction

- ◆ OD -2.00 + 5.00 x 20 VA 20/60
- ◆ OS -0.75 + 7.50 x 165 VA 20/25

Intraocular pressure (applanation): OD 16 mmHg, OS 18 mmHg

Pupils: Equal, round, 4 mm in dark, 2 mm in light, no relative afferent pupillary defect

Visual fields: Full to confrontation both eyes (OU)

Motility: Full OU

Slit Lamp Exam

- ◆ **External:** Normal OU
- ◆ **Lids & lashes:** Inspissated meibomian glands with thick waxy secretions and telangiectasia, normal lashes OU
- ◆ **Conjunctiva & sclera:** Clear and quiet
- ◆ **Cornea**
 - OD: Greyish nodules between the corneal epithelium and Bowman's layer in the paracentral superonasal region extending centrally into the visual axis; iron line at inferior border of the lesion
 - OS: Greyish nodules between the corneal epithelium and Bowman's layer in the paracentral superior and superotemporal regions extending centrally into the visual axis; iron line at inferior border of the lesion. See Figure 1.
- ◆ **Anterior chamber:** Deep and quiet OU
- ◆ **Iris:** Normal architecture OU
- ◆ **Lens**
 - OD: 2-3+ nuclear sclerosis
 - OS: 1-2+ nuclear sclerosis
- ◆ **Vitreous:** Normal OU

Dilated Fundus Exam

- ◆ **Disc:** Normal, cup-to-disc ratio 0.3 OU
- ◆ **Vessels:** Normal OU
- ◆ **Macula:** Normal OU
- ◆ **Periphery:** Normal OU

Other Tests

Topography was ordered to characterize the corneal nodules seen on slit lamp exam in the setting of significant astigmatism. Figure 2 shows the crab-claw like pattern of irregular astigmatism superiorly on each eye due to the superior Salzmann's nodules. Placido images show irregular mires most noticeable superiorly on each eye corresponding to the Salzmann's nodules.

Diagnosis

A diagnosis of Salzmann's nodular degeneration was made on the basis of the characteristic clinical appearance and the clinical history of progressive increasing irregular

astigmatism associated with worsening of best corrected visual acuity. She was also diagnosed with nuclear sclerotic cataracts on the right greater than left eye.

Treatment and Clinical Course

To improve visual acuity and to decrease the irregular astigmatism a superficial keratectomy was recommended to remove the Salzmann's nodules.

Course

The patient underwent superficial keratectomy on her right eye. Postoperatively, there was complete clearing of the subepithelial opacities with excellent clarity of the underlying stroma. One month later, reliable keratometry and intraocular lens (IOL) calculations were obtained and an uneventful phacoemulsification and implantation of a posterior chamber IOL was performed (see Figure 3). Several months later, she underwent superficial keratectomy on her left eye with similar results, followed by cataract surgery on her left eye one month later. Postoperatively both eyes achieved best corrected visual acuity of 20/20, with substantial reduction in the astigmatic error (Table 1; Figure 4). At the time of this writing, the vision and examination remains stable for 47 months with no recurrence of Salzmann's nodular corneal degeneration. The mild dry eye continues to be well controlled with artificial tears.


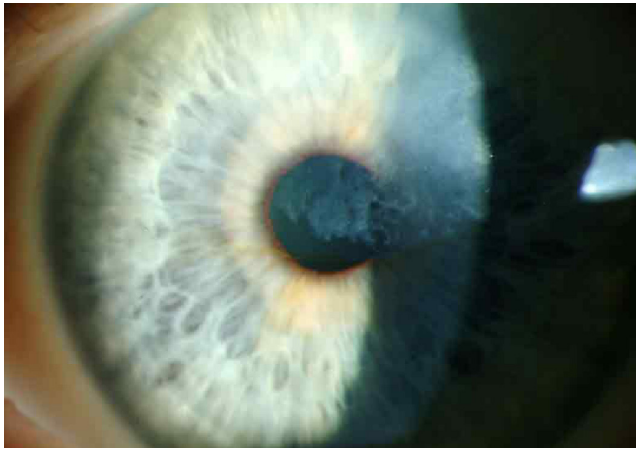


Figure 1a-b. Slit lamp photos of the left eye before treatment

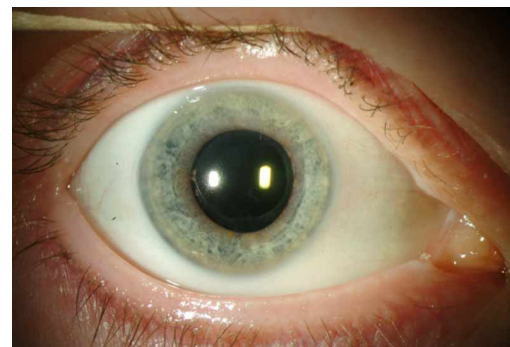

Figure 3: Right eye slit lamp photography, after superficial keratectomy, cataract extraction and intraocular lens placement.

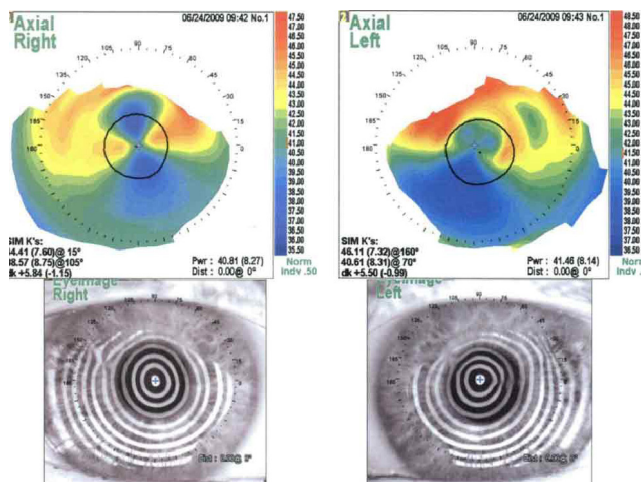


Figure 2: Topography before treatment.

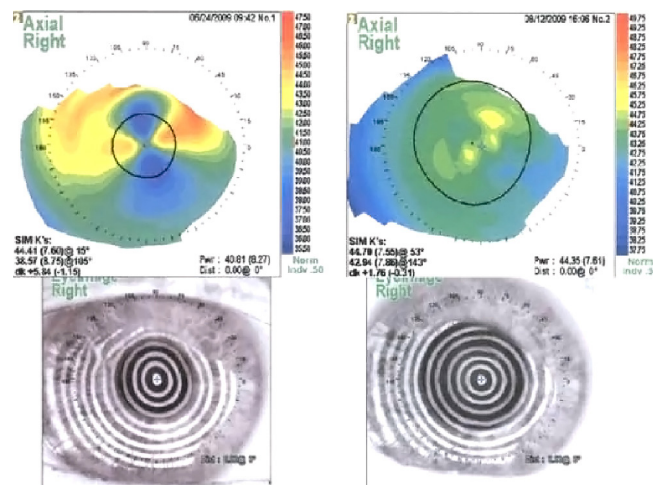


Figure 4: Right eye topography after superficial keratectomy. The overall corneal curvature is reduced with substantial reduction of both regular and irregular astigmatism.

Table 1

Pre-operative Manifest Refraction		
-2.00 + 5.00 x 20	VA 20/60	OD
-0.75 + 7.50 x 165	VA 20/25	OS
Post-operative Manifest Refraction		
-0.25 + 0.75 x 045	VA 20/20	OD
-1.00 + 1.00 x 150	VA 20/20	OS

Pathology

Salzmann's nodules are characterized by hyaline deposited anterior to a disrupted or even displaced Bowman's layer, posterior to an atrophic corneal epithelium. Figure 5 for is an example of the typical histopathology of Salzmann's nodules.

Discussion

Salzmann's nodular corneal degeneration was described by Katz in 1930 following a 1925 case series on the condition published by Maximilian Salzmann, although Salzmann concedes that a case published by Ernst Fuchs in 1901 appears to be the first published case of this corneal degeneration [1].

Salzmann's nodular corneal degeneration is characterized by bilateral gray-white elevated nodules anterior to Bowman's layer, which may be visually significant, cause foreign body sensation, or be asymptomatic. It is most common in middle-aged women. The cause of this degeneration is unknown; however, it has been associated with chronic ocular surface inflammation [1-6]. A case series of 152 eyes concluded that the most common associations were, in descending order, meibomian gland dysfunction (MGD), contact lens wear (especially hard contact lenses), peripheral vascularization, pterygium, keratoconjunctivitis sicca, and exposure keratitis [1]. Another case series of 180 eyes also identified MGD as the most common comorbidity [2].

Conservative treatment consists of management of the underlying etiology, such as MGD. Eyelid hygiene and doxycycline may be considered to treat the MGD prior to surgical treatment. Contact lens cessation or re-fitting may also be beneficial. Medical management is successful in preventing the need for surgery in most cases; the indications for surgery are (1) discomfort; (2) reduced vision due to progressive increase in astigmatic error. Surgery is uniformly successful in removal of the nodule and almost invariably successful in reducing the astigmatic error in allowing for improvement in best corrected visual acuity, usually with a much weaker spectacle prescription. Stabilization of the refractive error usually takes 3 to 6 weeks. In rare cases of neglected nodules within the visual axis, anterior stromal haze may compromise the final visual results.

Whereas subtle recurrences are common in most cases over a 5 to 15 year period, visually significant recurrences are uncommon (5 to 20%) and can be minimized with

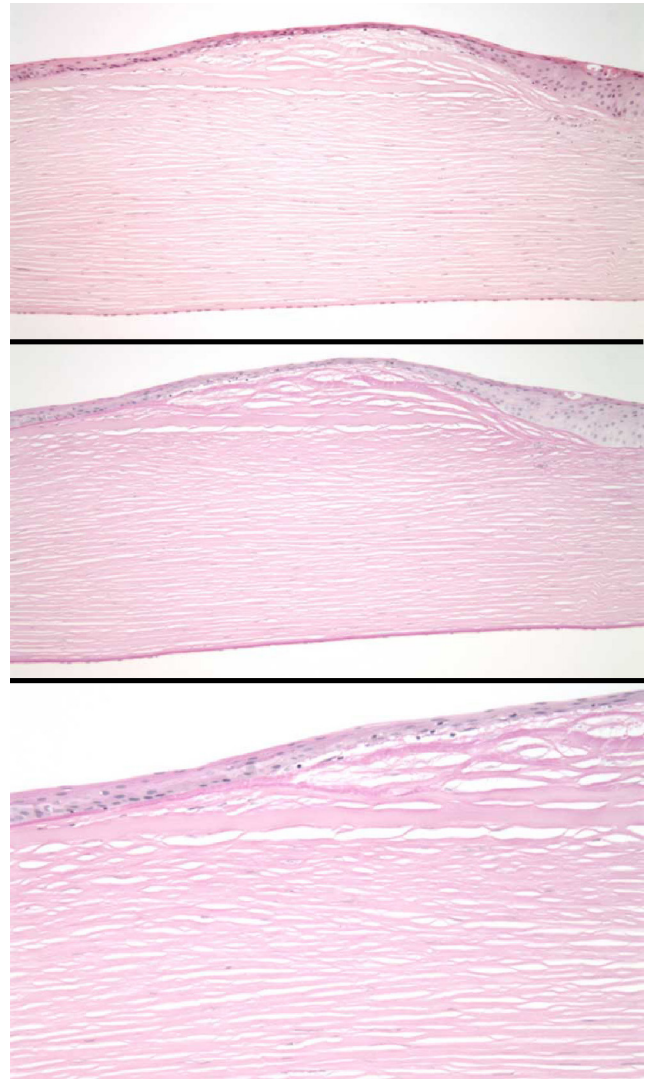


Figure 5: Salzmann's nodule histopathology. A. Atrophic corneal epithelium overlies a nodular, hyalinized fibrous plaque between the epithelium and Bowman's layer. A portion of Bowman's layer is absent at the right side of the lesion. H&E, 50x. B and C. Periodic acid Schiff stain highlights the thickened, irregular epithelial basement membrane. 50x, 100x.

meticulous control of the etiology responsible for the condition [1, 2]. Those cases can be treated with repeat superficial keratectomy. If anterior stromal haze persists in the visual axis after treatment of primary or recurrent nodules, phototherapeutic keratectomy can be offered [1].

Superficial keratectomy of astigmatism-inducing Salzmann's nodules should always be performed prior to cataract surgery. Stable keratometry readings and IOL calculations cannot be reliably obtained until 3 to 6 weeks after surgery. Toric IOLs should be avoided because of the risk of recurrent nodules and induction of post-operative astigmatism.

Examples of Salzmann's nodular corneal degeneration, Figures 6-10

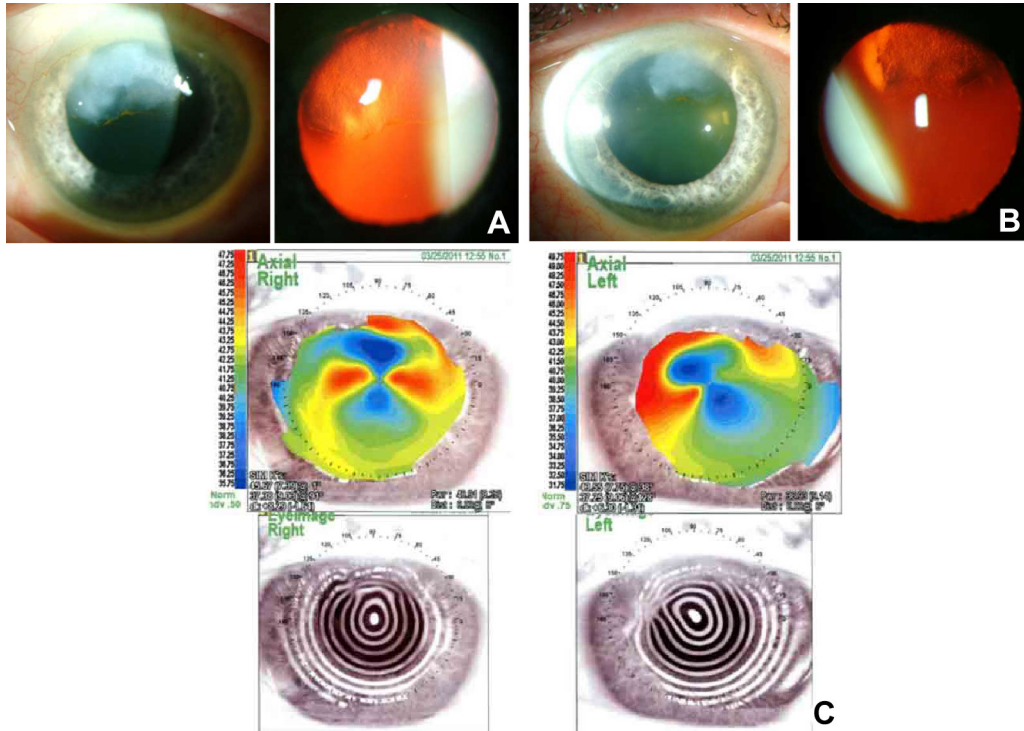


Figure 6

A: Slit lamp photo of the right eye of another patient with a superior Salzmann's nodule.

B: Slit lamp photo of the left eye of another patient with a superior Salzmann's nodule.

C: Corneal topography. The right eye has an against the rule irregular astigmatism with superior steepening. The Placido image shows irregular mires superiorly. The left eye has an asymmetric against the rule irregular astigmatism with superonasal steepening and corresponding irregular mires on Placido image.

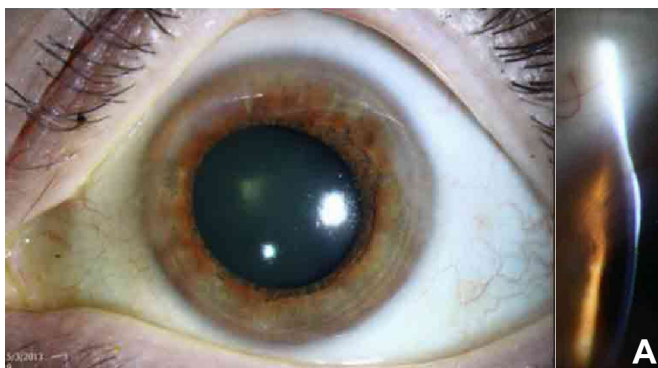


Figure 7a: Slit lamp photo of the left eye of another patient with Salzmann's nodular corneal degeneration. Nodules are peripheral and most evident superonasally and superotemporally in this photo.

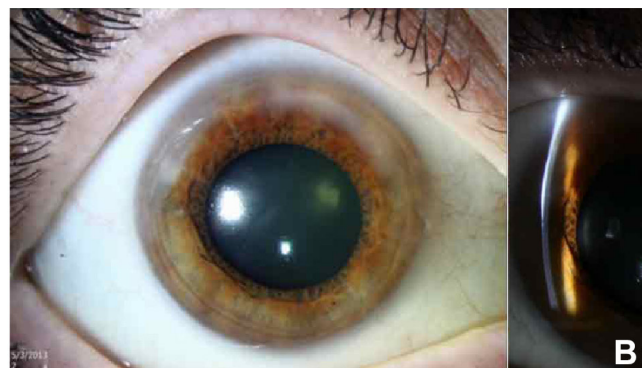

Figure 7b: Slit lamp photo of the right eye. Salzmann's nodules are annular in the superior periphery.

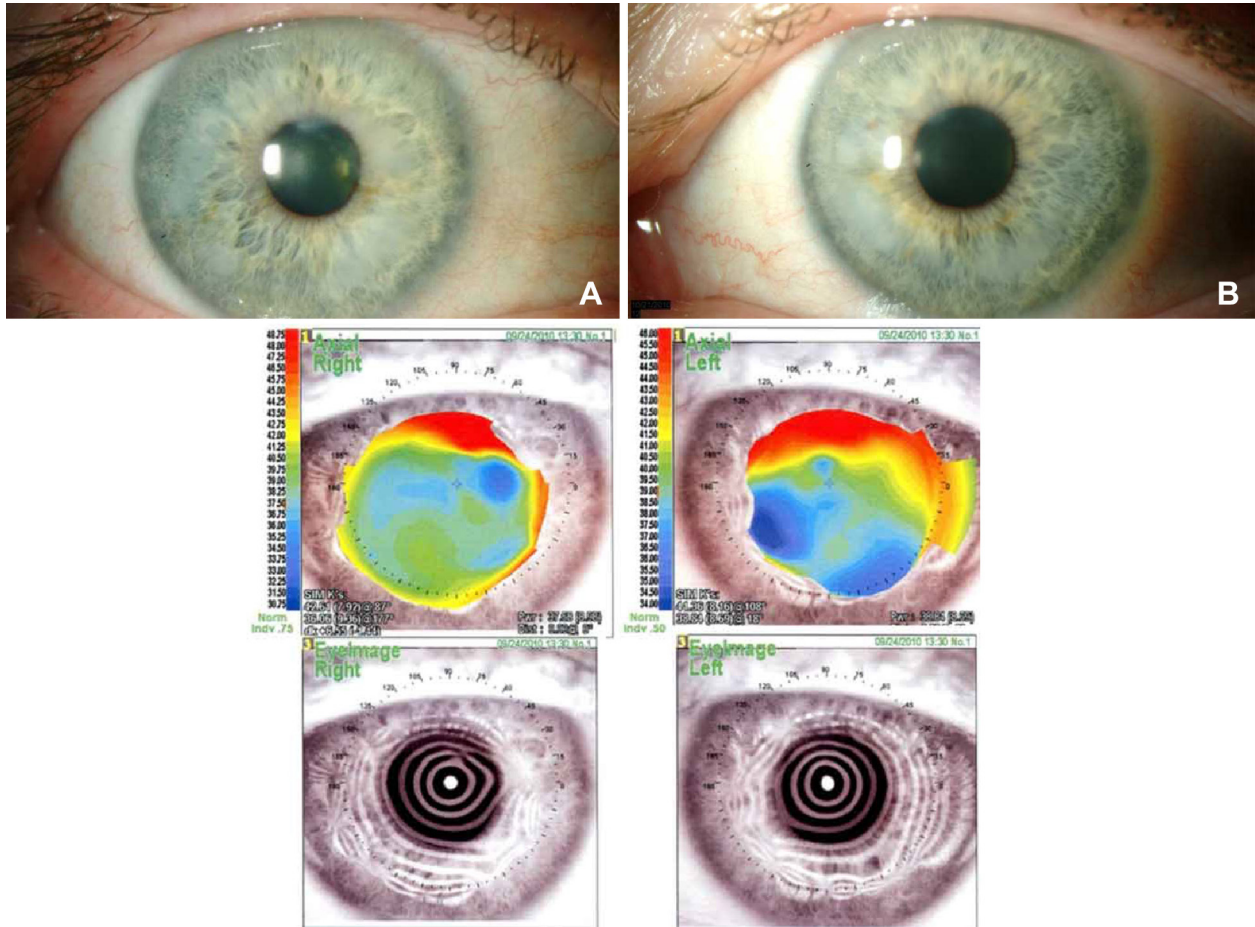


Figure 8a: Slit lamp photo of the right eye of another patient with Salzmann's nodular corneal degeneration. Nodules are annular in the mid-periphery.

Figure 8b: Slit lamp photo of the left eye of another patient with Salzmann's nodular corneal degeneration. Nodules are annular in the interior mid-periphery. F

Figure 8c: Corneal topography. The right eye shows a very irregular astigmatism with superior and nasal steepening. Placido image shows irregular mires in the mid-periphery in all directions. The left eye has a very irregular astigmatism with marked superior and temporal steepening. The placido image has irregular mires with some nasal steepening.

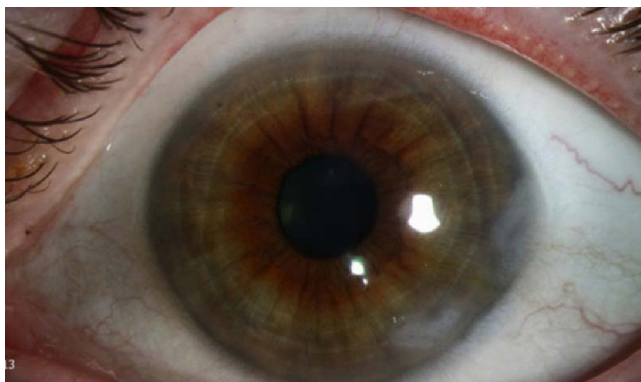


Figure 9: Slit lamp photo of the right eye of another patient with Salzmann's Nodular Corneal Degeneration. Nodules are nasal and inferonasal.

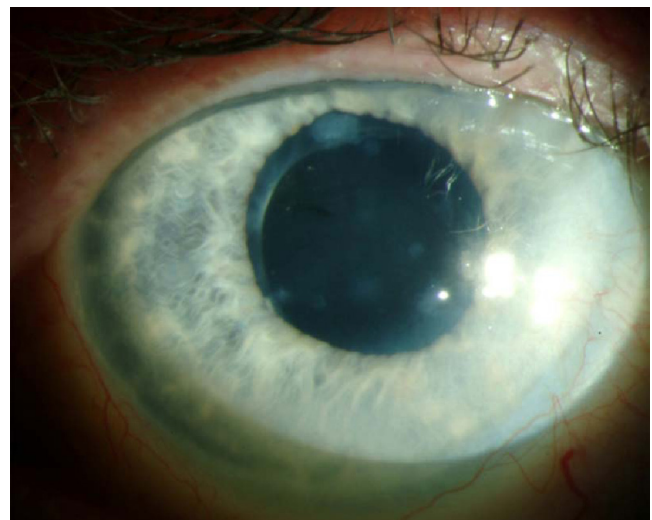

Figure 10: Slit lamp photo of another patient with Salzmann's Nodular Corneal Degeneration. Several small nodules, superior and inferior approach the visual axis.

Summary of the key facts regarding Salzmann's nodular corneal degeneration

<p>Epidemiology</p> <ul style="list-style-type: none"> ◆ Onset often around 50 years of age, but has been reported in ages 13-92 [2] ◆ Female patients account for 75-90% of all cases [1,2]. ◆ Often bilateral [1,2]. ◆ Deposits are progressive ◆ Associated chronic ocular surface inflammation <ul style="list-style-type: none"> • Meibomian gland dysfunction • Contact lens wear • Keratoconjunctivitis sicca • Exposure keratitis • Trachoma 	<p>Signs</p> <ul style="list-style-type: none"> ◆ Bilateral gray-white elevated corneal subepithelial nodules in the paracentral or central cornea or near the limbus with associated pannus, most commonly in an annular distribution [4]. ◆ There is a subset of Salzmann's nodules with associated vascularization [5]. <p>Symptoms</p> <ul style="list-style-type: none"> ◆ Decreased visual acuity ◆ Asymptomatic ◆ Foreign body sensation
<p>Diagnosis</p> <ul style="list-style-type: none"> ◆ Clinical: based on slit lamp exam ◆ Topography: may be helpful for making the diagnosis. Nodules cause irregular astigmatism. ◆ Histopathology: Thin epithelium, thick basement membrane with displaced Bowman layer, and non-specific stromal scarring 	<p>Treatment</p> <ul style="list-style-type: none"> ◆ Superficial keratectomy (SK) is standard to reduce irregular astigmatism. In a large case series SK was successful in 90.2% of eyes [2]. ◆ Phototherapeutic keratectomy has been used in some cases following SK, and a case review has not identified a significant difference in outcomes compared to repeat SK [1]. ◆ Recurrence after SK is common, in one series recurrence occurred in 21.9% after a mean follow-up time of 61 months [2]. Visually significant recurrences occur in only 5-20% of patients [1].

Conclusion

Salzmann's nodular corneal degeneration is a non-inflammatory, slowly progressive nodular corneal degeneration that may induce ocular surface discomfort and progressive astigmatism with decreased best corrected visual acuity. The diagnosis is based on clinical examination. Topography is helpful in evaluating the contribution of the nodule to visual impairment. Superficial keratectomy is a successful treatment option, and visually significant recurrence afterward is relatively rare.

Differential diagnosis [4]

- ◆ Corneal scarring
- ◆ Spheroidal degeneration

References

1. Farjo AA, Halperin GI, Syed N, Sutphin JE, Wagoner MD. Salzmann's Nodular Corneal Degeneration Clinical Characteristics and Surgical Outcomes. *Cornea*. 2006; 25(1): 11-15. [PMID: 16331034]
2. Graue-Hernandez EO, Mannis MJ, Eliasieh K, Greasby TA, Beckett LA, Bradley JC, Schwab IR. Salzmann Nodular Degeneration. *Cornea*. 2010; 29(3):283-9. [PMID: 20098304]
3. Nissirios NJ, Barsam A, Nadji E, Donnenfeld ED, Perry HD. Relationship of Bell Phenomenon with Salzmann Nodular Degeneration. *Cornea*. 2013; 32(7): 939-942. [PMID: 23442252]
4. Das S, Langenbucher A, Pogorelov P, Link B, Seitz B. Long-term outcome of excimer laser phototherapeutic keratectomy for treatment of Salzmann's nodular degeneration. *Journal of Cataract & Refractive Surgery*. 2005;31(7):1386-1391. [PMID: 16105611]
5. Gore DM, Iovieno A, Connell BJ, Alexander R, Meligonis G, Dart JK. Peripheral hypertrophic subepithelial corneal degeneration: nomenclature, phenotypes, and long-term outcomes. *Ophthalmology*. 2013;120(5):892-8. [PMID: 23474249]

6. Hamada S, Darrad K, McDonnell PJ. Salzmann's nodular corneal degeneration (SNCD): Clinical findings, risk factors, prognosis and the role of previous contact lens wear. *Contact Lens and Anterior Eye*. 2011;34(4):173-178. [PMID: 21349758]

Citing this article

Carroll JN, Maltry AC, Kitzmann AS. Salzmann's Nodular Corneal Degeneration: 62-year-old woman presents with 3 years of progressive decrease in vision. *EyeRounds.org*. September 9, 2013; available from <http://EyeRounds.org/cases/180-salzmann-nodular-corneal-degeneration.htm>

last updated: 9/9/2013

Treatment of Epithelial Basement Membrane Dystrophy with Manual Superficial Keratectomy

Leslie T. L. Pham, MD; Kenneth M. Goins, MD; John E. Sutphin, MD; Michael D. Wagoner, MD, PhD

February 22, 2010

Epithelial basement membrane dystrophy (EBMD) is the most common type of corneal dystrophy, affecting 2% of the population.[1] Although the majority of patients remain asymptomatic or experience minor episodic subjective discomfort, about 10% will eventually complain of recurrent erosions and/or visual disturbances.[1,2] The clinical course is often biphasic: Recurrent epithelial erosions predominate in the early phase, and visual disturbances occur in the later phase.

The pathophysiologic hallmark of EBMD is an abnormality in the formation and maintenance of the epithelial basement membrane adhesion complex of the corneal epithelium, a phenomenon that accounts for the recurrent erosions that are associated with this disorder. Originally described by Hansen[3] over a century ago, and further characterized by Thygeson[4] a half century later, recurrent erosions are acute disruptions of the corneal epithelium,

which classically occur upon awakening and are associated with severe, sharp pain that may be transient or last for several hours or days, depending upon the surface area of epithelial sloughing. In severe cases, the erosion syndrome may be associated with considerable morbidity and occupational disability. Although erosions may occur in association with prior corneal trauma, EBMD is the most common cause of this disorder.

Initially, there may be few clinical signs associated with EBMD; however, a history of recurrent erosions should suggest this diagnosis, especially if they are bilateral and occur in multiple sites. With continued cycles of epithelial breakdown and aborted efforts at the development of a stable epithelial basement membrane adhesion complex, morphological changes eventually develop, which lead to

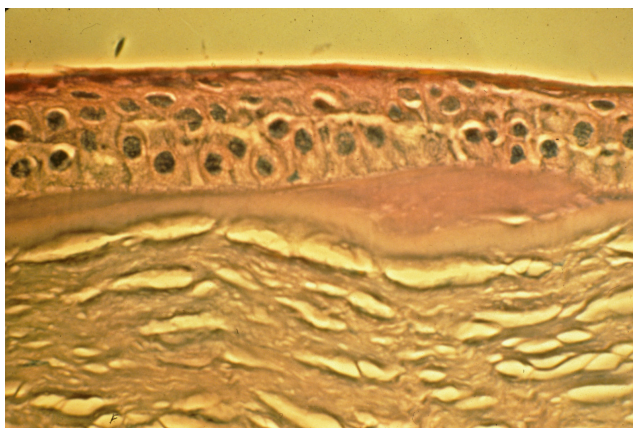
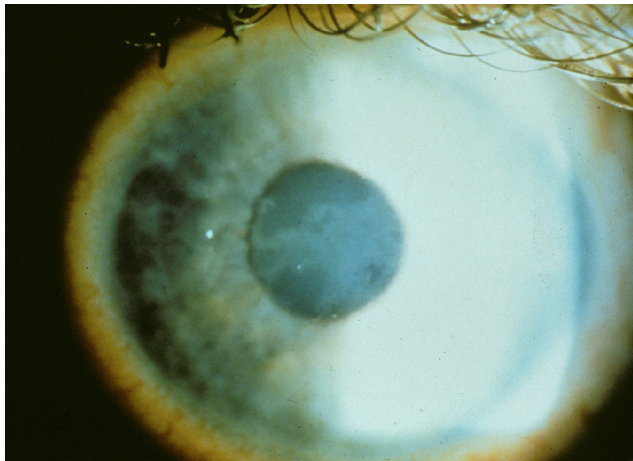


Figure 1. Epithelial basement membrane dystrophy: "map" changes. (A) Clinical appearance. (B) Duplication of the basement membrane correlates with the clinical findings

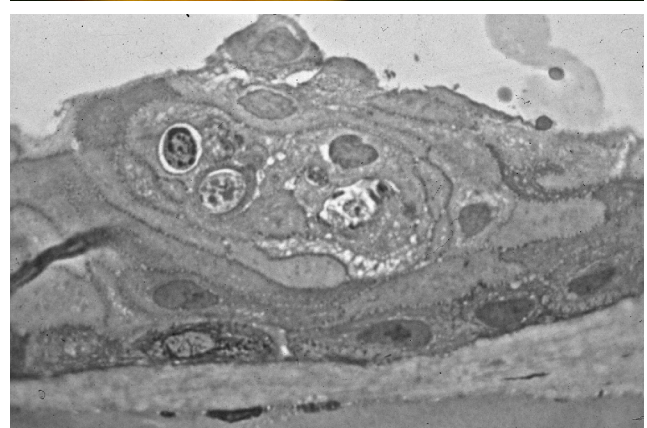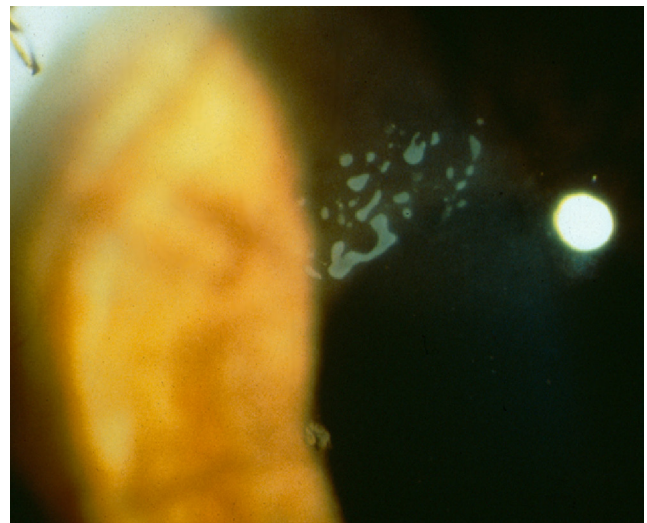


Figure 2. Epithelial basement membrane dystrophy: "dot" changes. (A) Clinical appearance. (B) Intraepithelial deposition of fibrillar material correlates with the clinical findings.

the classic “map-dot-fingerprint” epithelial and subepithelial findings that characterize this disorder (Figures 1-3)[2]. Inadequate formation of hemidesmosomes by the basal epithelial cells results in compensatory aberrant regeneration and duplication of the epithelial basement membrane, a change that is clinically manifested by the “fingerprint” lines. The deposition of fibrogranular material below and above the abnormal basement membrane is responsible for the “map” and “dot” findings, respectively. When present in the visual axis, these epithelial and subepithelial irregularities initially result in irregular astigmatism and induction of higher order optical aberrations, which are subjectively associated with monocular diplopia and visual distortion—often before the development of a decrease in Snellen acuity. However, a progressive decline in Snellen acuity does occur as the morphological abnormalities increase in density, often in association with a paradoxical improvement in the erosion syndrome.

Successful treatment of EBMD is predicated upon optimizing conditions necessary for the formation of stable epithelial basement membrane adhesion complexes throughout the entire cornea, preferably before the development of vision-compromising morphological abnormalities in the visual axis. In most cases of EBMD, recurrent epithelial erosions can be prevented by the bedtime application of a lubricating or hyperosmotic ointment. If mild erosions fre-

quently occur despite bedtime lubrication, the prolonged use of a bandage soft contact lens (SCL) may eliminate or greatly reduce the frequency of symptomatic erosions.

In the event that substantial epithelial erosions develop (Figure 4), more aggressive intervention is indicated. Successful management can be accomplished with manual superficial keratectomy (SK), followed by the reestablishment of an intact corneal epithelium that is firmly adherent and remains optically clear. Clinical and experimental evidence that has accumulated for more than a century regarding the development of the technique of manual SK and its application in this setting is summarized as follows:

- ◆ **Epithelial debridement.** For more than a century, the treatment of choice for recurrent erosions was the simple debridement of devitalized and poorly adherent epithelium and the use of pressure patching until reepithelialization was complete. Although the prolonged subsequent use of bedtime lubricating ointments subsequently resulted in permanent resolution in many cases, recurrent disease remained quite common. In 1983, Buxton and Fox[5] reported a success rate of 85% with

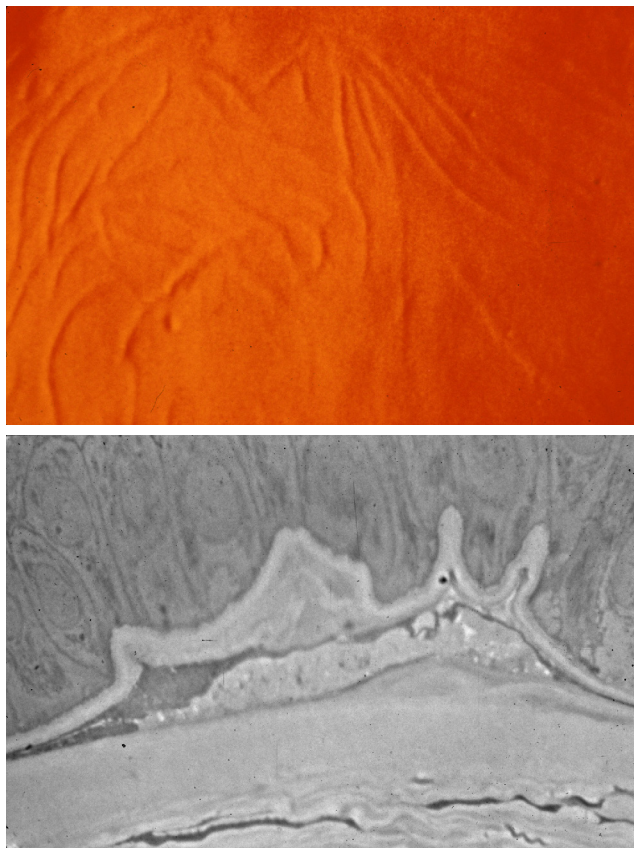


Figure 3. Epithelial basement membrane dystrophy: “fingerprint” changes. (A) These changes are easily seen by retroillumination. (B) Duplication of the epithelial basement membrane correlates with the clinical findings.

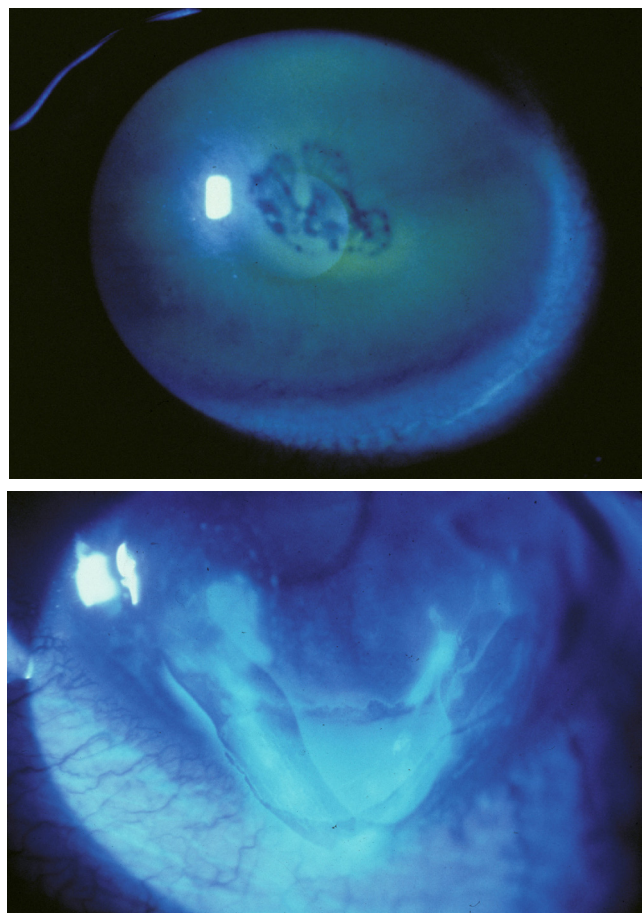


Figure 4. Recurrent corneal epithelial erosions. (A) Small areas of epithelial loss with adjacent areas of rapid tear film breakup associated with poorly adherent corneal epithelium in the axial cornea. (B) Large area of poor adhesion with pseudobullous elevation of the corneal epithelium in the peripheral cornea.

epithelial debridement followed by the extended use of bandage SCL therapy, which facilitated the uninterrupted development of a stable epithelial basement membrane adhesion complex.

- ◆ **Removal of aberrant basement membrane and subepithelial debris and fibrosis.** Simple epithelial debridement may not be effective in removing all the abnormal basement membrane and may be associated with the recurrence of epithelial erosions even after the discontinuation of extended bandage SCL therapy.[6] As early as 1906, Franke[7] reported a reduced rate of recurrent epithelial erosions when epithelial debridement was followed by the application of chlorinated water. Kenyon and Wagoner[2,8] further emphasized the importance of meticulously cleaning the subepithelial debris as an integral part of the management of this disorder.
- ◆ **Disruption of Bowman's layer.** Brown and Bron[6] suggested that some disruption of Bowman's layer may be necessary to maximize the opportunity for permanent resolution of recalcitrant epithelial erosions. Anecdotally, it has long been recognized that substantial trauma to Bowman's layer is associated not only with scarring but also with excellent epithelial adhesion. Accordingly, the guiding principle in managing recalcitrant erosions is striking an appropriate balance between sufficient disruption of Bowman's layer to facilitate firm epithelial adhesion and minimization of visually significant scarring. Broad area treatment of Bowman's layer with iodine was reported by Thygeson[4] in 1954, with diathermy by Wood[9] in 1984, with a diamond burr by Buxton and Constad[10] in 1987, with the neodymium:YAG laser by Geggel[11] in 1990, and subsequently with excimer laser phototherapeutic keratectomy (PTK) by numerous authors.[12,13] Focal disruption of Bowman's layer with anterior stromal puncture was demonstrated by McLean et al.[14] to be effective in the management of most cases of recurrent erosion. Although the anterior stromal puncture marks do not seem to be visually compromising, most authors recommend applying this technique aggressively outside the visual axis and either sparingly or not at all in the visual axis.
- ◆ **Pharmacological control of matrix metalloproteinase-9.** The manual SK techniques of epithelial debridement, removal of aberrant basement membrane and subepithelial debris, and focal disruption of Bowman's layer with stromal puncture, followed by a 6-to-12-week period of bandage SCL therapy, are almost invariably associated with the reestablishment of a firmly adherent corneal epithelium that tends to remain optically clear. However, this outcome is optimized by providing pharmacological intervention that is designed to minimize subepithelial collagenase production and its deleterious impact on the development of the stable epithelial basement membrane adhesion complex during the postoperative period. Durson et al.[15] documented the efficacy of the systemic administration of doxycycline and the topical use of corticosteroids in further improving therapeutic outcomes associated with the medical and surgical management of recurrent erosion syndromes.

In the present study, we reviewed the outcome of treating symptomatic EBMD with manual SK at University of Iowa Hospitals and Clinics (UIHC).

PATIENTS AND METHODS

The medical records of every patient with EBMD who had been treated with manual SK by a member of the Cornea Service at UIHC from January 1, 1998, to December 31, 2007, were retrospectively reviewed. The diagnosis was established by a member of the cornea faculty on the basis of the characteristic clinical findings. Every eye had been treated with at least one mode of medical therapy before undergoing SK, including the use of topical lubrication, hyperosmotic agents, and/or bandage SCL therapy. The indications for surgical intervention were decreased vision and/or recurrent corneal epithelial erosions. Outcome measures included best spectacle-corrected visual acuity (BSCVA), the presence or absence of recurrent erosions, and symptomatic recurrent EBMD. Cases in which more than 3 months of postoperative follow-up were available were included in the statistical analysis. Eyes that had been previously treated with either manual SK or PTK prior to referral to UIHC or before the study period were excluded from the statistical analysis.

Surgical Technique

The surgical procedures were performed with topical anesthesia by members of the cornea faculty (KMG, JES, MDW) in the minor outpatient procedure room. The central corneal epithelium (6.0-8.0 mm) was debrided with a Weck cell sponge in most cases. Occasionally, a no. 57 Beaver blade was required to complete the epithelial removal. Poorly adherent epithelium in the periphery was also debrided when present. A no. 57 Beaver blade was also used to remove the basement membrane and subepithelial fibrosis with gentle scraping. Special precautions were taken to minimize the disturbance of the underlying Bowman's layer. The surface of Bowman's layer was then vigorously smoothed with a Weck cell sponge. In some cases early in the study period, a diamond burr was gently applied to the anterior surface of Bowman's layer. Later in the study period, stromal puncture was directly applied to Bowman's layer outside the visual axis where the epithelium had been debrided and through the epithelium in areas where it remained in place. One surgeon (MDW) applied light treatment in the visual axis in cases where erosions had been documented to occur in this zone or where substantial subepithelial fibrosis had been detected prior to the operative procedure. At the conclusion of the case, a bandage SCL was placed on the eye.

Postoperatively, all patients were treated with topical antibiotics and steroid drops 4 times daily for 1 week. Early in the study period, the bandage SCL therapy was discontinued in most cases after 1 week, the topical antibiotics and steroids were rapidly tapered and discontinued, and bedtime lubricating ointment was continued for at least 3 months. Later in the study period, the bandage SCL therapy was continued for 6 to 12 weeks in most cases, along

with the administration of prophylactic topical antibiotics. In the latter half of the study, most patients were concomitantly treated with systemic doxycycline and topical corticosteroids until the bandage SCL therapy was completed.

RESULTS

Of 20 patients (14 men; 6 women), 22 eyes with EBMD were treated with manual SK for decreased vision (20 eyes) and/or recurrent epithelial erosions (15 eyes). The mean follow-up after surgery was 43.6 months (range, 3.0-115.2 months).

The treatment outcomes for decreased visual acuity are summarized in Table 1. Improvement was detected in BSCVA from a mean preoperative logMAR acuity of 0.313 (Snellen equivalent 20/41) to a best postoperative acuity of 0.038 (20/22) and a final acuity of 0.079 (20/24). A BSCVA of 20/20 or better was achieved in 12 (60.0%) eyes, and the same result was achieved at the most recent examination in 10 (50.0%) eyes. A BSCVA of 20/30 or better was achieved in 20 (100.0%) eyes, and the same result was achieved at the most recent examination in 19 (95.0%) eyes.

All 15 (100.0%) eyes with recurrent erosions had complete resolution of symptoms during the first 6 postoperative months. Between 6 and 60 months after initial treatment, 3 (20.0%) eyes experienced recurrent erosions. Among these, 2 eyes were successfully treated with a course of bandage SCL therapy, and 1 eye was successfully treated with excimer laser PTK.

No surgical complications resulted from any of the manual SK procedures.

DISCUSSION

Our study strongly suggests that manual SK is a safe and effective treatment for visual disturbances and recurrent

epithelial erosions associated with EBMD. No complications occurred in any of the 22 eyes treated with manual SK. Furthermore, all 20 eyes treated for visual disturbances experienced a sustained improvement in vision for the entire follow-up period. Although it would be intuitive to anticipate that the same morphological abnormalities would occur postoperatively in this genetic disorder, the establishment of stable epithelial basement membrane adhesion complexes and the reduction of recurrent epithelial erosions in the visual axis either completely prevents or substantially retards the recurrence of these changes and their adverse effects on visual function. Every patient experienced complete relief of recurrent erosion symptoms during the first 6 months, with only 3 experiencing symptoms in the subsequent decade. Among these, 2 cases were relatively minor and were managed with a 3-month course of bandage SCL therapy. One case was troublesome and required treatment of the entire basement membrane of the affected eye with excimer laser PTK.

Obtaining a lasting and satisfactory result with manual SK requires meticulous attention to the surgical technique, especially the thorough removal of all abnormal subepithelial pathology in the visual axis and the use of anterior stromal puncture, prolonged postoperative bandage SCL therapy, and appropriate pharmacological support. This technique is effective in providing a sustained improvement in the spectacle acuity of virtually every patient and relief from recurrent erosions in the vast majority of patients. It is preferred over broad area ablation with the excimer laser because it is much less expensive, is not associated with a hyperopic shift in the baseline refractive error, and is less likely to induce visually significant haze in the visual axis (Table 2).^{12,13} Nonetheless, it will occasionally be necessary to offer excimer laser PTK to the small percentage of patients in which manual SK is not completely successful in providing sustained relief from recurrent erosions, as was the case with 1 patient in the present series.

Best Spectacle-corrected Visual Acuity			
Vision	Preoperative	Best Obtained	Final
LogMAR			
Mean	0.313	0.038	0.079
Range	0.097 to 0.903	-0.125 to 0.176	-0.125 to 0.477
Snellen			
Mean	20/41	20/22	20/24
Range	20/25 to 20/160	20/15 to 20/30	20/15 to 20/60
Cumulative, %			
≥20/20	0	60	50
≥20/25	25	85	65
≥20/30	55	100	95
≥20/40	65	100	95

Table 1. Manual Superficial Keratectomy for Decreased Visual Acuity Associated with Epithelial Basement Membrane Dystrophy (n = 20)

	Manual SK	PTK
Cost	Inexpensive	Expensive
Equipment	Simple surgical instruments are sufficient	Excimer laser required
Surgical skill	Minimal training required	Certification course required
Postoperative morbidity	Pain may be present until epithelial defect resolves; minimal risk of corneal infection; virtually no risk of visually significant haze or scar formation	Pain may be present until epithelial defect resolves; minimal risk of corneal infection; significant haze or scar formation (especially if large refractive errors are treated)
Efficacy	Excellent prognosis for improved vision and resolution of recurrent epithelial erosions	Excellent prognosis for improved vision and resolution of recurrent epithelial erosions
Refractive changes	Little or no change in spherical refractive error	Hyperopic shift may occur
Retreatment	Simple and inexpensive	Simple but expensive

Table 2. Manual Superficial Keratectomy (SK) Versus Excimer Laser Phototherapeutic Keratectomy (PTK) for Treatment of Epithelial Basement Membrane Dystrophy

Excimer laser PTK may be offered in combination with photorefractive keratectomy (PRK) in primary therapy of EBMD if the therapeutic objective is to attain an improvement in uncorrected visual acuity. If this approach is adopted, the treating ophthalmologist must be cognizant of the potential that some of the measured refractive error may be factitiously induced by the epithelial and subepithelial morphological abnormalities associated with EBMD and that the refractive accuracy of PRK cannot be predicted with certainty. In such cases, a more conservative approach would be to perform a 2-stage procedure consisting of manual SK followed by PRK (after the refractive error has stabilized and can be measured accurately).

References

1. Waring GO 3rd, Rodriques MM, Laibson PR. Corneal dystrophies I. Dystrophies of the epithelium, Bowman's layer, and stroma. *Surv Ophthalmol.* 1978;23:71-122.
2. Kenyon KR, Wagoner MD. Corneal epithelial defects and noninfectious ulceration. In: Albert DM, Jakobiec FA, eds. *Principles and Practice of Ophthalmology.* Vol 2. 2nd ed. Philadelphia, Pa: WB Saunders; 2000:926-943.
3. Hansen E. Om den intermettende keratitis vesiculosa neuralgica af traumatisk oprndelse. *Hosp Tidende.* 1872;15:201-203.
4. Thygeson P. Observations on recurrent epithelial erosion of the cornea. *Am J Ophthalmol.* 1959;27:48-52.
5. Buxton JN, Fox ML. Superficial keratectomy in the treatment of epithelial basement membrane dystrophy: a preliminary report. *Arch Ophthalmol.* 1983;101:392-395.
6. Brown N, Bron A. Recurrent erosion of the cornea. *Br J Ophthalmol.* 1976;60:84-86.
7. Franke E. Uber Erkrankungen des Epithels der Hornhaut. *Klin Monatsbl Augenheilkd.* 1906;44:508-532.
8. Wagoner MD, Kenyon KR. Keratectomy and lamellar keratoplasty. In: Bruner WE, Stark WJ, Maumenee AE, eds. *A Manual of Corneal Surgery.* New York, NY: Churchill Livingstone; 1987:29-38.
9. Wood TO. Recurrent erosion. *Trans Am Ophthalmol Soc.* 1984;82:850-898.
10. Buxton JN, Constad WH. Superficial epithelial keratectomy in the treatment of epithelial basement membrane dystrophy. *Ann Ophthalmol.* 1987;19:92-96.
11. Geggel HS. Successful treatment of recurrent corneal erosion with Nd:YAG anterior stromal puncture. *Am J Ophthalmol.* 1990;110:404-407.
12. Hersh PS, Wagoner MD. *Excimer Laser Surgery for Corneal Disorders.* New York/Stuttgart: Thieme Medical Publishers; 1998.
13. Hersh PS, Klein S, Wagoner MD. Phototherapeutic keratectomy. In: Krachmer JH, Mannis MJ, Holland EJ, eds. *Cornea.* Vol 2. 2nd ed. St Louis, Mo: Mosby; 2005: 1735-1747.
14. McLean EN, MacRae SM, Rich LF. Recurrent erosion. Treatment by anterior stromal puncture. *Ophthalmology.* 1986;784-788.
15. Dursun D, Kim MC, Solomon A, Pflugfelder SC. Treatment of recalcitrant recurrent corneal erosions with inhibitors of matrix metalloproteinase-9, doxycycline and corticosteroids. *Am J Ophthalmol.* 2001;132:8-13.

Suggested Citation Format

Pham LTL, Goins, KM, Sutphin JE, Wagoner MD. Treatment of Epithelial Basement Membrane Dystrophy With Manual Superficial Keratectomy. *EyeRounds.org.* Feb 22, 2010; Available from: <http://www.eyerounds.org/cases/78-EBMD-treatment.htm>

last updated: 02-22-2010

Acute Corneal Hydrops

Miles F. Greenwald BS, Jesse M. Vislisel MD, Kenneth M. Goins MD

Posted: August 3, 2016

INITIAL PRESENTATION

Chief Complaint

Poor vision and pain in the left eye

History of Present Illness

A 51-year-old male with keratoconus and history of rigid gas permeable (RGP) contact lens wear in the left eye presented with left eye redness, pain, light sensitivity, and tearing for 1 week. He was initially seen at an acute care clinic where he was told he had scratched his conjunctiva. He then presented to his regular ophthalmologist who found him to have acute corneal edema and referred him to the University of Iowa Hospitals and Clinics (UIHC). He was started on ciprofloxacin and hypertonic saline drops by the outside provider. At the time of his presentation, his pain was rated as 7 out of 10 and described as a constant surface irritation and scratchy sensation. He described constant tearing and blurry vision which did not change throughout the day. The patient took out his contact lens when symptoms began.

Past Ocular History

- ◆ Keratoconus
- ◆ RGP contact lens wear in the left eye, soft contact lens wear in the right eye
- ◆ Mild dry eye syndrome, both eyes
- ◆ No history of ocular surgery or trauma

Past Medical History

- ◆ Non-contributory

Medications

- ◆ Ciprofloxacin drops three times daily in the left eye
- ◆ Sodium chloride 5% (Muro 128) drops four times daily in the left eye
- ◆ Artificial tears as needed in both eyes

Allergies

- ◆ None

Family Ocular History

- ◆ Mother has had several ocular surgeries and treatment for an unknown disorder

Social History

- ◆ Works as an educational product distributor and travels frequently for work

Review of Systems

- ◆ Negative except for what is detailed in the history of present illness

OCULAR EXAMINATION

Visual Acuity (Snellen chart)

- ◆ Right eye (OD): 20/20 with soft contact lens
- ◆ Left eye (OS): 20/100 without correction, pinhole to 20/60

Intraocular Pressure (Tonopen)

- ◆ OD: 17 mmHg
- ◆ OS: 24 mmHg

Confrontation Visual Fields

- ◆ Full in both eyes

Pupils

- ◆ No relative afferent pupillary defect in either eye

Extraocular Motility

- ◆ Full in both eyes

Pachymetry

- ◆ OD: 541 μ m
- ◆ OS: Unable to measure

External

- ◆ Epiphora in left eye, appears to be in discomfort

Slit Lamp Exam OS (Figure 1)

- ◆ Lid/lashes: Reactive ptosis
- ◆ Conjunctiva/sclera: Diffuse 1+ injection
- ◆ Cornea: Inferior conical protrusion, focal area of massive inferior corneal edema with overlying microcystic edema and bullae, epithelium intact, no infiltrates or keratic precipitates
- ◆ Anterior chamber: Deep, rare cell
- ◆ Iris: Normal architecture, dilated
- ◆ Lens: Trace nuclear sclerosis

Differential Diagnosis

- ◆ Acute corneal hydrops
- ◆ Infectious keratitis
- ◆ Autoimmune keratitis
- ◆ Traumatic posterior annular keratopathy

- ◆ Post-surgical Descemet's membrane detachment
- ◆ Fuchs corneal endothelial dystrophy
- ◆ Posterior polymorphous corneal dystrophy
- ◆ Iridocorneal endothelial syndrome

Additional testing

Anterior Segment Optical Coherence Tomography (OCT) (Figure 2) showed massive inferior corneal edema and overlying epithelial bullae.

Diagnosis

Acute corneal hydrops in the setting of keratoconus

CLINICAL COURSE

Initial conservative management included prednisolone 4 times daily, sodium chloride 5% (Muro 128) drops 4 times daily, and cyclopentolate 2 times daily in the affected eye. A Kontur bandage contact lens was placed for comfort. The patient was placed on timolol once daily to treat the ocular hypertension caused by reactive inflammation.

Placement of an anterior chamber sulfur hexafluoride (SF6) gas bubble was offered to speed his recovery, but due to upcoming travel necessitating air travel and inability to position due to work requirements, he declined.

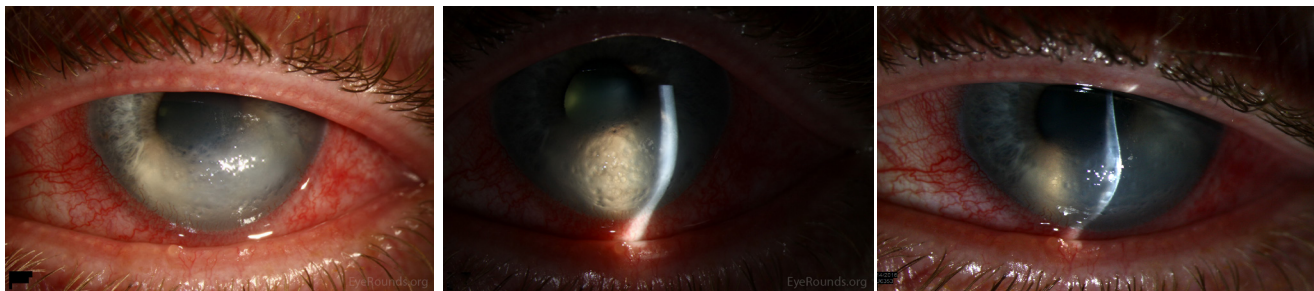


Figure 1

a: Broad illumination of the left eye showing severe, inferior corneal edema.

b: Broad slit beam view of left eye showing microcystic edema and bullae overlying the area of stromal edema.

c: Narrow slit beam demonstrating the inferior conical protrusion and magnitude of corneal edema.

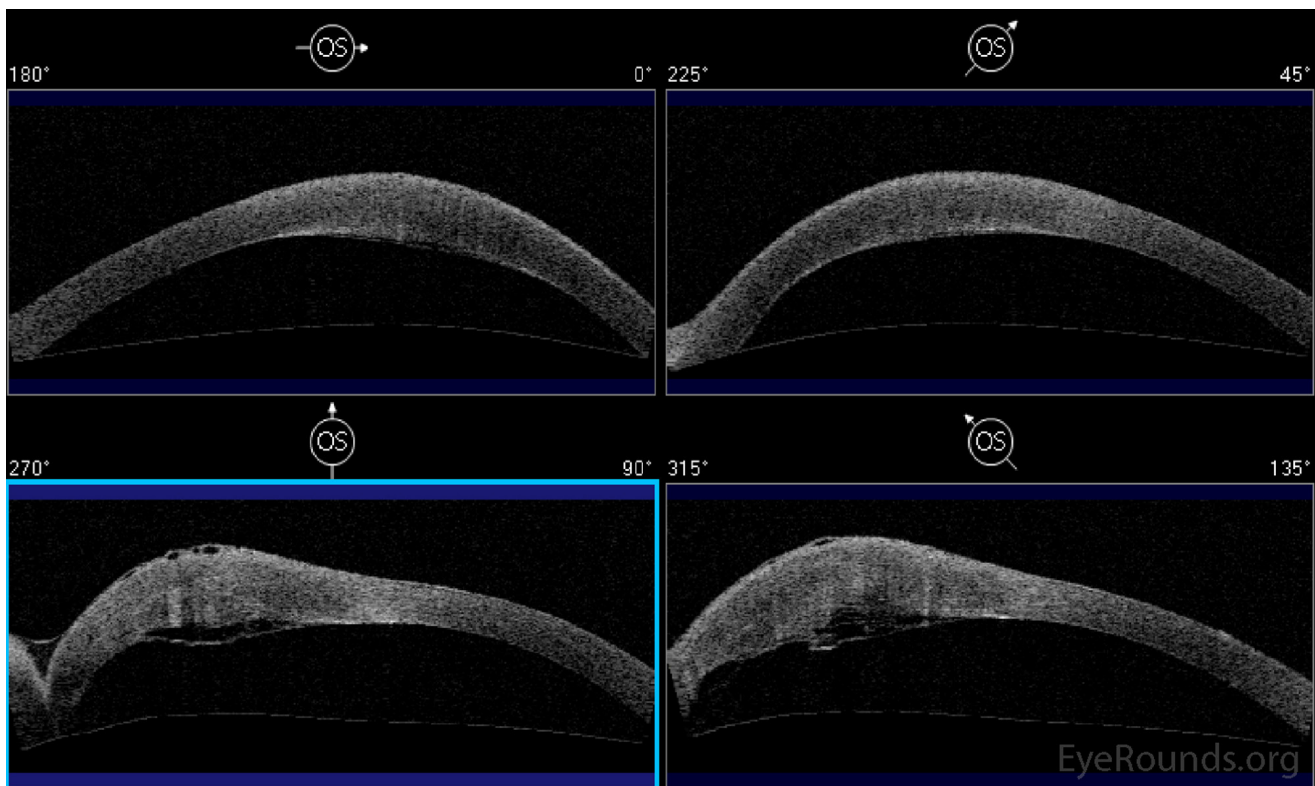


Figure 2: Anterior segment OCT showing massive inferior corneal edema and overlying epithelial bullae. A break in Descemet's membrane with Descemet's membrane detachment is visible below the area of edema.

The edema gradually improved and 3 weeks later he was found to have some improvement in corneal clarity, but a large amount of scarring and contour irregularity in the area of the hydrops. A penetrating keratoplasty (PK) was performed for restoration of vision.

DISCUSSION

Etiology/Epidemiology

Acute corneal hydrops is caused by the acute disruption of Descemet's membrane in the setting of corneal ectasia. Hydrops is a term used to denote an abnormal accumulation of fluid in a body tissue or cavity. The term is also used to describe fetal swelling in utero, often due to Rh blood group isoimmunization (hydrops fetalis). Acute corneal hydrops occurs in approximately 3% of patients with keratoconus. Although most cases of hydrops are associated with keratoconus due to the prevalence of the disease, the incidence of hydrops is actually higher in other corneal ectatic disorders such as pellucid marginal degeneration (see <http://EyeRounds.org/atlas/pages/Pellucid-marginal-degeneration>) and keratoglobus, with some reports being as high as 11% [1-2]. The average age of onset is typically around 25 years of age, with males being more commonly affected than females [3]. A history of eye rubbing and seasonal allergies is associated with hydrops development [1,3].

Pathophysiology and Natural History

The focal corneal edema of acute hydrops results from the compromise of the barrier function of Descemet's membrane and subsequent fluid uptake by the overlying corneal stroma. It has been postulated that resolution of hydrops requires two steps. First, the detached Descemet's membrane must reattach to the posterior stroma. This process is dependent on the depth of the detachment. Second, the endothelium must migrate from the reattached Descemet's membrane to cover the gaps between the broken ends. This process depends on the size of the break [4].

Most cases of acute corneal hydrops spontaneously resolve over 2-4 months [5-7]. Depending on the degree of swelling and timeline of resolution, vision-impairing scarring can necessitate the need for corneal transplantation. Larger disruptions of Descemet's membrane are associated with more prolonged resolution of corneal edema, increased risk of neovascularization, and a worsened visual outcome after final resolution of edema compared to smaller disruptions of Descemet's membrane [8].

Signs/Symptoms

Clinical manifestations of acute corneal hydrops include severe corneal edema with a corresponding reduction in visual acuity. Epiphora, photophobia, and pain may also occur. If these manifestations are seen in patients with previously diagnosed corneal ectasia and/or evidence of

corneal ectasia, the diagnosis of acute corneal hydrops can be made [9].

Imaging

Anterior segment optical coherence tomography (AS-OCT) is not required for diagnosis but can be helpful to quantify the extent and location of corneal edema and the extent of the break in Descemet's membrane. Imaging techniques such as AS-OCT also allow improved ability to monitor the response to treatment [9].

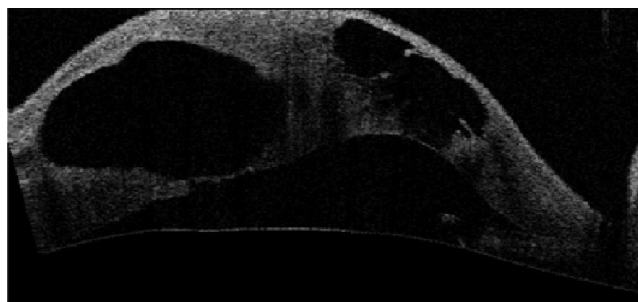


Figure 3: AS-OCT showing large, cystic intrastromal accumulation of fluid in a patient with keratoconus and acute corneal hydrops.

Treatment

Due to the spontaneous resolution of acute corneal hydrops, classical treatment is focused on medical therapy to increase patient comfort and prevent permanent sequelae. Conservative management for acute corneal hydrops includes hypertonic sodium chloride to reduce epithelial edema, and cycloplegia for comfort. Topical steroids are controversial, but we often employ them to reduce the inflammation and subsequent neovascularization that can accompany these episodes. A bandage contact lens can be placed for comfort, but a large diameter soft lens may be necessary to fit the steep contours of these eyes.

Pneumatic descemetopexy, or placement of an anterior chamber air or gas bubble to tamponade the Descemet's membrane break, has been shown to speed recovery following acute hydrops [5-7]. In the last 15 years, this practice has gained popularity because of its ability to significantly reduce the time needed for the resolution of edema. The quicker recovery not only shortens the period of discomfort and poor vision for the patient, but theoretically decreases the risk of visually-significant scarring and need for post-resolution corneal transplantation [5-7,9]. Miyata and colleagues found that the corneal edema lasted an average of 20 days in a group of 9 patients receiving intracameral air compared to 65 days for a control group of 21 patients. The treatment group was able to return to hard contact lens use in one-fourth the time of the control group. However, there was no difference in final best corrected visual acuity after the complete resolution of edema [5]. Panda and colleagues showed that corneal hydrops resolved at an average of 4 weeks in 9 patients who received injections of intracameral SF6 gas compared to 12 weeks

in the control group of 9 patients. This study showed that the treatment group had slightly better best corrected visual acuity, but it was measured at 12 weeks and not after resolution of edema [6]. Basu and colleagues, using C3F8 gas and a much larger group of patients, showed that the edema resolved significantly quicker in the treatment group (57 days for 62 eyes vs. 104 days for 90 control eyes ($p < 0.0001$)). Notably, best corrected visual acuity was not significantly different between the two groups [7]. Ting and Srinivasan reported using C2F6 gas with a similar increase in the rate of edema resolution to the previous studies [10]. No study has yet found a difference in the need for corneal transplantation between those who received a gas or air bubble and those who did not. Several groups have reported using an air bubble along with sutures through Descemet's membrane to even more tightly re-adhere the membrane after hydrops [11-12].

The choice between air and gas depends on the estimated amount of time needed to repair the defect in Descemet's membrane. Air lasts the shortest duration, often only 2-3 days, which may require repeat bubble placement to achieve the desired effect. This was seen in the study by Miyata et al. where 78% of patients required the placement of more than one bubble [5]. At our institution, SF6 is normally utilized with the duration of 7-10 days typically being sufficient to allow for re-apposition and healing of Descemet's membrane.

Penetrating keratoplasty (Figure 4) can be performed to treat the underlying ectatic disorder and any corneal stromal scarring that may result from the hydrops. Deep anterior lamellar keratoplasty (DALK) is extremely challenging to perform following hydrops due to difficulty separating Descemet's membrane from the posterior stroma in the setting of a Descemet's break and the posterior scarring that often accompanies these episodes. Thus, PK is usually our procedure of choice for these patients. When reviewing PK outcomes in ectatic patients who previously developed hydrops, studies have been inconclusive regarding differences in graft survival between grafts with prior episodes of hydrops and grafts without prior hydrops [13-14]. Basu et al. recently compared the allograft survival in the absence of rejection for keratoconus eyes with and without hydrops and found eyes with hydrops had significantly decreased graft survival (83% 5 year rejection-free graft survival in 32 hydrops eyes vs. 98% in 70 non-hydrops eyes) [15]. The proposed mechanism for this increase in graft rejection and failure rates is the presence of intraocular inflammation that accompanies hydrops. While corneal graft success rates decrease somewhat following hydrops, these patients still often have excellent postoperative outcomes.

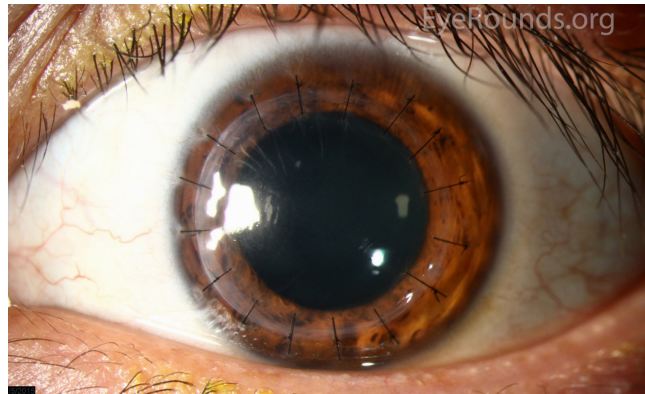


Figure 4: Penetrating keratoplasty performed for keratoconus [17]

Treatment/Management Guidelines

<p>EPIDEMIOLOGY</p> <ul style="list-style-type: none"> ◆ Occurs in 3% of those with keratoconus and 11% of those with pellucid marginal degeneration or keratoglobus ◆ Associated with ocular allergies and eye rubbing 	<p>SIGNS</p> <ul style="list-style-type: none"> ◆ Reduced visual acuity ◆ Conjunctival injection ◆ Corneal edema ◆ Signs of underlying corneal ectasia
<p>SYMPTOMS</p> <ul style="list-style-type: none"> ◆ Decreased vision ◆ Eye pain or irritation ◆ Eye redness ◆ Tearing ◆ Light sensitivity 	<p>TREATMENT/MANAGEMENT</p> <ul style="list-style-type: none"> ◆ Conservative treatment <ul style="list-style-type: none"> ● Cycloplegia ● Hypertonic saline ● Topical steroids ● A bandage contact lens may be placed for comfort ● Injection of anterior chamber air or gas may accelerate recovery ◆ Penetrating keratoplasty for definitive treatment

REFERENCES

1. Grewal S, Laibson P, Cohen E, et al. Acute hydrops in the corneal ectasias: associated factors and outcomes. *Am J Ophthalmol.* 2000;129(5):702-3. [PMID 10844084]
2. Sridhar MS, Mahesh S, Bansal AK, et al. Pellucid marginal corneal degeneration. *Ophthalmology.* 2004;111(6):1102-7. [PMID 15177959]
3. Fan gaskin JC, Good WR, Jordan CA, et al. The Auckland keratoconus study: identifying predictors of acute corneal hydrops in keratoconus. *Clin Exp Optom.* 2013;96(2):208-13. [PMID 23432147]
4. Basu S, Vaddavalli PK, et. al. Anterior segment optical coherence tomography features of acute corneal hydrops. *Cornea.* 2012;31(5):479-85. [PMID 15177959]
5. Miyata K, Tsuji H, Tanabe T, et al. Intracameral air injection for acute hydrops in keratoconus. *Am J Ophthalmol.* 2002;133(6):750-2. [PMID 1203664]
6. Panda A, Aggarwal A, Madhavi P, et al. Management of acute corneal hydrops secondary to keratoconus with intracameral injection of sulfur hexafluoride (SF6). *Cornea.* 2007;26(9):1067-9. Inoue Y. Review of clinical and basic approaches to corneal endotheliitis. *Cornea.* 2014;33 Suppl 11:S3-8. [PMID 17893535]
7. Basu S, Vaddavalli PK, Ramappa M, et al. Intracameral perfluoropropane gas in the treatment of acute corneal hydrops. *Ophthalmology.* 2011;118(5):934-9. [PMID 21211841]
8. Al suhaibani AH, Al-rajhi AA, Al-motowa S, et al. Inverse relationship between age and severity and sequelae of acute corneal hydrops associated with keratoconus. *Br J Ophthalmol.* 2007;91(7):984-5. [PMID 17576720]
9. Fan gaskin JC, Patel DV, Mcghee CN. Acute corneal hydrops in keratoconus - new perspectives. *Am J Ophthalmol.* 2014;157(5):921-8. [PMID 24491416]
10. Ting DS, Srinivasan S. Pneumodescemetopexy with perfluoroethane (C2F6) for the treatment of acute hydrops secondary to keratoconus. *Eye (Lond).* 2014;28(7):847-51. [PMID 23833179]
11. Rajaraman R, Singh S, Raghavan A, Karkhanis A. Efficacy and safety of intracameral perfluoropropane (C3F8) tamponade and compression sutures for the management of acute corneal hydrops. *Cornea.* 2009;28(3):317-20. [PMID 19387234]
12. Yahia chérif H, Gueudry J, Afriat M, et al. Efficacy and safety of pre-Descemet's membrane sutures for the management of acute corneal hydrops in keratoconus. *Br J Ophthalmol.* 2015;99(6):773-7. [PMID 25563765]
13. Tuft SJ, Gregory WM, Buckley RJ. Acute corneal hydrops in keratoconus. *Ophthalmology.* 1994;101(10):1738-44. [PMID 7936572]
14. Akova YA, Dabil H, Kavalcioglu O, Duman S. Clinical features and keratoplasty results in keratoconus complicated by acute hydrops. *Ocul Immunol Inflamm.* 2000;8(2):101-9. [PMID 10980682]
15. Basu S, Reddy JC, Vaddavalli PK, et al. Long-term outcomes of penetrating keratoplasty for keratoconus with resolved corneal hydrops. *Cornea.* 2012;31(6):615-20 [PMID 22236783]
16. Donaghy CL, Vislisel JM, Greiner MA. An Introduction to Corneal Transplantation. May 21, 2015; Available from: <http://EyeRounds.org/tutorials/cornea-transplant-intro/>

Suggested Citation Format

Greenwald MF, Vislisel JM, Goins KM. Acute Corneal Hydrops. *EyeRounds.org.* August 3, 2016; Available from: <http://EyeRounds.org/cases/241-acute-corneal-hydrops.htm>

last updated: 08/01/2016

Case Presentations

Cataract

Marfan Syndrome

Jeffrey Welder, MD; Erik L. Nylén, MSE; Thomas A. Oetting, MS, MD

May 6, 2010

Initial Presentation

Chief Complaint: Decreased vision and glare in both eyes.

History of Present Illness: A 28-year-old female with a history of Marfan syndrome presented to the comprehensive ophthalmology clinic reporting a progressive decrease in vision and worsening glare in both eyes. She had been seen by ophthalmologists in the past, and had been told that her crystalline lenses were subluxed in both eyes. She had not had problems with her vision until recent months.

Medical History: Marfan syndrome with aortic stenosis followed by cardiology

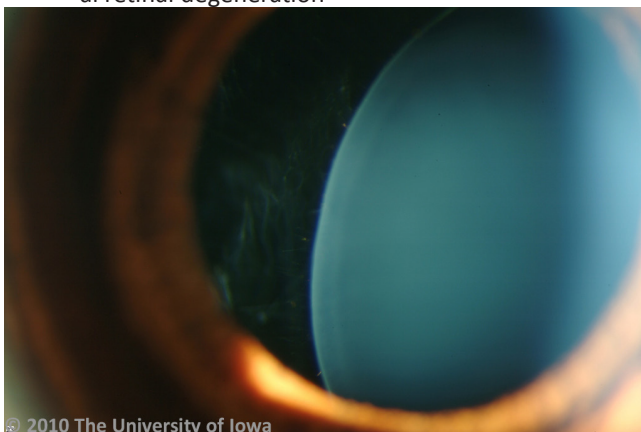
Medications: Oral beta blocker

Family History: No known family members with Marfan Syndrome. Grandmother with glaucoma

Social History: The patient is a graduate student.


Ocular Exam

- ◆ External Exam Normal.
- ◆ Visual Acuity (with correction)
 - OD 20/40
 - OS 20/50
- ◆ Current glasses: OD: 6.75+ 5.00 x 135 OS: -5.25 + 4.25 x 60
- ◆ Pupils: No anisocoria and no relative afferent pupillary defect
- ◆ Motility: Ocular motility full OU.
- ◆ Anterior segment exam
 - Inferiorly subluxed lenses OU (figure 1 and 2).
 - The angle was deep OU and there was no lens apposition to the cornea in either eye.
- ◆ Dilated funduscopic exam
 - Posterior segment was normal OU with no peripheral retinal degeneration



© 2010 The University of Iowa

Figure 1: Note the inferiorly subluxed lens.



© 2010 The University of Iowa

Figure 2: Inferior lens subluxation highlighted with retroillumination

Clinical Course

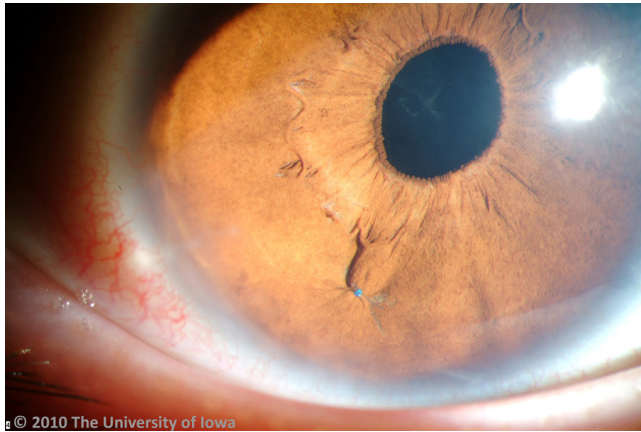
The patient's subluxed lenses led to poor vision from peripheral lenticular irregular astigmatism and glare. She was taken to the operating room where her relatively clear lenses were removed and iris sutured intraocular lenses were placed. The surgical video for one eye is shown below.

Video: <https://www.facebook.com/cataract.surgery/videos/153379281140/>

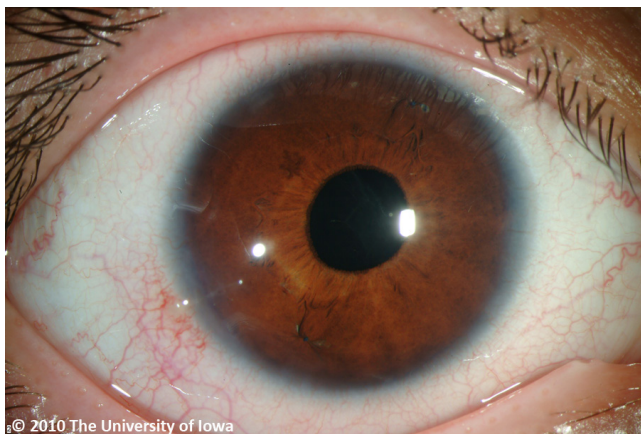
Her post-operative course was unremarkable with excellent improvement in her visual function. Her iris-sutured intraocular lenses have remained stable for several years as shown in figure 3 and 4.

Discussion

Marfan syndrome is a pleiotropic autosomal dominant genetic disorder that results in weakening of connective tissue in the musculoskeletal, cardiovascular and ocular organ systems. It is the second most common inherited connective tissue disorder, with an incidence of between 1/5,000 and 1/20,000. The abnormality in over 80% of Marfan patients involves defects in the protein fibrillin 1 (FBN1) on chromosome 15, a structural component of microfibrils found in connective tissue throughout the body. More than 500 different mutations in the FBN1 gene have been identified. Another mutation believed to result in the Marfan phenotype is the inactivation of the TGF- β receptor 2 (TGFBR2), thought to disrupt the integration of fibrillin into connective tissue.



© 2010 The University of Iowa
Figure 4: Note the Prolene suture securing the lens to the iris



© 2010 The University of Iowa
Figure 3: Centered iris-sutured intraocular lens several years after surgery

The diagnosis of Marfan syndrome is complicated by a genotype-phenotype inconsistency that presents with widely variable clinical manifestations. Clinical diagnosis is currently based on Ghent Nosology (1996) which specifies the involvement of at least 3 organ systems (Skeletal, ocular, cardiovascular, dura mater, pulmonary, or skin/integument), 2 of which must meet "major criteria." Marfan syndrome can also be diagnosed with equivocal genetic testing, which can be offered to patients in the context of family planning and pedigree formation.

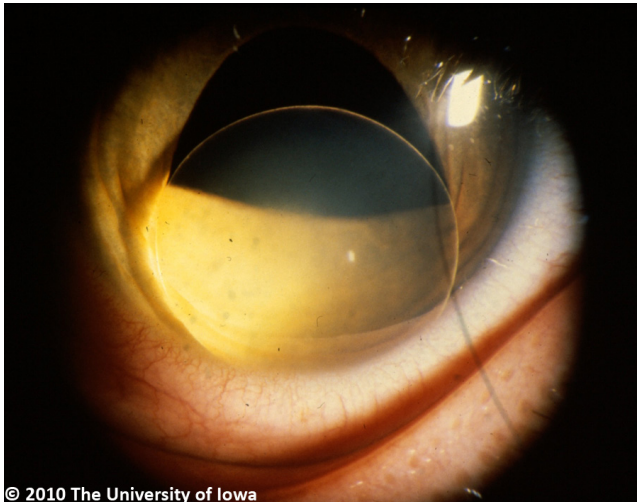
The systemic manifestations of Marfan syndrome are well-studied, the most obvious of which are the musculoskeletal abnormalities. Again, the common thread in the variety of Marfan phenotypes is the weakness or incompetence of the connective tissues due to defects in fibrillin. The Marfan patient is often very tall with long, flexible extremities and marked scoliosis. They exhibit arachnodactyly (spider fingers, see Figure 5) with the ability to dramatically encircle the wrist (Walker-Murdoch sign). In addition, they often have pectus excavatum, a high-arched palate, and facial abnormalities. The cardiovascular findings range from mild mitral valve prolapse to severe aortic aneurysm or dissection; the severe cardiovascular complications are the primary causes of mortality among Marfan patients.

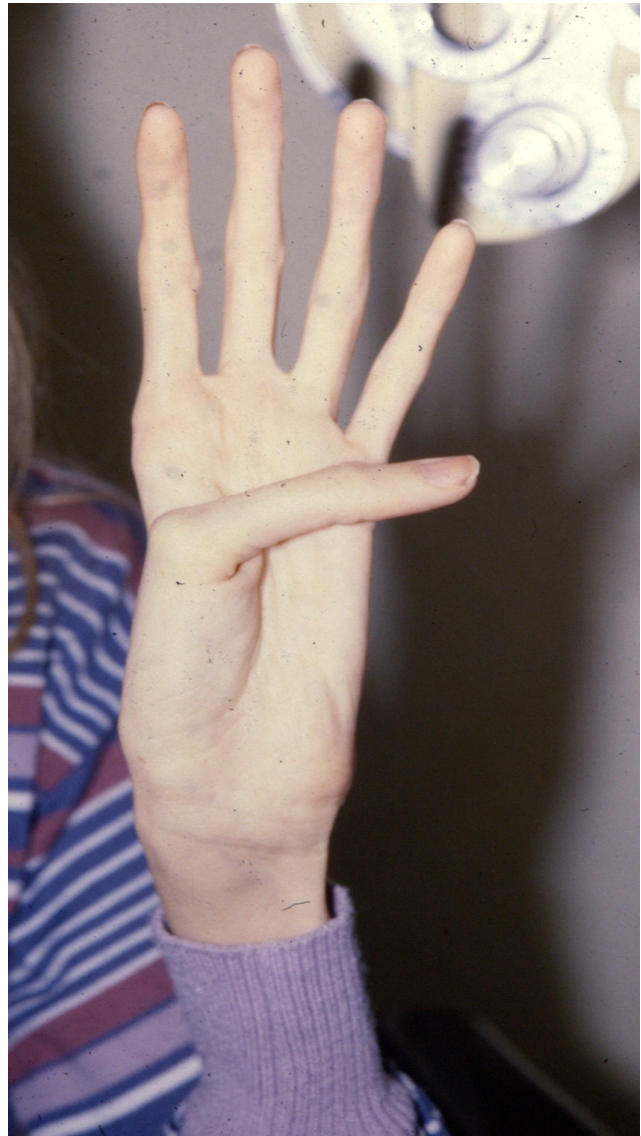

Figure 5: Arachnodactyly (spider fingers)

Pulmonary diseases include apical blebs or spontaneous pneumothorax.

The major ocular abnormality in Marfan syndrome is ectopia lentis (lens subluxation or dislocation, see Figure 6). While relatively little is known about the exact mechanism of this ocular pathology in Marfan syndrome, a number of theories have been suggested. Wheatley et. al (1995) found that while fibrillin is localized to the superficial capsule and ciliary epithelial surface at the attachment of the zonules in normal eyes, Marfan patients lack such localization and exhibit abnormal ciliary processes with absent or severely disorganized zonules. This pathology was found to be positively correlated with lens subluxation. Clinically, ectopia lentis is bilateral in 60-87% of Marfan patients and is stable from childhood. Symptoms include fluctuating blurred vision, monocular diplopia, and pain. On exam, patients demonstrate refractive instability with myopia and astigmatism, iridodonesis, phacodonesis, and a recessed angle. The most common direction of dislocation on exam



© 2010 The University of Iowa

Figure 6: Ectopia Lentis (lens subluxation or dislocation)

is superotemporal. In addition, there may be secondary complications from lens movement such as phacolytic uveitis from posterior subluxation of the lens to the vitreous.

Retinal tears and detachments are also quite common in patients with Marfan syndrome. The Marfan eye has many risk factors for tears and detachments including high myopia, excess lattice degeneration, vitreous liquefaction, choroidal and scleral thinning, and vitreous traction from ectopia lentis. Each of these changes is thought to be related to fibrillin alterations. Retinal detachment occurs in 5-26.5% of patients with Marfan syndrome and is bilateral in 30-42% of these cases. Rigorous screening and close follow-up of symptoms is important to prevent retinal detachment in these cases.

Other ocular manifestations of Marfan syndrome include flattened cornea (causing astigmatism), keratoconus, increased globe length (causing myopia), iris coloboma, cataracts, glaucoma, strabismus, amblyopia, and vascular malformations. Central to each of these findings is the ubiquitous abnormality of fibrillin in the ocular connective tissue of the Marfan patient.

With regard to ectopia lentis, a number of treatment options exist. Mild subluxation allows for near normal vision with the patient seeing through the phakic portion of the pupil. The other extreme would be severe subluxation in a child which requires urgent surgical correction to avoid irreversible amblyopia. The principle surgical method employed in Marfan syndrome is lens extraction with either IOL placement or contact lens correction. Surgery is indicated when the lens position causes irregular astigmatism and glare, when the lens is posteriorly dislocated into the vitreous, when the lens is dislocated anteriorly and causes secondary glaucoma, or in the setting of cataract formation. Because of the altered anatomy and weakening of the connective tissues in Marfan syndrome, all of the usual complications of lens extraction are amplified. As the capsule is unstable from loss of zonules, the intraocular lens (IOL) must either be placed in the anterior chamber, or be secured to the iris or sclera with permanent Prolene sutures.

One important complication of IOL fixation to the sclera in young patients is that the 10-0 Prolene sutures may break three to ten years following surgery. This has led many surgeons to use larger suture such as 8-0 Gortex or 9-0 Prolene in the hopes that the suture will last longer. In cases of complete posterior lens dislocation, a pars plana vitreolensectomy can be performed. Another surgical option is to secure the capsule to the sclera using sutured Cionni modified capsular tension rings (CTR from Morcher) or Ahmed capsular tension segments (CTS from Morcher). These surgical interventions, while complicated, have great success in restoring vision in these patients.

Diagnosis: Marfan syndrome with lens dislocation

Differential diagnosis for crystalline lens dislocation

- ◆ Trauma
- ◆ Homocystinuria
- ◆ Sulfite oxidase deficiency
- ◆ Weill-Marchesani Syndrome
- ◆ Hyperlysinemia

Summary

<p>EPIDEMIOLOGY</p> <ul style="list-style-type: none"> ◆ Incidence: 1/5000 - 1/2000. 60-87% with ectopia lentis. ◆ Gender: Males and females equally represented. ◆ Genetics: Autosomal dominant. 80% from FBN1 mutations on chromosome 15. ◆ Other mutations include TGFBR1 and TGFBR2. 	<p>SIGNS (Ocular)</p> <ul style="list-style-type: none"> ◆ Ectopia lentis (most commonly superotemporal dislocation) ◆ Retinal detachment ◆ Myopia ◆ Hypoplastic iris with miosis ◆ Amblyopia ◆ Strabismus ◆ Keratoconus ◆ Enophthalmos
<p>SYMPTOMS</p> <ul style="list-style-type: none"> ◆ Multiple systems including cardiovascular, musculoskeletal, and ocular complaints. ◆ Ocular: blurred vision, monocular diplopia, pain, flashes and floaters. 	<p>TREATMENT of ocular complications</p> <ul style="list-style-type: none"> ◆ Lens extraction for ectopia lentis with Contact lens or IOL (anterior chamber, sutured to sclera/iris) ◆ Retinal laser for detachments or tears ◆ Regular screen for myopia, amblyopia, strabismus, keratoconus, and glaucoma.

References

1. Abboud E. Retinal detachment surgery in Marfan's syndrome. *Retina* 1998;18:405–409.
2. De Paepe A, Devereux RB, Dietz HC, Hennekam RC, Pyeritz RE. Revised diagnostic criteria for the Marfan Syndrome. *Am J Med Genet* 1996;62(4):417 .
3. Fuchs J. Marfan syndrome and other systemic disorders with congenital ectopia lentis. A Danish national survey. *Acta Paediatr* 1997;86:947-52.
4. Kohnen T, Baumeister M and Bühren J. Scheimpflug imaging of bilateral foldable in-the-bag intraocular lens implantation assisted by a scleral-sutured capsular tension ring in Marfan's syndrome. *J Cataract Refract Surg* 2003;29:598–602.
5. Maumenee I. The eye in the Marfan syndrome. *Trans Am Ophthalmol Soc* 1981;79:684–733.
6. Meire F, Delleman W and Bleeker-Wagemakers E. Ocular manifestations of congenital Marfan syndrome with contractures (CMC syndrome). *Ophthalmic Paediatr Genet*1991;12: 1–9.
7. Nemet AY, Assia EI, Apple DJ, Barequet, IS. Current Concepts of Ocular Manifestations in Marfan Syndrome. *Sur Ophth* 2006;51(6): 561-575.
8. Pessier A and Potter K. Ocular pathology in bovine Marfan's syndrome with demonstration of altered fibrillin immunoreactivity in explanted ciliary body cells. *Lab Invest* 1996;75:87–95.
9. Pyeritz RE. The Marfan syndrome. *Annu Rev Med* 2000;51:481–510.
10. Remulla JF, Tolentino FI. Retinal detachment in Marfan's syndrome. *Int Ophthalmol Clin* 2001; 41: 235-40.
11. Robinson PN, Booms P, Katzke S, Ladewig M, Neumann L, Palz M, Pregla R, Tiecke F, Rosenberg T. Mutations of FBN1 and genotype-phenotype correlations in Marfan syndrome and related fibrillinopathies. *Hum Mutat* 2002;20(3):153-61.
12. Siganos D, Siganos C and Popescu C *et al*. Clear lens extraction and intraocular lens implantation in Marfan's syndrome. *J Cataract Refract Surg* 2000;26(5):781-4.
13. Vadalà P, Capozzi P and Fortunato Met *al*. Intraocular lens implantation in Marfan's syndrome. *J Pediatr Ophthalmol Strabismus* 2000;37: 206–208.
14. Weyman AE and Scherrer-Crosbie M. Marfan syndrome and mitral valve prolapse. *J Clin Invest* 2004; 114: 1543–1546.
15. Wheatley H, Traboulsi E and Flowers B *et al*. Immunohistochemical localization of fibrillin in human ocular tissues. Relevance to the Marfan syndrome. *Arch Ophthalmol*1995;113:103–109.
16. Zhao L, Liang T, Xu J, Lin H, Li D, and Qi Y. Two novel FBN1 mutations associated with ectopia lentis and marfanoid habitus in two Chinese families. *Mol Vis* 2009;15: 826–832.

Suggested citation format

Welder J, Nysten EL, Oetting TA. Marfan Syndrome. EyeRounds.org. May 6, 2010; Available from: <http://www.EyeRounds.org/cases/110-Marfan.htm>

last updated: 05-06-2010

Posterior Polar Cataract

Emily S. Birkholz, MD; Thomas A. Oetting, MD; Anna S. Kitzmann, MD

January 22, 2011

Chief Complaint: 38-year-old male with blurry distance vision

History of Present Illness: The patient noticed blurry distance vision and problems seeing at night for years, more noticeably in his left eye than in his right. When driving at night, he noticed a significant amount of glare from oncoming headlights. On a previous examination 15 years ago, he was informed he had cataracts.

Past Ocular History: The patient wore glasses and had no other ocular history, including no history of amblyopia.

Medical History: No chronic medical conditions, including no diabetes or history of steroid use.

Medications: None

Allergies: No known drug allergies

Family History: Father and brother had posterior polar cataracts.

Social History: The patient smoked but did not drink alcohol.

Review of Systems: A full review of systems was negative.

OCULAR EXAMINATION

Visual acuity in the distance without correction

- ◆ Right eye (OD): 20/60
- ◆ Left eye (OS): 20/40

Best Corrected Visual Acuity (BCVA)

- ◆ OD: 20/20-2
- ◆ OS: 20/30-2

Glare testing

- ◆ OD: 20/20-2
- ◆ OS: 20/40-2

Ocular motility: Full, both eyes (OU), no nystagmus

Intraocular pressure (IOP): 14 mmHg OD, 17 mmHg OS

Pupils: Reactive to light in each eye from 4mm in the dark to 2 mm in the light. No relative afferent pupillary defect (RAPD).

Confrontation visual fields: Full, OD and OS.

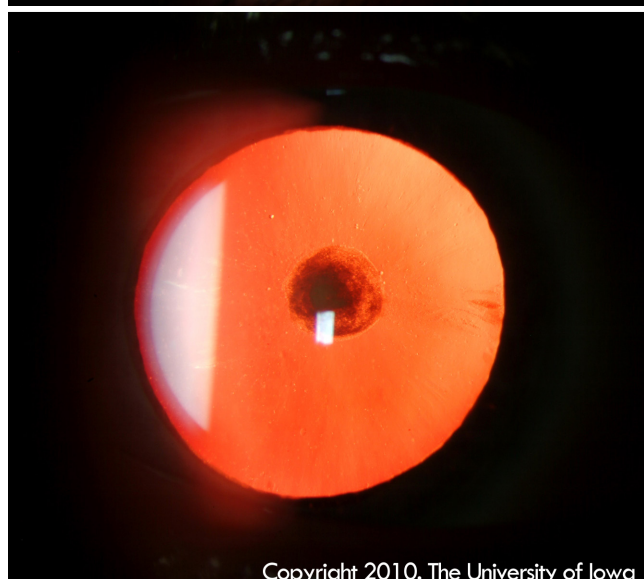
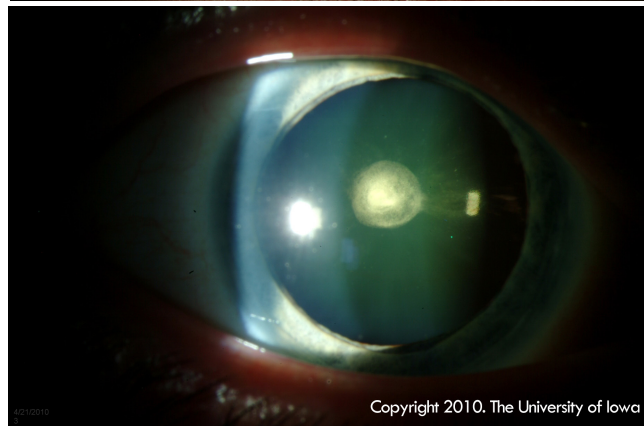
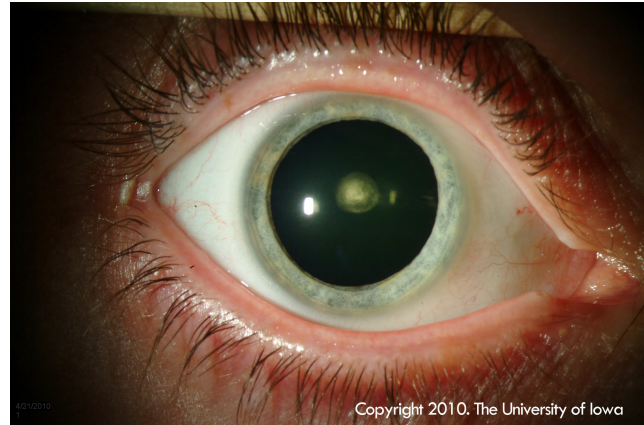
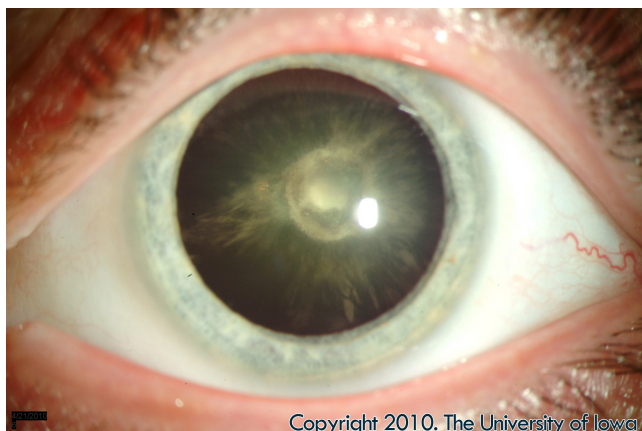
Figure 1. A: Posterior polar cataract of the right eye. B: Slit lamp photo of the posterior polar cataract in the right eye. C: Red reflex showing posterior polar cataract of the right eye

Slit lamp exam (OU)

- ◆ Normal lids and lashes, quiet conjunctiva, clear corneas. The anterior chambers were deep and quiet. The irides were normal and dilated well.
- ◆ There was a central 2.5 mm opacity in the posterior aspect of the lens OD (See Figure 1). The lens OS had a central 3.0 mm opacity in the posterior aspect of the lens with surrounding posterior subcapsular cataract and trace anterior subcapsular cataract (See Figure 2). Neither lens had any nuclear sclerosis.



Copyright 2010. The University of Iowa

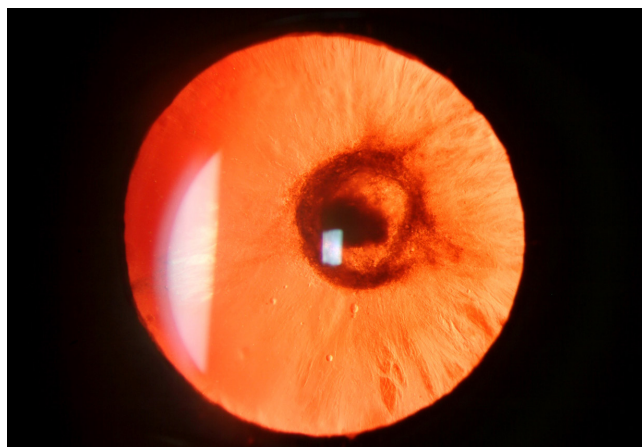
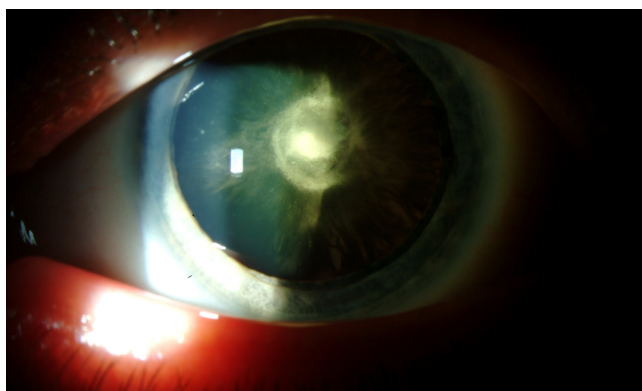


Figure 2. A: Posterior polar cataract of the left eye. B: Slit lamp photo of the posterior polar cataract of the left eye. Note the posterior subcapsular change and anterior subcapsular/cortical spokes. 2C: Red reflex of the left eye demonstrating the posterior polar cataract

Dilated fundus examination (DFE) OU

- ◆ Clear media, normal healthy optic nerves, normal macula, vessels and periphery

CLINICAL COURSE

The patient's symptoms and anterior segment findings were consistent with posterior polar cataracts. His vision could be improved with refraction to 20/20-2 OD and 20/30-2 OS. Options for management were discussed with the patient including trying a new pair of glasses to improve distance vision or pursuing cataract surgery, which would likely improve distance vision as well as improve symptoms of decreased night vision and glare. Because the cataract was significantly affecting his activities of daily living, the patient opted to pursue cataract surgery for the left eye. The patient was informed that cataract surgery for posterior polar cataracts is associated with increased risk of capsular rupture and vitreous loss that can lead to worse visual outcomes.

Because of the increased complexity of the case, the surgical plan involved obtaining anesthesia with a retrobulbar block, avoiding hydrodissection, sculpting out a bowl in the anterior cortical and nuclear material prior to performing gentle viscodissection, avoiding rotation of the nucleus, and using the anterior vitrector to remove nuclear and cortical material with very low aspiration and slow cut rate settings. In this video you will note that after the cortical material was removed, the surgeon opted not to polish the remaining posterior subcapsular fibers to avoid rupturing the posterior capsule (See Video 1). This remaining material was treated with a Nd:YAG (neodymium yttrium aluminum garnet) laser capsulotomy post-operatively.

Video 1. Posterior-Polar-Cataract vimeo.com/18022572

Video 2. Another surgical video demonstrates a similar technique but uses irrigation and aspiration to remove the cortical material rather than anterior vitrectomy www.facebook.com/cataract.surgery/videos/454807036140/

Neither case resulted in posterior capsular rupture.

DISCUSSION

Pathophysiology

Posterior polar cataract is a congenital condition that can be sporadic or familial. Sporadic posterior polar cataracts are typically unilateral and associated with remnants of the tunica vasculosa lentis, an embryologic hyaloid structure that fails to regress. Familial posterior polar cataracts are typically bilateral and follow an autosomal dominant pattern of inheritance (Basic and Clinical Science Course, Section 11). More recently, mutations resulting in a 17-base-pair duplication in the PITX 3 gene have been associated with posterior polar cataract. This gene codes for a transcription factor that participates in anterior segment and

lens development (Berry *et al.* 2004, Addison *et al.* 2004). The exact mechanism of how the mutation causes cataract is unknown, but the result is dysplastic, abnormal lens fibers that, as they migrate posteriorly from the equator, form an opacity in the region of the central posterior capsule. The opacity is usually a round discoid plaque, clearly demarcated from the rest of the lens and often associated with vacuoles in the lens surrounding the plaque (Eshaghian and Streeten 1980). Satellite opacities, which may represent fluid entering the lens, can also develop with time around the original plaque. The abnormal lens fibers can become adherent to the central posterior capsule, and the capsule around the plaque is often weakened. Thus, posterior capsular rupture is a feared complication when removing this type of cataract (Osher *et al.* 1990). These cataracts often present in the first few months of life, and if visually significant at an early age, can lead to amblyopia. Most posterior polar cataracts are stationary but can progress in severity over time.

Treatment

When posterior polar cataracts become visually significant (either in infancy if the cataracts are large enough to be amblyogenic, or in adulthood when they cause glare), they can be surgically removed. However, the high risk of posterior capsular rupture makes surgical removal often very difficult. There have been reported rates of posterior capsular rupture in 26-36% of cases depending on the series studied (Osher *et al.* 1990, Vasavada and Singh 1999). More recent studies demonstrate lower rates of posterior capsular rupture (Hayashi 2003). To avoid posterior capsular rupture the following techniques have been described in the literature.

- ◆ **Injection of Viscoelastic:** Avoid injecting excessive viscoelastic into the anterior chamber as the increased anterior pressure can cause posterior capsular rupture (Fine 2003).
- ◆ **Capsulorhexis:** Avoid a large anterior capsulotomy. In the setting of a posterior capsular rupture, a large opening may not provide enough support for a sulcus intraocular lens (Vasavada and Singh 1999).
- ◆ **Hydrodissection:** Avoid hydrodissection as the fluid wave can cause rupture of the weak posterior capsule (Vasavada and Singh 1999, Hayashi 2003). Viscodissection can be safely utilized if the nucleus has been debulked as was demonstrated in the above video.
- ◆ **Hydrodelineation:** “Inside-out delineation” is a technique described by Vasavada and Raj. A central bowl or trench is made in the anterior epinuclear material using low phacoemulsification settings [slow motion phacoemulsification utilizes low aspiration flow rate, vacuum, and infusion pressure (Osher 1993)]. The low vacuum level and aspiration flow rate provide a more stable anterior chamber and reduce the risk of surge, which can cause chamber collapse, anterior posterior movement of the iris lens diaphragm, and strain on the zonules and capsule. Low bottle height prevents the posterior capsule from ballooning (Vasavada and Singh 1999). After this initial sculpting, the nuclear material

is hydrodelineated from the epinuclear material by carefully placing the tip of the syringe in the central lens material and slowly injecting fluid in this plane until a golden ring is seen. This “inside-out” hydrodelineation technique can avoid the inadvertent injection of fluid in the subcapsular plane, which can lead to posterior capsular rupture (Vasavada and Raj 2004). Lim and Goh describe another technique called “modified epinucleus pre-chop” for posterior polar cataracts with a dense nucleus. This technique involves pre-chopping the anterior epinucleus using “in situ” chop where the chopper is placed in the mid-periphery of the anterior epinuclear material and repositioned in different meridians with each chop. Once this anterior epinuclear material is removed, hydrodelineation and mobilization of the remaining dense nuclear core can be performed more easily (Lim and Goh 2008).

- ◆ **Lens Rotation:** This step should be avoided (Vasavada and Singh 1999).
- ◆ **Nucleofractis:** Aspirate the nuclear material if the nucleus is soft, or use slow motion phacoemulsification (example: bottle height 50 cm, vacuum 100 mm Hg, and aspiration flow rate at 20 ml per minute) to gently remove nuclear fragments within the epinuclear shell, which was created by hydrodelineation. Vasavada describes a stop, chop, chop and stuff technique where the vertical chopper is placed more centrally than in traditional chop and small continuous chopping produces small fragments which are then “stuffed” into the phaco tip by the chopper (Vasavada and Desai 1996). The V groove (also known as the “victory”) technique described by Kelman in 1994 and “lambda” technique described by Lee and Lee in 2003 involve sculpting the nucleus in the shape of a V or the Greek letter lambda (λ). This is followed by cracking along both “arms” and then removing the central piece first. See Video 3. This offers an advantage of not stretching the capsule while removing the pieces (Kelman 1994, Lee and Lee 2003).

Video 3. www.facebook.com/cataract.surgery/videos/472413536140/

- ◆ **Epinucleus removal:** Vasavada and Singh utilize the phacoemulsification probe and low settings to gently strip the epinucleus 360 degrees. The central epinuclear material and plaque are aspirated last (Vasavada and Singh 1999). Fine describes using viscodissection for mobilizing the epinuclear and cortical material (Fine *et al.* 2003). The vitrectomy cutter can also be used to remove the remaining epinucleus. This may provide better control of the anterior chamber, avoids surge, and allows the surgeon to be prepared if the anterior hyaloid face is violated in the setting of posterior capsular rupture.
- ◆ **Polish:** Avoid polishing techniques as the posterior polar plaque is very adherent to the capsule, and polishing may lead to rupture of the capsule (Vasavada and Singh, 1999).
- ◆ **Lens insertion:** Vasavada and Raj recommend using an AcrySof IOL in the bag if possible, even if there is a small

posterior capsular rupture. In the setting of posterior capsular rupture, the anterior vitreous face can be tamponaded with a dispersive viscoelastic, and then the lens can be gently inserted into the bag. The AcrySof lens unfolds gently, which will reduce the chance of extending a capsular tear. Their technique for manipulating the lens into the bag involves using a Lester manipulator to place the trailing haptic, rather than dialing the lens into place. Irrigation and aspiration to remove the viscoelastic should not be performed posterior to the IOL (Vasavada and Raj 2008).

In summary, there are various surgical techniques that can be utilized to minimize the risk of posterior capsular tear in posterior polar cataract extraction. Avoid hydrodissection, perform hydrodelineation, use slow motion phacoemulsification settings, consider viscodissection of the epinuclear material, and do not polish the remaining posterior polar remnant. Laser posterior capsulotomy can safely be performed post-operatively.

DIAGNOSIS

Posterior Polar Cataracts

Differential Diagnosis

- ◆ Posterior subcapsular cataract
- ◆ Traumatic cataract
- ◆ Mittendorf dot

<p>EPIDEMIOLOGY</p> <ul style="list-style-type: none"> ◆ Congenital ◆ Sporadic or autosomal dominant inheritance ◆ Unilateral or bilateral ◆ 17 bp duplication in PITX3 gene 	<p>SIGNS</p> <ul style="list-style-type: none"> ◆ Abnormal red reflex ◆ Amblyopia ◆ Central posterior discoid plaque on the lens
<p>SYMPTOMS</p> <ul style="list-style-type: none"> ◆ Asymptomatic ◆ Decreased vision ◆ Glare 	<p>TREATMENT</p> <ul style="list-style-type: none"> ◆ Surgical removal with care due to high risk of posterior capsular rupture ◆ Avoid hydrodissection ◆ Perform hydrodelineation ◆ Slow motion phacoemulsification (low irrigation, aspiration, bottle height, and phacoemulsification settings) ◆ Viscodissect cortical material ◆ Consider anterior vitrectomy to remove cortical material ◆ Discuss with patient the increased risk of capsular rupture

References

Addison PK, Berry V, Ionides AC, et al. Posterior polar cataract is the predominant consequence of a recurrent mutation in the PITX3 gene. *Br J Ophthalmol* 2005;89(2):138-141

Berry V, Yang Z, Addison PK, et al. Recurrent 17 bp duplication in PITX3 is primarily associated with posterior polar cataract. *J Med Genet* 41(8):e109

Chapter 4. Embryology: Rosenfeld, SI et al. *Section 11. Lens and Cataract. 2007-2008 Basic and Clinical Science Course*. San Francisco: American Academy of Ophthalmology; 2007; p. 34-35.

Eshaghian J, Streeten BW. Human posterior subcapsular cataract; an ultrastructural study of the posteriorly migrating cells. *Arch Ophthalmol* 1980 98:134-143

Fine IH, Packer M, Hoffman RS. Management of posterior polar cataract. *J Cataract Refract Surg* 2003;29:16-19

Hayashi K, Hayashi H, Nakao F, Hayashi F. Outcomes of surgery for posterior polar cataract. *J Cataract Refract Surg* 2003; 29:45-49

Kelman CD. V Groove phaco technique: Fast, easy, safe: Interview with Dr. Kelman. *Ophthalmology Times* 1994;19(18):12

Lee MW, Lee YC. Phacoemulsification of posterior polar cataracts—a surgical challenge. *Br J Ophthalmol* 2003;87(11):1426-1427

Lim Z, Goh J. Modified epinucleus pre-chop for the dense posterior polar cataract. *Ophthalmic Surg Lasers Imaging* 2008;39(2):171-173

Osher RH, Yu BC, Koch DD. Posterior polar cataracts: a predisposition to intraoperative posterior capsular rupture. *J Cataract Refract Surg* 1990;16:157-162

Osher RH. Slow motion phacoemulsification approach (letter). *J Cataract Refract Surg* 1993;19:667

Vasavada A, Singh R. Phacoemulsification in eyes with posterior polar cataract. *J Cataract Refract Surg* 1999;25:238-245

Vasavada AR, Desai JP. Stop, chop, chop and stuff. *J Cataract Refract Surg* 1996;22:526-529

Vasavada AR, Raj SM. Inside-Out delineation. *J Cataract Refract Surg* 2004;30:1167-1169

Vasavada AR, Raj, SM. Posterior polar cataract and pre-existing posterior capsular defect. *Cataract & Refractive Surgery Today Europe* 2008 March:73-77

Citing this article

Birkholz ES, Oetting TA, Kitzmann AS. Posterior Polar Cataract. EyeRounds.org. January 22, 2011. Available from EyeRounds.org/cases/128-Posterior-Polar-Cataract.htm

last updated: 01-22-2011

True Exfoliation Syndrome

Aaron M. Ricca, MD, A. Tim Johnson, MD

posted November 28, 2017

INITIAL PRESENTATION

Chief Complaint

Blurry vision

History of Present Illness

An 84-year-old male presented with gradually worsening blurry vision in both eyes (OU), left worse than right, over a period of several years. He described the vision as hazy and poor in dim lighting. He also reported difficulty with reading, driving, or watching TV. He noted worsening glare and halos with lights, making nighttime driving unsafe.

Past Ocular History

- ◆ Ocular hypertension both eyes (OU)
- ◆ Removal of numerous metallic corneal foreign bodies OU
- ◆ Intermediate non-exudative macular degeneration OU

Past Medical History

- ◆ Coronary artery disease status-post left combined coronary artery endarterectomy and bypass
- ◆ Myocardial infarction status-post stenting
- ◆ Hypertension
- ◆ Hyperlipidemia

Medications

- ◆ Latanoprost every evening OU
- ◆ AREDS2 vitamins
- ◆ Atenolol
- ◆ Simvastatin
- ◆ Spironolactone

Allergies

- ◆ No known drug allergies

Family History

- ◆ Non-contributory

Social History

- ◆ Currently retired, but worked as a metal welder for most of his life

Review of Systems

- ◆ Negative except for what is detailed in the history of present illness

OCULAR EXAMINATION

Distance Visual Acuity (with correction)

- ◆ Right eye (OD): 20/25-2
- ◆ Left eye (OS): 20/30-2

Glare Visual Acuity

- ◆ OD: 20/40
- ◆ OS: 20/300

Ocular Motility/Alignment

- ◆ Full, orthophoric OU

Intraocular Pressure (IOP) by Tonopen®

- ◆ OD: 12 mmHg
- ◆ OS: 15 mmHg

Confrontation Visual Fields

- ◆ OD: small inferonasal field defect by finger counting
- ◆ OS: full to finger counting

Slit Lamp Exam

- ◆ Lids/lashes: Normal OU
- ◆ Conjunctiva/sclera: Clear and quiet OU
- ◆ Cornea: Clear OU
- ◆ Anterior chamber: Deep and quiet OU
- ◆ Iris: Round and flat OU
- ◆ Lens
 - OD: 2+ Nuclear sclerosis, 1 + central posterior sub-capsular cataract, elevated scrolled flap of the lens capsule from 4:30 clockwise to 11 (Figures 1 - 3)
 - OS: 3+ Nuclear sclerosis, 1 + central posterior sub-capsular cataract, elevated scrolled flap of the lens capsule from 8:30 clockwise to 4 (Figure 4)

Dilated Fundus Examination

- ◆ Vitreous: Quiet OU
- ◆ Disc: Normal OU
- ◆ Cup-to-disc ratio: 0.2 OU
- ◆ Macula
 - OD: Large soft drusen, no heme
 - OS: Subfoveal low-lying fibrovascular PED, large soft drusen, RPE mottling, no heme or subretinal fluid
- ◆ Vessels: Normal OU
- ◆ Periphery: Normal OU

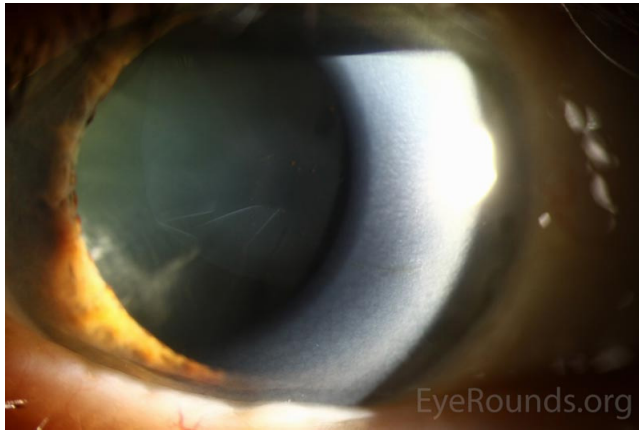


Figure 1: Slit lamp photograph OD demonstrating delamination of the anterior lens capsule with wrinkling of the free-floating flap in the anterior chamber.

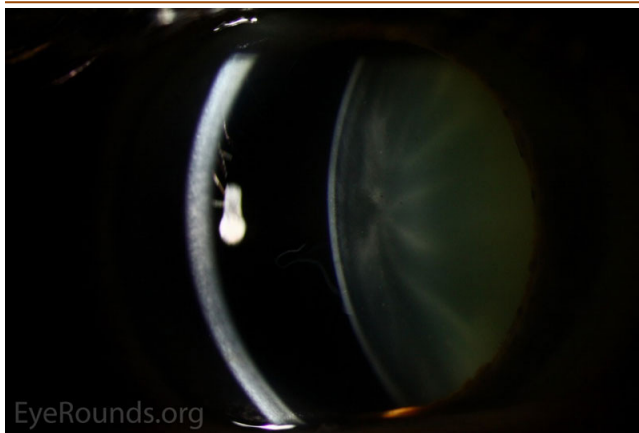

Figure 2: Slit lamp photograph OD with slit beam passing through and outlining the free-floating flap of lens capsule schisis.

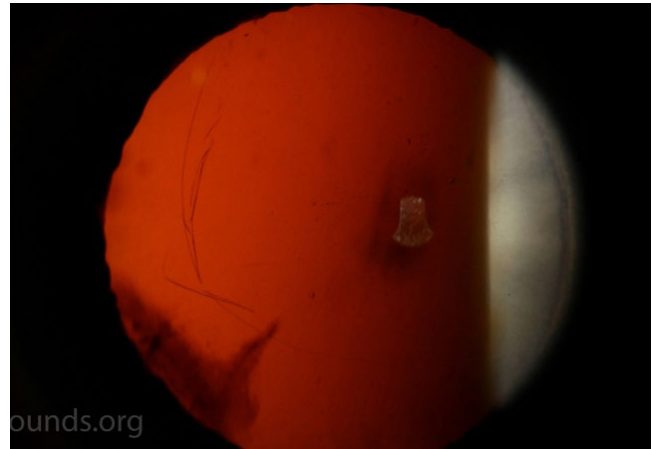


Figure 3: Slit lamp photograph OD with retro-illumination clearly outlining the circular region of schisis with wrinkling of the delaminated free-floating flap.

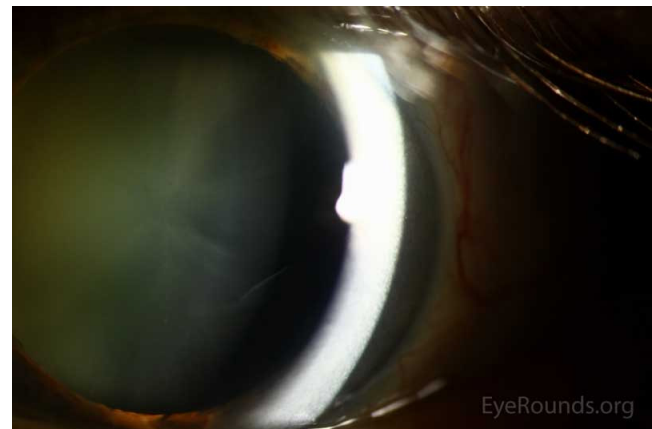


Figure 4: Slit lamp photograph OS demonstrating bilateral disease with the floating rolled edge of the delaminated flap of anterior lens capsule.

Differential Diagnosis

- ◆ Spontaneous rupture of anterior lens capsule
- ◆ True exfoliation syndrome
- ◆ Pseudoexfoliation syndrome eyerounds.org/atlas/pages/pseudoexfoliation-syndrome/

CLINICAL COURSE

The patient underwent cataract extraction by phacoemulsification first OS then OD.

Given the delamination present in the anterior lens capsules that was noted on exam, great care was taken during this procedure, most specifically in performing the continuous curvilinear capsulorrhexis. Trypan blue dye was used to stain the anterior capsule, providing improved visualization. No complications occurred. The patient tolerated the procedures well, and his post-operative visual outcome was excellent.

A video of the surgery is presented at vimeo.com/244672221. **The continuous curvilinear capsulorrhexis is performed in each eye in this patient.**

The pieces of the lens capsule that were removed from each eye during the capsulorrhexis were submitted for histological analysis, and images of these samples are presented below. (Figures 5 and 6)

DIAGNOSIS

True exfoliation syndrome

DISCUSSION

Etiology/Epidemiology

True exfoliation syndrome is a rare disease that was first reported in 1922 by Elschnig; it was initially described in a series of two patients, both of whom were glassblowers [1]. The classic scenario is an asymptomatic glassblower by trade, diagnosed on routine exam. It has been reported in people with other occupational exposures such as steelworkers, blacksmiths, and bakers [2]. The common denominator linking all these professions is excessive exposure to

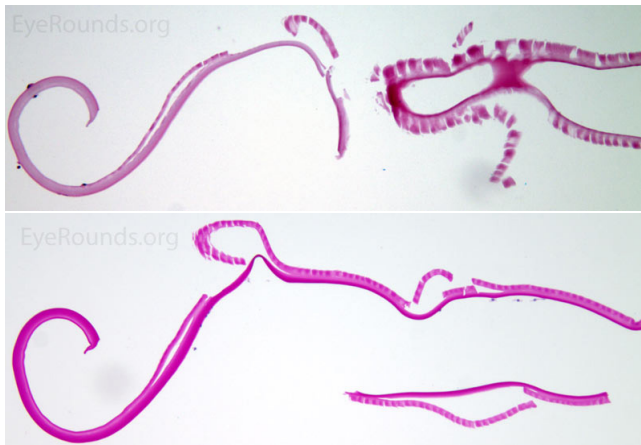


Figure 5: Two images of the anterior lens capsule OS (H&E stain on the top and PAS stain on the bottom image). Both stains clearly demonstrate delamination of the anterior lens capsule with the flap attachment point and breakdown of the anterior delaminated portion.

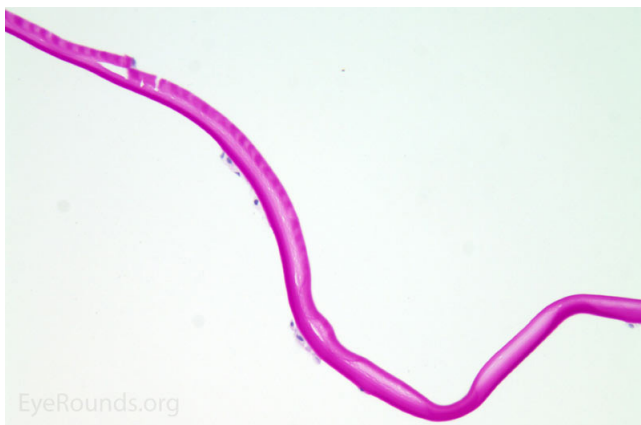

Figure 6: PAS staining of the anterior lens capsule from the left eye showing early delamination of the anterior capsule with schisis cavities forming and beginning to coalesce.

high heat and infrared radiation. However, there have also been reports of exfoliation associated with inflammation, such as uveitis, and trauma [3], as well as cases of idiopathic exfoliation syndrome seen in elderly patients with no identifiable risk exposures [4,5].

Given the rarity of the disease, it is difficult to estimate the incidence or prevalence of this condition. One of the largest case series to date by Teekhasaenee *et al.* demonstrated that 248 out of 259 total cases were idiopathic with no identifiable exposure. In this series, 118 patients were men and 141 patients were women with a combined average age of 75. The overwhelming majority of patients had bilateral disease, and the only statistically significant risk factors identified were age, heat exposure, and trauma [5]. Another smaller case series of 12 patients only identified one with a prior history of infrared exposure or trauma [6]. The mean age at diagnosis in this series was 77.9 and most were bilaterally affected as well, further supporting the idea that this disease is likely age-related in the mod-

ern day population. Some suggest a correlation with the development of glaucoma [4], but most recent data has not borne this out to be true. Some literature reports laser energy as a risk factor, such as that received during a laser peripheral iridotomy, but other reports suggest this is not true [5].

Pathophysiology

The classic theory is that repeated exposure to high levels of infrared radiation causes epithelial damage to the lens capsule with vesicular degeneration. The degeneration leads to capsular dehiscence and schisis, then delamination of the anterior portion of the capsule [3]. It is well known that lens epithelial cells near the equator have the most mitotic activity. These actively dividing cells are also most susceptible to damage from radiation, which may impair the function of future cell generations [2]. It has been shown that areas of zonular disruption are often the location of initial delamination with concomitant progression and zonular damage [5]. Another theory is that the thermal injury directly activates enzymes that are responsible for proteolysis of the collagen in the capsule [7].

Signs/Symptoms

There are often no symptoms reported by the patient when exfoliation occurs, and the diagnosis is commonly made as an incidental finding during physical exam [6]. This is a relatively benign process with the delamination occurring only anteriorly. The integrity of the lens capsule remains intact with no intra-ocular exposure to lens material. True exfoliation can present as a very small linear rent, a very large free-floating flap, or anywhere in between, based on the extent of delamination present [5]. One of the classic signs is known as the double-ring sign (DRS). The DRS is seen when partial splitting of the anterior capsule occurs, giving the appearance of two rings on the capsule [8]. The DRS is diagnostic for true exfoliation syndrome. Another name for this sign is capsulorrhexis masquerade, as it can mimic a partial capsulorrhexis with a free-floating flap of delaminated capsule when DRS has progressed far enough [5]. It is also possible to develop a double delamination where the delaminated flap can split again resulting in parallel flaps [5]. Pigment deposition on the delaminated membrane is a common finding, seen in 68.7% of patients in the case series by Teekhasaenee and colleagues [5].

Testing/Laboratory work-up

The diagnosis is clinical. There are currently no blood tests available to aid in identifying this disease. There is also no known underlying genetic association at this time. Tissue evaluation of the anterior lens capsule after surgical removal during cataract extraction is a common method for definitive diagnosis. When evaluated *via* histology, the section through a lens capsule with true exfoliation syndrome shows a thinned residual capsule, due to loss of tissue from delamination, with an abnormal underlying epithelial layer [2]. Epithelial cells become smaller and spaced out, but the overall thickness of the capsule, when

including the delaminated portion, is increased [2,9]. It is possible to see vesicles within the capsule, and the area of splitting often coincides with the highest areas of vesicle concentration [2]. If the capsule sample is well preserved and a portion of the delaminated tissue still attached, the specific area of dehiscence can be seen [2].

Imaging

Numerous recent diagnostic instruments have been used in identifying and investigating exfoliation syndrome with several recent publications documenting the potential benefits. For example, the Pentacam® will provide a cross-sectional image of the anterior chamber and can be used to visualize a floating membrane attached to the anterior capsule [10]. Anterior segment optical coherence tomography (OCT) has also been used to identify true exfoliation, and numerous sources have reported clear display of the split in the capsule with membrane floating in the anterior chamber [2,11]. Newer spectral domain OCT can provide such fine resolution, it may be able to detect subclinical delamination of the anterior capsule prior to developing free-floating flaps [11].

Treatment/Management/Guidelines

True exfoliation of the capsule typically presents no acute issues. As such, it is appropriate to monitor these patients on a routine basis.

Some have proposed grading systems based on the extent of delamination and location of the flap, with the most detailed criteria put forth by Teekhasaene and colleagues [5]. Clinically, however, there is limited benefit of a breakdown into stages given the lack of impact on management and prognosis. The benefit of staging is that it recognizes the disease is not a static process, and it can be useful in quantifying the extent of exfoliation when presenting early on, as well as documenting the progression.

The major significance of exfoliation is in surgical management and complications during cataract surgery. True exfoliation can make capsulorrhexis difficult and can predispose to radial tears [2,5,10,12]. A radial tear can occur in either the deep or superficial portion of the split capsule [12]. Trypan blue can be used to aid in visualization of the capsule. If possible, the final size of the capsulorrhexis should be larger than the delaminated portion in order to remove all split and weakened tissue [11].

True exfoliation has also been reported to have a relatively high prevalence of phacodonesis and lens dislocation, seen in approximately 10% of patients [5]. This can depend somewhat on the initial location of the split, with more peripheral tears predisposing to zonular weakness.

It is also possible to have true exfoliation concurrent with pseudoexfoliation [13].

<p>EPIDEMIOLOGY OR ETIOLOGY</p> <ul style="list-style-type: none"> ◆ Very rare condition ◆ Average age of presentation: mid-70's [5,6] ◆ Proven risk factors: age, heat exposure, trauma [5] ◆ History of glassblowing, steel working, blacksmithing, or any other activities predisposing to recurrent high infrared radiation exposure [2] 	<p>SIGNS</p> <ul style="list-style-type: none"> ◆ Small, partial thickness, linear rent in the anterior capsule [5] ◆ Double ring sign (DRS), AKA capsulorrhexis masquerade [8] ◆ Partial, free-floating flap scrolled in the anterior chamber ◆ Use of anterior segment imaging can aid in diagnosis, i.e. OCT or Pentacam [10,11]
<p>SYMPTOMS</p> <ul style="list-style-type: none"> ◆ Asymptomatic unless the patient develops concurrent lens dislocation 	<p>TREATMENT/MANAGEMENT</p> <ul style="list-style-type: none"> ◆ Observation unless the patient develops concurrent lens dislocation, which can occur in up to 10% of patients [5] ◆ Great care when performing intraocular surgery ◆ Use Trypan blue when performing the capsulorrhexis and make final size of rhexis larger than delaminated portion [11]

References

1. Elschmig A. A Detachment of the zonular lamellae in glassblowers. *Klin Monatsbl Augenheilkd* 1922;69:732-734.
2. Cooke CA, Lum DJ, Wheeldon CE, Teoh H, McGhee CN. Surgical approach, histopathology, and pathogenesis in cataract associated with true lens exfoliation. *J Cataract Refract Surg* 2007;33(4):735-738. [PubMed.gov/17397753](https://pubmed.ncbi.nlm.nih.gov/17397753)
3. Wong AL, Chan TC, Fong AH, Lam BN, Yuen HK. Clinical characteristics and surgical outcomes of phacoemulsification in true exfoliation syndrome. *J Cataract Refract Surg* 2014;40(1):82-86. [PubMed.gov/24238944](https://pubmed.ncbi.nlm.nih.gov/24238944)
4. Cashwell LF, Jr., Holleman IL, Weaver RG, van Rens GH. Idiopathic true exfoliation of the lens capsule. *Ophthalmology* 1989;96(3):348-351. [PubMed.gov/2710527](https://pubmed.ncbi.nlm.nih.gov/2710527)
5. Teekhasaene C, Suwan Y, Supakontanasan W, Tulvatana W, Ritch R. The Clinical Spectrum and a New Theory of Pathogenesis of True Exfoliation Syndrome. *Ophthalmology* 2016;123(11):2328-2337. [PubMed.gov/27596291](https://pubmed.ncbi.nlm.nih.gov/27596291)
6. Chen HS, Hsiao CH, Chuang LH, Su WW. Clinicohistopathology of cataract associated with true exfoliation of the lens capsule. *J Cataract Refract Surg* 2011;37(5):969-970. [PubMed.gov/21511162](https://pubmed.ncbi.nlm.nih.gov/21511162)
7. Callahan A, Klien BA. Thermal detachment of the anterior lamella of the anterior lens capsule; a clinical and histopathologic study. *AMA Arch Ophthalmol* 1958;59(1):73-80. [PubMed.gov/1348699](https://pubmed.ncbi.nlm.nih.gov/1348699)
8. Braude LS, Edward DP. Partial splitting of the anterior lens capsule giving a 'double-ring' sign. *Arch Ophthalmol* 1995;113(6):705-708. [PubMed.gov/7786204](https://pubmed.ncbi.nlm.nih.gov/7786204)
9. Kulkarni AR, Al-Ibrahim J, Haider S, Elsherbiny S, Scott R. Phacoemulsification in true exfoliation of the lens capsule: a case series. *Eye (Lond)* 2007;21(6):835-837. [PubMed.gov/16751758](https://pubmed.ncbi.nlm.nih.gov/16751758)
10. Chamney SM, Hughes ME, Sinton JE. The use of Pentacam in the assessment of true exfoliation of the lens capsule. *Eur J Ophthalmol* 2015;25(4):e50-52. [PubMed.gov/25684157](https://pubmed.ncbi.nlm.nih.gov/25684157)
11. Tan DK, Aung T, Perera SA. Novel method of assessing delamination of the anterior lens capsule using spectral-domain optical coherence tomography. *Clin Ophthalmol* 2012;6:945-948. [PubMed.gov/22791977](https://pubmed.ncbi.nlm.nih.gov/22791977)
12. Kim KH, Chung ES, Chung TY. Radial extension of capsulorhexis in true exfoliation patient: a potentially hazardous complication. *J Cataract Refract Surg* 2009;35(3):590-592. [PubMed.gov/19251155](https://pubmed.ncbi.nlm.nih.gov/19251155)
13. Kuchle M, Iliff WJ, Green WR. Kombinierte "Feuerlamelle" und Pseudoexfoliation der vorderen LinsenkapSEL. [Combined true exfoliation and pseudoexfoliation of the anterior lens capsule]. *Klin Monatsbl Augenheilkd* 1996;208(2):127-129. [PubMed.gov/8648988](https://pubmed.ncbi.nlm.nih.gov/8648988)

Citing this article

Ricca AM, Johnson AT. True exfoliation syndrome. EyeRounds.org. posted November 29, 2017; Available from EyeRounds.org/cases/262-True-Exfoliation-Syndrome.htm

last updated: 11/29/2017

Case Presentations

Glaucoma

Aphakic Glaucoma

Nayasha Madhan, BS; Heather A. Stiff, MD; Ze Zhang, MD; Wallace L.M. Alward, MD

posted December 14, 2017

INITIAL PRESENTATION

Chief Complaint

Referral for evaluation of elevated intraocular pressure (IOP) and suspected aphakic glaucoma

History of Present Illness

A 5-year-old female was referred to the University of Iowa Hospitals and Clinics (UIHC) Glaucoma Clinic for evaluation of suspected aphakic glaucoma of the left eye (OS). The patient was born with a congenital cataract OS, which was removed at 7 months of age by an outside provider. She was diagnosed with amblyopia OS and underwent patching of the right eye (OD) for 3 hours per day for a short period of time. At 5 years of age, she was found to have an IOP of 32 mmHg OS and was started on timolol 0.25% twice daily OS. She was then referred for further evaluation.

Past Ocular History

- ◆ Congenital cataract OS status post extracapsular cataract extraction at 7 months of age
- ◆ Amblyopia OS
- ◆ Sensory exotropia OS

Past Medical History

No significant past medical history

Medications

Timolol 0.25%, 1 drop, twice a day, OS

Allergies

No known drug allergies

Family History

No family history of congenital cataracts, glaucoma, or other eye diseases

Social History

Non-contributory

Review of Systems

Negative except for what is listed in the history of present illness

OCULAR EXAMINATION

Visual Acuity with Correction (Snellen)

- ◆ OD: 20/30
- ◆ OS: 20/100

Extraocular Motility

- ◆ OD: Full
- ◆ OS: 45 prism diopters (PD) left exotropia (Figure 2)

Intraocular Pressure (IOP) by Tonopen®

- ◆ OD: 14 mmHg
- ◆ OS: 23 mmHg

Slit Lamp Examination

- ◆ External: Normal OD, significant buphthalmos OS
- ◆ Lids: Normal OD, upper and lower eyelid retraction OS
- ◆ Conjunctiva/sclera: Normal in both eyes (OU)
- ◆ Cornea: Clear OD, clear with contact lens in place OS
- ◆ Anterior chamber: Deep and quiet OU
- ◆ Iris: Normal OD, superotemporal peripheral iridectomy OS
- ◆ Lens: Normal OD, aphakic OS

Dilated Fundus Examination

- ◆ Disc: Normal OD, thinning of neuroretinal rim OS
- ◆ Cup-to-disc ratio: 0.35 OD, 0.7 OS
- ◆ Macula: Normal OU
- ◆ Vessels: Normal OU
- ◆ Periphery: Normal OU

Gonioscopy

Difficult view; appeared to be open for 360 degrees OU

Visual Field

- ◆ OD: full field
- ◆ OS: generalized constriction with only a small paracentral island of I2e remaining.
- ◆ See Figure 1, next page

CLINICAL COURSE

The patient was diagnosed with aphakic glaucoma OS. Because IOP was 23 mmHg, she was switched from timolol 0.25% to timolol-dorzolamide twice daily OS. At 2 months follow-up, IOP was 27 mmHg. Therefore, latano-

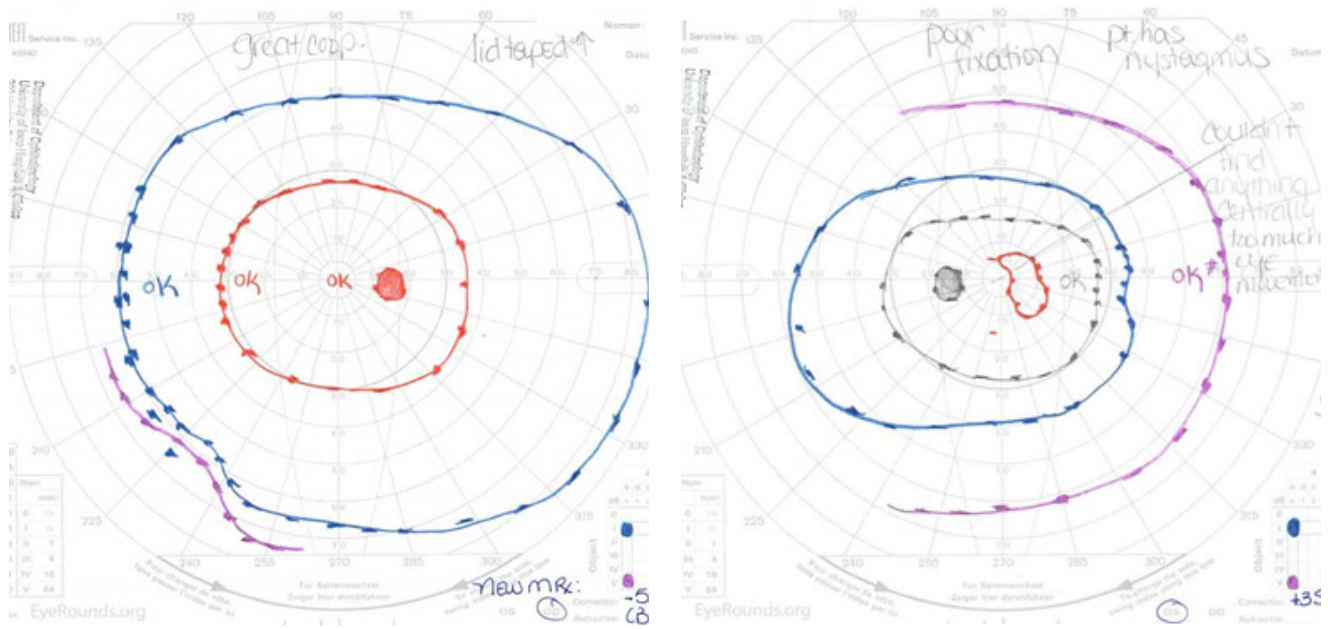


Figure 1. Goldmann visual field (A) OD showing a full field and (B) OS showing generalized constriction with only a small paracentral island of I2e remaining.

prost 0.005% at night was added. She continued to have persistently elevated IOP over the next 2 years, resulting in progressive optic nerve cupping and deterioration of her visual field with a superior arcuate scotoma encroaching on fixation. At this point, it was decided that she would need a surgical procedure. A trabeculectomy was considered, but because she wore contact lenses, the decision was made to precede with a pars plana vitrectomy with insertion of a Baerveldt drainage device. The surgery was performed without complication. IOP decreased to 14 mmHg on timolol-dorzolamide and latanoprost.

Two years after her surgery, she presented with 3 days of pain OS with an IOP of 50 mmHg. She was scheduled for emergent surgical evaluation of her Baerveldt implant. Intra-operative assessment showed drastic anterior migration of the tube, past the posterior capsule and into the iris tissue. During surgery, the tube was freed from the iris, and IOP decreased. The tube was then pulled through the existing peripheral iridectomy and placed on the anterior surface of the iris (Figure 2). The patient did well postoperatively, and her IOP remained in the mid-teens on timolol-dorzolamide and latanoprost.

The patient was followed closely and was later noted to have high myopia and buphthalmos OS (Figure 3). She was referred to the oculoplastic service for proptosis, eyelid retraction, and a large left exotropia (Figure 3). At age 22, she underwent an elective procedure for cosmesis of her proptosis, which involved a medial and lateral orbital wall decompression. At age 23, she underwent large left medial rectus resection for exotropia, taking care to avoid area of the Baerveldt implant superotemporally. Both surgeries were performed without complications (Figure 4).

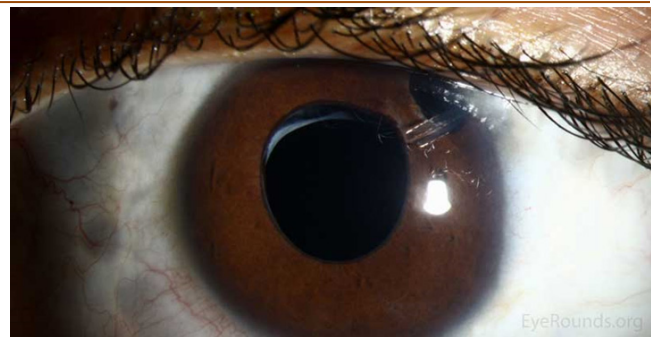


Figure 2. Slit lamp photograph demonstrating Baerveldt tube emerging anteriorly, through the iridectomy.

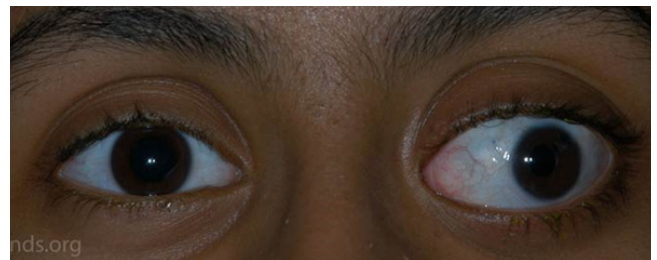

Figure 3. External photograph demonstrating significant buphthalmos, eyelid retraction, and exotropia OS.

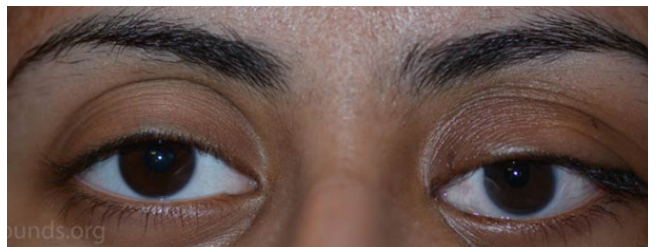

Figure 4. External photograph demonstrating improved eyelid retraction, alignment, and proptosis after orbital decompression and strabismus surgery.

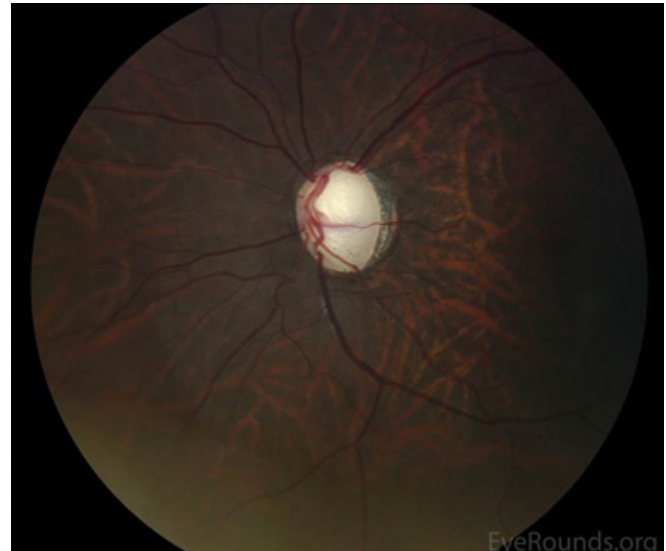
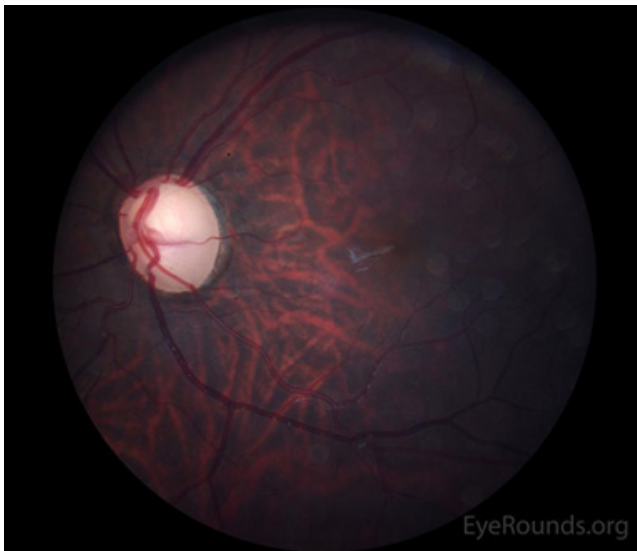

Figure 5. Color fundus photos of left eye (A) Cup-to-disc ratio of 0.9 at age 15 and (B) Cup-to-disc ratio of 0.9 at age 20.

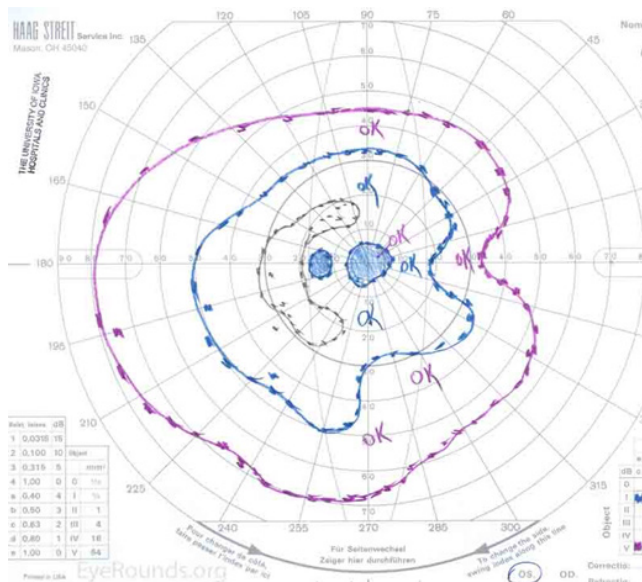


Figure 6. Goldmann visual field OS showing general constriction with superior and inferior arcuate scotomas, along with a central scotoma.

At her most recent appointment, 17 years after her initial presentation, her IOP was 17 mmHg OS on timolol only. Unfortunately, her vision had decreased from 20/100 to 20/1250 OS over her 17-year course. Remarkably, her optic nerves (Figure 5A and B) and OCT of the optic nerves were unchanged over the last 7 years. Her visual field did show some slow progression over time OS (Figure 6).

DIAGNOSIS

Aphakic glaucoma

DISCUSSION

Etiology/Epidemiology

Aphakic glaucoma is classified as a secondary form of open angle glaucoma and ranks second as the most common cause of glaucoma in the pediatric population [1]. The following factors have been implicated in its development: surgery within the first year of life, corneal diameter less than 10 mm, retained lens proteins, the presence of other ocular abnormalities, certain cataract types (e.g. complete, nuclear, or persistent hyperplastic vitreous), and a history of secondary surgeries [2]. The most consistent risk factor across the literature has been cataract surgery at a young age [3]. In one study of 137 patients with prior congenital cataract surgery, 12% of patients developed aphakic glaucoma within a mean of 9.6 years following surgery. A meta-analysis using individual patient data on 470 children who underwent cataract surgery in infancy revealed 17% developed glaucoma within a median 4.3 years. The risk was highest in patients who underwent surgery at less than 4 weeks of age or infants with microphthalmos [1]. In an article by Kirwan in 2006, the incidence of aphakic glaucoma following congenital cataract surgery ranged from 15% to 45% [4].

A genetic etiology has also been considered as an explanation for the condition. There are a number of genes that contribute to both the development of cataracts and glaucoma, such as the PAX6 gene [5].

Pathophysiology

As stated above, early cataract surgery has been described as the most commonly identified risk factor for aphakic glaucoma. Early lensectomy is thought to interfere with maturation of the trabecular meshwork. In particular, normal meshwork development requires structural interactions between the native lens, zonules, ciliary body, and trabecular meshwork [6]. Other studies have postulated that aphakic glaucoma may develop from chronic trabecu-

litis secondary to postoperative inflammation or blockade of the trabecular meshwork with retained lens material [7]. Additionally, lens proteins that remain after extraction may degenerate into byproducts that are toxic to the trabecular meshwork [6]. In a retrospective review in 2004, 15% of patients were found to have retained lens material postoperatively; the same study cited literature that reported 41.6% to 78% of patients had residual cortex or lens material [6]. Aphakic glaucoma is typically an open-angle glaucoma, adding weight to the proposition that an interaction occurs between trabecular meshwork cells and lens epithelial cells and/or the vitreous leading to the development of elevated intraocular pressure [8].

There has been some discussion that corticosteroids could contribute to aphakic glaucoma. However, this mechanism has received less support as post-operative steroids are typically used for 1 to 2 months following surgery whereas aphakic glaucoma often develops years later [6].

Signs/Symptoms

Typically, patients develop aphakic glaucoma between 4 to 6 years after cataract surgery and present with elevated IOP, corneal clouding, and excessive loss of hyperopia [8]. Patients often have thick corneas and small anterior segments [9]. Children may present with vague symptoms ranging from irritability to photophobia [8]. However, most commonly, aphakic glaucoma is asymptomatic. Therefore, careful monitoring and surveillance of patients at risk is crucial [4], as IOP elevation may go unrecognized and untreated until fundoscopic exam reveals optic nerve cupping [1].

Workup

IOP measurement in children is commonly performed under general anesthesia. However, general anesthetics can lower IOP, resulting in unreliable readings, and IOP alone is insufficient to make the diagnosis of aphakic glaucoma. A

full examination should be performed including cycloplegic refraction, measurement of corneal thickness, gonioscopy, slit lamp exam of the anterior segment, optic nerve head evaluation, visual fields and ocular coherence tomography of the optic nerve if the patient is able. Although aphakic glaucoma is typically an open angle glaucoma, acquired angle defects may be visible on gonioscopy. A retrospective study conducted in 1995 looked at pediatric glaucoma patients who had a history of lensectomy and developed glaucoma two or more years after surgery. Gonioscopy prior to the operation revealed no consistent angle defects, but post-operatively, 96% of patients with glaucoma had an angle defect characterized by blockage of the trabecular meshwork, often caused by pigment or crystalline deposits [6, 10]. Screening for aphakic glaucoma after congenital cataract surgery should occur every 3 months for the first year postoperatively and twice yearly for the next 10 years, after which, annual exams can be resumed [2].

Treatment Guidelines

Treatment of aphakic glaucoma is similar to the treatment of any other secondary open-angle glaucoma. Both medical and surgical treatments play a role, with topical medications serving as the first approach [8].

If patients continue to have consistently elevated IOPs on maximum medical management, surgical management, such as placement of a glaucoma drainage device, becomes necessary. Placement of a drainage device can be difficult in these patients given their thick corneas and small anterior segments. Therefore, a pars plana vitrectomy may be required to facilitate placement of the tube behind the iris [9]. This type of surgery is not without risks, and complications can occur including malpositioning or migration of the tube, endophthalmitis, and corneal decompensation [8]. Trabeculectomy is another option, but these patients often require use of aphakic contact lenses, which may be difficult in the context of a bleb [9]. Many children go on to require subsequent interventions [8].

Summary Table

<p>EPIDEMIOLOGY OR ETIOLOGY</p> <ul style="list-style-type: none"> ◆ Second most common cause of glaucoma in the pediatric population [1] ◆ Incidence is 15-45% [4] ◆ Cataract surgery at a young age is most consistent risk factor [3] <ul style="list-style-type: none"> • Early lensectomy may interfere with maturation of the trabecular meshwork [6] ◆ Postoperative inflammation and retained lens material may contribute to the development of disease [6,7] 	<p>SIGNS</p> <ul style="list-style-type: none"> ◆ Elevated IOP, corneal clouding [8] ◆ Excessive loss of hyperopia ◆ Thick cornea and small anterior segment [9] ◆ Open angle but can see obstruction of the trabecular meshwork by pigment or crystalline deposits [6,10] ◆ Optic nerve cupping ◆ Constriction of the visual field ◆ Thinning of the retinal nerve fiber layer on ocular coherence tomography of the optic nerve
<p>SYMPTOMS</p> <ul style="list-style-type: none"> ◆ Often asymptomatic ◆ Can present with photophobia or irritability [8] 	<p>TREATMENT/MANAGEMENT</p> <ul style="list-style-type: none"> ◆ Topical IOP-lowering medications ◆ Trabeculectomy, although may be difficult in contact lens wearers [9] ◆ Glaucoma drainage devices [9]

References

1. Olitsky SE, Reynolds JD. Overview of glaucoma in infants and children. UpToDate (online resource). Topic 6272, Version 6215.6270. [Last updated Oct 18, 2017; Accessed Nov 4, 2017]:Available from <https://www.uptodate.com/contents/overview-of-glaucoma-in-infants-and-children>
2. Baily C, O'Keefe M. Paediatric Aphakic Glaucoma. *J Clin Exp Ophthalmol* 2012; 3:article 203. <http://dx.doi.org/210.4172/2155-9570.1000203> .
3. Zhu XJ, Zhang KK, He WW, Sun XH, Meng FR, Lu Y. Diagnosis of pupillary block glaucoma after removal of congenital cataracts with
4. Kirwan C, O'Keefe M. Paediatric aphakic glaucoma. *Acta Ophthalmol Scand* 2006; 84(6):734-739. <https://pubmed.gov/17083529>
5. Levin AV. Aphakic glaucoma: a never-ending story? *Br J Ophthalmol* 2007; 91(12):1574-1575. <https://pubmed.gov/18024804>
6. Chen TC, Walton DS, Bhatia LS. Aphakic glaucoma after congenital cataract surgery. *Arch Ophthalmol* 2004; 122(12):1819-1825. <https://pubmed.gov/15596586>
7. Phelps CD, Arafat NI. Open-angle glaucoma following surgery for congenital cataracts. *Arch Ophthalmol* 1977; 95(11):1985-1987. <https://pubmed.gov/921576>
8. Jeganathan VSE, Mulvihill A, Montgomery D. Paediatric Aphakic Glaucoma: A Diagnostic and Management Challenge. *Optom Open Access* 2016; 1:article 115. <http://dx.doi.org/110.4172/2476-2075.1000115> .
9. Alward WLM. Aniridia, Phacomatoses, & other pediatric glaucomas. Iowa Glaucoma Curriculum, [accessed Nov 4, 2017]: Available from <http://curriculum.iowaglaucoma.org/chapter/13/video/183> .
10. Walton DS. Pediatric aphakic glaucoma: a study of 65 patients. *Trans Am Ophthalmol Soc* 1995; 93:403-420. <https://pubmed.gov/8719689>

Suggested Citation Format

Madhan N, Stiff HA, Zhang Z, Alward WLM. Aphakic Glaucoma. *EyeRounds.org*. posted December 14, 2017; Available from <http://EyeRounds.org/cases/263-aphakic-glaucoma.htm>

last updated: 12/14/2017

Uveitis Glaucoma Hyphema (UGH) Syndrome

Cheng Liang, BS, Austin R. Fox, MD, Jason P. Kam, MD, Wallace L.M. Alward, MD

posted October 3, 2017

INITIAL PRESENTATION

Chief Complaint

Elevated intraocular pressure and "cloudy, hazy" vision of the left eye

History of Present Illness

A 54 year-old-man was referred for elevated intraocular pressure (IOP) and decreased vision in the left eye (OS). His ocular history was remarkable for cataract extraction with intraocular lens (IOL) placement in both eyes (OU) and retinal detachment OU repaired by pars plana vitrectomy OU. Eight months prior to presentation, the IOL (Acrysof SN60AT single-piece lens) in the patient's left eye became displaced, and was subsequently repositioned in the ciliary sulcus. The patient developed macular edema in his left eye three months later for which he received a sub-Tenon triamcinolone acetonide injection and started prednisolone acetate eye drops. Two months prior to presentation, the patient developed an IOP of 48 mmHg OS. The patient's left eye was treated with latanoprost every night, timolol-brimonidine (Combigan©) two times a day, and dorzolamide two times a day. He also started oral acetazolamide 500 mg two times a day. One week later, IOP was noted to be in the upper teens, and acetazolamide was discontinued. However, two weeks prior to presentation, his IOP was again elevated to 52 mmHg, and acetazolamide 500 mg two times a day was restarted. Pigment was noted in the anterior chamber one week prior to presentation, and he was restarted on prednisolone acetate eye drops. The patient was referred to the Department of Ophthalmology at the University of Iowa Hospitals and Clinics for evaluation.

Past Ocular History

Traumatic hyphema of right eye (OD) secondary to a bungee cord injury (30 years prior)

Past Ocular Surgeries

Right Eye

- ◆ Cataract extraction/posterior chamber IOL placement (18 years prior)
- ◆ Pars plana vitrectomy (PPV) for retinal detachment (7 years prior)

Left Eye

- ◆ Cataract extraction/posterior chamber IOL placement (16 years prior)
- ◆ PPV for retinal detachment (11 years prior)
- ◆ PPV, repositioning of single-piece IOL into the ciliary sulcus (1 year prior)

Past Medical History

None

Medications

Clindamycin (tooth abscess)

Allergies

No known drug allergies

Family History

Father with glaucoma, retinal detachment

Social History

Social alcohol use, no tobacco use

Review of Systems

Unremarkable

OCULAR EXAMINATION

Snellen Distance Visual Acuity (with correction)

- ◆ OD: 20/20
- ◆ OS: 20/20-1

Ocular Motility/Alignment

- ◆ OD: Full, Ortho
- ◆ OS: Full, Ortho

Intraocular Pressure (Goldmann Applanation)

- ◆ OD: 17 mmHg
- ◆ OS: 42 mmHg

Pupils

- ◆ OD: 5 mm to 3 mm, brisk reaction, no relative afferent pupillary defect (RAPD)
- ◆ OS: 5.5mm to 5 mm, minimal reaction, 0.9 log units RAPD by reverse

Pachymetry

- ◆ OD: 565 microns
- ◆ OS: 556 microns

Confrontation visual fields

- ◆ OD: Full to count fingers
- ◆ OS: Partial superior temporal, inferior temporal, superior nasal, inferior nasal deficiencies by count fingers

Slit lamp exam

OD

- ◆ Lids/lashes: Normal
- ◆ Conjunctiva/sclera: Clear, quiet
- ◆ Cornea: Clear
- ◆ Anterior chamber: 1+ pigment, trace flare (post-fluorescein)
- ◆ Iris: Normal Architecture
- ◆ Lens: Posterior chamber IOL

OS

- ◆ Lids/lashes: Normal
- ◆ Conjunctiva/sclera: Conjunctival scarring at area of previous sclerotomies
- ◆ Cornea: Krukenberg spindle, no keratic precipitates
- ◆ Anterior chamber: 1+ pigment, trace flare (post-fluorescein)
- ◆ Iris: Broad transillumination iris defects in the shape of the IOL (Figure 1)
- ◆ Lens: Sulcus IOL (single-piece)

Gonioscopy (Spaeth grading system*)

- ◆ OD Temporal, Nasal, Inferior: E45f 1+; Superior: E45f 2+
- ◆ OS: Temporal, Nasal, Superior: E50f 3+; Inferior: E50f 4+

*Note: A description of the Spaeth grading system is available at glaucomatoday.com/pdfs/0505_0506.pdf

Dilated fundus examination (DFE)

OD

- ◆ Vitreous: Optically empty
- ◆ Disc: Normal
- ◆ Cup-to-disc ratio: 0.45
- ◆ Macula: Normal
- ◆ Vessels: Normal
- ◆ Periphery: Laser scars inferiorly and nasally

OS

- ◆ Vitreous: Optically empty
- ◆ Disc: Vertically cupped, no disc hemorrhage
- ◆ Cup-to-disc ratio: 0.7
- ◆ Macula: Normal
- ◆ Vessels: Normal
- ◆ Periphery: Laser scars inferiorly and temporally

Additional testing

see figures 1-3

CLINICAL COURSE

The patient underwent a pars plana vitrectomy (23 gauge) with removal of the single-piece IOL and placement of a 3-piece sulcus IOL (Acrysof MA60AC, Alcon Laboratories, Ft. Worth, TX). Immediately following the PPV, an Ahmed

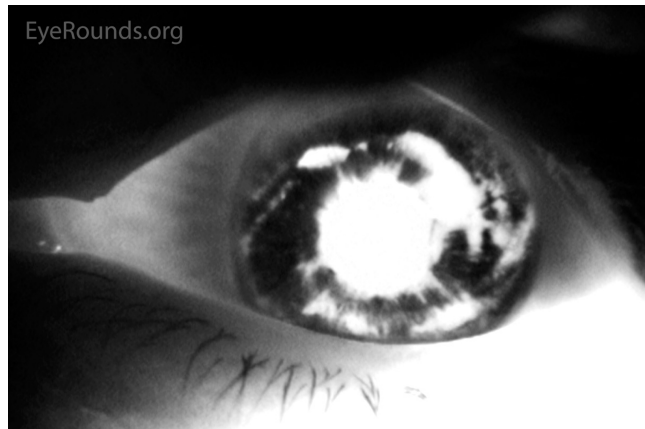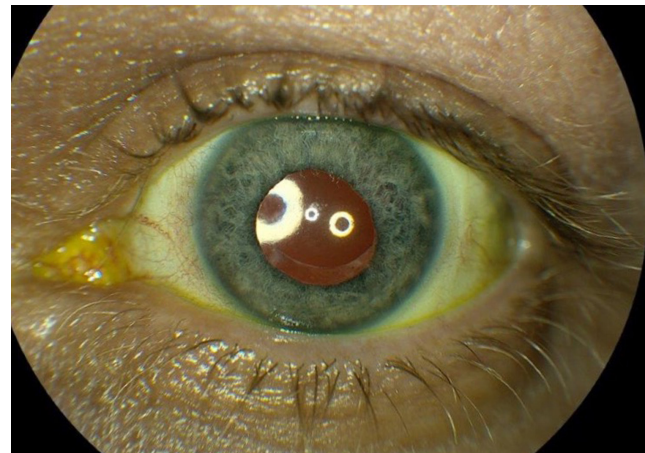


Figure 1: Color and infrared transillumination photos of the left eye. Multiple radial transillumination defects of the iris as well as circumferential defects that match the shape of the IOL haptics.

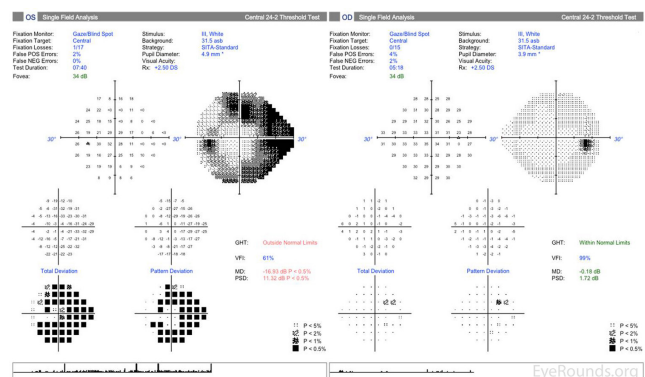
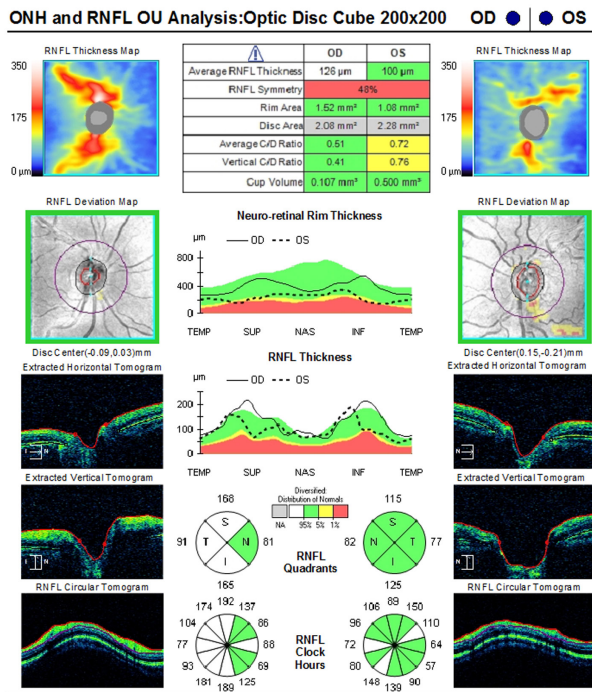


Figure 2: Humphrey Visual Fields (24-2). Left image: Normal visual field OD with good test reliability. Right image: Good test reliability with evidence of severe stage glaucoma with superior and inferior arcuate scotomas OS.

seton (model FP7, New World Medical, Rancho Cucamonga, CA) was inserted. By post-operative week 16, the visual acuity was 20/25, and IOP was 14 mm Hg on timolol-bromonidine (Combigan©) two times daily.



EyeRounds.org

Figure 3: Optical coherence tomography (OCT) of the optic nerve head (ONH) of both eyes. Although the signal strength is poor (6/10 OD and 5/10 OS), the ONH OCT demonstrates robust retinal nerve fiber layer (RNFL) in both eyes. However, the RNFL of the left eye is relatively thinned compared to that of the right eye. There is glaucomatous cupping and a thin neuroretinal rim in the left eye when compared with the right eye.

DIAGNOSIS

Uveitis-Glaucoma-HypHEMA-Syndrome

DISCUSSION

Uveitis-glaucoma-hypHEMA (UGH) syndrome was first described by Ellingson in 1978 and classically included uveitis, glaucoma, and hypHEMA in the setting of an anterior chamber IOL.[1] However, the term UGH syndrome is often used when one, two, or all three of these entities are present in the setting of any IOL causing irritation of the iris or angle structures.

Epidemiology

Although the incidence is not known, UGH syndrome is thought to be a rare condition that can occur in any patient population, including pediatric populations.[2] UGH syndrome was first associated, and is more commonly associated, with anterior chamber IOLs, single-piece acrylic IOLs, or sulcus lenses;[3] however, it can be seen with any type of IOL, including posterior chamber lenses and cosmetic iris implants.[4] With the predominant use of posterior chamber IOLs and modern advances in lens design, the incidence of UGH syndrome has declined.

Etiology/Pathophysiology

UGH syndrome results from an IOL chafing the iris, irido-corneal angle, or ciliary body, which leads to recurrent trauma to these structures. Uveitis results from mechanical breakdown of the blood aqueous barrier and resultant inflammation. A hypHEMA results from recurrent damage by the IOL to vascular tissue of the iris, ciliary body, or angle. Intraocular pressure elevation can be caused by pigment dispersion, uveitis, hypHEMA, direct injury to the aqueous drainage system, or a steroid response to corticosteroids used to treat UGH-related inflammation. Given that IOL irritation underlies the etiology of UGH syndrome, selection of the appropriate lens type, design, and size is crucial to minimize the risk of developing UGH syndrome.

Anterior chamber IOLs have traditionally been associated with UGH syndrome, as they were used when the first cases of UGH syndrome were described. The sizing of an anterior chamber IOL is crucial and should be approximated by measuring the horizontal white-to-white corneal diameter (limbus to limbus) and adding 1 mm. The anterior chamber IOL size and positioning should be assessed following implantation to ensure optimal fit. A small anterior chamber IOL may rotate or tilt to contact iris, whereas a large anterior chamber IOL may directly contact and irritate the iris and angle structures to cause UGH syndrome.

Sulcus IOLs are thought to be a more common cause of UGH syndrome given the close proximity to uveal tissue when intentionally or unintentionally placed in the sulcus. IOLs placed in the sulcus with square optic edges and large, thick, square haptics (e.g., single-piece acrylic IOLs) may contact and irritate iris anteriorly to cause UGH syndrome. In addition, sulcus IOLs with small, planar haptics (e.g., AcrySof SN60AT) may more easily dislocate to contact the uveal tissue.[3] An IOL with a thin, posteriorly angulated haptic and a smooth optic surface with rounded edges would be preferable to minimize iris chafing and the occurrence of UGH syndrome. As with anterior chamber IOLs, proper sizing and positioning of sulcus IOLs are crucial to decrease the contact with uveal tissue and chances of UGH syndrome. It has been recommended that single-piece acrylic IOLs and other IOLs designed for the capsular bag not be placed in the sulcus.[2] However, when placed in the sulcus, IOLs should be secure and clear of the posterior or iris surface. UGH syndrome may also occur with sulcus IOLs in the setting of reverse pupillary block, especially in susceptible eyes (i.e., myopia, post-vitreotomy).[5]

Posterior chamber IOLs may or may not be completely positioned in the capsular bag to contact uveal tissue and, though more rare, cause UGH syndrome.[6] In the setting of weakened zonules, such as in exfoliation syndrome or IOL subluxation, UGH syndrome is more likely to occur due to poor zonular support and posterior chamber IOL movement.

Signs/Symptoms

Patients may complain of blurred vision, transient vision loss, ocular pain or ache, erythropsia (i.e., objects take on a reddish hue), or photophobia. Slit lamp examination is

essential to help establish the diagnosis. A poorly positioned IOL optic or haptic contacting uveal tissue may be directly observed. Hyphema, cell and/or flare, transillumination iris defects, synechiae, pseudophacodonesis, or corneal pigment may also be identified on the slit lamp examination. Gonioscopy may demonstrate blood within the inferior angle, signs of mechanical erosion, poorly positioned haptics, or increased pigmentation of the trabecular meshwork. Ocular hypertension is often present, and optic disc cupping and glaucomatous vision loss may be present in advanced cases (Figures 2 and 3).

Testing/Laboratory work-up

Prothrombin time and international normalized ratio should be tested in patients on anticoagulation medications as these patients may have an increased risk of bleeding.

Imaging

Ultrasound biomicroscopy and OCT of the anterior segment may be useful to identify IOL position and contact with the iris or angle structures (Figure 4). Posterior segment ultrasound (B-scan) may be useful to identify a vitreous hemorrhage, if present. UGH plus syndrome is the name given to UGH syndrome in the presence of vitreous hemorrhage.

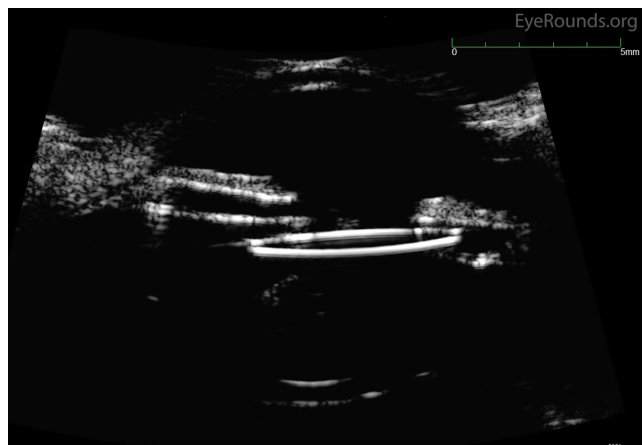


Figure 4: Ultrasound biomicroscopy of the left eye. The nasal optic of an IOL is seen abutting the posterior iris surface in a patient with UGH syndrome. (Note: Figure 4 was obtained from a different patient and is used only for illustration.)

Treatment / Management / Guidelines

Medical Management

Uveitis: Topical corticosteroid drops

Glaucoma: Prostaglandin analogs, beta-blockers, and carbonic anhydrase inhibitors.

Pilocarpine and other cholinergics should be avoided to prevent further chafing of the iris.

Hyphema: Topical corticosteroids drops and cycloplegics (e.g., cyclopentolate)

Surgical Management

Definitive treatment is to secure or exchange the IOL or iris implant. The UGH syndrome is one of the more common indications for IOL exchange surgery, representing 11.9% of IOL exchanges in one study.[7] Laser peripheral iridotomy may be used for the management of UGH syndrome resulting from reverse pupillary block.[5] In addition, serial intracameral anti-VEGF injections have been used to successfully manage UGH syndrome.[8]

<p>EPIDEMIOLOGY OR ETIOLOGY</p> <ol style="list-style-type: none"> Any population with an IOL <ul style="list-style-type: none"> ACIOL > Sulcus IOL > PCIOL Single-piece IOL > 3-piece IOL Iris implant 	<p>SIGNS</p> <ul style="list-style-type: none"> Cell and/or flare Pigment in angle or on cornea Transillumination iris defects Displaced lens/haptics Hyphema or blood in the angle or vitreous Ocular hypertension Optic disc cupping Glaucomatous field changes
<p>SYMPTOMS</p> <ul style="list-style-type: none"> Blurred vision Transient vision loss Ocular pain Erythropsia Photophobia 	<p>TREATMENT / MANAGEMENT</p> <ul style="list-style-type: none"> IOL exchange Uveitis: topical corticosteroids drops Glaucoma: Prostaglandin analogs, beta-blockers, Carbonic anhydrase inhibitors Hyphema: topical corticosteroids drops, cycloplegics

References

- Ellingson FT. The uveitis-glaucoma-hyphema syndrome associated with the Mark VIII anterior chamber lens implant. *J Am Intraocul Implant Soc* 1978;4(2):50-53. pubmed.gov/701165
- Lin CJ, Tan CY, Lin SY, Jou JR. Uveitis-glaucoma-hyphema syndrome caused by posterior chamber intraocular lens--a rare complication in pediatric cataract surgery. *Ann Ophthalmol (Skokie)* 2008;40(3-4):183-184. pubmed.gov/19230361
- Chang DF, Masket S, Miller KM, Braga-Mele R, Little BC, Mamalis N, Oetting TA, Packer M, Committee ACC. Complications of sulcus placement of single-piece acrylic intraocular lenses: recommendations for backup IOL implantation following posterior capsule rupture. *J Cataract Refract Surg* 2009;35(8):1445-1458. pubmed.gov/19631134

4. Arthur SN, Wright MM, Kramarevsky N, Kaufman SC, Grajewski AL. Uveitis-glaucoma-hyphema syndrome and corneal decompensation in association with cosmetic iris implants. *Am J Ophthalmol* 2009;148(5):790-793. pubmed.gov/19660735
5. Singh H, Modabber M, Safran SG, Ahmed, II. Laser iridotomy to treat uveitis-glaucoma-hyphema syndrome secondary to reverse pupillary block in sulcus-placed intraocular lenses: Case series. *J Cataract Refract Surg* 2015;41(10):2215-2223. pubmed.gov/26703298
6. Zhang L, Hood CT, Vrabec JP, Cullen AL, Parrish EA, Moroi SE. Mechanisms for in-the-bag uveitis-glaucoma-hyphema syndrome. *J Cataract Refract Surg* 2014;40(3):490-492. pubmed.gov/24417893
7. Davies EC, Pineda R, 2nd. Intraocular lens exchange surgery at a tertiary referral center: Indications, complications, and visual outcomes. *J Cataract Refract Surg* 2016;42(9):1262-1267. pubmed.gov/27697243
8. Rech L, Heckler L, Damji KF. Serial intracameral bevacizumab for uveitis-glaucoma-hyphema syndrome: a case report. *Can J Ophthalmol* 2014;49(6):e160-162. pubmed.gov/25433757

Citing this article

Cheng L, Fox AR, Kam JP, Alward WLM. Uveitis Glaucoma Hyphema (UGH) Syndrome. EyeRounds.org. posted October 3, 2017; Available from: EyeRounds.org/cases/257-UGH-syndrome.htm

last updated: 10/03/2017

Aqueous Misdirection

Aqueous misdirection synonyms are **malignant glaucoma**, **vitreous block glaucoma**, **ciliary block glaucoma**, **ciliolecular glaucoma**, or **ciliovitreous block glaucoma**.

Jacob A. Evans, BS; Jaclyn M. Haugsdal, MD; Wallace L. M. Alward, MD

posted September 26, 2016

Initial Presentation

Chief Complaint

Left-sided headache and eye pain

History of Present Illness

An 88-year-old hyperopic female presented with left eye pain rated 10/10 and associated blurred vision, headache, nausea, and vomiting. The pain started approximately 4 hours previously and progressively became worse. She denied other ocular symptoms including tearing and photophobia. The patient had a history of cataract extraction with intraocular lens placement and Nd:YAG (neodymium: yttrium aluminium garnet) capsulotomy bilaterally. She also had a history of having a laser procedure previously for an unknown diagnosis.

Past Ocular History

- ◆ Pseudophakia
- ◆ Hyperopia
- ◆ Pseudoexfoliation syndrome

Past Ocular Surgery

- ◆ Cataract extraction with posterior chamber intraocular lens in both eyes (OU) (more than 5 years previously)
- ◆ Nd:YAG laser capsulotomy OU (approximately 1 year previously)
- ◆ Unknown laser procedure (more than 10 years previously)

Past Medical History

- ◆ Hypothyroid
- ◆ Chronic pain
- ◆ Depression

Medications

- ◆ Venlafaxine
- ◆ Levothyroxine
- ◆ Trazodone
- ◆ Tramadol
- ◆ Hydromorphone

Allergies

- ◆ Iodine contrast

Ocular Family History

- ◆ Noncontributory

Social History

- ◆ Former smoker
- ◆ Uses occasional alcohol

Review of Systems

- ◆ Per HPI, Otherwise negative

Visual Acuity

- ◆ Distance without correction
 - Right eye: 20/30 -1
 - Left eye: 20/600
- ◆ Distance with correction
 - Left eye: 20/60
- ◆ Near card without correction
 - Right eye: 20/25
 - Left eye: 20/160

Ocular Alignment and Motility

- ◆ Orthotropic with full motility OU

Intraocular Pressure (IOP)

IOP measured by Tonopen®

- ◆ Right eye: 11 mmHg
- ◆ Left eye: 50 mmHg

Pachymetry

- ◆ Right eye: 518 μ m
- ◆ Left eye: 551 μ m

Pupil examination

- ◆ Right eye: 3 mm in dark \rightarrow 2 mm in light; brisk but minimal reaction to light
- ◆ Left eye: 5 mm in dark \rightarrow 5 mm in light; no reaction to light. 0.9 log unit relative afferent pupillary defect (RAPD)

Slit-lamp examination

- ◆ Right eye
 - Lids/Lashes: Normal
 - Conjunctiva: Clear and quiet
 - Cornea: Clear
 - Anterior chamber: Quiet and deep
 - Iris: Normal
 - Lens: Posterior chamber intraocular lens with open posterior capsule
 - Vitreous: Normal

- ◆ Left eye
 - Lids/Lashes: Normal
 - Conjunctiva: 1+ injection
 - Cornea: Clear
 - Anterior chamber: Shallow anterior chamber with 2 corneal thickness depth centrally and peripheral iridocorneal apposition
 - Iris: Peripheral iridotomy located at 10:30
 - Lens: posterior chamber intraocular lens with open posterior capsule
 - Vitreous: Normal; no cell

Fundus examination

- ◆ Right eye
 - Disc: Normal, peripapillary atrophy
 - Cup to disc ratio 0.45
 - Macula: Normal
 - Vessels: Normal
 - Periphery: Normal
- ◆ Left Eye
 - Disc: inferior notch, peripapillary atrophy
 - Cup to disc ratio 0.75
 - Macula: Normal
 - Vessels: Normal
 - Periphery: Normal

Gonioscopy

- ◆ Right eye: D35f1+ in all directions
- ◆ Left eye: A(A)25b in all directions

Ancillary Studies

Standardized ocular echography, left eye

- ◆ Mild vitreal opacities seen. Severe excavation of optic nerve. No retinal detachment or mass lesion was visualized.

CLINICAL COURSE

Multiple rounds of topical dorzolamide/timolol, brimonidine, and latanoprost were given to this patient in the emergency room. Additionally, she received dilating drops and intravenous acetazolamide. Her intraocular pressure declined to the low 30's and the anterior chamber started to deepen in the emergency room. She was seen in the eye clinic the following morning. At that time, the anterior chamber had again shallowed and the IOP returned to mid 40's (Left eye) by applanation. The patient received four additional rounds of topical dorzolamide/timolol, brimonidine, latanoprost, and atropine, in addition to immediate release acetazolamide. The IOP was unresponsive, and a pars plana vitrectomy with Ahmed Seton was performed. The day after the procedure, the patient had resolution of headache and eye pain (Left eye). The intraocular pressure was found to be 5. Unfortunately, the intraocular lens had dislocated posteriorly in the postoperative setting, likely

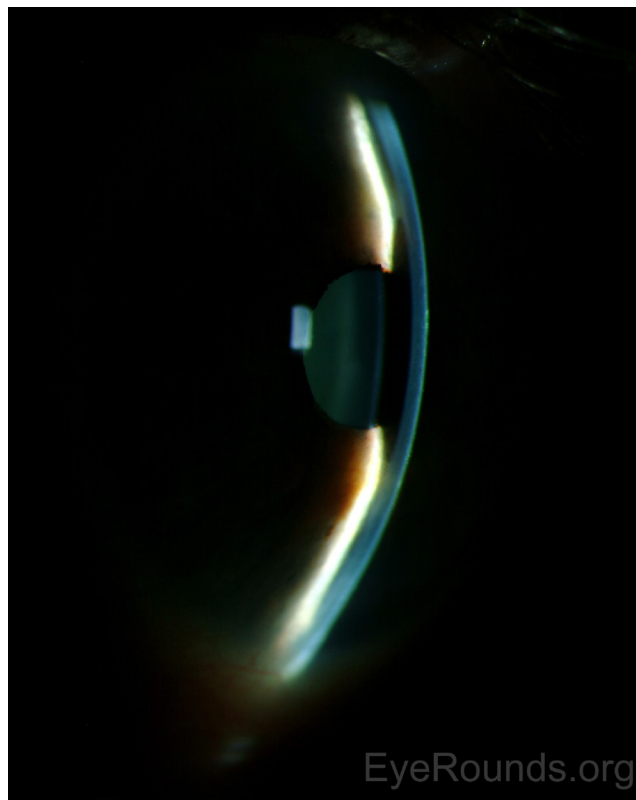


Figure 1: Slitlamp photo, Left eye (Photographer Brice Critser): Using the slit beam to assess anterior chamber depth, there is iridocorneal touch peripherally with approximately two corneal thicknesses deep centrally. The iris does not have the bombé configuration and the anterior chamber is diffusely shallow.

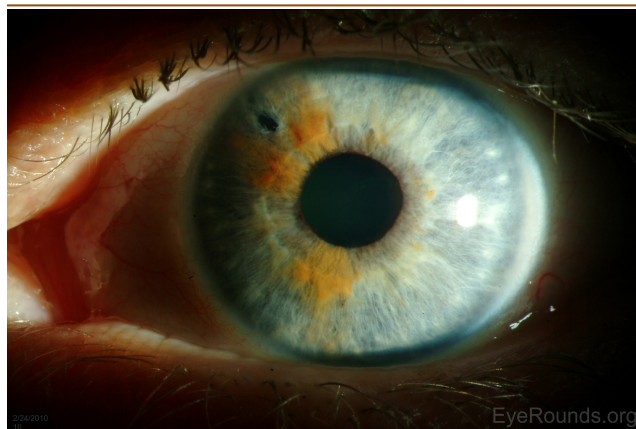


Figure 2: Slitlamp photo, Left eye (Photographer Brice Critser): Using a light aimed from the temporal limbus across the iris plane, a shadow is cast on the nasal aspect of the iris. This is created from the shallowing of the anterior chamber and anterior shift of the iris blocking the passage of light.

secondary to pseudoexfoliation, but vision with +10D lens and pinhole was in 20/40 range. She elected to defer additional surgery at this time.

DIAGNOSIS: Aqueous Misdirection

Differential Diagnosis of flat or shallow anterior chamber and elevated IOP

- ◆ Aqueous misdirection
- ◆ Pupillary block
- ◆ Choroidal effusion/hemorrhage/mass lesion
 - Hemorrhagic, Appositional/Kissing Choroidal Detachment
 - Serous, Appositional/Kissing Choroidal Detachment
- ◆ Ciliary body rotation
- ◆ Hypotony with appplanation of crystalline lens

DISCUSSION

Aqueous misdirection is a form of secondary glaucoma, related to pressure buildup from trapping of aqueous within the vitreous. It typically presents with diffuse shallowing (both central and peripheral) of the anterior chamber in the setting of elevated intraocular pressure, and is considered a diagnosis of exclusion (1, 2).

Etiology/Epidemiology

Aqueous misdirection typically occurs after correctional surgery for angle closure glaucoma. These patients usually have a history of angle closure or peripheral anterior synechiae (3). Aqueous misdirection has infrequently been associated with trauma, inflammation, or an unknown cause (4-6). It may occur days to months postoperatively; one study found median time to diagnosis was 33 days (7).

Pathophysiology

Aqueous misdirection occurs when aqueous is directed posteriorly and becomes trapped within the vitreous (8). This causes compression of the anterior vitreous making it more impermeable to aqueous (6, 9). This impermeability decreases the ability of the aqueous to flow freely forward through the posterior chamber to the anterior chamber, which leads to further trapping of aqueous in the posterior segment (8). The mechanism by which aqueous initially becomes directed posteriorly and trapped is unknown, though many theories have been proposed (9).

Signs/Symptoms

The key features that distinguish aqueous misdirection from similar diagnoses are diffuse shallowing of the anterior chamber (thus absent iris bombe), anterior displacement of the lens-iris diaphragm and a posterior segment free of hemorrhage, masses, or vein occlusion (6). A patent iridotomy/iridectomy in the setting of a flat or shallow anterior chamber is another clue to this diagnosis (4).

Distinguishing aqueous misdirection from other clinical entities can be difficult. Pupillary block presents with a deep central anterior chamber with a shallow periphery, and does not appear in the presence of a patent iridotomy

(4, 6). Pupillary block may be either primary (the most common mechanism of primary angle closure glaucoma) or secondary. Major secondary etiologies include ectopia lentis, cataractous lens intumescence, aphakia/pseudophakia with dislocated intraocular lens, pupillary capture by intraocular lens implant, or posterior synechiae. Pupillary block is uncommon after surgery for angle closure glaucoma.

Anterior rotation of the ciliary body due to swelling, inflammation, medications, or masses can also cause a shallow anterior chamber. Additional testing, such as echography and anterior segment imaging, can be used to look for masses or effusions causing the anterior movement of the ciliary body.

Suprachoroidal hemorrhage is associated with severe eye pain, and hemorrhage will be detected either by dilated fundus exam or with echography (6). The absence of such on B-scan ultrasonography rules out suprachoroidal hemorrhage (1).

Finally, hypotony may be deceptive because it can present with a shallow anterior chamber and the lens may be opposed to the cornea causing artificial elevation of intraocular pressure (6, 10). This entity should be distinguishable from the others simply by palpation of the eye, revealing a hypotonous globe.

Imaging

B-scan ultrasonography is useful to rule out other causes of flat anterior chamber such as choroidal effusions, suprachoroidal hemorrhage, and masses (1). High-resolution ultrasound biomicroscopy may assist in diagnosis by demonstrating anterior displacement of the lens-iris diaphragm, and possibly even anterior rotation of the ciliary body, ciliary processes, and/or zonules (5).

Treatment Guidelines

The first line treatment is medical therapy consisting of cycloplegics and aqueous suppressants (1, 3). Cycloplegia is the most important treatment as it moves the iris-lens diaphragm posteriorly in addition to relieving iris-lens apposition with dilation. A typical regimen includes atropine 1% four times a day (8). Aqueous suppressants include beta blockers, alpha 2 agonists, and oral and topical carbonic anhydrase inhibitors. Osmotic agents can be used to shrink the vitreous (3, 8). Cholinergics should be avoided as these medications tend to shift the lens-iris diaphragm forward. It is possible for up to 50% of cases to be relieved using such a regimen for 5 days, after which the medications may be tapered. However, recurrence is common, and a more definitive treatment may be necessary (8). Other potential treatment options include Nd:YAG laser therapy for aphakic and pseudophakic patients to disrupt the anterior vitreous face.

A pars plana vitrectomy is considered the definitive treatment (1, 3, 11). Removal of the anterior hyaloid is the most critical part of this surgery in order to prevent recurrence (8). Pars plana lensectomy should be added if damage to

Table. Summary: Aqueous Misdirection

<p>EPIDEMIOLOGY</p> <ul style="list-style-type: none"> ◆ Incidence 0.4 – 4% of eyes after incisional surgery, especially for angle-closure glaucoma (4, 5, 13-16) ◆ Risk factors <ul style="list-style-type: none"> ○ Hyperopia ○ History of angle closure ○ Trauma or inflammation (4, 6, 7) ○ May occur days to months postoperatively (7) 	<p>SIGNS</p> <ul style="list-style-type: none"> ◆ <i>Diffusely</i> shallow anterior chamber (absent iris bombe) (1, 6) ◆ Elevated intraocular pressure (2, 6) ◆ Patent iridotomy/iridectomy (2) ◆ Dilated fundus exam or echography without choroidal detachment, suprachoroidal hemorrhage, or masses (4)
<p>SYMPTOMS</p> <ul style="list-style-type: none"> ◆ Eye pain ◆ Blurry vision/halos ◆ headache/brow ache ◆ nausea or vomiting 	<p>TREATMENT</p> <ul style="list-style-type: none"> ◆ Medical management with cycloplegia, aqueous suppressants (topical beta blockers, alpha 2 agonists, and both topical and oral carbonic anhydrase inhibitors), while avoiding cholinergics (3, 6, 8) ◆ Nd:YAG laser capsulotomy (3, 6) ◆ Definitive treatment is pars plana vitrectomy (1, 3, 6, 8, 11)

the crystalline lens occurs or if it is not possible to deepen the anterior chamber by vitrectomy and anterior hyaloidectomy alone (1, 8). Prophylactic pars plana vitrectomy may be considered during intraocular surgery for the fellow eye of a patient with a prior history of aqueous misdirection (12).

Supplemental Information

Gonioscopy gonioscopy.org

Hemorrhagic, Appositional/Kissing Choroidal Detachment eyerounds.org/atlas/pages/choroidal-detachments/HAK.htm

Iowa glaucoma curriculum video on aqueous misdirection: curriculum.iowaglaucoma.org/chapter/19

Serous, Appositional/Kissing Choroidal Detachment eyerounds.org/atlas/pages/choroidal-detachments/SAK.htm

REFERENCES

1. Alvi NP, Cantor LB. Aqueous Misdirection Syndrome. In: Yanoff M, Duker JS, editors. Ophthalmology. London: Elsevier; 2014. p. 1092-3.
2. Kaplowitz K, Yung E, Flynn R, et al. Current concepts in the treatment of vitreous block, also known as aqueous misdirection. *Surv Ophthalmol.* 2015;60(3):229-41.
3. Ophthalmology AAO. Aqueous Misdirection. Basic and Clinical Science Course: Section 10, 2015-2016 Glaucoma. San Francisco: AAO; 2015. p. 131-3.
4. Foreman-Larkin J, Netland PA, Salim S. Clinical Management of Malignant Glaucoma. *J Ophthalmol.* 2015;2015:283707.
5. Shen CJ, Chen YY, Sheu SJ. Treatment course of recurrent malignant glaucoma monitoring by ultrasound biomicroscopy: a report of two cases. *Kaohsiung J Med Sci.* 2008;24(11):608-13.
6. Alward WLM. Aqueous Misdirection. Iowa Glaucoma Curriculum. Updated March 2016. Cited June 30, 2016.; Available from curriculum.iowaglaucoma.org/chapter/19/video/191.
7. Greenfield DS, Tello C, Budenz DL, et al. Aqueous misdirection after glaucoma drainage device implantation. *Ophthalmology.* 1999;106(5):1035-40.
8. Ramulu PY, Gedde SJ. Aqueous Misdirection. In: Shaarawy TM, Sherwood MB, Hitchings RA, Crowston

- JG, editors. *Glaucoma*. London: Elsevier; 2015. p. 836-46.
9. Epstein DL, Hashimoto JM, Anderson PJ, et al. Experimental perfusions through the anterior and vitreous chambers with possible relationships to malignant glaucoma. *Am J Ophthalmol*. 1979;88(6):1078-86.
 10. Liebmann JM, Weinreb RN, Ritch R. Angle-closure glaucoma associated with occult annular ciliary body detachment. *Arch Ophthalmol*. 1998;116(6):731-5.
 11. Bitrian E, Caprioli J. Pars plana anterior vitrectomy, hyaloido-zonulectomy, and iridectomy for aqueous humor misdirection. *Am J Ophthalmol*. 2010;150(1):82-7. e1.
 12. Chaudhry NA, Flynn HW, Jr, Murray TG, et al. Pars plana vitrectomy during cataract surgery for prevention of aqueous misdirection in high-risk fellow eyes. *Am J Ophthalmol*. 2000;129(3):387-8.
 13. Nguyen QH, Budenz DL, Parrish RK, 2nd. Complications of Baerveldt glaucoma drainage implants. *Arch Ophthalmol*. 1998;116(5):571-5.
 14. Olayanju JA, Hassan MB, Hodge DO, et al. Trabeculectomy-related complications in Olmsted County, Minnesota, 1985 through 2010. *JAMA ophthalmology*. 2015;133(5):574-80.
 15. Jampel HD, Musch DC, Gillespie BW, et al. Perioperative complications of trabeculectomy in the collaborative initial glaucoma treatment study (CIGTS). *Am J Ophthalmol*. 2005;140(1):16-22.
 16. Gedde SJ, Schiffman JC, Feuer WJ, et al. Three-year follow-up of the tube versus trabeculectomy study. *Am J Ophthalmol*. 2009;148(5):670-84.

Citing this article

Evans JA, Haugsdal JM, Alward WLM. Aqueous Misdirection. *EyeRounds.org*. September 26, 2016; Available from: EyeRounds.org/cases/244-Aqueous-Misdirection.htm

last updated: 09/26/2016

Hypotony: Late hypotony from trabeculectomy and Ahmed Seton with resulting hypotony maculopathy

Ben J. Janson MD, Jason P. Kam MD, Wallace L.M. Alward MD

posted April 24, 2017

INITIAL PRESENTATION

Chief Complaint

Decreased vision in right eye, without pain.

History of Present Illness

A 36-year old female presented with poor vision secondary to a low intraocular pressure (IOP) in her right eye. She had been diagnosed with bilateral idiopathic anterior uveitis in both eyes at age 27 and subsequently developed secondary glaucoma, either due to chronic intraocular steroid use or chronic uveitis, in the right eye (OD) worse than in the left eye (OS). She underwent bilateral trabeculectomies with mitomycin C (MMC) in 2009 and cataract extraction with intraocular lens implantation in 2010 OD and 2011 OS. She was lost to follow up until 2015 when she was found to have an over-filtering bleb with visual acuity (VA) of 20/70 and an IOP of 3 mmHg OD with hypotony maculopathy. She underwent blood patching with temporary improvement in the maculopathy, and another blood patching two months later in the right eye (8/2015 and 10/2015). She was lost to follow-up for another ten months and, in 2016, was urgently referred back with visual acuity in the right eye of 20/60 and IOP of 2 mmHg.

Past Ocular History

- ◆ Idiopathic bilateral non-granulomatous anterior uveitis
- ◆ Pseudophakia both eyes (OU)

Past Ocular Surgery

Right Eye

- ◆ Sub-tenon's triamcinolone (Kenalog®) (10/08)
- ◆ Trabeculectomy with MMC (3/09)
- ◆ Phacoemulsification with posterior chamber intraocular lens implant (PCIOL) (2010)
- ◆ Blood patch x2 (2015)

Left Eye

- ◆ Trabeculectomy with MMC (07/09)
- ◆ Phacoemulsification with PCIOL (2011)

Ocular medications

- ◆ Difluprednate (Durezol®) three times a day (TID) OU

Past Medical History

- ◆ Intramural leiomyoma of uterus
- ◆ Depression
- ◆ Generalized anxiety disorder
- ◆ Appendectomy
- ◆ Laparoscopic salpingo-oophorectomy
- ◆ Cholecystectomy

Medications

- ◆ Alprazolam 0.5mg, hydrocodone-acetaminophen 5-325mg, zolpidem 10mg

Allergies

- ◆ Clindamycin, doxycycline, morphine, ibuprofen, naproxen, penicillin, fluoxetine

Family History

- ◆ Non-contributory

Social History

- ◆ Smokes 3-4 cigarettes a day

Review of Systems

- ◆ Negative except for what is detailed in the history of present illness

OCULAR EXAMINATION

Visual Acuity with correction – Linear Snellen

- ◆ OD: 20/70-1 (pinhole 20/50+2)
- ◆ OS: 20/20-1

Ocular Motility/Alignment

- ◆ OD: Full
- ◆ OS: Full

Intraocular Pressure - Goldmann Applanation

- ◆ OD: 03 mmHg
- ◆ OS: 06 mmHg

Pupils

- ◆ OD: 5 mm in dark, 3 mm in light, no relative afferent pupillary defect (RAPD)
- ◆ OS: 5 mm in dark, 3 mm in light, no RAPD

Pachymetry

- ◆ OD: 552 microns
- ◆ OS: 566 microns

Slit lamp exam

- ◆ Lids/lashes: Normal OU
- ◆ Conjunctiva/sclera
 - OD: avascular Seidel-negative elevated bleb
 - OS: avascular Seidel-negative elevated bleb
- ◆ Cornea
 - OD: Descemet folds
 - OS: clear
- ◆ Anterior chamber: Deep and quiet OU
- ◆ Iris: Surgical superior iridectomy OU,
- ◆ Lens: PCIOL OU

Dilated fundus examination (DFE)

- ◆ Vitreous: Normal OU
- ◆ Disc
 - OD: Relative pallor, no disc hemorrhage
 - OS: No disc hemorrhage, healthy rim
- ◆ Cup-to-disc ratio
 - OD: 0.85
 - OS: 0.40
- ◆ Macula
 - OD: Striae
 - OS: Flat
- ◆ Vessels: Normal OU
- ◆ Periphery: Normal OU

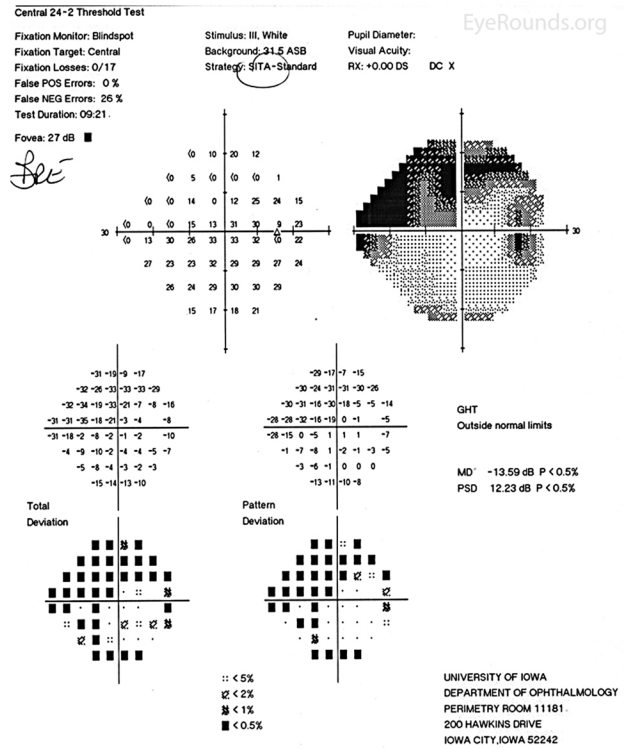


Figure 1: Humphrey Visual Field (HVF) of the right eye. This is a 24-2 visual field commonly used in the screening and monitoring of glaucoma patients. This patient's visual field represents severe stage glaucoma. There are both inferior and superior field defects and these defects approach central vision.

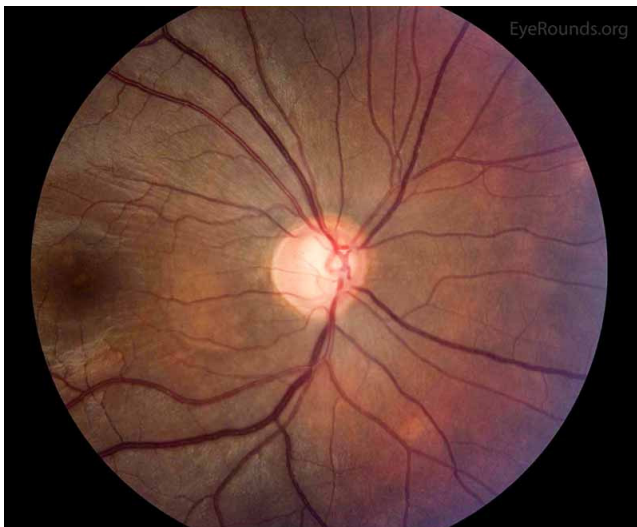


Figure 2: Color fundus photo of the right eye, centered over the optic nerve head. In this photo, the optic nerve appearance is consistent with glaucoma as the cup to disc ratio is increased due to loss of the nerve tissue. The supporting history and other studies support these changes as attributable to glaucoma as compared to other etiologies of enlarged cup to disc ratio.

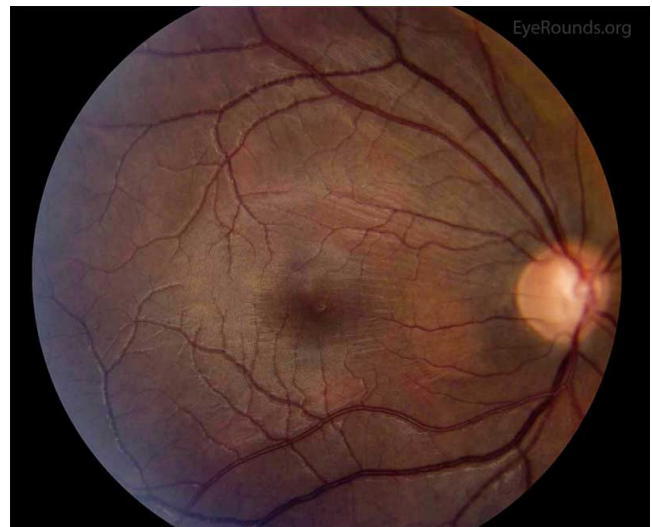


Figure 3: Color fundus photo of the right eye, centered over the macula. In this photo, the wrinkling and striation of the macula is present from the hypotony maculopathy. Due to the low intraocular pressure, folds form in the chorioretinal tissue. There are fine folds radiating out from the fovea and more prominent folds radiating from the optic disc.

Gonioscopy (Spaeth grading system)

- ◆ OD: B40f1+, scattered peripheral anterior synechiae (PAS)
- ◆ OS: B40f1+, scattered PAS nasally

Additional testing

Visual Fields (figure 1) and Fundus Photography (figures 2 and 3)

Differential Diagnosis: Hypotony after glaucoma surgery

- ◆ Overfiltering bleb or inadvertent bleb
- ◆ Cyclodialysis
- ◆ Retinal Detachment
- ◆ Uveitis
- ◆ Bleb leak
- ◆ Vascular Occlusion
- ◆ Ocular ischemia
- ◆ Infection/inflammation

CLINICAL COURSE

The patient underwent blood patching in the right eye to help raise the IOP in 8/2015, which improved her vision from 20/70 to 20/20 and her IOP from 3 mmHg to 8 mmHg. This improvement was short-lived and blood patching was performed again in 10/2015. Due to insurance and transportation issues, the next evaluation did not occur until 8/2016. At that time the IOP was 2 mmHg in her right eye and she had 20/60 vision. The patient's macular optical coherence tomography (OCT) at the time showed hypotony maculopathy (Image 4). She underwent surgery in 9/2016. During the surgery, the bleb was removed and the trabeculectomy site closed with a scleral patch graft. At the same time an Ahmed seton was inserted and covered with a corneal patch graft.

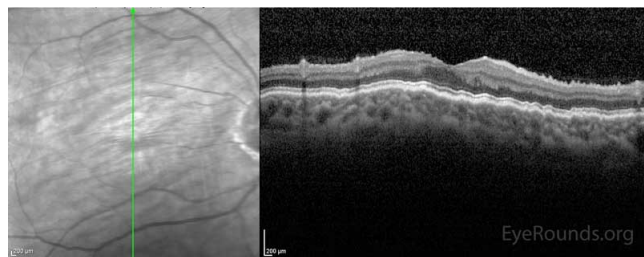


Figure 4: OCT showing hypotony maculopathy. There is a wrinkled appearance to all of the chorioretinal layers.

Post operative course

On post operative day 1, the visual acuity in the right eye was stable at 20/60 with an IOP of 8 mmHg however the following week her vision had dropped to 20/150 and her IOP was 0 with worsening corneal and macular folds and mild choroidal effusions. No retinal detachment was not-

ed. B-scan echography demonstrated a shallow choroidal effusion superiorly (Image 5) and the OCT showed persistent macular folds (Image 6). Atropine was added to her drop regimen to deepen the anterior chamber. There was no change in her weekly exam until she was seen on post operative week 7, at which time her vision had improved to 20/40 (PH 20/25) with an IOP of 9 mmHg, no corneal folds, and improved macular folds. At three months post-operatively her visual acuity was 20/20 and her IOP 7 mmHg. She was off all medications. Her macular folds had completely resolved

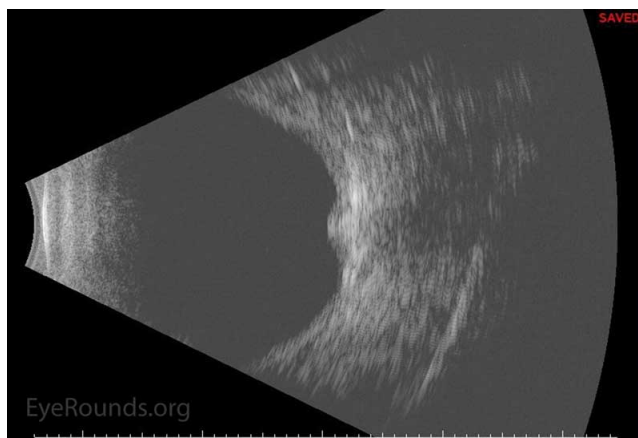


Figure 5: -B-scan echo showing superior shallow choroidal during post-operative course

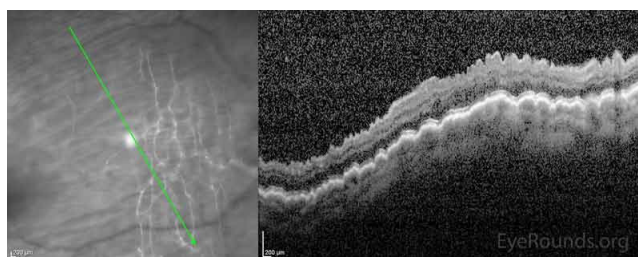


Figure 6: OCT during post-operative course showing worsening macular hypotony as compared to presentation OCT (see Figure 4)

DIAGNOSIS

- ◆ Hypotony due to overfiltering bleb

DISCUSSION

Etiology/Epidemiology

Hypotony is low intraocular pressure. Some define hypotony as an IOP <5 mmHg. More appropriately it should be considered to be an IOP below which the eye does not maintain its normal shape and may subsequently lose vision. Hypotony can be encountered in the ophthalmologist's practice, with many cases being caused by glaucoma surgery, as in this case report. The causes of hypotony include overfiltering blebs, inadvertent blebs created traumatically or during non-glaucoma surgery, leaking blebs, traumatic or surgically-induced cyclodialysis cleft, retinal

detachment, retinal vascular occlusion, or inflammation. [1] These cases typically present unilaterally, but bilateral cases of hypotony can occur due to systemic disease like myotonic dystrophy, dehydration, uremia, hyperosmotic agents, acidosis, and hyperglycemia.[1, 2]

Modern filtration surgery techniques have reduced the incidence of hypotony, but rates of post-operative hypotony still occur in up to 38% of cases. The risk increases in cases using antifibrotic agents like mitomycin C.[3] Meta-analysis suggests an increased risk of hypotony due to trabeculectomies performed without releasable sutures (RR 4.04) as compared to with releasable sutures (RR 2.57).[4]

Hypotony can occur early (within two weeks of surgery), or late (after two weeks). In one study, late hypotony after primary trabeculectomy with mitomycin C and laser suture lysis occurred in 42.2% of eyes after two years of follow up.[3] Risk factors associated with hypotony include younger age, male gender, myopia, and systemic illness.[3]

Hypotony is associated with a number of complications including hypotony maculopathy, choroidal effusion, cystoid macular edema, optic disc edema, and cataract formation. [1, 3]

Pathophysiology

The principles underlying hypotony can be divided into aqueous underproduction, increased aqueous outflow, or combination of the two.

Overfiltering blebs or leaking blebs are the most common causes of hypotony due to increased aqueous outflow. Increased drainage may also occur due to a cyclodialysis cleft, which is a disinsertion of the ciliary body from the scleral spur. This may develop following trauma or surgery and allows aqueous to drain into the suprachoroidal space. [3, 6]

Inflammation both decreases aqueous production in the ciliary body and increases outflow by increasing uveoscleral tract permeability.[1] Inflammation is not the only cause of decreased aqueous production, however. Aqueous suppressant medications (such as beta-adrenergic antagonists), disruption of the ciliary epithelium, or proliferative downgrowth over the ciliary body can all decrease aqueous production.[3]

Hypotony may cause several secondary structure-related complications which may lead to decreased vision, including chiliochoroidal detachment, hypotony maculopathy, papilledema, and phthisis bulbi. In a chiliochoroidal detachment, fluid accumulates in the space between the choroid and sclera due to relative difference between the higher choroidal vascular pressure and the lower intraocular pressure. As the IOP further declines, so too does the structural support to the eye, which can lead to collapse of the scleral wall and development of the hypotony-related macular folds seen in hypotony maculopathy. The redundant retina tissue becomes distorted, leading to a decline in visual acuity. Hypotony maculopathy is most likely to occur in younger individuals whose sclera is thinner, more flexible, and thus more conforming to pressure changes.

[5, 6] Papilledema may also be seen in hypotony, which is thought to be due to constriction of axonal bundles from an anteriorly-bowed lamina cribosa. In severe cases, prolonged hypotony can result in phthisis bulbi.[1, 2]

Signs/Symptoms

Hypotony is not always symptomatic and no IOP cutoff exists below which intervention is indicated. One study found 40% of eyes with low IOP lacked any associated physical signs and two-thirds of eyes maintained visual acuity within two lines of baseline acuity.[5] Individual eyes have a wide range of sensitivity to hypotony.[1] Even patients with a bleb-leak often remain asymptomatic, making objective signs critically important.

However, when symptoms do develop, visual acuity is often affected. The severity of this decline in visual acuity is quite variable, but will usually improve as the IOP improves.[2] The cornea can develop Descemet folds, astigmatism, and edema. The cornea can also decompensate in shallow anterior chambers and lead to cataract formation if contact develops between the lens and cornea.[1] Distinguishing iridocorneal touch from cornea-lenticular touch is important as cornea-lenticular touch can cause deterioration of both the cornea and lens.

Serous choroidal detachments may be visible on exam, but are usually asymptomatic. These serous choroidal detachments may enlarge significantly to the point of retina-to-retina contact, known as "kissing choroidals." [3, 7] (see Related EyeRounds atlas page eyerounds.org/atlas/pages/choroidal-detachments/SAK.htm) However, sudden vision loss and severe, throbbing pain can occur due to breakage of vessels, leading to suprachoroidal hemorrhage. This presence of hemorrhage carries a worse prognosis as compared to serous detachments.[3] Choroidal detachments can be distinguished from retinal detachments as their convex cross sectional appearance extends to the ciliary body, instead of stopping at the ora serrata like a retinal detachment.[7]

The optic nerve head may become edematous due to constriction of axons. With this, the optic nerve head can be mistaken to have a decreased cup to disc ratio as this edema leads to pseudo-reversal of cupping.[1]

The macula may have tortuous vasculature and folds in the chorioretinal tissue. In hypotony maculopathy, there are fine retinal folds radiating out from the fovea and branching chorioretinal folds radiating from the optic disc.

Testing/Laboratory work-up

Slit lamp and dilated fundus examination are important mainstays of the evaluation of hypotony. IOP should be checked by a reliable and accurate method, like Goldmann applanation tonometry. However, false elevations of IOP can occur when the lens contacts the cornea during applanation.[1] Slit lamp examination should include evaluation of trabeculectomy blebs. Seidel testing must be done to test for a leak. However, false negative results occur in slow or intermittent leaks and pressing on the globe may

be necessary.[1] Gonioscopy is utilized to examine for a cyclodialysis cleft and if unsuccessful, other methods like anterior segment OCT or ultrasound biomicroscopy should be utilized.

- ◆ OCT for evaluation of retinal and choroidal architecture changes
- ◆ B-scan ultrasound for ciliochoroidal effusion
- ◆ Ultrasound biomicroscopy or anterior segment OCT for evaluation of angles (if gonioscopy unsuccessful)

Treatment/Management/Guidelines

There are many approaches to the treatment of hypotony and should be tailored to the etiology. In general, it is difficult to increase the IOP. Medications like sodium azide, sodium nitroprusside, cation ionophores, and parasympathetic medications increase IOP, but are too toxic for clinical use.[3] Topical corticosteroids can be introduced, especially in inflammatory etiologies to increase both production of aqueous and create a steroid-induced IOP increase.[3] Atropine can also be used to deepen the anterior chamber and reduce the contact between the iris and cornea.

A recent Cochrane review of interventions of late trabeculectomy bleb leak found no evidence of comparative effectiveness except for one randomized controlled trial which found superiority of conjunctiva advancement technique in sealing leaks compared to amniotic membrane transplant.[8] Other approaches include fibrin glue, autologous blood, cryotherapy, conjunctiva compression sutures, bandage contact lens, Simmons shell, or laser grid treatment.[3, 8] Leaks should be evaluated carefully and treated due to the risk of endophthalmitis. If early after surgery, sometimes pressure patching or aqueous suppressants are enough to allow the epithelium to seal the defect.[1, 3]

Overfiltering blebs can be treated with pressure patches, wound revision, blood injection, trichloroacetic acid, stopping corticosteroids, or tightening the scleral flap with sutures.[1] The trabeculectomy site can also be revised

with bleb excision and placement of a full thickness scleral patch graft. In case reports, this approach achieved rapid return of visual acuity, reformation of the filtering bleb, and IOP control without medication.[9] A cyclodialysis cleft can sometimes be closed with laser treatment or can be surgically sutured.[1, 6] Retinal detachments should be repaired surgically. Ciliochoroidal effusions will often spontaneously resolve as the IOP improves, but can be treated with corticosteroids and anticholinergic eye drops.[1] If the ciliochoroidal effusion is large or touching the midline, surgical drainage should be considered.[1]

<p>EPIDEMIOLOGY OR ETIOLOGY</p> <ul style="list-style-type: none"> ◆ Overfiltering bleb ◆ Inadvertent bleb (surgical or trauma) ◆ Leaking bleb ◆ Cyclodialysis cleft (trauma or surgical) ◆ Retinal detachment ◆ Retinal vascular occlusion ◆ Inflammation 	<p>SIGNS</p> <ul style="list-style-type: none"> ◆ Decreased IOP ◆ Corneal/Descemet folds ◆ Astigmatism ◆ Corneal edema ◆ Shallow/flat anterior chamber ◆ Associated signs of ciliochoroidal effusions, suprachoroidal hemorrhage, optic nerve head edema, hypotony maculopathy
<p>SYMPTOMS</p> <ul style="list-style-type: none"> ◆ Asymptomatic ◆ Decreased visual acuity ◆ Pain 	<p>TREATMENT/ MANAGEMENT</p> <ul style="list-style-type: none"> ◆ Varies by etiology ◆ Observation acceptable in some cases ◆ Surgical revision ◆ Autologous blood injection ◆ Fibrin glue ◆ Laser (cyclodialysis cleft)

References

1. Alward WLM. Hypotony. *Iowa Glaucoma Curriculum Version 1.2*. E-published. 2016; Chapter 50, p. 347-355 (itun.es/us/MIXqcb.l OR curriculum.iowaglaucoma.org/)
2. Bowling B. Acquired macular disorders. In Bowling B (eds), *Kanski's Clinical Ophthalmology, 8th edition*. Philadelphia: Elsevier; 2016; Chapter 14, p. 579-639.
3. Thygesen J. Late Hypotony. In Shaarawy TM, Sherwood MB, Hitchings RA, Cowston JG (eds), *Glaucoma, 2nd edition*. Philadelphia: Elsevier Saunders; 2015; Chapter 88, p. 863-881.
4. Zhou M, Wang W, Huang X, Zhang X. Trabeculectomy with versus without releasable sutures for glaucoma: a meta-analysis of randomized controlled trials. *BMC Ophthalmol* 2014;14(41):1-8. [PMID 24685235]
5. Yun S, Chua B, Clement CI. Does chronic hypotony following trabeculectomy represent treatment failure? *J Curr Glaucoma Pract* 2015;9(10):12-15. [PMID 26997826]
6. Gonzalez-Martin-Moro J, Contreras-Martin I, et al. Cyclodialysis: an update. *Int Ophthalmol* 2016; 37(2):441-457 [PMID 27392912]
7. Guthoff RF, Labriola LT, Stachs O. Diagnostic ophthalmic ultrasound. In Ryan SJ, Sadda SR (eds), *Retina, 5th edition*. Philadelphia: Elsevier Saunders; 2013; Chapter 9, p. 227-284.
8. Bochmann F, Azuara-Blanco A. Interventions for late trabeculectomy bleb leaks. *Cochrane Database Syst Rev*. 2012;9. ID CD006769. Available at dx.doi.org/10.1002/14651858.CD006769.pub2 [PMID 22972097]
9. Haynes WL, Alward WLM. Rapid visual recovery and long-term intraocular pressure control after donor scleral patch grafting for trabeculectomy-induced hypotony maculopathy. *J Glaucoma* 1995;4(3):200-201 [PMID 19920669]

Citing this article

Janson BJ, Kam JP, Alward WLM. Hypotony: Late hypotony from trabeculectomy and Ahmed seton with resulting hypotony maculopathy. EyeRounds.org. posted April 24, 2017; Available from: EyeRounds.org/cases/250-Hypotony.htm

last updated: 04/24/2017

Posner-Schlossman Syndrome (Glaucomatocyclitic Crisis)

Stephanie K. Lynch, MD, Lorraine M. Provencher, MD, Wallace L. M. Alward, MD

Posted August 25, 2016

History of Present Illness (HPI)

A 63-year-old male was evaluated on an urgent basis for pain, redness, and "elevated eye pressure" in the left eye. He described a history of three similar episodes in his left eye, in which he had the same symptoms and his eye pressure was elevated. His first episode occurred approximately 20 years ago (1980s), and at that time, he was diagnosed with acute angle-closure glaucoma (AACG) and treated with a large surgical iridectomy by an outside provider. Review of previous intraocular pressure (IOP) measurements showed an IOP spike to 54 mmHg in 2004 and 54 mmHg again in 2014. Left eye IOP ranged from 11 to 15 in between the episodes of high IOP. He has not required IOP-lowering medications in between episodes.

He denied any history of cold sores, shingles, or other rash. The episodes of pain and high pressure have not been preceded by or accompanied by systemic symptoms or illness.

Past Ocular History

- ◆ Described above in HPI
- ◆ Multiple iris nevi, right eye

Family Ocular History

- ◆ Mother with glaucoma

Past Medical History

- ◆ Hyperlipidemia
- ◆ Esophagitis
- ◆ Allergic rhinitis

Medications

- ◆ No ocular medications
- ◆ Atorvastatin, omeprazole, fluticasone nasal spray

Social History

- ◆ Occupation: real estate appraisal
- ◆ Rare/occasional alcohol use
- ◆ Denies tobacco or illicit drug use

Review of Systems

- ◆ Negative except as stated in HPI

Physical Examination

Visual Acuity (with correction)

- ◆ 20/20 Right eye (**OD**)
- ◆ 20/20-2 Left eye (**OS**)

Pupils

- ◆ **OD**: 3 → 2, brisk, no relative afferent pupillary defect (RAPD)
- ◆ **OS**: 4 → 4, fixed, 1+ RAPD by reverse

Confrontation Visual Fields

- ◆ Full to counting fingers both eyes (**OU**)

Extraocular Motility

- ◆ Full **OU**

Intraocular Pressure (Goldmann applanation tonometry)

- ◆ **OD**: 20 mmHg
- ◆ **OS**: 53 mmHg

Pachymetry

- ◆ **OD**: 553 microns
- ◆ **OS**: 583 microns

Slit Lamp Examination

Right eye

- ◆ **Eyelids/lashes**: Normal
- ◆ **Conjunctiva/Sclera**: Clear and quiet
- ◆ **Cornea**: Clear
- ◆ **Anterior Chamber**: Deep and quiet
- ◆ **Iris**: Multiple small nevi inferotemporally, blue iris
- ◆ **Lens**: 1+ nuclear sclerosis

Left eye

- ◆ **Eyelids/lashes**: Normal
- ◆ **Conjunctiva/Sclera**: 1+ injection, nasal pinguecula
- ◆ **Cornea**: Trace diffuse microcystic edema, cluster of small keratic precipitates (KP) inferonasally
- ◆ **Anterior Chamber**: Deep, no flare, a single cell visible
- ◆ **Iris**: Patent superonasal surgical peripheral iridectomy (PI), mild irregularity of the pupil, blue iris
- ◆ **Lens**: 2+ nuclear sclerosis, mild pigment on the anterior lens capsule, posterior synechiae at 11 o'clock

Gonioscopy (Spaeth grading system)

- ◆ **OD:** D40 f 1+
- ◆ **OS:** D40 f 1+ with small area of peripheral anterior synechiae superiorly over the PI

Fundus Examination

OD

- ◆ **Vitreous:** Normal, no cell
- ◆ **Disc:** Healthy rim, no disc hemorrhages, cup-to-disc ratio: 0.3
- ◆ **Macula:** Normal
- ◆ **Vessels:** Normal

OS

- ◆ **Vitreous:** Normal, no cell
- ◆ **Disc:** Mild thinning of inferior rim, no disc hemorrhages, cup-to-disc ratio: 0.4
- ◆ **Macula:** Normal
- ◆ **Vessels:** Normal

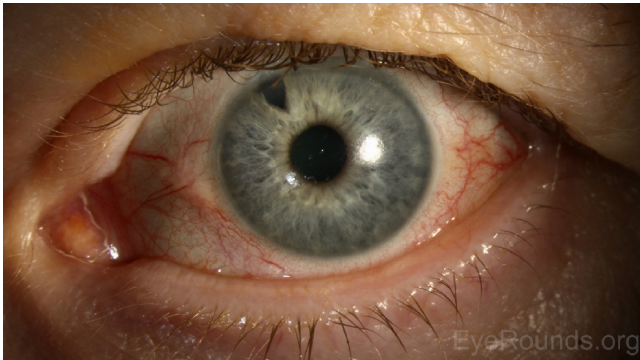

Figure 1: Slit lamp photograph of the left eye shows mild conjunctival injection. The pupil is irregular with posterior synechiae at 11 o'clock. The cornea is clear. The surgical PI is visible at 11 o'clock.

Clinical Course

The patient presented with a history of multiple episodes of elevated IOP OS over a period of several decades. IOP returned to normal without medications between spikes (Figure 3). A local provider initially treated our patient for AACG with surgical PI. Given his deep/wide angles on gonioscopy OU, this acute elevation of IOP in the 1980s was likely misdiagnosed as AACG. Outside records surrounding this episode could not be obtained. Our records, which captured two of the past three episodes, indicate that the IOP spiked to the mid-50s with only mild concurrent inflammation. With the episode detailed above, there was again evidence of subtle inflammation, including mild conjunctival injection, faint KP, and trace anterior chamber inflammation.

There was no evidence that his high IOP and inflammation were due to herpes simplex virus (HSV) (i.e., no history of skin lesions, corneal dendrites, transillumination defects, ciliary flush, or decreased corneal sensation). He had previously tested negative for other causes of infectious/inflam-

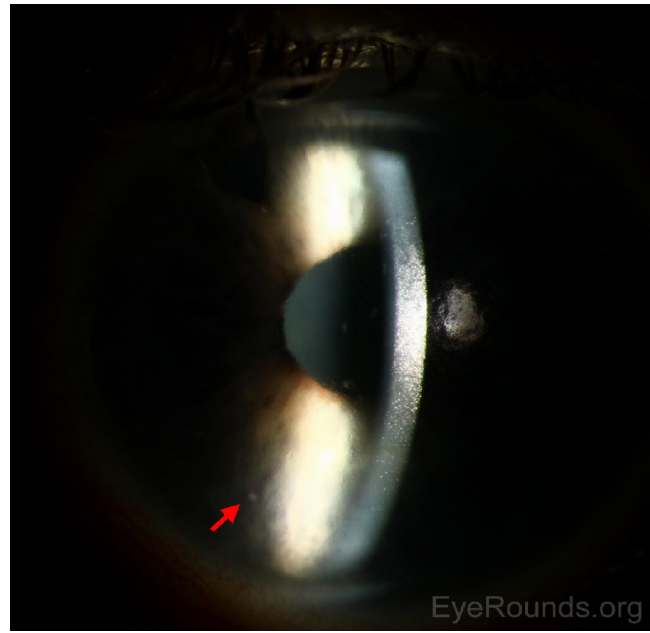


Figure 2: Slit lamp photograph of the left eye reveals a faint, small KP visible on the corneal endothelium (arrow).

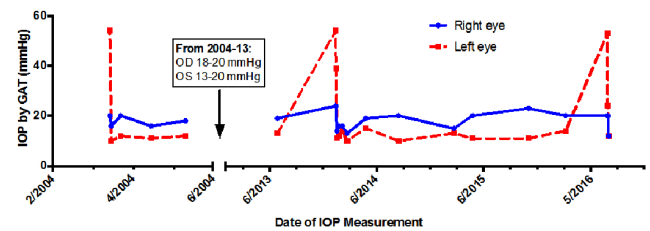


Figure 3: IOP for the patient over several decades with episodes of elevated IOP in 2004, 2014, and 2016. This graph is modeled after a graph by Posner and Schlossman (1948) [1].

matory uveitis, including syphilis, sarcoidosis, HLA-B27, tuberculosis, and Lyme disease. The presence of small peripheral anterior synechiae (PAS) was suggestive of prior inflammation. However, despite his history of recurrent episodes, he had very little sequelae of chronic inflammation. Although Fuchs' heterochromic iridocyclitis (FHI) is on the differential for recurrent unilateral inflammatory glaucoma, there was no iris heterochromia, iris transillumination defects, stellate KP, or fine angle neovascularization to suggest this diagnosis.

Humphrey 24-2 visual field testing from a routine follow-up visit five months prior indicated that the patient had a full visual field in both eyes. Cup-to-disc ratio was slightly larger on the left, and optical coherence tomography (OCT) of the retinal nerve fiber layer (RNFL) confirmed mild RNFL thinning and ganglion cell loss in the left eye only. On review of prior IOP records, the pressure in the left

eye appeared to range in the low teens to 20 in between episodes.

For acute management of the patient's elevated IOP, he received three rounds of brimonidine tartrate and timolol-dorzolamide (Cosopt®) every 15 minutes in addition to one dose of 500 mg oral acetazolamide. IOP decreased to 24 mmHg after several hours. Due to the subtle anterior segment inflammation, prednisolone acetate 1% was also started. The patient was instructed to continue timolol-dorzolamide (Cosopt®) twice daily (BID), brimonidine tartrate BID, and prednisolone four times daily OS. One week later, IOP OS had decreased to 12 mmHg. His prednisolone acetate 1% was tapered, and his IOP lowering medications were gradually stopped.

Diagnosis

Posner-Schlossman Syndrome

Discussion

Posner-Schlossman syndrome (PSS), also called glaucomatocyclitic crisis, is a rare inflammatory glaucoma that was first described in 1948 and affects individuals ages 20 to 60 [1]. PSS classically presents as recurrent episodes of unilateral, transient elevations in IOP, ranging in the 40s to 50s mmHg. The IOP elevation is typically out of proportion to the degree of pain and anterior chamber inflammation. IOP as high as 70 mmHg has been reported [2]. Vision loss occurs due to glaucomatous damage, which is thought to accumulate during episodes of markedly raised IOP.

Clinically, scant KP are seen; these may be referred to as "sentinel KPs." In our patient, the anterior chamber inflammation was minimal, and only a small cluster of KP was detected. Generally, peripheral anterior synechiae (PAS), and other severe sequelae of chronic uveitis, are not seen in PSS, unlike in other inflammatory glaucomas. Our patient was noted to have only a small area of PAS. Mild corneal edema due to elevated IOP may also be present on exam, as was noted with our patient.

Some evidence suggests that PSS may be associated with certain human leukocyte antigen (HLA) genes [3]. Several observational studies have investigated the association between PSS and active cytomegalovirus (CMV) infection in the anterior chamber [4-6]. Some uveitis specialists advocate treatment with valganciclovir both during attacks and between attacks as a prophylactic measure. However, a clear causal relationship between CMV infection and attacks of PSS has not been established. Other infectious associations have been proposed, including herpes simplex virus (HSV) [7], varicella zoster virus (VZV) [8], and *Helicobacter pylori* [9]. Unlike other inflammatory forms of glaucoma, the etiology of increased IOP in PSS cannot be explained completely by trabeculitis and/or inflammatory debris causing obstruction of the trabecular meshwork, as there is minimal anterior segment inflammation. Other explanations that have been postulated include alterations in vascular regulation or autonomic physiology [10-11]. Attacks may last up to several weeks, but they can also resolve within one day when properly treated.

Acute attacks of PSS are managed with IOP-lowering agents (topical +/- oral) as well as anti-inflammatory drops, such as prednisolone. Between episodes of PSS, the IOP is usually within a normal range. This characteristic helps distinguish PSS from other forms of inflammatory glaucoma that include subacute or chronically elevated IOP. The exception to this rule is that some patients with PSS may also have underlying primary open-angle glaucoma [12]. Current research has not clearly established whether treatment with IOP-lowering medications reduces the frequency of future glaucomatocyclitic attacks.

In one retrospective case series of 50 patients diagnosed with PSS, the development of glaucomatous visual field changes and optic neuropathy was proportional to the duration of disease [2]. Therefore, patients with PSS should be followed, at minimum, on an annual basis even if their attacks occur on a less frequent basis.

For more photographs and videos, please visit the chapter from the **Iowa Glaucoma Curriculum** on glaucomatocyclitic crisis (<https://curriculum.iowaglaucoma.org/chapter/24>)

<p>EPIDEMIOLOGY</p> <ul style="list-style-type: none"> ◆ Rare ◆ Most common in the middle decades (30 - 60 years old) ◆ Possible association with CMV virus 	<p>SIGNS</p> <ul style="list-style-type: none"> ◆ Elevated intraocular pressure (30 - 70 mmHg) ◆ Mild conjunctival injection ◆ Scant keratic precipitates ◆ Trace inflammation (cell and flare)
<p>SYMPTOMS</p> <ul style="list-style-type: none"> ◆ Decreased vision ◆ Discomfort or pain (brow ache) ◆ Mild injection 	<p>TREATMENT</p> <ul style="list-style-type: none"> ◆ Aqueous suppressants during the acute episode ◆ Topical corticosteroids, then taper ◆ Long-term follow-up - important for all patients

Differential Diagnosis for Posner-Schlossman Syndrome

- ◆ Fuchs heterochromic iridocyclitis <https://curriculum.iowaglaucoma.org/chapter/25>
- ◆ Herpetic keratouveitis
- ◆ Uveitic glaucoma <https://curriculum.iowaglaucoma.org/chapter/23>
- ◆ Acute angle-closure glaucoma <https://curriculum.iowaglaucoma.org/chapter/17>
- ◆ Chronic angle-closure glaucoma
- ◆ Primary open-angle glaucoma <https://curriculum.iowaglaucoma.org/chapter/14>

References

1. Posner A, Schlossman A. Syndrome of unilateral recurrent attacks of glaucoma with cyclitic symptoms. *Arch Ophthalmol* 1948; 39:517-520.
2. Jap A, Sivakumar M, Chee SP. Is Posner Schlossman syndrome benign? *Ophthalmol* 2001; 108(5):913-918.
3. Hirose S, Ohno S, Matsuda H. HLA-Bw54 and glaucomatocyclitic crisis. *Arch Ophthalmol* 1985; 103(12):1837-1839.
4. Chee SP, Bacsal K, Jap A, et al. Clinical features of cytomegalovirus anterior uveitis in immunocompetent patients. *Am J Ophthalmol*. 2008; 145:834-840.
5. Chee SP, Jap A. Presumed Fuchs heterochromic iridocyclitis and Posner-Schlossman syndrome: comparison of cytomegalovirus-positive and negative eyes. *Am J Ophthalmol* 2008; 146:883-889.
6. Rodier-Bonifas C, Cornut PL, Billaud G, et al. Cytomegalovirus research using polymerase chain reaction in Posner-Schlossman syndrome. *J Fr Ophthalmol* 2011; 34:24-29.
7. Yamamoto S, Pavan-Langston D, Tada R, et al. Possible role of herpes simplex virus in the origin of Posner-Schlossman syndrome. *Am J Ophthalmol* 1995; 119:796-798.
8. Tanaka Y, Harino S, Hara J. Cellular immunity as judged by varicella skin test in Posner-Schlossman syndrome in patients. *Folia Jpn* 1985; 36:972-976.
9. Choi CY, Kim MS, Kim JM, et al. Association between *Helicobacter pylori* infection and Posner-Schlossman syndrome. *Eye (Lond)* 2010; 24(1):64-69.
10. Raitta C, Vannas A. Glaucomatocyclitic Crisis. *Arch Ophthalmol* 1977; 95(4):608-612.
11. Puri P Verma D. Bilateral glaucomatocyclitic crisis in a patient with Holmes Adie syndrome. *J Postgrad Med* 1998; 44(3):76-77.
12. Kass MA, Becker B, Kolker AE. Glaucomatocyclitic crisis and primary open-angle glaucoma. *Am J Ophthalmol* 1973; 75(4):668-673.

Citing this article

Lynch SK, Provencher LM, Alward WLM. Posner-Schlossman Syndrome (Glaucomatocyclitic Crisis). *EyeRounds.org*. August 25, 2016; Available from: <http://eyerounds.org/cases/242-Posner-Schlossman-Syndrome.htm>

last updated: 01/30/2017

Case Presentations

Neuro-Ophthalmology

Functional Visual Loss

John J Chen, MD, PhD and Yanjun (Judy) Chen, MD, PhD

March 6, 2013

Chief complaint: "I can't see anything."

History of Present Illness: A 37-year-old male presented with decreased vision for the past 10-15 years, which had been progressively worsening over the past year. The patient was referred by his local optometrist because he could not read any of the letters on the chart and showed no improvement with refraction. He was referred for visual loss with a high suspicion for functional visual loss.

Past Ocular History: None

Past Medical History: Mild mental retardation and developmental delay, schizophrenia

Medications: Olanzapine

Allergies: None

Family History: Non-contributory

Social History: Disabled, semi-independent living. He denied alcohol or tobacco use.

Review of systems: As above, otherwise negative

Ocular exam

Visual Acuity

- ◆ Right eye (OD): Hand motion
- ◆ Left eye (OS): Hand motion
 - Despite claiming hand motion vision, he was able to check boxes on a questionnaire sheet. In addition, he was able to ambulate in an unfamiliar environment without difficulty.
 - On formal testing, he claimed that he was unable to see the optokinetic drum. However, he had appropriate nystagmus to the optokinetic drum.
 - He saw two eye charts with a vertical prism placed over one eye.

Pupils: 5→3, no Relative Afferent Pupillary Defect (RAPD), both eyes (OU)

Extraocular movements: Full

Confrontation visual fields: Unable to count fingers, but able to track objects placed in all four quadrants.

Intra-ocular pressure

- ◆ OD: 10 mmHg
- ◆ OS: 17 mmHg (squeezing)

External: Normal

Slit Lamp Exam: Unremarkable except mild para-central thinning of the cornea in both eyes.

Dilated Fundus Exam

Normal appearing optic nerves with cup-to-disc ratio of 0.2 in both eyes. The maculae were normal. The vessels and peripheral retina were normal.

Retinoscopy was performed given that the evaluation of subjective visual function was unreliable. The retinoscopy exam revealed an irregular reflex with scissoring in both eyes. This finding raised a suspicion of corneal irregularity as the cause of the decreased vision. Corneal topography showed asymmetric inferior steepening consistent with keratoconus or pellucid marginal degeneration (Figure 1).

We were unable to perform a manifest refraction because he stated that things were blurred and refused to acknowledge counting fingers. However, when we gave him a trial frame with the estimated refraction from the corneal topography, he was very satisfied with the outcome. He said he was seeing the best that he had in years. Although his best visual outcome would likely be achieved by the use of rigid gas permeable contact lenses due to his underlying keratoconus, he would be a poor candidate for this option due to his inability to manage contact lenses. Providing astigmatic correction with glasses appeared to have improved his visual acuity and will remain a viable treatment option.

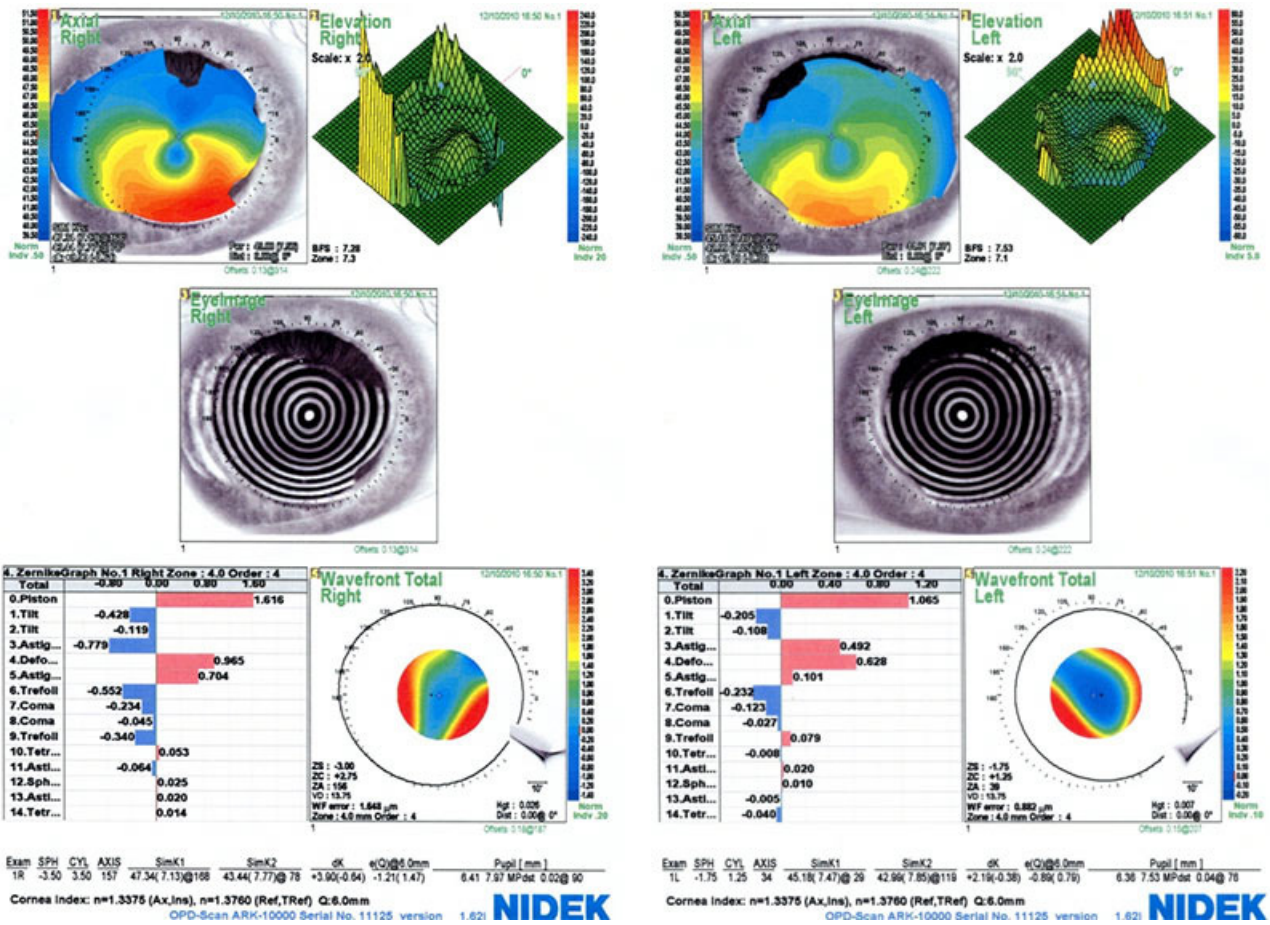
Diagnosis: Keratoconus masked by functional overlay.

Although there was clear functional overlay, the patient had true ocular pathology causing decreased vision. This case was challenging in that the reliability of the visual function testing was limited by his decreased mental capacity and poor cooperation. It would be easy to ignore his complaints of blurred vision because of the obvious discordance between his behavior and expressed visual capacities; although his visual acuity was measured hand motion, he clearly demonstrated ability to ambulate through unfamiliar territory, shake hands, and touch the examiner's finger reliably in various positions.

Keratoconus appeared to contribute to the visual decline, based on ocular exam findings of paracentral corneal thinning and irregular retinoscopic reflex, as well as corneal topography finding of asymmetric steepening inferiorly.

Discussion

Functional visual loss refers to a decrease in visual acuity or loss of visual field with no underlying physiologic or organic basis. Patients with functional visual loss make up 1-5% of the referrals to ophthalmologists.[1,2] The highest incidence occurs in 11-20-year-old patients with a female predominance (63%).[3] The average workup for a patient



Right eye

Left Eye

Figure 1. Corneal topography showing asymmetric inferior steepening consistent with keratoconus or pellucid marginal degeneration

with functional visual loss is greater than \$500 and likely millions of dollars are spent on fraudulent disability claims. [4] A thorough clinical examination can avoid unnecessary investigations and disability expenditures, therefore saving society money as a whole.

First and foremost, the diagnosis of functional or non-organic visual loss is one of exclusion. There is often an underlying true organic visual problem that is masked by functional complaints, and the main goal of any examination is to find the kernel of truth. Functional visual loss can be seen in a variety of patients. There can be a conscious purposeful report of decreased vision in malingering patients, such as patients seeking disability or monetary gain. A nonorganic report of decreased vision can also be part of a somatization disorder. Regardless of the etiology, it is important to have a repertoire of tests to differentiate true functional visual loss from organic visual loss. The approach and tests performed depends on the patient's complaint and can be broken down into two broad categories: decrease in visual acuity and loss of visual field. These can be further stratified between monocular or binocular visual loss and the degree of visual impairment.

Binocular blindness

◆ Nonvisual tasks

- The examination starts as the patient walks into the room, observing his ability to navigate to the chair and to shake hands. Appearance and demeanor of the patient can also contribute. For instance, it was shown that patients wearing sunglasses to a tertiary neuro-ophthalmology practice were more likely to have functional visual loss.[5]
- **Fingertip touching:** A patient with true binocular blindness can still touch their index fingers of opposite hands together because this task is based on proprioception and not visual cues. Patients with functional binocular blindness will often claim they are unable to do this.
- **Sign signature:** Same principal as fingertip touching. This can be done in a patient with true binocular blindness.

◆ Mirror test

- If the vision is at least light perception, moving a mirror in different angles will result in non-suppressible nystagmoid movements as the eyes follow the moving reflections.

- Sudden unannounced placement of a mirror in front of the patient may lead to accommodation, convergence, and miosis as the patient focuses on the image of themselves.
- ◆ **Optokinetic nystagmus drum:** Induced jerk nystagmus indicates at least 20/400 vision.
- 1. **Shock value test:** These include a variety of tests including the menace reflex where the examiner presents visual threats such as a closed fist and observes for blinking or flinching. The examiner can also suddenly drop an object to see if a patient will reflexively react.

Monocular blindness or visual impairment

- ◆ **Relative afferent pupillary defect (RAPD):** This is the most important objective test that can be performed if the patient claims to have a large difference in visual acuity between the two eyes. If there is no refractive error or media opacity causing the disparity in acuity, a RAPD will likely be present in the affected eye if there is true pathology.
- ◆ **Fogging test**
 - This can be done by placing a plus lens ($\geq +5.00D$ over the normal refractive correction) in front of the good/unaffected eye and a lens with minimal power over the affected eye. The patient is then asked to read the chart with both eyes. The patient may not realize that the unaffected eye is fogged and a patient with functional monocular visual loss often reads well with the “affected” eye.
 - Paired cylinders can also be used. A plus cylinder and a minus cylinder of the same power are placed in parallel in front of the good/unaffected eye. While the patient reads the chart, the axis on one cylinder is rotated 10-15 degrees to fog the good/unaffected eye. If the patient continues to read the chart successfully, they are revealing adequate vision in the “affected” eye.
- ◆ **Titmus stereopsis test:** Stereopsis requires binocular vision. Ability to see 9/9 circles requires 20/20 vision in both eyes. Visual acuity can be estimated based on stereopsis (see Table 1).

Table 1: Relationship of visual acuity and stereopsis

Visual acuity	Average Stereopsis (seconds of arc)	Titmus stereopsis
20/20	40	9/9 circles
20/25	43	8/9 circles
20/30	52	8/9 circles
20/40	61	7/9 circles
20/50	78	6/7 circles
20/70	94	5/9 circles
20/100	124	3/3 animals or 4/9 circles
20/200	160	3/9 circles or 2/3 animals

-Modified from [7]

◆ Prism tests

- **Base-out prism test:** A 10-prism diopter lens placed base-out in front of one eye should normally elicit a movement of both eyes toward the direction of the apex of the prism followed by a shift of the fellow eye back toward the center. A true loss of monocular vision will not result in conjugate movement when the prism is placed over the affected eye.
- **Vertical prism dissociation test:** A 4-prism diopter lens is placed base-down in front of the good/unaffected eye. A 20/20 or larger size Snellen is projected. If the patient is able to see two letters of equal clarity, it establishes good vision in the affected eye.[6]
- ◆ **Red-Green duochrome test:** The patient is given red-green glasses with the red lens over the affected eye. The patient is asked to read the red-green duochrome chart with both eyes. The eye behind the red lens is able to see letters on both sides of the chart, whereas the eye behind the green lens can only see letters on the green side of the chart. If the patient is able to read all of the letters, this demonstrates that the affected eye is able to read the letters displayed.
- ◆ **Color plate test:** The patient is given red-green glasses with the red lens over the affected eye. The Ishihara plates cannot be seen by the eye with the green filter. Ability to read the colors indicates at least 20/400 vision in the affected eye.
- ◆ **Cycloplegic test:** For younger patients with the ability to accommodate, a cycloplegic test can be used. Place tropicamide in only the good eye and saline in the affected eye. After accommodation is paralyzed, check the patient’s visual acuity at near with both eyes open. The patient may not realize that they are only reading with the affected eye and may demonstrate good near visual acuity.
 - Caveat: high myopes will still have good near vision after cycloplegia.

Bilateral visual impairment

- ◆ **Bottom-up visual acuity testing:** Begin with the smallest line (20/10 if available). Progressively increase the size saying that the size is “doubled” in size and express astonishment that the letters cannot be seen. This can often uncover better visual acuity than top-down visual acuity testing in patients with functional vision loss.
- ◆ **“Vision aids”:** The patient is given trial frames with four lenses equaling the correct prescription and told that the lenses are special magnifying lenses. This may lead to improvement in visual acuity indicating a nonorganic component.
- ◆ **Near vision testing:** A large discrepancy between near-visual acuity and distance acuity provides evidence of nonorganic disease.
- ◆ **Stereopsis:** see above. As mentioned above, this also can provide an assessment of visual acuity (Table 1).
- ◆ **Size consistency test:** Evaluate a patient’s ability to read the Snellen chart at 20 feet and then at 10 feet. The

patient should be able to read letters half the size of the letters read at the full distance. A patient with functional visual loss will often not admit to being able to read the smaller optotypes regardless of the proximity to the target.

Visual field loss

- ◆ **Saccade test:** Test saccadic eye movements into the reported absent portion of the field. A patient with nonorganic visual field loss may demonstrate accurate saccades to targets in the “nonseeing” field because they are assuming eye movements and not visual fields are being tested.
- ◆ **Confrontation testing**
 - The examiner asks the patient to count fingers in the “non-seeing” field and instructs to report “none” when none are seen. As the test progresses, the examiner changes to showing fingers silently. A patient response of “none” when the fingers are silently displayed in the “non-seeing” field confirms vision in that area.
- ◆ **Monocular and binocular visual field testing:** If the patient reports a monocular visual field defect, the visual field test can be repeated with both eyes open. If the field defect is still present under binocular testing, the monocular defect can be assumed nonorganic. This can be done with confrontation visual field testing or with formal evaluation such as Humphrey or Goldmann visual field testing.
- ◆ **Goldmann visual field testing:** Nonorganic visual fields often demonstrate a spiraling field that becomes smaller as the test object is moved around the field. Crossing isopters or a visual field that remains the same size regardless of the size or brightness of the test stimulus (yielding isopters nearly one on top of another) is also often seen in functional visual field loss.
- ◆ **Tangent screen:** A tangent screen test can be performed at two different distances from the screen (usually 1 and 2 meters) while maintaining the same ratio of target size to target distance (i.e., larger target at further distance). A patient with organically constricted visual fields will show an increase in the size of the visual field when moved to a farther distance while a patient with functional visual field loss will often report the same absolute size of the field (tubular or gun-barrel field).
 - A nonorganic tubular visual field can also be elicited with repeated confrontation visual field testing at 1 meter and at 2 meters from the patient.

Other tests

In addition to the above examination techniques, retinal imaging and electrophysiological testing can be helpful in elucidating functional vision loss from true organic vision loss. Optical coherence tomography can help identify optic nerve and retinal pathology.[8] In addition, fundus autofluorescence is very sensitive in detecting subtle macular pathology.[9] Multifocal electroretinogram is able to detect focal problems of the rods and/or cones within the macula, although responses can be voluntarily suppressed.

[10,11] Visually evoked potentials, which measure the speed of signal from the optic nerve to the occipital cortex, can also be helpful in some circumstances in differentiating nonorganic vision loss from true pathology.[12-15]

Management

Reassurance alone is the best treatment. Providing non-specific treatments, like glasses or eyedrops, provides a mixed message to the patient and is less effective than reassurance alone.[16,17] It is important to stress a good prognosis, which provides “a way out” and gives the patient the opportunity to recover.[18] Confrontation is rarely helpful.[19] Between 45% and 78% of patients will experience resolution of their visual symptoms with reassurance alone.[3,18,20,21] However, some patients will continue to have persistent functional visual loss, especially in patients with co-existing psychiatric disease or in patients with motivation for material secondary gain. Adults are more likely to have underlying psychiatric illness compared to children. Concomitant psychosocial stressors are more likely in children, while adults often develop functional visual loss after trauma.[3]

Once functional visual loss is diagnosed, it is important to schedule at least one follow-up appointment to maintain a rapport with the patient and also to ensure that there is no organic disease underlying the symptoms. It is estimated that approximately 2% of patients with a diagnosis of functional visual loss have true organic disease.[3] Common masqueraders include keratoconus, cone dystrophy, Stargardt disease, amblyopia, paraneoplastic syndromes, small occipital infarcts, and acute zonal occult outer retinopathy.

Diagnosing functional visual loss is an important skill that can begin the healing process for the functional patient. Using the appropriate clinical tests can obviate the need to perform expensive investigations, such as magnetic resonance imaging, and avoid false disability expenditures, therefore saving society money as a whole.

Differential Diagnosis

True organic disease, commonly keratoconus, cone dystrophy, Stargardt disease, amblyopia, paraneoplastic syndromes, small occipital infarcts, and acute zonal occult outer retinopathy.

Epidemiology	Symptoms
<ul style="list-style-type: none"> ◆ 1-5% of referrals to ophthalmologists. ◆ Highest proportion in 11-20-year-old patients, but can occur at any age. ◆ 63% female 	<ul style="list-style-type: none"> ◆ Binocular or monocular decreased vision and/or visual field loss
Signs	Treatment
<ul style="list-style-type: none"> ◆ See above for clinical tests 	<ul style="list-style-type: none"> ◆ Reassurance with appropriate follow-up

References

1. Bose S, Kupersmith MJ. Neuro-ophthalmologic presentations of functional visual disorders. *Neurol Clin* 1995;13(2):321-3
2. Schlaegel TF, Jr., Quilala FV. Hysterical amblyopia; statistical analysis of forty-two cases found in a survey of eight hundred unselected eye patients at a state medical center. *AMA Arch Ophthalmol* 1955;54(6):875-84.
3. Lim SA, Siatkowski RM, Farris BK. Functional visual loss in adults and children patient characteristics, management, and outcomes. *Ophthalmology* 2005;112(10):1821-8.
4. Keltner JL, May WN, Johnson CA, Post RB. The California syndrome. Functional visual complaints with potential economic impact. *Ophthalmology* 1985;92(3):427-35.
5. Bengtzen R, Woodward M, Lynn MJ, Newman NJ, Biousse V. The "sunglasses sign" predicts nonorganic visual loss in neuro-ophthalmologic practice. *Neurology* 2008;70(3):218-21.
6. Golnik KC, Lee AG, Eggenberger ER. The monocular vertical prism dissociation test. *Am J Ophthalmol* 2004;137(1):135-7.
7. Levy NS, Glick EB. Stereoscopic perception and Snellen visual acuity. *Am J Ophthalmol* 1974;78(4):722-4.
8. Sakata LM, Deleon-Ortega J, Sakata V, Girkin CA. Optical coherence tomography of the retina and optic nerve - a review. *Clin Experiment Ophthalmol* 2009;37(1):90-9.
9. Schmitz-Valckenberg S, Holz FG, Bird AC, Spaide RF. Fundus autofluorescence imaging: review and perspectives. *Retina* 2008;28(3):385-409.
10. Lai TY, Chan WM, Lai RY, Ngai JW, Li H, Lam DS. The clinical applications of multifocal electroretinography: a systematic review. *Surv Ophthalmol* 2007;52(1):61-96.
11. Vrabec TR, Affel EL, Gaughan JP, Foroozan R, Tennant MT, Klancnik JM, Jr., et al. Voluntary suppression of the multifocal electroretinogram. *Ophthalmology* 2004;111(1):169-76.
12. Bobak P, Khanna P, Goodwin J, Brigell M. Pattern visual evoked potentials in cases of ambiguous acuity loss. *Doc Ophthalmol* 1993;85(2):185-92.
13. Gundogan FC, Sobaci G, Bayer A. Pattern visual evoked potentials in the assessment of visual acuity in malingering. *Ophthalmology* 2007;114(12):2332-7.
14. Leavitt JA. Diagnosis and management of functional visual deficits. *Curr Treat Options Neurol* 2006;8(1):45-51.
15. Rover J, Bach M. Pattern electroretinogram plus visual evoked potential: a decisive test in patients suspected of malingering. *Doc Ophthalmol* 1987;66(3):245-51.
16. Kathol RG, Cox TA, Corbett JJ, Thompson HS. Functional visual loss. Follow-up of 42 cases. *Arch Ophthalmol* 1983;101(5):729-35.
17. Thompson HS. Functional visual loss. *Am J Ophthalmol* 1985;100(1):209-13.
18. Chen CS, Lee AW, Karagiannis A, Crompton JL, Selva D. Practical clinical approaches to functional visual loss. *J Clin Neurosci* 2007;14(1):1-7.
19. Gross MP, Sloan SH. Patients with eye symptoms and no organic illness: an interdisciplinary study. *Psychiatry Med* 1971;2(4):298-307.
20. Kathol RG, Cox TA, Corbett JJ, Thompson HS, Clancy J. Functional visual loss: II. Psychiatric aspects in 42 patients followed for 4 years. *Psychol Med* 1983;13(2):315-24.
21. Sletteberg O, Bertelsen T, Hovding G. The prognosis of patients with hysterical visual impairment. *Acta Ophthalmol (Copenh)* 1989;67(2):159-63.

Citing this article

Chen JJ, Chen Y. Functional Visual Loss. EyeRounds.org. March 6, 2013; available from: <http://www.EyeRounds.org/cases/165-functional-visual-loss.htm>

last updated: 03/06/2013

Ocular Tilt Reaction

53-year-old female complaining of vertical diplopia following a stroke and found to have a skew deviation, fundus torsion, and torticollis

Christopher A. Kirkpatrick MD; Matthew J. Thurtell MBBS, MSc

December 31, 2014

Chief Complaint: "Double vision"

History of Present Illness

A 53-year-old female presents as a referral from her neurosurgeon with a complaint of double vision. It was acute in onset, painless, and first noticed two weeks prior, immediately upon awakening from a cerebral angiogram with aneurysm stenting and coiling. She has a history of a dissecting left posterior cerebral artery (PCA) aneurysm and underwent coil embolization 5 months prior to presentation. Unfortunately, only 80% of the aneurysm was coiled, which led to her repeat cerebral angiogram with stenting and re-coiling of the remaining aneurysm. The procedure was complicated by decreased flow in several of the posterior circulation arteries, a small thrombus at the origin of the left PCA, and a complicated deployment of the pipeline stent. Following the procedure, she was noted to have a deteriorating neurologic status and an MRI was obtained that showed multiple subacute infarcts in the bilateral thalami, right occipital pole, right paramedian midbrain, cerebellar vermis, and both cerebellar hemispheres (Figure 1).

She complains of binocular diplopia that is vertical in nature. It has been constant and non-progressive since the onset. It is relieved with closing of either eye. The diplopia is unchanged in any particular gaze direction or head positioning and is similar for both distance and near.

Past Ocular History

- ◆ Refractive error and presbyopia for which she wears bifocal glasses
- ◆ No prior eye surgery or trauma
- ◆ No history of childhood strabismus

Past Medical History

- ◆ Left PCA aneurysm (as above)
- ◆ Breast cancer status post bilateral mastectomy with subsequent breast reconstruction
- ◆ Osteoarthritis status post right total hip replacement
- ◆ Hypertension
- ◆ Hyperlipidemia
- ◆ Anxiety

Medications

- ◆ Alprazolam
- ◆ Clopidogrel
- ◆ Anastrozole
- ◆ Quinapril
- ◆ Aspirin
- ◆ Simvastatin

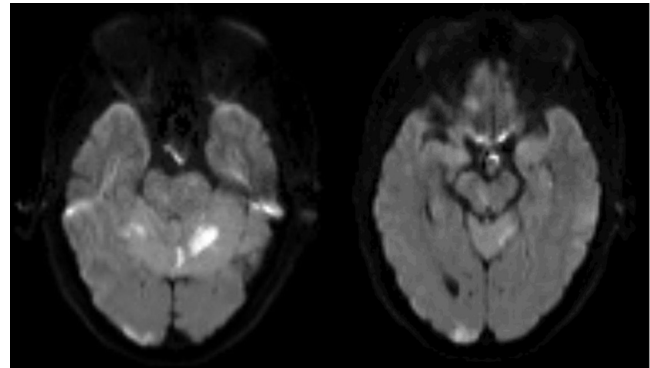


Figure 1: MRI axial diffusion-weighted imaging (DWI) showing hyperintensity (diffusion restriction) in the cerebellum, right occipital lobe, and right paramedian midbrain.

Family History

- ◆ Non-contributory

Social History

- ◆ She endorses very rare alcohol consumption and denies any current or past tobacco or illicit drug use.

Review of Systems

- ◆ She specifically denies noticing any ptosis, anisocoria, or loss of peripheral vision.

Ocular Exam

Visual Acuity (with correction)

- ◆ Right eye (OD): 20/25
- ◆ Left eye (OS): 20/25

Pupils

Both eyes (OU): 3 mm in dark, 2 mm in light, no relative afferent pupillary defect (RAPD)

Intraocular Pressure (IOP)

- ◆ OD: 11 mmHg
- ◆ OS: 12 mmHg

Confrontation Visual Fields

- ◆ Full OU

Motility

- ◆ Full OU

Alignment (Figure 2)

- ◆ Alternate head position: right head tilt
- ◆ A 7-8 prism diopter comitant left hypertropia
- ◆ 5 degrees of excyclotorsion OD and 7 degrees of incyclotorsion OS on double Maddox rod testing

Slit Lamp Exam

- ◆ External/Lids/Lashes: Normal OU
- ◆ Conjunctiva/Sclera: Clear and quiet OU
- ◆ Cornea: Clear OU
- ◆ Anterior Chamber: Deep and quiet OU
- ◆ Iris: Normal OU
- ◆ Lens: 1+ nuclear sclerosis OU

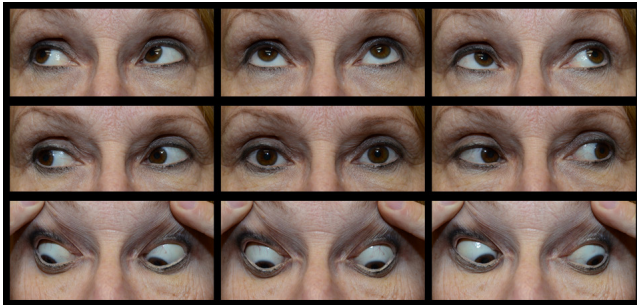

Figure 2: The patient had a very small angle, comitant left hypertropia (LHT). She adopted a compensatory right head tilt (not shown) and there was 5 degrees of excyclotorsion OD and 7 degrees of incyclotorsion OS with double Maddox rod (DMR) testing (see Figure 3). The alignment did not improve with earth neutral positioning.

Dilated Fundus Exam (Figure 3)

- ◆ Excyclotorsion OD and incyclotorsion OS
- ◆ Vitreous: Normal OU
- ◆ Disc: Normal OU
- ◆ Cup to Disc Ratio: 0.2 OU
- ◆ Macula: Normal OU
- ◆ Vessels: Normal OU
- ◆ Periphery: Normal OU

Diagnosis

Right ocular tilt reaction – skew deviation, fundus torsion, and torticollis, secondary to posterior circulation infarction

Clinical Course

The patient was able to achieve sensory fusion with 7 prism diopters of base down prism over her left eye. A Fresnel prism of this strength was placed on the left lens of her glasses. Given the comitant nature of her deviation, she was able to fuse well in all directions of gaze. She was scheduled to follow-up in the Neuro-ophthalmology clinic in 3 months time to assess for any change in her alignment or resolution of her diplopia.

DISCUSSION

A skew deviation is a vertical misalignment of the eyes that is caused by damage to the otolithic input to the ocular motor nuclei. When accompanied by binocular torsion, torticollis, and a tilt in the subjective visual vertical, it is termed the ocular tilt reaction. Lesions causing this are classically localized to the posterior fossa and can be from a variety of causes, but are many times a result of an acute lesion, such as ischemic stroke, demyelination, trauma, iatrogenic/post-surgical, hemorrhage, or tumor affecting the brainstem, cerebellum, or vestibular structures or pathways. It is thought that the ocular tilt reaction is likely

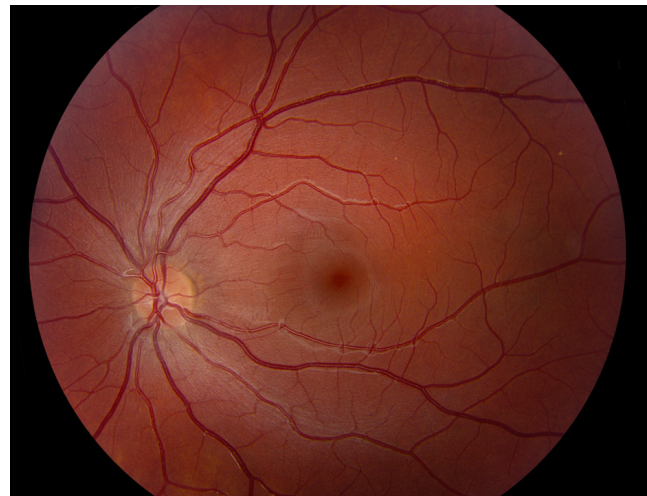
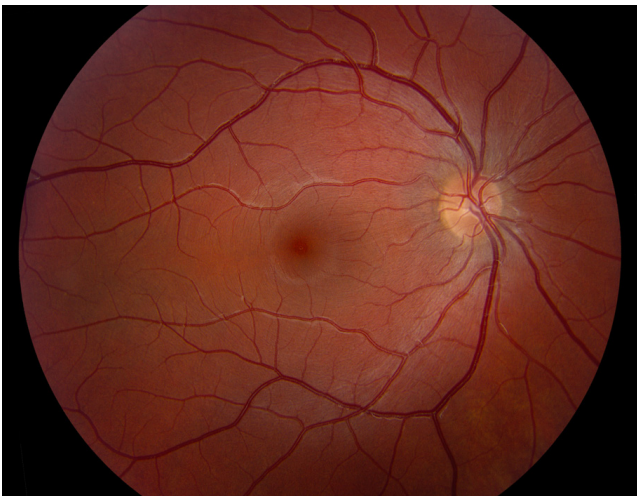
Figure 3: Excyclotorsion OD and incyclotorsion OS

a vestigial remnant of the primitive otolithic righting reflex that is tonically suppressed under normal physiologic conditions in frontal-eyed species (i.e., humans) in the interest of single binocular vision and only becomes manifest in the presence of pathology.

Pathophysiology

The vestibular system plays a major role in control of head-eye posture in the roll plane – the plane in which the head or body tilt or rotate from side to side. The vestibulo-ocular system has a primary function to maintain eye position and stabilize fixation during movements of the head or whole body in this plane. In the labyrinth of the inner ear, the semi-circular canals sense angular acceleration while the otoliths (sacculles and utricles) sense linear acceleration of the head in space. Bilateral input from these structures projects to the central vestibular system that in-turn modulates extraocular muscle tone (via the vestibulo-ocular reflex) to maintain eye position and stable foveation during changes in head position. Input from this system also plays a role in spatial perception and in postural tonus of the head and body (via the vestibulo-spinal reflex).

Under normal physiologic conditions, a change in head or body position in the roll plane initiates asymmetric sensory input from the vertical semicircular canals and utricle to the central vestibular system as a response. For example, consider a leftward body tilt in the roll plane (Figure 4). Physiologically, this would initiate a compensatory rightward ocular tilt reaction. If the body is tilted to the left, it causes the left eye to be lower in space than the right. The compensatory skew deviation will cause subsequent upward rotation of the lowermost left eye and downward rotation of the uppermost right eye to realign them. Also, when the body is tilted to the left, there is a torsional deviation of both eyes toward the left. The compensatory ocular counter-roll results in incyclotorsion of the left eye and excyclotorsion of the right eye relative to the head, so that there is no torsion of the eyes relative to space. The third component of the physiologic ocular tilt reaction is the compensatory head tilt or torticollis that will more closely realign the head with the gravitational vertical. In the example of a leftward body tilt in the roll plane, this will result in a compensatory rightward head tilt.

In a pathologic ocular tilt reaction, a unilateral lesion (or stimulation) of the utricle or its pathways will result in asymmetric vestibular input to the central nervous system (CNS) that mimics a change in body position in the roll plane as sensed by the CNS (Figure 4). This will result in two main findings: 1) an ocular tilt reaction in the absence of any true body tilt in the roll plane - this can be tonic or paroxysmal and can be a complete ocular tilt reaction or partial with only certain components becoming manifest (i.e., only a skew deviation or only synkinetic ocular torsion), and 2) a tilt in the subjective visual vertical – a perception by the patient that vertical orientation is different from what is true vertical. Patients are usually asymptomatic from this and do not perceive a tilt in their perception of the world until placed in artificial testing situations that eliminate external cues. Given that the ocular torsion is in

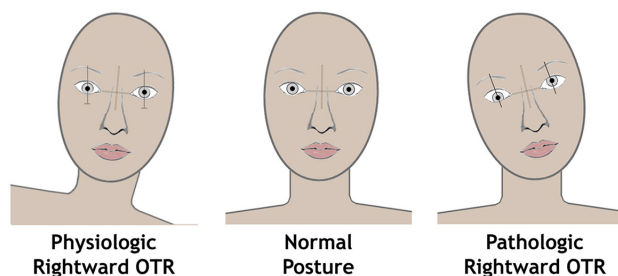


Figure 4: Left: A physiologic ocular tilt reaction (OTR) in response to a left body tilt in the roll plane – there is a compensatory right head tilt with downward rotation and excyclotorsion of the right eye and upward rotation and incyclotorsion of the left eye. Right: A pathologic OTR will have the same changes in head posture, eye position and rotation as the physiologic OTR in the absence of a change in body position in the roll plane to stimulate it. [adapted from 1]

the same direction as the patient's perception of vertical, it is thought that this may be the driving force for all components of the ocular tilt reaction – to realign the eyes and body with the subjective and CNS perception of true gravitational vertical.

Neuroanatomy and Localization

The otolithic and graviceptive pathways that mediate vestibular input and modulate the vestibulo-ocular reflex begin peripherally with sensory organs of the otoliths in the labyrinth of the inner ear and project to the ipsilateral vestibulocochlear nucleus (CN VIII) at the ponto-medullary junction via the vestibular portion of CN VIII (Figure 5). This pathway then decussates to the contralateral side at the level of the pons to ascend the brainstem in the medial longitudinal fasciculus (MLF) to the supranuclear centers for vertical-torsional eye movements in the rostral midbrain. The rostral interstitial nucleus of the medial longitudinal fasciculus (riMLF) contains the excitatory burst neurons that generate vertical and torsional saccades. The interstitial nucleus of Cajal (INC) contains the inhibitory burst neurons for vertical and torsional saccades and also acts as the neural integrator for vertical and torsional gaze holding; it likely plays a major role in producing the ocular tilt reaction. These nuclei send signals to the ocular motor nuclei (oculomotor nucleus (CN III), trochlear nucleus (CN IV) and abducens nucleus (CN VI)) that will in-turn modulate extraocular muscle tone and eye position.

Knowing the above anatomy of the pathway can help with localization of a causative lesion. For example, diminished input from the right utricle anywhere along the pathway will cause asymmetric vestibular input from the right and will result in the CNS perception that the head is being tilted to the left in the roll plane thereby producing a right ocular tilt reaction (Figure 5). The causative lesion will be ipsilateral if it is located caudal to the decussation of the otolithic pathway in the pons and will be contralateral if is located rostral to the decussation. For example, an ipsilateral ocular tilt reaction can occur with lesions of

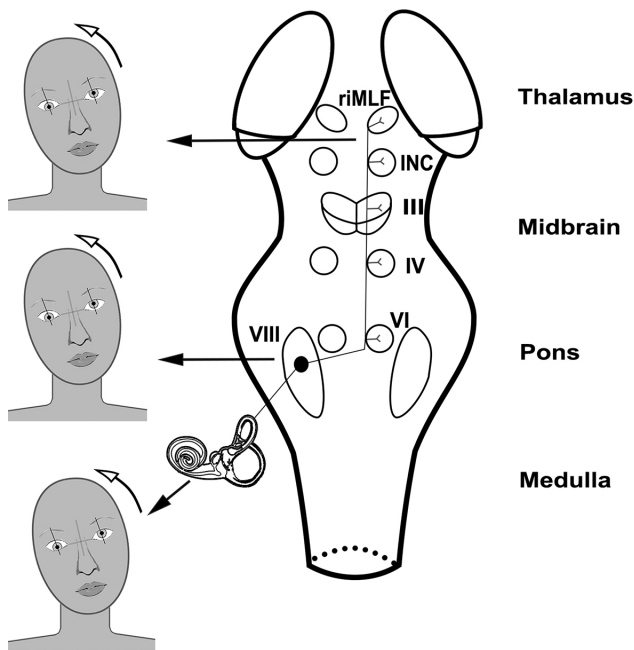


Figure 5: A schematic showing the pathway of vestibular input to the vestibulo-ocular reflex (VOR) (see Neuro-anatomy and Localization section in the article for more detailed information). Note that the schematic on the left is showing a right ocular tilt reaction resulting from an ipsilateral lesion of the pathway if it is caudal to the decussation in the pons or resulting from a contralateral lesion of the pathway if it is rostral to this decussation. [adapted from 3]

the utricle/labyrinth, vestibular nerve, or lateral medulla (i.e., in Wallenberg syndrome) that are all caudal to the decussation of the graviceptive pathway fibers in the pons; a contralateral ocular tilt reaction can occur with lesions that affect the rostral pons, MLF (i.e., in conjunction with internuclear ophthalmoplegia), the midbrain or INC (i.e., in dorsal midbrain syndrome) that are all rostral to the decussation of the graviceptive pathway fibers in the pons. There are a variety of etiologies that can affect these areas, but, as stated previously, stroke, demyelination, trauma, iatrogenic/post-surgical, and tumor are common etiologies. Furthermore, there are multiple otolithic projections to the cerebellum. Lesions of the cerebellum are also known to cause complete or partial ocular tilt reactions.

Presentation

Patients with lesions affecting the otolithic input to the ocular motor nuclei do not always present with the entire spectrum of the ocular tilt reaction (i.e., skew deviation, ocular torsion, and torticollis), but can present with variable components and severity of each. An isolated skew deviation typically presents as a fairly comitant, acquired, vertical misalignment of the eyes with a full range of extraocular movements. There is usually some degree of incyclotorsion of the hypertropic eye or excyclotorsion of the hypotropic eye (or both), which help differentiate it from CN IV palsy. These patients typically report vertical diplopia. There are variations of skew deviation including

comitant, incomitant, paroxysmal, periodic alternating, lateral alternating, and transient neonatal that will not be discussed in this article. As discussed above, synkinetic cyclorotation of the eyes and a tilt in the subjective visual vertical may be asymptomatic to patients, and can easily be missed on examination unless specifically sought.

The direction of torsion of the eyes will be the same as the direction of the ocular tilt reaction (i.e., in a right ocular tilt reaction there will be incyclotorsion of the left eye, excyclotorsion of the right eye, or both – torsion of the eyes to the right). This is also true of the head tilt (i.e., a right ocular tilt reaction will have a right head tilt). The hypotropic eye in the skew deviation will correspond to the side of the ocular tilt reaction (i.e., a hypotropic right eye will be present in a right ocular tilt reaction with a corresponding skew deviation).

Treatment and Prognosis

The majority of ocular tilt reactions are transient with spontaneous recovery in many cases. As a temporizing symptomatic measure, the vertical diplopia can be treated with prisms and is typically very amenable to this therapy given the comitant nature of the vertical deviation. Botulinum toxin injections into the extraocular muscles have also been used with some success. In patients with persistent skew deviation with vertical diplopia, prism, repeated botulinum toxin, or strabismus surgery (typically vertical rectus muscle recession) can be offered. It is important to note that these treatments will not eliminate the head tilt component of the ocular tilt reaction, as this, along with the synkinetic ocular torsion, are a compensatory mechanism to realign the head and eyes with gravitational vertical.

<p>Etiology</p> <ul style="list-style-type: none"> ◆ Damage to the vestibular pathways that mediate head-eye posture in the roll plane ◆ Localization: utricle/labyrinth, vestibular nerve, brainstem, or cerebellum ◆ Causative lesion: variable, but commonly stroke, demyelination, trauma, iatrogenic/post-surgical, hemorrhage, or tumor 	<p>Signs</p> <ul style="list-style-type: none"> ◆ Skew deviation – comitant vertical misalignment of the eyes (comitant hypertropia) ◆ Synkinetic ocular torsion – incyclotorsion of the hypertropic eye and excyclotorsion of the hypotropic eye, torsion in the same direction as the head tilt ◆ Head tilt – tilt in the direction of the ocular torsion and/or toward the hypotropic eye
<p>Symptoms</p> <ul style="list-style-type: none"> ◆ Vertical diplopia ◆ Tilt in the subjective visual vertical 	<p>Treatment</p> <ul style="list-style-type: none"> ◆ Observation ◆ Prism ◆ Botulinum toxin injection ◆ Strabismus surgery

Differential Diagnosis

- ◆ Superior oblique palsy (with or without spread of comitance)
- ◆ Inferior oblique palsy
- ◆ CN III palsy (superior division, inferior division)
- ◆ Myasthenia Gravis
- ◆ Thyroid eye disease
- ◆ Cranial dysinnervation syndromes (i.e., CFEOM)
- ◆ Chronic progressive external ophthalmoplegia (CPEO)
- ◆ Brown syndrome
- ◆ Monocular elevation deficiency (e.g., due to orbital floor fracture with inferior rectus entrapment or iatrogenic inferior rectus fibrosis following retrobulbar block)
- ◆ Ocular neuromyotonia

References

1. Brodsky, MC, Donahue, SP, Vaphiades, M, Brandt, T. Skew Deviation Revisited. *Surv Ophthalmol.* 2006; 51(2):105-128. [PMID:16500212](#)
2. Brodsky, MC. Dissociated vertical divergence: a righting reflex gone wrong. *Arch Ophthalmol.* 1999;117(9):1216-1222. [PMID:10496394](#)
3. Brandt T, Dieterich M. Vestibular syndromes in the roll plane: topographic diagnosis from brainstem to cortex. *Ann Neurol.* 1994;36(3):337-47. [PMID: 8080241](#)

Suggested Citation Format

Kirkpatrick CA, Thurtell MJ. Ocular Tilt Reaction: 53-year-old female complaining of vertical diplopia following a stroke and found to have a skew deviation, fundus torsion, and torticollis. Dec 31, 2014; Available from: <http://EyeRounds.org/cases/200-OTR.htm>

last updated: 12/31/2014

Ethambutol Toxicity and Optic Neuropathy

60-year-old female with bilateral painless central vision loss

Elizabeth M. Grace and Andrew G. Lee, MD

November 5, 2007

Chief Complaint: 60-year-old Caucasian, diabetic female with subacute awareness of bilateral blurry central vision.

History of Present Illness: The patient had been on ethambutol as part of treatment for her recent diagnosis of *Mycobacterium avium intracellulare* (see Medical History below). Months after initiation of therapy, the patient noted increasing glare with bright lights in her left eye and arranged an appointment to visit an eye doctor. However, only days before the appointment she fell down a flight of stairs, resulting in a fracture of the C2/C3 vertebrae. She was hospitalized at another facility and placed in a stabilizing "halo" for 12 weeks. A few days into her hospitalization, the patient awakened from sedation and noticed blurry central vision in both eyes, which she described as "whited out". This was not addressed at the time and her medications were continued, including ethambutol. The blurry vision worsened over the next couple months. The patient saw an optometrist two months after the fall, who documented her vision to be 20/400 in each eye. The optometrist noted no disc edema referred the patient to a retinal specialist.

One month later the patient was examined by a local retinal specialist who noted that her vision had slowly worsened to CF at 2-3 feet in both eyes. The patient also reported dyschromatopsia with difficulty distinguishing brown from green and light blue from pink. The notes from that visit document a normal slit lamp examination, no afferent pupillary defect (RAPD), and intraocular pressures of 24 and 25 mmHg in the right and left eyes, respectively. On ophthalmoscopy 2-3+ disc pallor was evident in both optic nerves, with spontaneous venous pulsations noted. An MRI of the brain and orbits was performed and showed no optic abnormality (see Figure 1). She returned to the retinal specialist who also performed a FDT 30-2 Threshold visual field test, which showed bilateral dense central scotomas (see Figure 2). The patient was then referred to the University of Iowa for further evaluation within two weeks.

Past Ocular History: Refractive error (corrected with trifocals). No ocular history of eye disease, surgery or trauma.

Medical History: The patient had a known history of pulmonary *Mycobacterium avium intracellulare* (MAI) ten months prior to presentation. She was initially treated with azithromycin, rifampin, and ethambutol. The rifampin was discontinued after the patient developed a rash during the first months of therapy. The ethambutol was started at 25 mg/kg/day for 2 months and then decreased to a maintenance dose of 15 mg/kg/day (800 mg daily). At the time she was seen at UIHC her ethambutol dose was 14.4 mg/kg/day (800 mg daily).

In addition, the patient had auto-immune Addison's disease diagnosed 3 years ago, an 11-year history of diabetes mellitus, and a history of hypothyroidism. There were no other health issues. Recent PPD and HIV testing was negative.

Medications: Synthroid, Fludrocortisone, Hydrocortisone, Actonel, Lantus, Humalog, Ethambutol, Azithromycin, and PRN medications (Protonix, Tylenol, multivitamin, calcium)

Allergies: Codeine and sulfa medications. (Prednisone has caused erosive esophagitis as a side-effect in the past).

Family History: Diabetes Mellitus in mother and brother. Denies any history of glaucoma.

Social History: Denies smoking cigarettes or drinking alcohol.

Review of Systems: Unremarkable. Specifically negative for renal or liver disease.

Ocular Examination

- ◆ **General:** Pleasant female wearing a soft neck collar and visually assisted by her daughter
- ◆ **Visual Acuity:** Right eye (OD)--Count fingers at 2 feet; Left eye (OS)--Count fingers at 1 foot
- ◆ **Ocular motility:** Full, both eyes (OU). No nystagmus
- ◆ **Intraocular pressure (IOP):** 32 mmHg OD and OS
 - drops of brimonidine and dorzolamide/timolol (Cosopt) were given immediately in each eye. Repeat IOP was 21 OD and 19 OS.
 - Gonioscopy: Open bilaterally (Spaeth grading 25-30R with 2+ pigment). No peripheral anterior synechiae (PAS).
- ◆ **Pupils:** Reactive to light in each eye from 6mm in the dark to 4mm in the light. No relative afferent pupillary defect (RAPD).
- ◆ **Slit lamp examination (OU)**
 - Quiet anterior chambers with no cell or flare, open angles, mild cataract, and no pseudoexfoliation (PXF), no pigment dispersion syndrome (PDS).
- ◆ **Goldmann visual fields (GVF):** Dense central scotomas with relatively full peripheral fields bilaterally (see Figure 3).
- ◆ **Dilated fundus examination (DFE), OU**
 - Normal, dry macula with no bull's eye maculopathy. Normal vessels and periphery in each eye. Cup-to-disc ratio was 0.5 in each eye, with a sloping to the rim, and bilateral mild temporal pallor (see Figure 4).

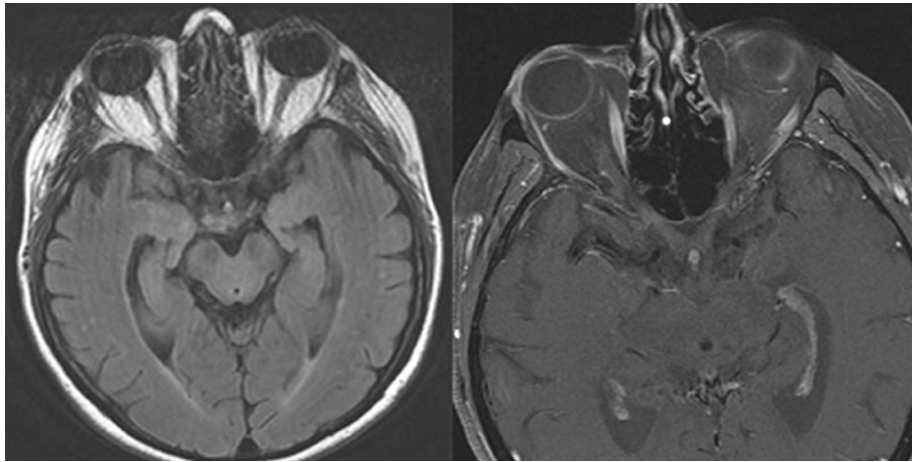


Figure 1: MRI of the brain and orbits - flare and T1 images demonstrate extensive non-enhancing white matter disease consistent with small vessel ischemic changes. However, there were no abnormalities of the orbit and no optic nerve enhancement.

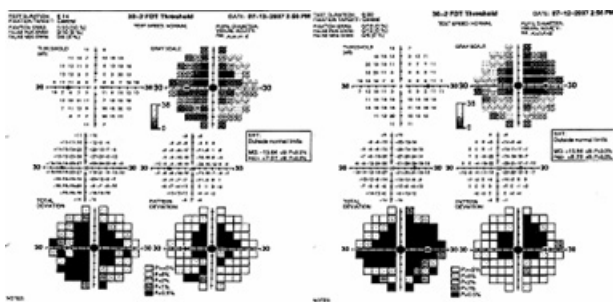


Figure 2: FDT 30-2 Threshold Test, demonstrating bilateral dense central scotomas.

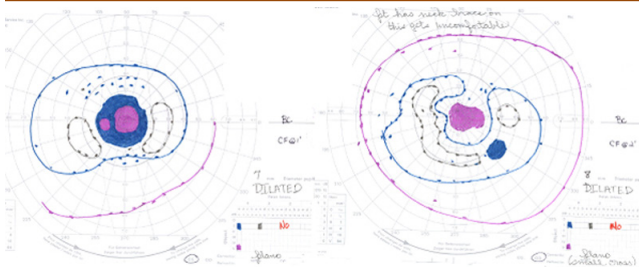


Figure 3: Goldmann Visual Fields indicate dense central scotomas with relatively full peripheral field, OD and OS.

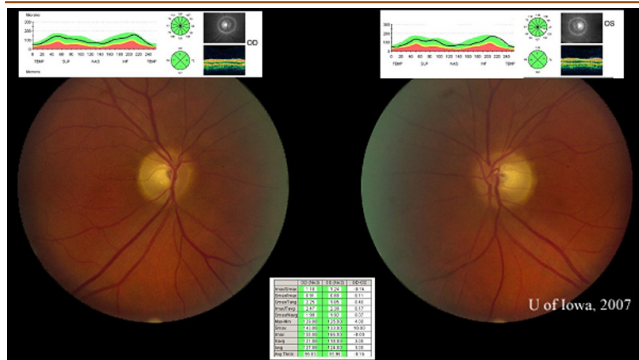


Figure 4: Fundus photos, showing a cup-to-disc ratio of 0.5 in each eye, a sloping rim, and mild temporal pallor. Superimposed OCT shows an average retinal nerve fiber layer thickness in both eyes, with no focal thinning.

Course

In summary, this is a 60-year-old female with a history of mycobacterium avium intracellulare (MAI) treated with ethambutol for 2 months at 25 mg/kg/day and then 8 months at 15 mg/kg/day, now with subacute bilateral central vision loss, with associated bilateral temporal optic disc pallor. OCT was obtained to investigate possible visual recovery via the nerve fiber layer thickness. A normal thickness of the retinal nerve fiber layer was seen in both eyes with no areas of focal thinning, average 95.83 OD and 95.99 OS (see Figure 4). The patient stopped the ethambutol immediately upon examination at the University of Iowa and her infectious disease physician was contacted about the toxic optic neuropathy. On follow-up with her infectious disease physician, the azithromycin treatment was continued and ciprofloxacin was added to the anti-MAI regimen. At her 3 week follow-up, the patient reported her vision slowly "lightening" with less dark shadows. She continues to have poor central vision, and difficulty distinguishing colors. On exam, color plate testing was poor, with 0/14 plates correct in each eye. Her visual acuity had improved to 20/400 OD and CF at 3 feet OS. Repeat Goldmann visual fields were performed at 3 and 6 weeks, showing some visual improvement of the dense central scotomas (see Figure 5).

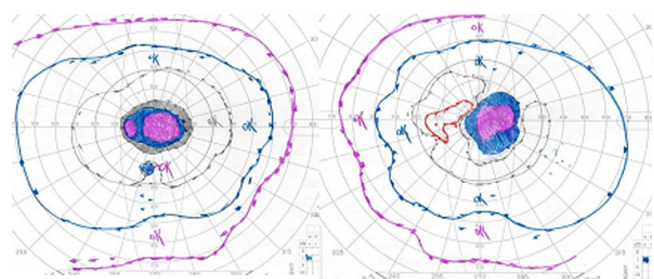


Figure 5: Goldmann Visual Fields 6 weeks after discontinuing ethambutol, demonstrating improving dense bilateral central scotomas.

The patient was evaluated in our Glaucoma Clinic for the high IOP measured previously. The patient used the latanoprost drops daily for 3 weeks and her pressure measured 28 in both eyes. Gonioscopy showed D35R, 1+ pigment in both eyes, and no synechiae. As no secondary causes of glaucoma were found, she likely has steroid induced ocular hypertension. It is believed the pressures were not contributing to her bilateral central visual field loss. Because of the optic neuropathy, a target IOP ≤ 20 was made by adding Timolol OD, Cosopt OS, and continuing the latanoprost OU. The patient returned for follow-up 3 weeks later. She had responded well to this medical therapy; her pressures were 16 in each eye. Also, a multi-focal electroretinogram (MERG) was obtained to ascertain whether there was a combination of retinal and optic nerve damage, as previously reported in cases of ethambutol-related optic neuropathies (Kardon et al., 2006). Her MERG showed a paracentral depression, especially superiorly in the first order waveforms of both eyes, thus demonstrating evidence of retinal involvement in addition to the optic neuropathy (see Figure 6).

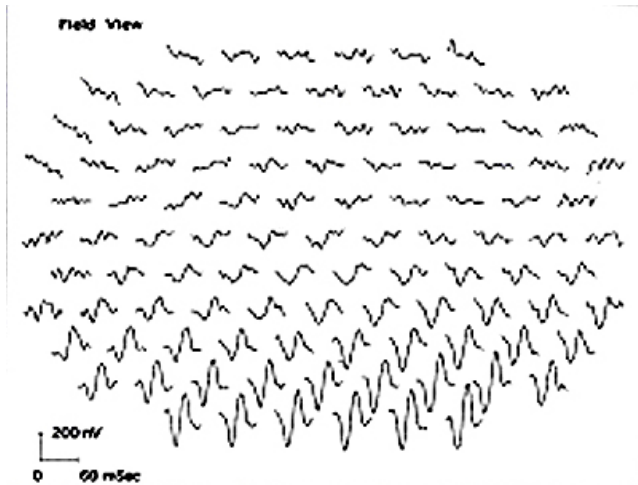


Figure 6: Multifocal electroretinogram (MERG) 6 weeks after discontinuing ethambutol, showing paracentral depression of first order waveforms especially superiorly (right eye shown).

Discussion

Toxic and metabolic optic neuropathies include the broad category of visual loss from medications, environmental toxins, and nutritional deficiencies. Recognition of these conditions is important because they are potentially reversible, particularly when caught early. Because the onset of these optic neuropathies is insidiously slow, most patients will already be symptomatic for weeks or months before being seen by a medical professional. Thus evaluation is recommended within 2 weeks of presentation, except for acute methanol toxicity, which is a medical and visual emergency (Levin et al., 2005).

Toxic Optic Neuropathy Symptoms

- ◆ Subacute, painless, bilateral central vision loss
- ◆ Color desaturation
- ◆ May be neurologic symptoms of "stocking and glove" peripheral neuropathy and cognitive decline in patients with vitamin B12 deficiencies

Toxic Optic Neuropathy Signs

- ◆ Bilateral visual acuity affected because the papillomacular bundle is preferentially affected, severity is variable
- ◆ Visual fields demonstrate bilateral central or cecentral scotomas, rarely bitemporal scotomas can be seen with ethambutol toxicity
- ◆ Pupils may react sluggishly, however there should be no RAPD because of symmetrical visual loss
- ◆ Optic discs may look normal initially or slight hyperemic, (similar to Leber's HON) over time temporal pallor develops

Differential Diagnoses of painless bilateral central vision loss with mild temporal disc pallor in an adult

- ◆ Toxic optic neuropathy (medications, environmental)
- ◆ Nutritional optic neuropathy
- ◆ Inflammatory optic neuropathy
- ◆ Leber's hereditary optic neuropathy (LHON)
- ◆ Compressive/infiltrative process

Table 1. Toxins, Medications, Deficiencies Associated with Optic Neuropathy

TOXINS	MEDICATIONS	VITAMIN DEFICIENCIES
<ul style="list-style-type: none"> ◆ Arsenics ◆ Carbon disulfide/tetrachloride ◆ Ethyl alcohol ◆ Ethylene glycol ◆ Methanol ◆ Thallium ◆ Tobacco 	<ul style="list-style-type: none"> ◆ Amiodarone ◆ Cyclosporine ◆ Chlorambucil ◆ Chloramphenicol ◆ Cisplatin ◆ Disulfiram ◆ Ethambutol ◆ Halogenated hydroxyquinolones ◆ Isoniazid ◆ Penicillamine ◆ Sildenafil ◆ Streptomycin 	<ul style="list-style-type: none"> ◆ B12 ◆ B1 (Thiamin deficiency = beriberi) ◆ B6 ◆ Nicotinic Acid (Niacin deficiency = pellagra)

There are numerous medications and toxins as well as nutritional deficiencies that can cause optic neuropathies, stressing the importance of taking a proper history and collecting an accurate medication list as well. Table 1 is an abbreviated list of substances and vitamin deficiencies associated with optic neuropathy.

Depending on the patient's presentation some ancillary tests may need to be performed. If suspicious for a nutritional optic neuropathy a CBC, serum B12, and RBC folate levels (provides a general index of nutritional status better than an isolated folate level) should be obtained, along with consideration for hematology consult if there is no underlying etiology for the vitamin deficiency. If concerned about alternate retinal cause of visual loss, a multifocal electroretinogram (MERG) and fluorescein angiogram may be appropriate to order. Lastly, an MRI may be necessary if the presentation is atypical (i.e. bitemporal visual field depression). The MRI should be ordered with contrast and orbital view with fat suppression to look for any demyelinating lesions and exclude compressive lesions (Levin et al., 2005).

Mycobacterium avium complex (MAC) encompasses two closely related organisms, *M. avium* and *M. intracellulare*. In patients with an intact immune system the major syndrome is pulmonary disease, whereas disseminated disease and cervical lymphadenitis is more commonly seen with advanced HIV infection. The clinical presentation of pulmonary MAC disease is quite non-specific and looks similar to other mycobacterial infections and COPD. Diagnosis is based on a complicated clinical case definition of chest scans, histopathologic specimen, positive sputum cultures, and positive bronchial wash cultures set forth by the American Thoracic Society. Successful treatment is based on multi-drug therapy similar to tuberculosis. The preferred regimens for pulmonary MAC is three drug therapy including a macrolide, either clarithromycin or azithromycin, ethambutol, and rifabutin. Once the sputum cultures are negative most experts treat for at least another 12 months, with most patient with pulmonary MAC receiving a total of 18 to 24 months of therapy (Gordin et al., 2005).

Ethambutol is a bacteriostatic antimicrobial medication used as a first line defense against tuberculosis (TB) and MAC. Ethambutol's therapeutic action is hypothesized to act as a chelating agent that disrupts a metal containing enzyme system in the mycobacteria. Inside the human mitochondria, the chelation of copper or zinc containing enzymes has been suggested as a optic neuropathy mechanism.

Since its beginning uses as a treatment for TB, ethambutol's potential optic neuropathy toxicity was well recognized. Early animal studies showed that ethambutol caused lesions in the optic nerves and the optic chiasm, causing a diminished visual acuity in an often normal fundus exam (Miller et al., 2005).

The regimens of ethambutol doses vary by disease. The TB regimens can begin at either 50 mg/kg/day (maximum 4 grams) for 2 weeks or 25-30 mg/kg/day (maximum 2

grams) for 3 weeks, and then patients are maintained at 15-20 mg/kg/day (max 2 grams). For MAC regimens the maintenance dose is 15 mg/kg/day (maximum 2.5 grams). However depending on the species of mycobacteria a patient may be treated with a loading dose of 25 mg/kg/day for the first two months of therapy (Mandell et al., 2005; Micromedex 2007).

Ethambutol optic toxicity is known to be dose related. Leibold first described the dose dependent nature of ethambutol's toxicity in the 1960s. He reported 18% of patients receiving high doses of ethambutol, > 35 mg/kg/day had vision loss, whereas only 3.3% of low dose therapy, < 30 mg/kg/day had vision loss (1966). Citron further characterized the ethambutol toxicities at 6% of patients receiving doses of 25 mg/kg/day and only 1% of patients on doses of 15 mg/kg/day had vision loss (1969). Because ethambutol is cleared mainly by the kidneys, doses need to be adjusted accordingly in any patient with renal insufficiency, based on their GFR (Micromedex 2007). If you recall, our patient did have a history of diabetes, however upon review of her chart she had no renal insufficiency based on normal creatinine values.

Once ethambutol toxicity is recognized and the medication is stopped many patients recover vision slowly over several months. Although medical literature suggests that the toxic effects of ethambutol are completely reversible with discontinuation, there have been numerous case reports of non-reversible vision loss after ethambutol use. Kumar described a series of 7 consecutive patients with severe vision loss caused by ethambutol at 25 mg/kg/day. After an average follow up of 8.3 months, only 3 of the 7 patients achieved visual recovery better than 20/200, with none of the patients having any predisposing risk factors to contribute to a poor prognosis (1993). Other investigators have also documented poor visual acuity recovery despite discontinuation of ethambutol at the onset of visual symptoms (Melamud et al., 2003).

When starting ethambutol, every patient should be warned about the potential visual toxicity. If patients have any symptoms of decreased acuity, reduced color discrimination, or visual field loss, the medication should be discontinued immediately and the prescribing physician notified. There are differing recommendations for monitoring the ethambutol related optic toxicity. The manufacturer recommends patients receiving ethambutol should have visual acuity testing before initiation of therapy and then periodically. Also the manufacturer recommends monthly eye examinations in patients receiving doses of 25 mg/kg/day or greater (Micromedex 2007). Recommendations for the routine visual acuity assessment prior to starting ethambutol have also been made by the Joint Tuberculosis Committee of the American and British Thoracic Societies (Thorax 1998; Bass et al., 1994). However, the committee no longer recommends visual acuity assessment during routine follow-up. Assessment of red-green color vision prior to treatment is also recommended by the American Thoracic Society. The TB and Chest Service of the Department of Health of Hong Kong also published guidelines recommending baseline vision tests for both visual acuity

(Snellen chart) and red-green color vision (Ishihara chart), however these tests do not require an ophthalmologist's expertise (Hong Kong Annual Report 2002).

In summary, we present a classic case of ethambutol related toxic optic neuropathy. Our patient presented with painless, progressive, bilateral central vision loss and blue-yellow dyschromatopsia. The patient's visual acuity was count fingers at 2 feet in both eyes and her visual fields demonstrated bilateral central scotomas. Ophthalmoscopy demonstrated a mild temporal pallor of both optic discs, however her OCT was promising with a normal average nerve fiber thickness seen in both eyes. Upon presentation she was taking 14.4 mg/kg/day of ethambutol. According to previous reports only 1% of patients on this dose would experience toxic optic neuropathy. She appropriately discontinued the ethambutol and continued monitoring of her visual acuity recovery and her MAC infection. This case is being presented to remind practitioners of the importance of knowing a patient's past medical history and medication list when evaluating vision loss. Lastly, the importance of proper counseling of the visual side effects

when starting a medication like ethambutol is imperative. The need to discontinue the medication immediately at the onset of any visual disturbances and follow-up with the treating physician should be reinforced with every patient taking these antibiotics.

Diagnosis: Ethambutol-Related Toxic Optic Neuropathy

Differential Diagnoses of painless bilateral central vision loss with mild temporal disc pallor in an adult

- ◆ Toxic optic neuropathy (medications, environmental)
- ◆ Nutritional optic neuropathy
- ◆ Inflammatory optic neuropathy
- ◆ Leber hereditary optic neuropathy (LHON)
- ◆ Compressive/infiltrative process

<p>EPIDEMIOLOGY</p> <ul style="list-style-type: none"> ◆ See Table 1. Toxins, Medications, and Vitamin deficiencies above 	<p>SIGNS</p> <ul style="list-style-type: none"> ◆ Bilateral visual acuity affected because the papillomacular bundle is preferentially affected, severity is variable ◆ Visual fields demonstrate bilateral central or cecocentral scotomas, rarely bitemporal scotomas can be seen with ethambutol toxicity ◆ Pupils may react sluggishly, however there should be no RAPD because of symmetrical visual loss ◆ Optic discs may look normal initially or slight hyperemic, (similar to Leber's hereditary optic neuropathy) <ul style="list-style-type: none"> ○ over time temporal pallor develops
<p>SYMPTOMS</p> <ul style="list-style-type: none"> ◆ Often asymptomatic early in course; symptoms may include <ul style="list-style-type: none"> ○ Subacute, painless, bilateral central vision loss ○ Color desaturation ○ May be neurologic symptoms of "stocking and glove" peripheral neuropathy and cognitive decline in patients with vitamin B12 deficiencies 	<p>TREATMENT</p> <ul style="list-style-type: none"> ◆ In most cases of medication-related optic neuropathy, immediate cessation of the offending agent is the only treatment option ◆ Vitamin replacement is essential in cases of optic neuropathy related to deficiency ◆ Specific anti-toxins may be indicated in cases of optic neuropathy related to environmental toxins

References

1. Kardon RH, Morrisey MC, Lee AG. Abnormal multifocal electroretinogram (mfERG) in ethambutol toxicity. *Semin Ophthalmol* 2006;21(4):215-222. [PubMed.gov/17182409](http://pubmed.gov/17182409). DOI: 10.1080/08820530600987454
2. Levin L, Arnold A. Chapter 25: Toxic and Metabolic Optic Neuropathies. *Neuro-ophthalmology: The Practical Guide*. New York: Thieme Medical Publishers; 2005.
3. Gordin FM, Horsburgh CR. Chapter 250: Mycobacterium avium Complex. In: Mandell GL, Bennet JE, Dolin R, editors. *Principles and Practice of Infectious Diseases*, 6th Edition. London: Churchill Livingstone; 2005.
4. Miller NR. Toxic and Deficiency Optic Neuropathies. 2005;. In: Bioussé V, editor. *Walsh and Hoyt's Clinical Neuro-Ophthalmology*. 6th Edition.: Lippincott Williams & Wilkins; 2005; p. 455-456.
5. Leibold JE. The ocular toxicity of ethambutol and its relation to dose. *Ann N Y Acad Sci* 1966;135(2):904-909. [PubMed.gov/5220245](http://pubmed.gov/5220245)

6. Citron KM. Ethambutol: a review with special reference to ocular toxicity. *Tubercle* 1969;50:Suppl:32-36. [PubMed.gov/4918612](http://pubmed.gov/4918612)
7. Kumar A, Sandramouli S, Verma L, Tewari HK, Khosla PK. Ocular ethambutol toxicity: is it reversible? *J Clin Neuroophthalmol* 1993;13(1):15-17. [PubMed.gov/8501256](http://pubmed.gov/8501256)
8. Melamud A, Kosmorsky GS, Lee MS. Ocular ethambutol toxicity. *Mayo Clin Proc* 2003;78(11):1409-1411. [PubMed.gov/14601701](http://pubmed.gov/14601701). DOI: 10.4065/78.11.1409
9. Chemotherapy and management of tuberculosis in the United Kingdom: recommendations 1998. Joint Tuberculosis Committee of the British Thoracic Society. *Thorax* 1998;53(7):536-548. [PubMed.gov/9797751](http://pubmed.gov/9797751)
10. Bass JB, Jr., Farer LS, Hopewell PC, O'Brien R, Jacobs RF, Ruben F, Snider DE, Jr., Thornton G. Treatment of tuberculosis and tuberculosis infection in adults and children. American Thoracic Society and The Centers for Disease Control and Prevention. *Am J Respir Crit Care Med* 1994;149(5):1359-1374. [PubMed.gov/8173779](http://pubmed.gov/8173779). DOI: 10.1164/ajrccm.149.5.8173779
11. Tuberculosis & Chest Service of the Department of Health of the Government of the Hong Kong SAR. Preventive measures against drug-induced ocular toxicity during anti-tuberculosis treatment (general recommendations) [TB&CS/DH0208]. 2002. [Last rev. on 2002; accessed on 05 Nov. 2007] Available at www.info.gov.hk/tb_chest/doc/Prevent_ocutox_TBRx.pdf.
12. National Library of Medicine, National Institutes of Health. Ethambutol. : TOXNET Toxicology Data Network, 2008. [Last rev. on 14 Apr 2008; accessed access verified 2 March 2018] National Library of Medicine, National Institutes of Health. Ethambutol. TOXNET Toxicology Data Network. Available online at National Library of Medicine. [Toxnet.nlm.nih.gov](http://toxnet.nlm.nih.gov). [bit.ly/2tbVqgk].

Citing this article

Grace EM, Lee AG: Ocular Sarcoidosis: Ethambutol Toxicity and Optic Neuropathy: 60-year-old female with bilateral painless central vision loss. *EyeRounds.org*. November 5, 2007; Available from: www.EyeRounds.org/cases/75-Ethambutol-Toxicity-Optic-Neuropathy.htm.

last updated: 11-05-2007

Optic Neuritis

Pavlina S. Kemp, MD, Kimberly M. Wings, MD, Michael Wall, MD

September 30, 2012

Chief complaint: 40-year-old female with cloudy vision of the right eye

History of Present Illness: The patient is a 40-year-old female who was well until two weeks prior to her clinic visit when she noticed visual loss in her right eye. It was accompanied by pain with eye movements and a dull retro-orbital ache. She also noted decreased perception of color and contrast. She denied weakness, numbness, tingling, double vision or headache. She recalled one episode of similarly blurred vision in the left eye one year ago, which resolved spontaneously.

Past Ocular History

- ◆ Recurrent corneal abrasion in the right eye
- ◆ Prism in glasses since age 8

Past Medical History

- ◆ Migraine headaches
- ◆ No history of hypertension, hyperlipidemia, or diabetes

Medications

- ◆ Fexofenadine-pseudoephedrine (Allegra-D®)
- ◆ Multivitamin

Allergies

- ◆ Azithromycin - stomach pain
- ◆ Betamethasone - hives
- ◆ Sulfadoxine - headaches

Family History

- ◆ Sister with multiple sclerosis, diagnosed 10 years ago, with a history of optic neuritis.
- ◆ Mother with amblyopia in right eye (OD), migraine
- ◆ Maternal and paternal grandfathers with glaucoma

Social History

- ◆ 1-2 alcoholic beverages per week
- ◆ No history of smoking

Review of Systems: As above, otherwise negative.

Ocular Exam

Best-Corrected Visual Acuity

- ◆ Right eye (OD): 20/20
- ◆ Left eye (OS): 20/20

Pupils

- ◆ OD: 3 mm (dark) to 2 mm (light), slow, 0.3-0.6 log unit relative afferent pupillary defect
- ◆ OS: 3 mm (dark) to 2 mm (light), brisk, no relative afferent pupillary defect

Intraocular pressure (applanation): OD: 15 mmHg, OS: 15 mmHg

Extraocular motility: Full OD and OS, pain with adduction and abduction OD, 4 prism diopters of comitant esophoria

Confrontation visual fields

- ◆ Full to finger confrontation OD and OS
- ◆ Red target testing revealed red desaturation OD temporally and centrally, normal OS

External: Normal both eyes (OU)

Slit Lamp Exam

- ◆ Lids/lashes: Normal OU
- ◆ Conjunctiva/sclera: Normal OU
- ◆ Cornea: Clear OU
- ◆ Anterior chamber: Deep and quiet OU
- ◆ Iris: Normal architecture OU
- ◆ Lens: Clear OU
- ◆ Vitreous: Normal OU

Dilated Fundus Exam (shown in Figure 1)

- ◆ Optic nerves: No pallor or edema OU, small cup:disc OD>OS
- ◆ Macula: Normal OU
- ◆ Vessels: Normal course and caliber OU
- ◆ Periphery: Normal OU

Goldmann perimetry (Figure 2)

- ◆ OD: Inconsistent answers and mild constriction of I2e and I1e isopters
- ◆ OS: Full

Spectral-domain optical coherence tomography (SD-OCT) of the optic nerve heads (Figure 3)

- ◆ No thinning of retinal nerve fiber layer OU. Smaller cup-to-disc ratio OD than OS

Optical coherence tomography of ganglion cell + inner plexiform layer (Figure 4)

- ◆ OD: Normal ganglion cell layer thickness
- ◆ OS: Reduced ganglion cell layer thickness inferiorly

Critical flicker fusion

- ◆ OD: 17.9 (standard deviation 0.8) (depressed)
- ◆ OS: 24.2 (standard deviation 1.6)
- ◆ Magnetic resonance imaging (MRI) of the orbits and brain with and without contrast show contrast enhancement of the right optic nerve, and multiple ovoid periventricular white matter lesions, seen in Figures 5 and 6.

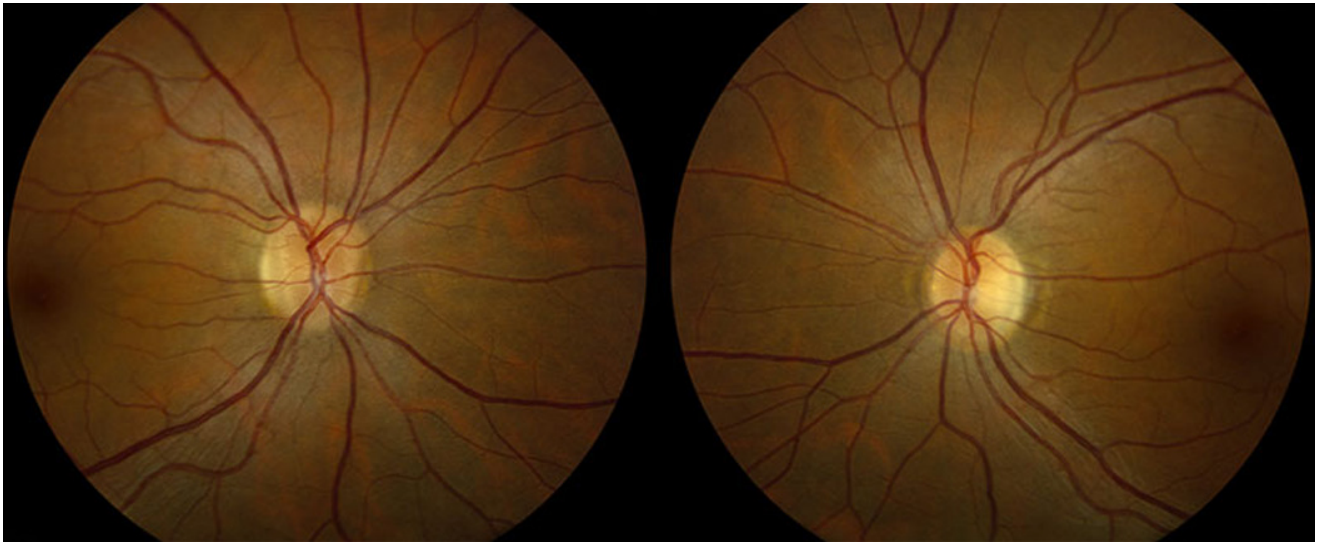


Figure 1: Color fundus photographs of the right and left eye show no optic disc edema. There is temporal pallor of the optic disc in the left eye.

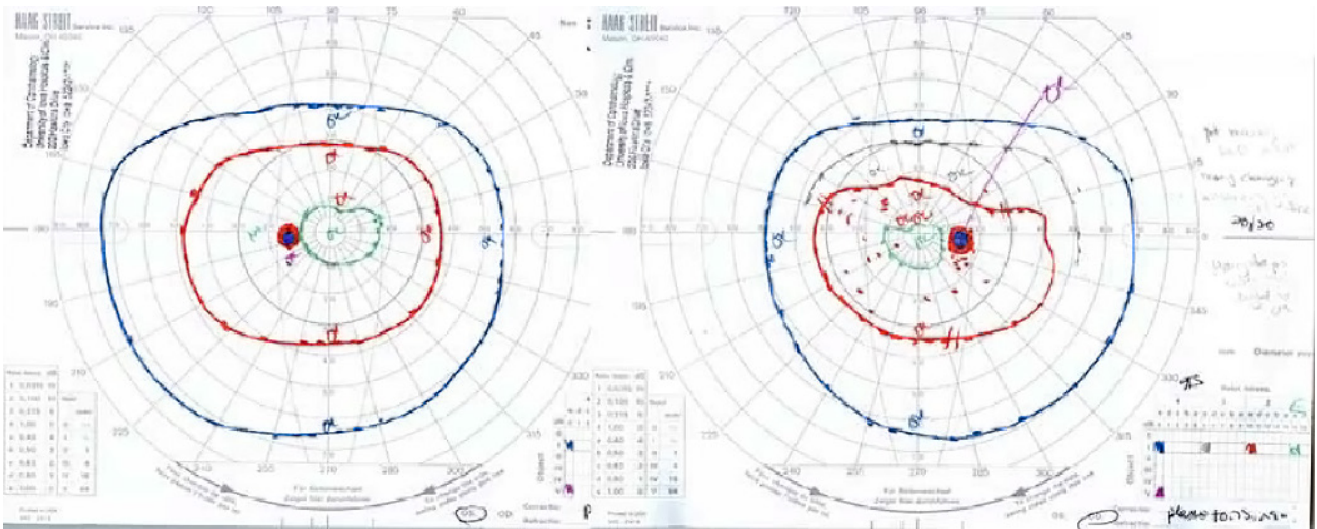


Figure 2: Goldmann perimetry OS (left) and OD (right).

Diagnosis: Optic neuritis of the right eye with a prior bout of optic neuritis in the left eye

Discussion

Optic neuritis is defined as inflammation of the optic nerve, which can be anterior, in which optic disc swelling is visible, or more commonly retrobulbar, in which inflammation is posterior to the globe without optic disc edema. The etiology of optic neuritis can be secondary to demyelination, vasculitis (such as secondary to systemic lupus erythematosus), infection (such as syphilis or post-viral optic neuritis, most commonly seen in children) or a granulomatous process (such as Wegener's granulomatosis or sarcoidosis). Demyelination may be isolated or associated with multiple sclerosis (MS) (Thurtell, 2012).

Presenting symptoms include subacute vision loss over a few days to 2 weeks, with recovery typically beginning by one month with the majority of recovery completed

by two months. Pain with eye movement is seen in 92% of patients, and often precedes visual loss. Decreased color vision and color desaturation with loss of contrast is common, and is often more severe than Snellen acuity loss. Patients may describe phosphenes (light flashes with eye movement) or photisms (light induced by noise, smell, taste or touch) (BCSC Section 5 - Chapter 4, 2011).

Exam findings of optic neuritis include decreased visual acuity ranging from 20/20 to no light perception. A relative afferent pupillary defect is usually present unless optic neuropathy is bilateral. Optic disc edema is seen in about one-third of adult patients, although subtle disc edema can be seen in a higher percentage of patients if OCT is used. Visual field testing can show various nerve fiber bundle defects. In a study of 448 patients with acute optic neuritis, 48.2% of affected eyes had diffuse visual field loss, 20.1% of eyes had altitudinal or other nerve fiber bundle-type defects, and 8.3% had central or ecocentral scotomas (Keltner, 1993). Please refer to Keltner et al. for exemplary

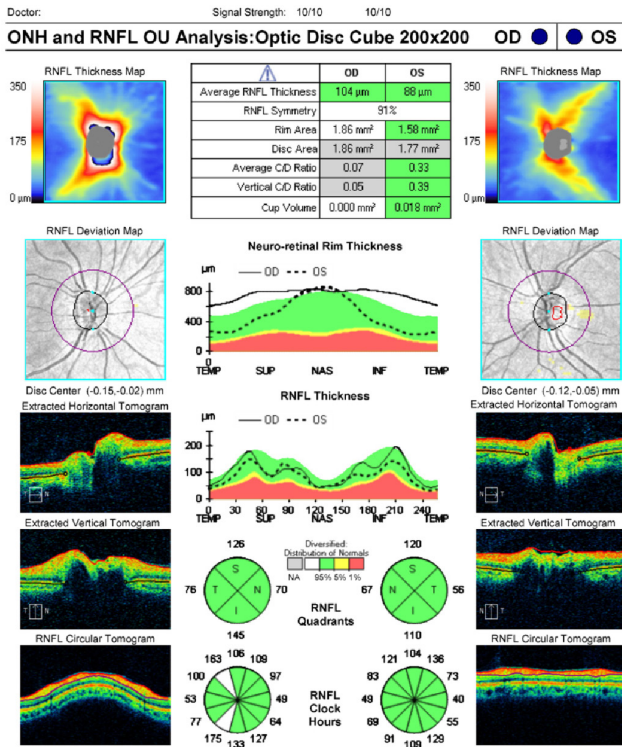


Figure 3: SD-OCT of optic nerve heads.

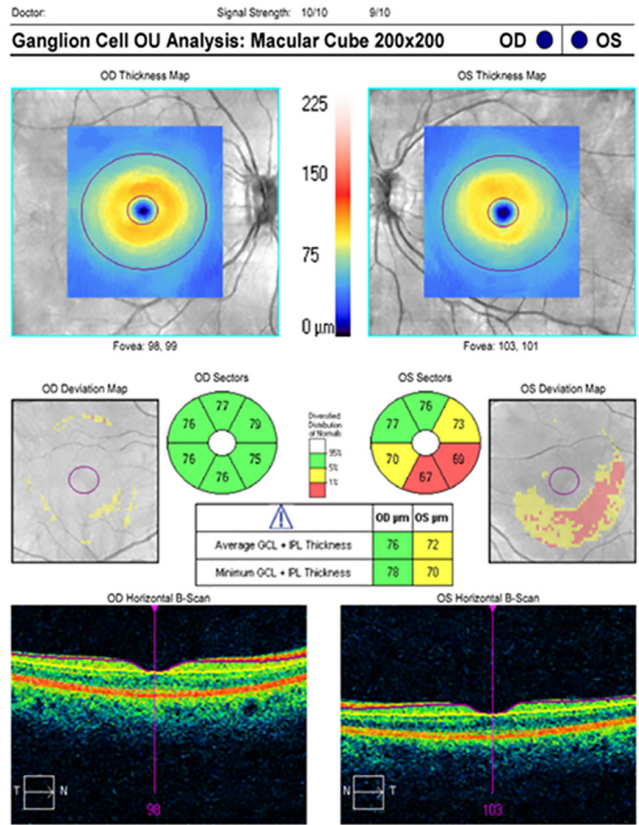


Figure 4: SD-OCT of ganglion cell + inner plexiform layer.

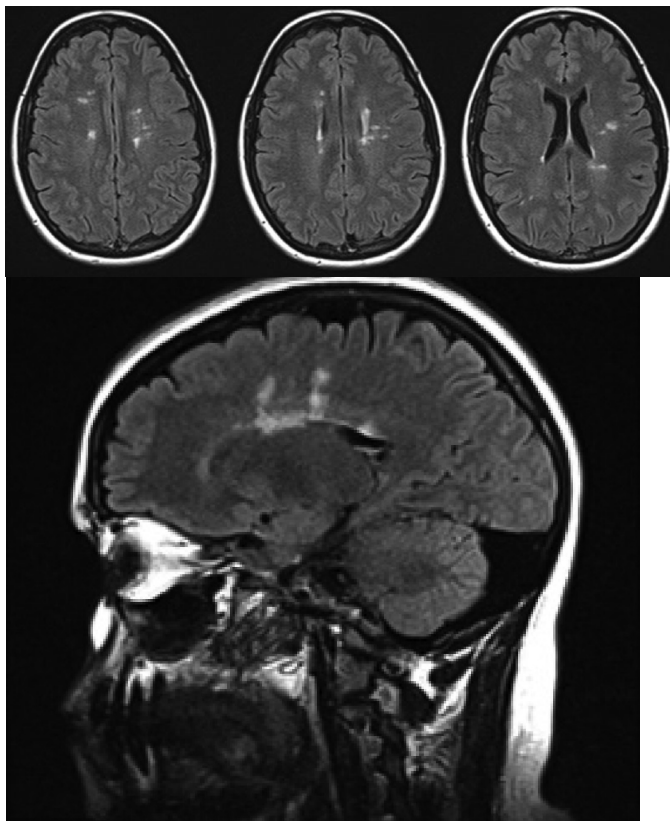


Figure 5: Axial (A) and sagittal (B) T2 - FLAIR sequence showing multiple "Dawson's Fingers": vertically oriented ovoid periventricular white matter lesions.

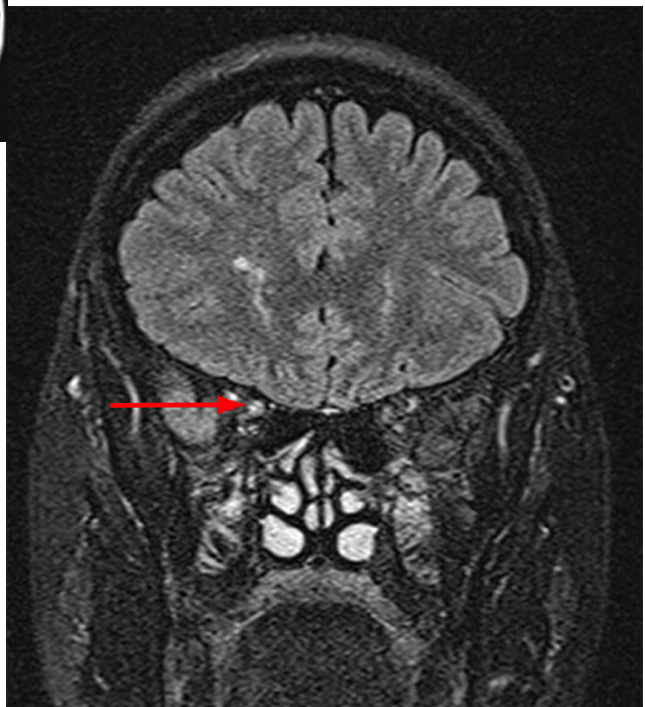


Figure 6: Coronal T2 - FLAIR sequence showing enhancement of the right optic nerve (arrow).

images of the visual field defects typically seen with acute optic neuritis. Of note, our patient's case is typical in all clinical respects except for her visual field defect; most patients have one of the patterns of visual loss listed above, whereas our patient's visual field had a mild relative paracentral defect.

Several eponymic signs and symptoms of demyelinating disease can be sought. Pulfrich's phenomenon represents an altered perception of motion; to a patient with unilateral optic neuritis, a swinging pendulum appears to trace an elliptical pathway rather than its true single-plane oscillation. This is due to a conduction delay in one optic nerve, causing a slowing in neuronal transmission compared with the other optic nerve (BCSC Section 5 - Chapter 6, 2011). Uhthoff's phenomenon describes worsening of vision or other demyelinating disease symptoms with physical activity or elevation in body temperature. L'Hermitte's sign describes an electrical "shock-like sensation" that runs down the spine and into the upper extremities with forward flexion of the neck (BCSC Section 5 - Chapter 14, 2011).

Optic neuritis should follow its typical course or other causes should be sought. Typically, optic neuritis worsens over days to several weeks, stabilizes and gradually improves over one to two months. If there is no substantial spontaneous improvement by one month, other causes should be considered. Further workup may include CSF studies of cell count, glucose, protein, VDRL and electrophoresis evaluating for oligoclonal bands. VDRL and FTA-ABS for syphilis, Lyme disease antibody titers, chest X-ray and serum angiotensin-converting enzyme levels for sarcoidosis and ANA for systemic lupus erythematosus and vasculitic disorders should be considered (BCSC Section 5 - Chapter 4, 2011).

MRI of the brain is performed when optic neuritis is suspected. If there are one or more white matter lesions typical for multiple sclerosis, a course of IV methylprednisolone followed by an oral tapering dosage is considered (see below). When ordering brain MRI scans, the FLAIR (fluid-attenuated inversion recovery) sequence should be obtained, and gadolinium contrast should be used to look for active lesions in which the blood-brain barrier has broken down. Fat suppression should be used for sequences looking at the orbits. Demyelinating lesions in the brain are seen as periventricular, ovoid hyper-intensities in the white matter, which are best seen on T2-weighted or FLAIR images (Thurtell, 2012). There is no role for CT scanning in optic neuritis. If there is uncertainty about the diagnosis of optic neuritis, MRI of the orbits with fat suppression and gadolinium are performed.

According to the Optic Neuritis Treatment Trial (Optic Neuritis Study Group, 2008), patients with no brain lesions on MRI had a 25% risk of progression to multiple sclerosis within 15 years, as compared to a 72% risk of progression in the same time period in patients with at least one demyelinating lesion seen on MRI. In this study, patients with normal MRIs who had not developed multiple sclerosis by year 10 had only a 2% risk of developing the disease by year 15. The highest rate of conversion to multiple sclerosis occurred in the first 5 years. Patients had a lower risk of

developing future multiple sclerosis if they had a normal baseline MRI, were male, had optic disc swelling, no pain, or if exam showed no light perception vision, peripapillary hemorrhages or retinal exudates, as these are atypical features of optic neuritis. Recovery of vision was not found to be related to the presence of pain, optic disc swelling or severity of visual loss. At 10 years, recovery of visual acuity to $\geq 20/20$ and $=20/40$ occurred in 74% and 92% of optic neuritis patients respectively, although most patients remain aware of residual abnormalities in contrast sensitivity, light brightness, visual field or color vision. Only 3% of patients had visual acuity worse than 20/200 in the Optic Neuritis Treatment Trial at 10 years. Recurrence of optic neuritis in the same eye or fellow eye is not uncommon, occurring in 35% of patients at 10 years according to the Optic Neuritis Treatment Trial.

Treatment for optic neuritis is based on the Optic Neuritis Treatment Trial protocol (Beck, 1992), which used IV methylprednisolone 250 mg q 6 hours x 3 days, followed by oral prednisone 1 mg/kg/day for 11 days. This therapy was shown to speed recovery by 1-2 weeks, although there was no long-term benefit for vision. In the group of patients with 2 or more white matter lesions, 16% of optic neuritis patients who were treated with this corticosteroid regimen developed multiple sclerosis, compared with 36% of untreated optic neuritis patients over a two year period. However, this difference equalized by year 3 of the trial (Beck, 1993). Interestingly, patients treated with oral prednisone had a higher rate of recurrence of optic neuritis and therefore is not recommended.

In patients with newly diagnosed optic neuritis, the question of a diagnosis of multiple sclerosis is often raised. In 15-20% of cases, optic neuritis is the initial manifestation of multiple sclerosis. Since it is important not to incorrectly give a patient the diagnosis of multiple sclerosis and commit the patient to lifelong disease modifying treatment, the best and safest criteria for diagnosing multiple sclerosis requires two or more clinical events typical for multiple sclerosis that are separated in time and space with related MRI lesions, as shown in Table 1 (adapted from Ropper, 2009). Table 2 (adapted from McDonald, 2001) shows the McDonald criteria for the diagnosis of multiple sclerosis, applying the classic multiple sclerosis criteria to specific clinical situations. The McDonald criteria were developed for use in research protocols, which remains their most appropriate use. Recurring optic neuritis in the absence of other clinical or laboratory manifestations is not sufficient diagnosis of multiple sclerosis; autoimmune optic neuritis should be considered.

The Controlled High-Risk Subjects Avonex Multiple Sclerosis Prevention Study (CHAMPS) (O'Connor, 2003), evaluated patients without clinically definite multiple sclerosis who are at high risk for developing the disease, based on a single demyelinating event. The single demyelinating event could be any one or more of: optic neuritis, spinal cord syndrome, or brainstem cerebellar syndrome, and 2 or more white matter lesions on MRI. This study found that patients treated with Avonex® (interferon beta-1a) were 44% less likely to develop clinically definite multiple sclero-

sis or to have progression of disability than those treated with placebo over a two-year period. The BENEFIT study showed similar results for Betaseron® (interferon beta-1b) (Kappos, 2007). Initiating immuno-modulating therapy in patients with a single demyelinating event remains controversial however, as this often means a lifetime of therapy in patients that may have a benign disease course without treatment. Many neurologists will follow the patient with repeat brain MRI every six months and decide on treatment based on the presence of the demyelinating activity observed.

In the case above, as is customary in our eye clinic when a patient presents with optic neuritis and has one or more typical demyelinating lesions on brain MRI, we treat based on the Optic Neuritis Treatment Trial protocol. We give 3 daily doses of 1 gram IV Solu-Medrol (methylprednisolone sodium succinate), followed by 1 mg of oral prednisone per kilogram of body weight per day for 11 days (rounded to the nearest 10 mg) followed by a tapering regimen of prednisone consisting of 20 mg on day 15 and 10 mg on

days 16 and 18. Treatment should begin within 8 days of the onset of visual symptoms. We consulted neurology for evaluation for treatment with immuno-modulating therapy for multiple sclerosis, based on 2 episodes of optic neuritis (showing dissemination in time) and multiple periventricular white matter lesions (showing dissemination in space).

Summary

This case describes a 40-year-old female with subacute onset of decreased vision in the right eye, associated with pain with right eye movement, 0.3 - 0.6 relative afferent pupillary defect OD, and a fundus exam notable for temporal pallor OS. Her diagnosis is retrobulbar optic neuritis of the right eye. In retrospect, the patient had similar symptoms in the left eye one year prior that had resolved spontaneously, which is presumed to be from a prior episode of optic neuritis. During the workup of this episode, she was found to have multiple periventricular white matter lesions on MRI, consistent with a diagnosis of multiple sclerosis.

Table 1: Diagnosis of multiple sclerosis based on dissemination in time and space (adapted from Ropper, 2009).

Dissemination in Time	Dissemination in Space
Any new cerebral or spinal T2 lesion on follow-up MRI at any time	One or more lesions in 2 or more characteristic sites <ul style="list-style-type: none"> ◆ periventricular, juxtacortical, posterior fossa, spinal cord ◆ excluding symptomatic brainstem and cord lesions

Table 2: Diagnosis of multiple sclerosis based on the McDonald criteria (adapted from McDonald, 2001).

Clinical Presentation	Additional Data Needed for Multiple Sclerosis Diagnosis
Two or more attacks; objective clinical evidence of 2 or more lesions	None
Two or more attacks; objective clinical evidence of 1 lesion	Dissemination in space, demonstrated by MRI <i>or</i> 2 or more MRI-detected lesions consistent with MS plus positive cerebrospinal fluid (CSF) <i>or</i> await further clinical attack implicating a different site
One attack; objective clinical evidence of 2 or more lesions	Dissemination in time, demonstrated by MRI <i>or</i> second clinical attack
One attack; objective clinical evidence of 1 lesion (monosymptomatic presentation; clinically isolated syndrome)	Dissemination in space, demonstrated by MRI <i>or</i> 2 or more MRI-detected lesions consistent with MS plus positive CSF <i>and</i> dissemination in time, demonstrated by MRI <i>or</i> second clinical attack
Insidious neurological progression suggestive of multiple sclerosis	Positive CSF <i>and</i> dissemination in space, demonstrated by <ol style="list-style-type: none"> 1. 9 or more T2 lesions in brain <i>or</i> 2. 2 or more lesions in spinal cord, <i>or</i> 3. 4-8 brain plus 1 spinal cord lesion <i>or</i> 4. abnormal visual evoked potential associated with 4-8 brain lesions, <i>or</i> 5. with fewer than 4 brain lesions plus 1 spinal cord lesion demonstrated by MRI and dissemination in time, demonstrated by MRI <i>or</i> continued progression for one year

<p>Differential Diagnosis</p> <ul style="list-style-type: none"> ◆ Optic neuritis <ul style="list-style-type: none"> ○ Secondary to demyelination ○ Secondary to infectious causes: Lyme disease, syphilis, tuberculosis ○ Secondary to vasculitis such as lupus ◆ Neuromyelitis optica (Devic's Disease) ◆ Compressive optic neuropathy ◆ Infiltrative optic neuropathy from granulomatous disease or malignancy 	<p>Signs</p> <ul style="list-style-type: none"> ◆ Decreased visual acuity <ul style="list-style-type: none"> ○ 20/20 to no light perception ◆ Visual field defect <ul style="list-style-type: none"> ○ Diffuse visual field loss most common, followed by altitudinal or other nerve fiber bundle-type defects ◆ Relative afferent pupillary defect ◆ Optic disc edema about one-third of adults ◆ Pulfrich's and Uhthoff's phenomena
<p>Symptoms</p> <ul style="list-style-type: none"> ◆ Subacute vision loss over 1-2 weeks, with spontaneous recovery over weeks to months ◆ Pain with eye movement ◆ Decreased color vision 	<p>Treatment</p> <ul style="list-style-type: none"> ◆ IV methylprednisolone 250 mg every 6 hours x 3 days, then ◆ Oral prednisone 1 mg/kg/day for 11 days, then ◆ Taper off over next 4 days

References

Beck RW, Cleary PA, Anderson MM Jr, Keltner JL, Shults WT, Kaufman DI, Buckley EG, Corbett JJ, Kupersmith MJ, Miller NR, et al. A randomized, controlled trial of corticosteroids in the treatment of acute optic neuritis. The Optic Neuritis Study Group. *N Engl J Med.* 1992;326(9):581-8.

Beck RW, Cleary PA, Trobe JD, et al. The effect of corticosteroids for acute optic neuritis on the subsequent development of multiple sclerosis. The Optic Neuritis Study Group. *N Engl J Med.* 1993; 329(24):1764-1769.

Chapters 4, 6 and 14: The Patient with Decreased Vision: Classification and Management Retrobulbar optic neuritis. *BCSC Section 5: Neuro-Ophthalmology.* San Francisco: American Academy of Ophthalmology, 2011.

Kappos L, Freedman MS, Polman CH, Edan G, Hartung HP, Miller DH, Montalban X, Barkhof F, Rade EW, Bauer L, Dahms S, Lanius V, Pohl C, Sandbrink R; BENEFIT Study Group. Effect of early versus delayed interferon beta-1b treatment on disability after a first clinical event suggestive of multiple sclerosis: a 3-year follow-up analysis of the BENEFIT study. *Lancet.* 2007;370(9585):389-97.

Keltner JL, Johnson CA, Spurr JO, Beck RW. Baseline visual field profile of optic neuritis. The experience of the optic neuritis treatment trial. Optic Neuritis Study Group. *Arch Ophthalmol.* 1993;111(2):231-4.

McDonald WI, Compston A, Edan G, et al. Recommended diagnostic criteria for multiple sclerosis: guidelines from the International Panel on the Diagnosis of multiple sclerosis. *Ann Neurol.* 2001;50(1):121-127.

O'Connor P; CHAMPS. The effects of intramuscular interferon beta-1a in patients with high risk for development of multiple sclerosis: a post hoc analysis of data from CHAMPS. *Clin Ther.* 2003;25(11);2865-2874.

Optic Neuritis Study Group. Visual function 15 years after optic neuritis: a final follow-up report from the Optic Neuritis Treatment Trial. *Ophthalmology.* 2008; 115(6):1079-1082.e5.

Chapter 36: Multiple Sclerosis and Allied Demyelinating Diseases. IN: Ropper AH, Samuels MA. *Adams and Victor's principles of neurology. 9th ed.* New York: McGraw-Hill Medical; 2009.

Chapter 1: Optic Neuritis. IN: Thurtell MJ, Tomsak RL, Daroff RB. *Neuro-Ophthalmology: What do I do now?* Oxford; New York: Oxford University Press; 2012.

Citing this article

Kemp PS, Wings, KM, Wall M. Optic neuritis. EyeRounds.org. Posted Sept. 30, 2012. Available from <http://www.EyeRounds.org/cases/159-optic-neuritis.htm>

last updated: 12/29/2012

Case Presentations

Oculoplastic Surgery

"I Can't Open My Eyes": A Case of Blepharospasm and Apraxia of Eyelid Opening

Imran Jivraj, MD; Meredith Baker, MD; Erin Shriver, MD, FACS

February 23, 2015

Initial Presentation

Chief Complaint: Difficulty Opening Eyes

History of Present Illness: A 72-year-old man presented to the oculoplastic clinic reporting an increasingly frequent difficulty opening his eyes for the past two years. He described being unable to open his eyes voluntarily, sometimes thrusting his head backwards or rubbing his brow with his fingers during these episodes. He was also bothered by frequent contractions of the muscles around the eyes on both sides of his face which caused forcible eyelid closure. He believes his inability to control eyelid opening was responsible for a driving accident a few months prior.

Past Ocular History: The patient suffered from bilateral ocular surface irritation, worse upon waking, for which he used preservative-free artificial tears.

Medical History: Previously repaired hip fracture after a motor vehicle accident.

Medications: None.

Family History: None.

Social History: Lives with his wife in a two-bedroom apartment. No smoking or alcohol consumption.

Physical Exam

- ◆ **Visual Acuity** (with correction): 20/25 Right eye (OD) and Left eye (OS)
- ◆ **Extraocular Motility:** Full both eyes (OU)
- ◆ **Pupils:** 4 mm dark, 2 mm light OD; 4 mm dark, 2 mm light OS, no RAPD OU
- ◆ **Intraocular Pressure:** 15 mmHg OU
- ◆ **Confrontation Visual Fields:** Full OU
- ◆ **Hertel Exophthalmometry:** 14 mm OU
- ◆ **External Examination:** Bilateral brow ptosis and dermatochalasis. Frequent spasms of the orbicularis oculi muscles, procerus, corrugators bilaterally, causing forcible eyelid closure. The patient had other episodes where he was unable to open his eyes voluntarily even in the absence of obvious contractions of the protractor muscles; during these moments, he would rub his temples or brows or thrust his head backwards. The upper eyelids were easily everted.
- ◆ **Slit Lamp Examination:** Mild inferior superficial punctate erosions and conjunctival hyperemia OU
- ◆ **Dilated Funduscopic Exam:** Normal disc, macula, vessels, and periphery OU

Course

The patient had evidence of blepharospasm with concurrent apraxia of eyelid opening (ALO). He also demonstrated brow ptosis, floppy eyelids, and dermatochalasis which were likely worsened by blepharospasm. The patient received 5 unit injections of botulinum toxin A into the procerus, corrugator, and at the medial and lateral junctions of the pretarsal and preseptal orbicularis in the upper lids. Injections of botulinum toxin offered symptomatic improvement and an obvious reduction in both the blepharospasm and ALO, although he required increased doses of botulinum toxin at subsequent follow-up appointments. When botulinum toxin failed to produce adequate functional improvements, the patient received bilateral upper eyelid blepharoplasty, pentagonal wedge resection for floppy eyelids, and limited myectomy of both upper lids. Three years later, he underwent bilateral direct browplasty.

He was lost to follow up and presented several years later after sustaining injuries from a motor vehicle collision which he attributed to his reduced visual function from blepharospasm and apraxia of eyelid opening. He underwent additional injections of botulinum toxin A in the pretarsal orbicularis and glabella. One month after the injections he noted significant improvement in his visual function with decreased blepharospasm and apraxia of lid opening. See video: vimeo.com/119006289

Discussion

Blepharospasm is characterized by bilateral, uncontrolled, involuntary spasms of the eyelid protractor muscles and brows, sometimes triggered by stress, intense light, or fatigue. Contractions of the procerus, corrugator, and orbicularis oculi are readily observed on clinical examination with depression of the brow (Charcot sign). During spasms, patients are unable to open their eyes. However, once obvious contractions cease, patients are able to readily initiate eyelid opening. Blepharospasm may occur independently or in association with other disorders of the orofacial muscles (Meige's Syndrome) or cervical muscles (Brüeghel's Syndrome). While the etiology is unclear, associations with essential tremor and Parkinson's disease suggest that blepharospasm may arise from dysfunction of the basal ganglia, although lesions at other cortical and subcortical structures have been identified as well.[1, 2] Because of the coexistence of ocular surface disease, lubrication with artificial tears and blepharitis management with warm compresses and eyelid scrubs should be considered prior to instituting more invasive modalities. FL-41 rose-tinted lenses have been shown to improve discomfort from photophobia as well as reduce blink rate and

eyelid contraction force in patients with blepharospasm.[3] Blepharospasm is exquisitely sensitive to botulinum toxin injection into the eyelid protractors and this is often administered every three months. True failures of botulinum are rare, occurring in fewer than 2% of patients.[4, 5]

Apraxia of eyelid lid opening (ALO) is a condition which may occur concurrently with blepharospasm, or rarely, as an independent condition. Blepharospasm and ALO are frequently observed together in patients with advanced Parkinson's disease (PD) and Progressive Supranuclear Palsy (PSP). A separate review on the diverse ophthalmological features of PD can be found on EyeRounds at eyerounds.org/cases/206-I-cannot-read.htm

ALO is characterized by the intermittent inability to open the eyelids after closure in the absence of apparent contraction of the orbicularis oculi muscle. Unlike blepharospasm, where visible contractions of the eyelid protractors are easily witnessed, patients with ALO exhibit contractions of the frontalis muscle which elevates the brow, employ motor tics such as backward thrusting of the head, or palpate the periocular skin to encourage eyelid opening. ALO is not a true eyelid apraxia; it is better considered a focal eyelid dystonia because the patient's motor system is temporarily prevented from contracting despite normal understanding of the command.[6-8]

Two mechanisms are thought to be at work in ALO. The first is prolonged, involuntary pretarsal orbicularis contraction, where there is persistence of tone in the pretarsal orbicularis muscle despite a command to open the eyelids. The levator palpebrae superioris is unable to overcome its antagonist muscle and eyelid opening is prevented. The second mechanism involves involuntary levator palpebrae inhibition, where initiation of levator contraction is delayed after the command to open the eyelid is initiated.[6, 8, 9]

Botulinum injections into the orbicularis muscle have been largely successful in the management of ALO. Krack and Marion treated 34 patients with ALO, either isolated or coexistent with blepharospasm, PD, or PSP with approximately 30 units of onabotulinumtoxin A per side and found improvements in 83% of patients in all groups.[8] They also suggested that the junction of the pretarsal and preseptal portions of the orbicularis is a more efficacious site of injection, favoring it over injections in the orbital component. Bogen *et al.* found that lid metrics, such as lid opening latency and lid movement durations were prolonged in patients with ALO and improved by 30-38% in patients who were treated with botulinum injections.[10] In a review on the role of botulinum toxin, Jankovic *et al.* summarized the strong evidence for the use of botulinum toxin into the pretarsal orbicularis muscle for patients with ALO, particularly if coexistent with blepharospasm.[11]

The role of systemic dopaminergic therapy as another treatment for ALO has been suggested in select case reports. Lee *et al.* described a patient with PD who developed ALO after the dose of levodopa/carbidopa was reduced.[12] When therapy was resumed, the ALO resolved. Yamada *et al.* described a patient with PSP whose ALO was resistant to injections of higher doses of botulinum toxin,

but responded to an augmented dose of levodopa/benserazide.[13] The mechanism at play is not well understood, but it is likely that supplementary dopamine at the level of the basal ganglia may improve the component of ALO resulting from involuntary inhibition of the levator muscle.

Deep brain stimulation of the subthalamic nucleus has been used as a therapeutic modality for PD and has been shown to induce ALO in some patients while improving pre-existing ALO in others.[14-16] The varied impact of subthalamic stimulation on ALO has not yet been explained, but it may relate to creating a lesion of unique structural and functional components within the subthalamic nucleus whose role on ALO is not yet understood. Another possibility is that electrical current from deep brain stimulation spreads to adjacent structures which impacts ALO.

In patients whose blepharospasm does not respond satisfactorily to botulinum toxin, the possibility of unwitnessed ALO must be considered. As mentioned, true failures of botulinum toxin are exceedingly rare, and it has been suggested that most patients whose blepharospasm does not respond to botulinum toxin have coexistent ALO. Rana *et al.* described two patients with ALO and blepharospasm and PSP who responded to an initial treatment with botulinum toxin but later stopped responding satisfactorily despite increased doses. Only after a partial orbicularis myectomy was performed in one, and eyelid crutches instituted in the other, did persistent botulinum toxin injections offer therapeutic benefit.[17] An approach which combines treatment modalities with botulinum toxin may be considered in patients with ALO who are refractory to botulinum alone.

Anderson *et al.* have been strong proponents for the role of surgical myectomy in patients with ALO coexistent with blepharospasm who are refractory to botulinum toxin.[5, 18, 19] They conducted a retrospective chart review of patients in whom blepharospasm was refractory to botulinum injections. Patients underwent a full orbicularis myectomy of the upper eyelids with removal of every filament of orbicularis muscle as well as removal of the procerus, corrugator, depressor supraciliaris, repair of associated eyelid malpositions, as well as punctal occlusion. Forty-five of the 51 patients had concurrent ALO, and 33% of patients had a completed "cure" of ALO, while 50% experienced some improvement in ALO symptoms. Complications from the surgery included orbital hemorrhage, post-operative ocular surface disease, forehead numbness, and the need for further surgery. This study was retrospective and subject to recall bias; moreover, the surgical procedure was not standardized as surgery for eyelid malposition and/or punctal occlusion was offered simultaneously. Despite these weaknesses, the study suggests a role for surgical myectomy in improving ALO refractory to botulinum toxin.[5]

Selected case reports have identified a potential role for brow lifting in patients who are refractory to botulinum and surgical myectomy. However, compromise of an already tenuous ocular surface from brow elevation must

be strongly weighed against the potential benefit on ALO symptoms in patients with PD.[20]

Blepharospasm, characterized by bilateral involuntary contractions of the eyelid protractors, is exquisitely sensitive to injections of botulinum toxin. True failures of botulinum toxin are rare, and ALO must be suspected in these cases. ALO, better described as an eyelid dystonia, is often responsive to botulinum toxin injections into the pretarsal orbicularis muscle or at the junction of the pretarsal and preseptal orbicularis muscle. In patients who are refractory to botulinum toxin injections, other complementary therapies, such as eyelid crutches and surgical myectomy should be considered. Patients suffering from PD may benefit from augmented systemic dopaminergic therapy in consultation with the patient's neurologist. The role of more invasive treatments, such as deep brain stimulation of the subthalamic nucleus, remains to be elucidated. Further research which seeks to quantify the electromyographic components of ALO will allow ophthalmologists to better understand the mechanisms at play in an individual patient's ALO and offer targeted treatments to improve patients' visual function and quality of life.

References

1. Coscarelli JM. Essential blepharospasm. *Semin Ophthalmol* 2010;25(3):104-8.[PMID: 20590421].
2. Khooshnoodi MA, Factor SA, Jinnah HA. Secondary blepharospasm associated with structural lesions of the brain. *J Neurol Sci* 2013;331(1-2):98-101.[PMID: 23747003].
3. Blackburn MK et al. FL-41 tint improves blink frequency, light sensitivity, and functional limitations in patients with benign essential blepharospasm. *Ophthalmology* 2009;116(5):997-1001.[PMID: 19410958].
4. Forget R. et al. Botulinum toxin improves lid opening delays in blepharospasm-associated apraxia of lid opening. *Neurology* 2002;58(12):1843-6.[PMID: 12084888].
5. Georgescu D et al. Upper eyelid myectomy in blepharospasm with associated apraxia of lid opening. *Am J Ophthalmol* 2008;145(3):541-547.[PMID: 18191096].
6. Ugarte M. and Teimory M. Apraxia of lid opening. *Br J Ophthalmol* 2007;91(7):854.[PMID: 17576707].
7. Jankovic J. Apraxia of lid opening. *Mov Disord* 1995;10(5):686-7.[PMID: 8552131].
8. Krack P, Marion MH. Apraxia of lid opening, a focal eyelid dystonia: clinical study of 32 patients. *Mov Disord* 1994;9(6): 610-5.[PMID: 7845400].
9. Esteban A. and Gimenez-Roldan S. Involuntary closure of eyelids in parkinsonism. Electrophysiological evidence for prolonged inhibition of the levator palpebrae muscles. *J Neurol Sci* 1988;85(3):333-45.[PMID: 3210029].
10. Boghen D. Apraxia of lid opening: a review. *Neurology* 1997;48(6):1491-4.[PMID: 9191752].
11. Jankovic J. Disease-oriented approach to botulinum toxin use. *Toxicon* 2009;54(5):614-23.[PMID: 19073203].
12. Lee KC, Finley R, and Miller B. Apraxia of lid opening: dose-dependent response to carbidopa-levodopa. *Pharmacotherapy* 2004;24(3):401-3.[PMID: 15040654].
13. Yamada S, et al. The effects of levodopa on apraxia of lid opening: A case report. *Neurology* 2004;62(5):830-1.[PMID: 15007147].
14. Fuss G. et al. Improvement of apraxia of lid opening by STN-stimulation in a 70-year-old patient with Parkinson's disease: A case report. *Minim Invasive Neurosurg* 2004; 47(1):58-60.[PMID: 15100935].
15. Tommasi G et al. Effects of varying subthalamic nucleus stimulation on apraxia of lid opening in Parkinson's disease. *J Neurol* 2012;259(9):1944-50.[PMID: 22349870].
16. Goto S et al. Apraxia of lid opening is alleviated by pallidal stimulation in a patient with Parkinson's disease. *Eur J Neurol* 2000;7(3):337-40.[PMID: 10886319].
17. Rana AQ and Shah R. Combination of blepharospasm and apraxia of eyelid opening: a condition resistant to treatment. *Acta Neurol Belg* 2012;112(1):95-6.[PMID: 22427299].
18. Jordan DR, Anderson RL, and Digre KB. Apraxia of lid opening in blepharospasm. *Ophthalmic Surg* 1990;21(5):331-4.[PMID: 2381654].
19. Pariseau B. Worley MW, and Anderson RL. Myectomy for blepharospasm 2013. *Curr Opin Ophthalmol* 2013;24(5):488-93.[PMID: 23925062].
20. Nicoletti AG, Pereira IC, and S. Matayoshi. Browlifting as an alternative procedure for apraxia of eyelid opening. *Ophthal Plast Reconstr Surg* 2009;25(1):46-7. [PMID: 19273924].

Suggested Citation Format

Jivraj I, Baker MS, Shriver EM. "I Can't Open My Eyes": A Case of Blepharospasm and Apraxia of Eyelid Opening. Feb 23, 2015; Available from: <http://EyeRounds.org/cases/207-blepharospasm.htm>

last updated: 02/23/2015

Carotid Cavernous Fistula

Alex W. Cohen, MD, PhD; Richard Allen, MD, PhD

May 14, 2010

Initial Presentation

Chief Complaint: Double vision.

History of Present Illness: A 46-year-old female patient presented to the Oculoplastics Clinic reporting double vision and visual distortion. The patient first noticed binocular horizontal diplopia two months prior to her visit. She described diplopia in primary position that worsened in right gaze and she had resorted to wearing an occlusive patch in order to control her symptoms. Three months prior to the current visit the patient noted the presence of a large blood vessel above her right eye. She also reported a whooshing sound in her right ear for 2-3 months.

Past Ocular History: The patient was in a bicycle accident four months prior during which she sustained a small zygomaticomalar complex fracture (Figure 1). The patient was seen in the ophthalmology clinic three weeks later and was noted to have no diplopia, no gaze restriction, and a normal eye exam. She was asked to follow up two months later.

Medical History: Alcohol dependency and depression

Medications: Claritin® (loratadine)

Family History: Substance abuse, neck cancer, heart disease.

Social History: Alcohol dependency

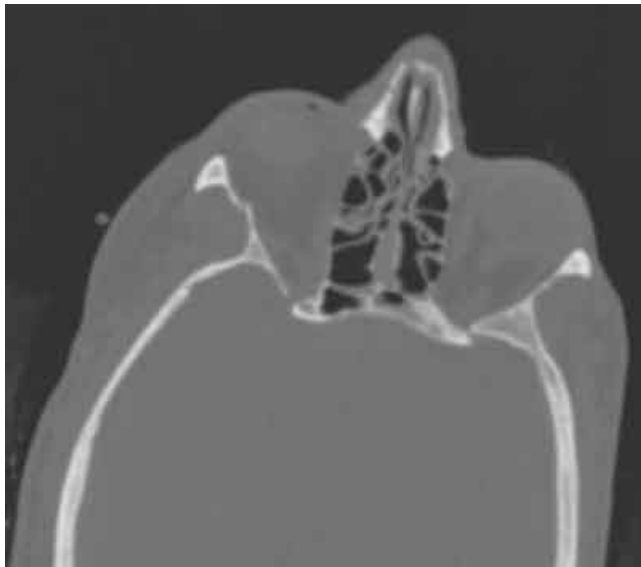


Figure 1: CAT scan obtained on initial presentation after biking injury. Note the small ZMC fracture on the right side (arrow)

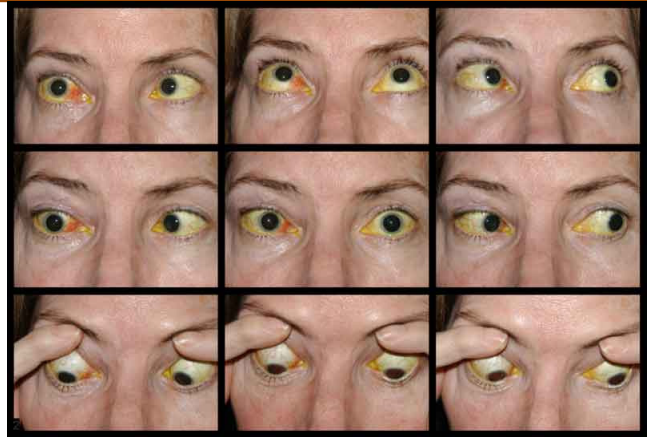


Figure 2: Motility photos: Note the abduction deficit in the right eye.

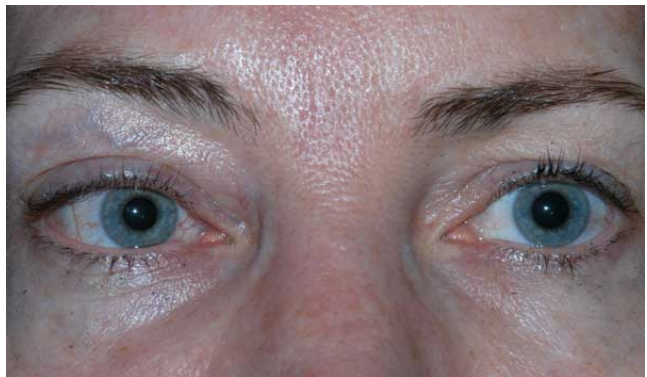

Figure 3: External Examination four months after initial injury. Note the dilated veins on the upper and lower right eyelids as well as the engorged nasal conjunctival vessels.

Physical Exam

- ◆ Visual Acuity (without correction)
 - 20/20 Right eye (OD)
 - 20/20 Left eye (OS)
- ◆ Extraocular motility: -3 abduction deficit OD and Full OS (see figure 2)
- ◆ Pupils: OD 6mm dark, 4 mm light; OS 6 mm dark, 4 mm light; No relative afferent pupillary defect (RAPD)
- ◆ Intra-ocular pressure: 14 mmHg OD, 12 mmHg OS
- ◆ Confrontation visual fields (CVF): Full OD and OS
- ◆ Hertel: 21 mm OD, 17 mm OS, base 95 mm
- ◆ External examination: Venous engorgement of the right upper and lower eyelids; Orbital bruit present over the right eye (see Figure 3).
- ◆ Anterior segment examination: Conjunctival injection OD. Otherwise normal examination, both eyes (OU)
- ◆ Dilated funduscopy exam: Normal macula, vasculature and periphery OU

Course

A presumptive diagnosis of right-sided carotid cavernous fistula (CCF) was made based on clinical suspicion and the findings of proptosis, venous engorgement, orbital bruit, and abduction deficit. The patient was sent for MRI/MRA imaging of the brain that afternoon. The images demonstrated a right CCF as well as a markedly dilated right superior ophthalmic vein (Figures 4, 5, and 6). The patient was then seen in the Neurointerventional Clinic and scheduled for coiling of the fistula later that week.

The patient underwent coiling of the right internal carotid artery (Figures 7 and 8). During the procedure, a high flow, expansive connection between the artery and the cavernous sinus and collateral veins was noted. There was also extensive arterial damage to the right cavernous internal carotid artery consistent with dissection. Good flow was seen to cross a patent anterior communicating artery so the fistula was treated with right internal carotid artery sacrifice, using coil embolization. Fortunately, the right ophthalmic artery remained perfused via collateral circulation. After the procedure the patient had an unremarkable hospital course and she was discharged home six days later.

Discussion

A carotid-cavernous fistula (CCF) is an abnormal communication between the venous cavernous sinus and the carotid artery. The fistula may occur spontaneously but usually occurs following some sort of head trauma, as in

the case of our patient. In one retrospective study, the time to presentation following injury ranged from one day to as late as 2 years.

There are four distinct types of fistulas (types A-D). A type A fistula is a direct, high flow fistula between the cavernous internal carotid artery and the cavernous sinus. It is the most common CCF following head trauma. Direct fistulas are thought to form from a traumatic tear in the wall of the cavernous internal carotid artery or following rupture of an aneurysm. Thus high pressure arterial blood gains rapid access to the venous system and leads to venous hypertension.

Type B-D, or indirect fistulas, occur between meningeal branches of the external or internal carotid artery and the cavernous sinus. These are low-flow fistulas. The etiology of types B-D is unclear, but they have been associated with pregnancy, sinusitis, age, and trauma. Symptoms are usually mild and may include dilated conjunctival and episcleral vessels and mild proptosis. These low flow fistulas generally resolve without treatment.

The onset of symptoms with a Type A fistula is usually rapid and can be very dramatic. Patients with a direct Type A fistula generally present with varied complaints, including unilateral visual loss, proptosis, lid swelling, pulsatile tinnitus and/or diplopia. A triad of clinical findings has been described as exophthalmos, orbital bruit, and dilated conjunctival vessels. Clinical findings include venous congestion of the eyelids, conjunctiva and episcleral vessels, cranial nerve palsies (3, 4, or 6), visual loss, proptosis, elevated intraocular pressure, optic disc edema, and dilated and tortuous retinal vessels.

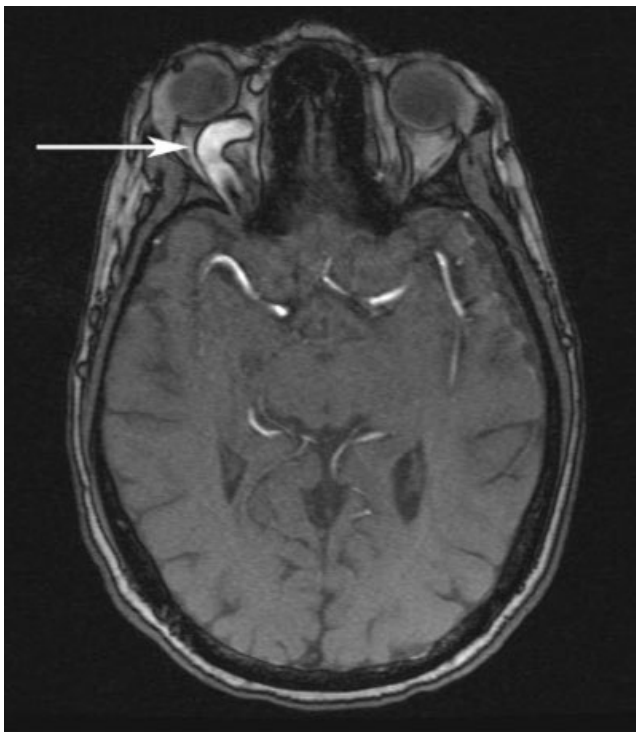


Figure 4: Magnetic Resonance Angiogram (MRA) image demonstrating an enlarged superior ophthalmic vein (arrow).

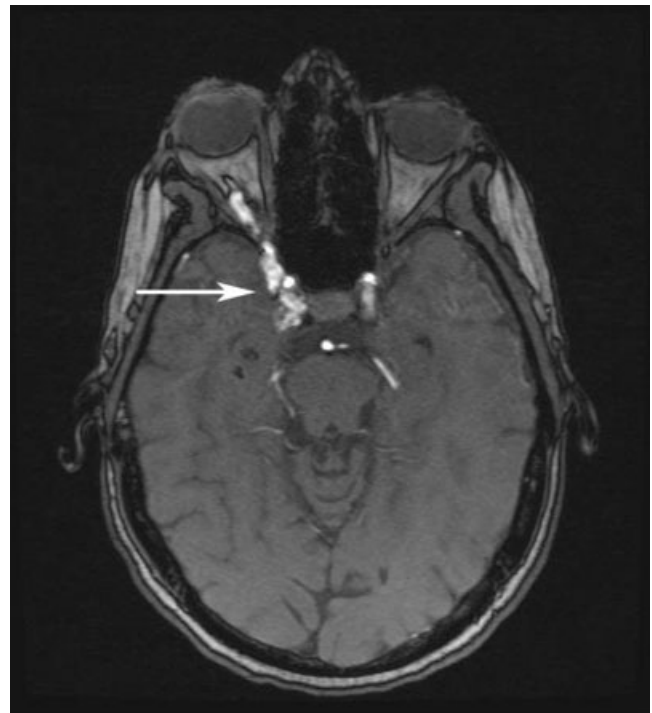


Figure 5: MRA demonstrating a right carotid cavernous fistula (arrow)

In one retrospective study of 11 traumatic CC fistulas the most common clinical signs were proptosis, dilated conjunctival vessels, and an orbital bruit, all of which were found in 100% of the patients (Brosnahan, 1992). The second most common clinical finding was conjunctival chemosis, occurring in 10/11 patients. 8/11 patients has a sixth nerve palsy while 5/11 patients had a third nerve palsy and 5/11 had a fourth nerve palsy. An efferent pupillary defect secondary to a third nerve palsy was present in 5/11 patients. Less common findings included elevated intraocular pressure (range 26-30 mmHg.3/11 patients), loss of vision(2/11 patients), optic disc edema (2/11 patients), and dilated retinal vessels (4/11 patients).

Once a direct CCF is identified it is important to direct the patient to the appropriate treating specialist, either an interventional neurologist or neurosurgeon. Direct fistulas

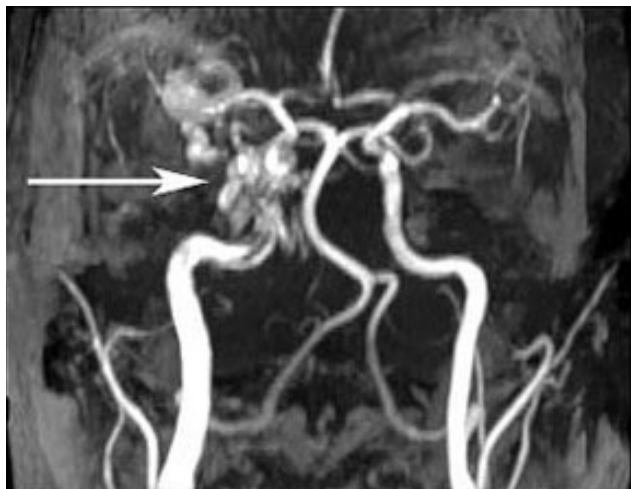

Figure 6: Three dimensional reconstructed image showing the CC fistula (arrow)

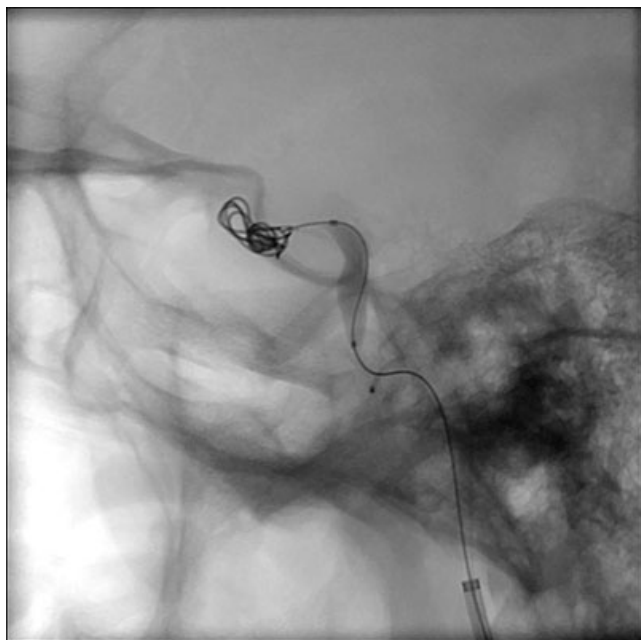


Figure 7: Intraoperative image demonstrating coil being deployed within the internal carotid system

always require treatment. The literature is replete with different treatment modalities, including transarterial or transvenous embolization with coils, liquid embolic agents, balloon embolization, and stent placement. The success rate of closing the fistula with these treatments ranges from 55-99%. Potential complications of treatment include worsening of an oculomotor nerve palsy and loss of vision.

Diagnosis

Carotid Cavernous Fistula

EPIDEMIOLOGY	SIGNS
<ul style="list-style-type: none"> ◆ Trauma ◆ Ruptured aneurysm 	<ul style="list-style-type: none"> ◆ Orbital bruit ◆ Dilated conjunctival vessels ◆ Exophthalmos ◆ Blood in Schlemm's Canal ◆ Elevated intraocular pressure ◆ Oculomotor nerve palsy
SYMPTOMS	TREATMENT
<ul style="list-style-type: none"> ◆ Decreased vision ◆ Pulsatile tinnitus ◆ Diplopia ◆ Proptosis 	<ul style="list-style-type: none"> ◆ Endovascular coiling ◆ Observation

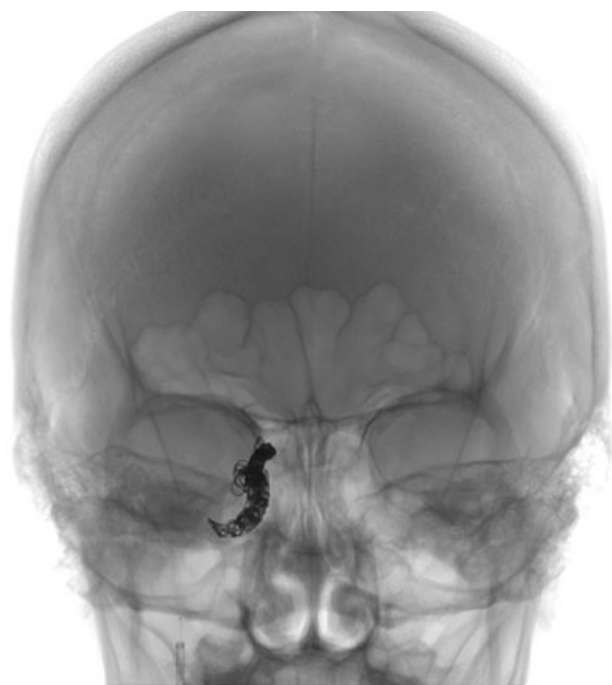

Figure 8: Postoperative image showing coils within the internal carotid artery

Differential Diagnoses

- ◆ Dural Cavernous Fistula
- ◆ Orbital Hemorrhage
- ◆ Orbital Tumor
- ◆ Orbital Varix

References

1. Brosnahan D, McFadzean RM, and Teasdale E. Neuro-ophthalmic features of carotid cavernous fistulas and their treatment by endoarterial balloon embolisation. *Journal of Neurosurgery, Neurosurgery, and Psychiatry*; 1992, Vol. 55:553-556.
2. Gemmete JJ, Ansari SA, Gandhi DM. Endovascular techniques for treatment of carotid-cavernous fistula. *J Neuro-Ophthalmology*. 2009, Vol 29: 62-71.
3. Uysal E, Kizilkili O, Ulusay M, Basak M. Endovascular trapping of direct carotid-cavernous fistula. *J Clin Neurosci*. 2010 Mar;17(3):392-4.
4. Wadlington VR, Terry JB. Endovascular therapy of traumatic carotid-cavernous fistulas. *Crit Care Clin*. 1999 Vol 15(4):831-54.

Suggested citation format

Cohen AW, Allen R. Carotid Cavernous Fistula. *EyeRounds.org*. May 14, 2010; Available from: <http://www.EyeRounds.org/cases/111-Carotid-Cavernous-Fistula.htm>.

last updated: 05-14-2010

Chalazion

Acute presentation and recurrence in a 4-year-old female

Justin Kuiper, BA, Jesse M. Vislisel, MD, Thomas A. Oetting, MD

August 23, 2014

History of Present Illness (HPI)

The patient is a 4-year-old female patient who was referred to the pediatric ophthalmology and strabismus clinic at the University of Iowa for evaluation of a bump of the right lower lid. The parents first noticed it about two weeks prior. There was no recollection of prior trauma or insect bites to the area. They were seen at their local family care center and were given oral Bactrim (trimethoprim/sulfamethoxazole). The patient had taken the medication for four days, but there was no improvement of the area. The patient was acting well and did not report any pain in the area.

Past Ocular History: No other ocular history.

Family Ocular History: Negative for ocular problems.

Past Medical History:

Normal growth and development and no history of illness.

Ocular medications:

Bactrim (trimethoprim/sulfamethoxazole) suspension 10 ml, by mouth (PO), twice daily (BID) for 10 days, currently on day four.

Systemic medications: None.

Social History:

The patient lives at home with her parents. She does not have siblings. The family recently moved to Iowa from Florida.

Review of Systems:

A complete review of systems is negative except as in HPI.

OCULAR EXAMINATION

Visual acuity (LEA symbols) without correction

- ◆ Right eye (OD): 20/30
- ◆ Left eye (OS): 20/25

Pupils: 4 mm in dark, 2 mm in light, no relative afferent pupillary defect both eyes (OU).

Alignment: Orthophoric

Extraocular movements: Full OU

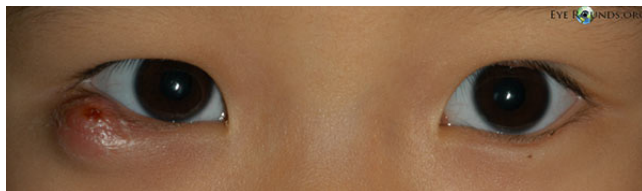

Figure 1. Initial presentation showed a 1.0 mm x 0.7 mm firm nodule on the lateral aspect of the right lower lid with superficial overlying skin breakdown and erythema.

Slit Lamp Exam (Figure 1)

Right eye

- ◆ Eyelids: 1.0 mm x 0.7 mm firm nodule on the lateral aspect of the right lower lid with superficial overlying skin breakdown and erythema. No periorbital erythema or edema.
- ◆ Conjunctiva: white and quiet
- ◆ Cornea: clear
- ◆ Anterior chamber: deep and quiet
- ◆ Iris: round and regular
- ◆ Lens: clear

Left eye

- ◆ Eyelids: normal
- ◆ Conjunctiva: white and quiet
- ◆ Cornea: clear
- ◆ Anterior chamber: deep and quiet
- ◆ Iris: clear
- ◆ Lens: clear

Clinical Course

The patient was diagnosed with a chalazion of the right lower eyelid. She was sent out with a plan for conservative management including warm compresses and topical erythromycin ointment. She was seen for follow-up 10 days later with continued enlargement of the lesion, so she was taken to the operating room for incision and drainage.

Following the procedure, the chalazion appeared significantly improved (Figure 2) and it eventually resolved completely. She presented again nine months after her initial presentation, this time for a left upper lid lesion, also thought to be a chalazion (Figure 3), which later resolved with conservative treatment.

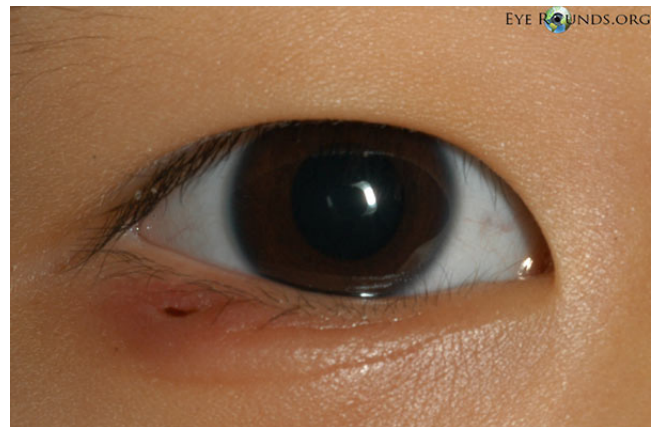

Figure 2. Post-operative appearance 1 week after chalazion incision and drainage showed significant improvement of the right lower lid.

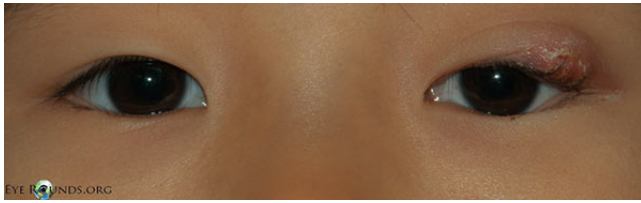

Figure 3. Clinical appearance 9 months after incision and drainage of the initial lesion. Note the complete resolution of the chalazion on the right lower lid. Since the procedure, the patient developed a large left upper lid chalazion.

DISCUSSION

A chalazion is a localized, lipogranulomatous lesion of the eyelid. It is an inflammatory process, caused by an obstruction of the sebaceous glands of the eyelid (meibomian and Zeiss) from inflammatory disease (eg, acne rosacea), infection (eg, seborrheic dermatitis), or neoplasm (eg, sebaceous gland carcinoma or Merkel cell carcinoma) (1). This obstruction causes secreted lipids to accumulate and leak into the collagenous stroma of the tarsal plate, triggering an immune reaction first made up of neutrophils, and later lymphocytes, plasma cells, macrophages, mononuclear cells, eosinophils, and multinucleated giant cells. Pathology of the lesion shows that acutely it presents with a suppurative pattern (mainly neutrophils), but may develop into a more chronic granulomatous pattern over time (2).

A chalazion is the most common inflammatory lesion of the eyelids (3). Patients often present with a persistent (often more than 2 weeks), initially painless nodule in the eyelid (Figure 4). The lesion may grow and distort the lid causing discomfort in the surrounding tissue (4). Chalazia can induce reversible vision changes from astigmatism and corneal irregularity due to compression of the cornea (5). This presentation is fairly consistent; a retrospective study of over 1000 cases showed that ophthalmologists are able to correctly diagnose chalazia by clinical symptoms nearly 94% of the time (3).

Other lesions can look similar to a chalazion, however in the setting of recurrent or difficult to treat chalazia in older patients, it is important to rule out neoplasm (6). One common mimic is sebaceous cell carcinoma. This also presents most commonly as a small, rubbery, firm nodule, and diagnosis is further complicated because sometimes there is true chalazion formation secondary to obstruction of the meibomian ducts from the carcinoma (7). Another lesion that can present similarly to a chalazion is a hordeolum (commonly referred to as "stye"). Although a chalazion and hordeolum are similar clinically, the underlying pathology is different. An internal hordeolum is an acute, painful, inflamed lesion near the eyelid margin caused by infection (predominantly staphylococcal) of the tarsal meibomian glands, which leads to a small abscess. An external hordeolum is also an abscess (predominantly staphylococcal), but it is located in the eyelash follicles and surrounding sebaceous and apocrine glands (Zeis and Moll) (1).

Although many patients wait for an acute chalazion to heal without any intervention, there are reports that this only occurs roughly 25-50% of the time (8-9). For patients that present to clinic, depending on how advanced the lesion is at presentation, most ophthalmologists recommend a trial of conservative management before surgical intervention. Conservative management includes some combination of frequent warm compresses, massage of the lesion, and lid scrubs. This increases clearance of acute inflammation to 40-80% (10-11).

If a patient fails conservative management, the two most common interventions are steroid injections and incision and drainage (I&D) (summary in Table 1). Steroid injections are usually performed with triamcinolone acetamide which may be injected transcutaneously or transconjunctivally. Steroid injections are effective at reducing the size of the lesion or curing it completely 60-84 % of the time with one treatment (9, 12-14), but success increases to as high as 77-89% with two or more injections (9, 15). The most common adverse reaction to this treatment is skin

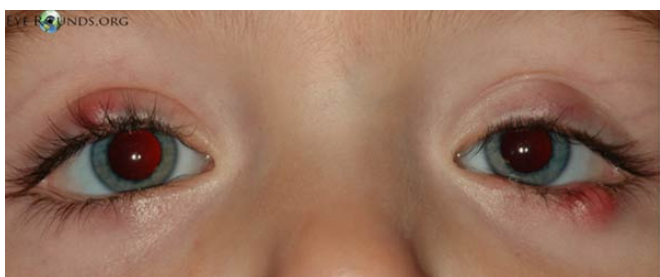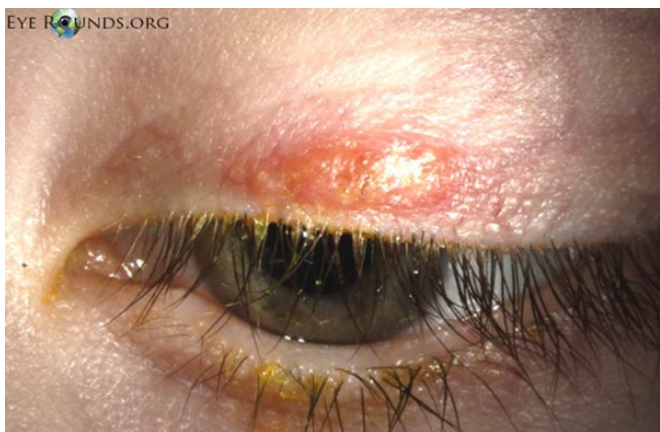

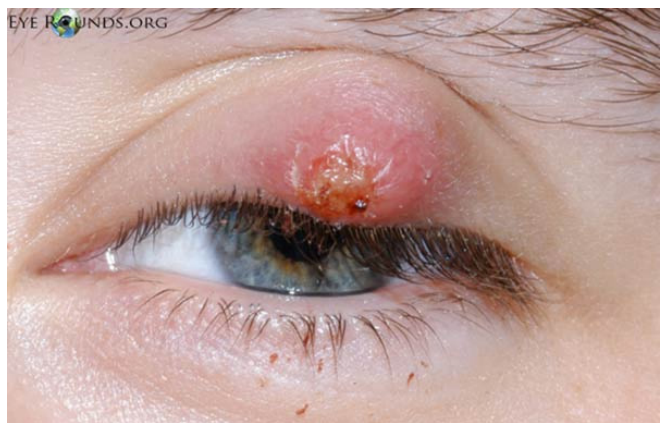
Figure 4. Examples of chalazia in three separate patients.

depigmentation (particularly in darkly pigmented patients), but using a transconjunctival approach to injection reduces this risk. Other possible risks include atrophy of the orbital and subcutaneous fat, increased intraocular pressure, and accidental intraocular injection (13). This treatment is less invasive than I&D and is generally considered more convenient for patients (9). It may also be safer in the setting of multiple chalazia or in those located near the lacrimal puncta (12).

The other common option for management is incision and drainage (Figure 5). This is performed by securing the lesion with a chalazion clamp, everting the eyelid, opening the conjunctiva over the lesion with a scalpel, and curetting out the granulomatous substance inside (Video 1). Risks of the operation include infection, bleeding, and damage to lid structures. Older children and adults can often undergo the procedure under local anesthesia, but general anesthesia is required in young children. It is highly effective; there is improvement of the lesion or complete resolution at a rate of 79-87% with a single operation (9, 12, 13) and as high as 90% with two operations (13, 15). There is reported to be an increased rate of complete resolution or "cure" compared to steroid injections (16). An additional benefit of I&D is that tissue may be sent to pathology to confirm the diagnosis, which is particularly useful in situations where the lesions are recurrent or clinically do not appear clearly to be a chalazion. Even with appropriate treatment of chalazia, recurrence is common. It is difficult to estimate the incidence however, as patients with resolution are often lost to follow up and chalazia can recur years after treatment, thus requiring a study with a very long follow up period. One study by Sendrowski and Maher showed that 22-26% of patients who have one chalazion treated with incision and drainage developed recurrence during the course of a two-year follow up period (17).

Diagnosis: Chalazion

Differential Diagnosis

- ◆ Hordeolum
- ◆ Sebaceous cell carcinoma
- ◆ Merkel cell tumor
- ◆ Seborrheic keratosis
- ◆ Basal cell carcinoma
- ◆ Squamous cell carcinoma
- ◆ Keratoacanthoma
- ◆ Epithelial inclusion cyst
- ◆ Pyogenic granuloma
- ◆ Preseptal cellulitis

See video demonstration of chalazion incision and drainage at www.youtube.com/watch?v=Zlaeh8CBJXc {<http://bit.ly/2t7Mmmq>}

Table 1. Comparison of steroid injection vs. I&D for management of chalazion

	Steroid Injection	Incision and Drainage
Efficacy - Single treatment	◆ 60-84 % (9,12-14)	◆ 79-87% (9,12,13)
- Second treatment	◆ 77-89% (9,15)	◆ >90% (13,15)
Pros	<ul style="list-style-type: none"> ◆ More convenient ◆ Less invasive ◆ Good for multiple lesions or near puncta 	<ul style="list-style-type: none"> ◆ Highly effective ◆ Pathological diagnosis ◆ Higher rate of complete cure
Cons	<ul style="list-style-type: none"> ◆ Risk of skin depigmentation ◆ May be less convenient if multiple treatments are required 	<ul style="list-style-type: none"> ◆ Less convenient ◆ Higher risks of bleeding and infection

<p>EPIDEMIOLOGY</p> <ul style="list-style-type: none"> ◆ Most common inflammatory lesion of the eyelid ◆ 13.4% of all benign lid lesions are chalazia (18) 	<p>SIGNS</p> <ul style="list-style-type: none"> ◆ Firm, persistent nodule of the eyelid which may progress to become edematous with overlying erythema
<p>SYMPTOMS</p> <ul style="list-style-type: none"> ◆ Typically painless, but eyelid discomfort and swelling can develop if the lesion progresses to a large size ◆ May cause astigmatism and visual distortion 	<p>TREATMENT</p> <ul style="list-style-type: none"> ◆ Warm compresses and lid hygiene ◆ Triamcinolone injection ◆ Incision and drainage

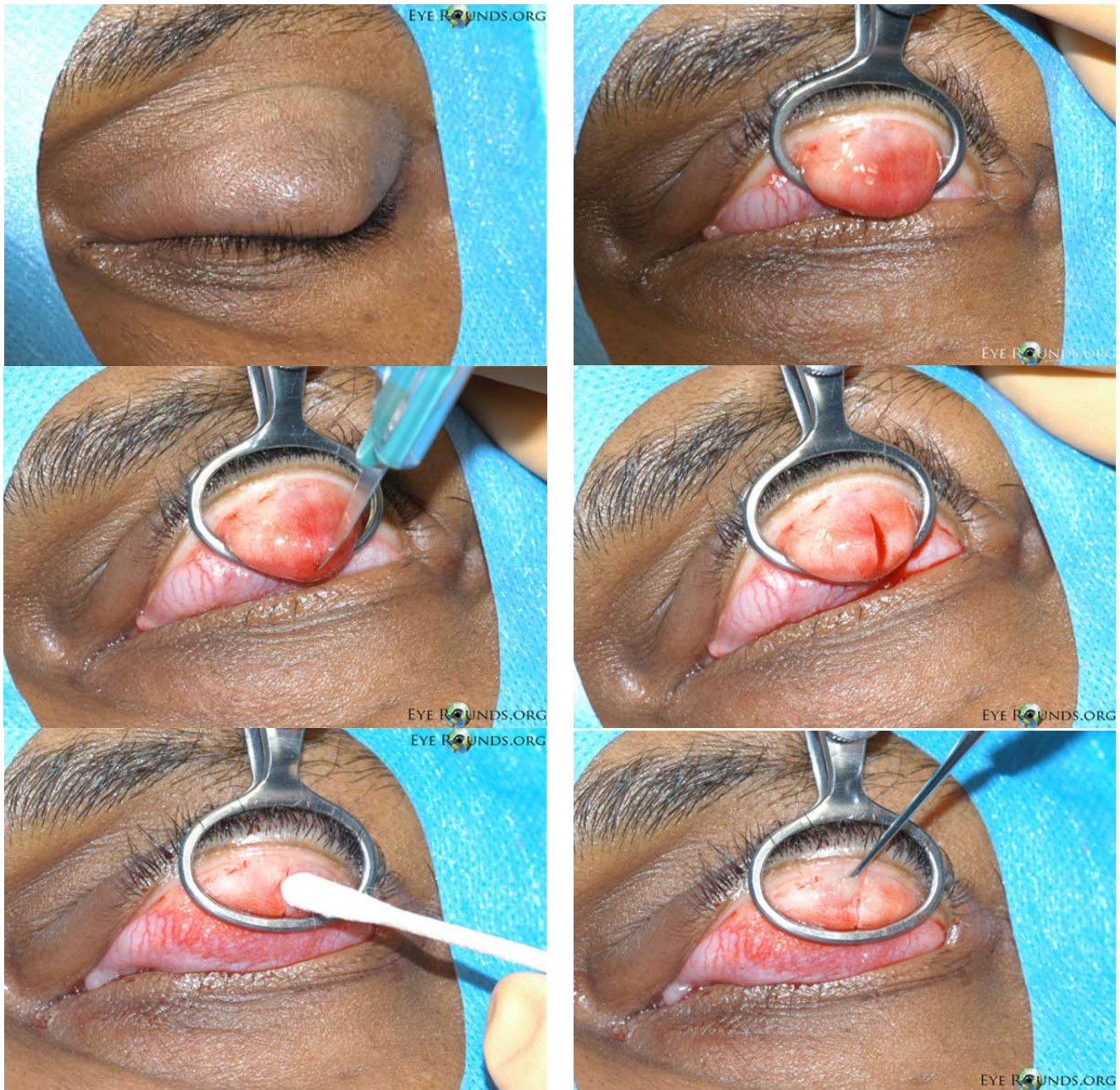


Figure 5. Procedural photographs for the incision and drainage of a chalazion.

(A) Draping of the patient with sufficient exposure of the lesion in the left upper lid. First, the eye is anesthetized topically. Then a mixture of lidocaine and epinephrine is injected into the eyelid to provide local anesthesia.

(B) A chalazion clamp is placed and tightened with the lesion in the center of the ring and the eyelid is everted. This exposes the lesion and helps with hemostasis.

(C) A size 11 scalpel blade is used to incise across the center of the lesion, dissecting down to the level of the tarsal plate.

(D) The lesion may be opened with a single, vertical incision as shown here, or with two perpendicular incisions forming an “x” shape. We usually prefer the single incision as there is less potential for disruption of adjacent meibomian glands.

(E) Some contents may be drained with gentle pressure from a cotton tip applicator.

(F) A curette is inserted into the lesion to thoroughly excise the remaining contents and break adhesions. Westcott scissors may be used to remove any excessive scar tissue within the lesion. Gentle electrocautery may be used to assist with hemostasis. The clamp is then removed and the incision is left open to encourage further drainage.

References

1. Skorin, L. Hordeolum and chalazion treatment: the full gamut. *Optometry Today*. 2002; 25-27.
2. Dhaliwal, U, Arora, VK, Singh, N, Bhatia, A. Cytopathology of Chalazia. *Diagnostic Cytopathology*. 2004; 31:118-122.
3. Ozdal, PC, Codere, F, Callejo, S, Caissie, AL, Burnier, MN. Accuracy of clinical diagnosis of chalazion. *Eye*. 2004; 18:135-138.
4. Wald, E. Periobital and orbital infections. *Infect Dis Clin N Am*. 2007; 21:393-408.
5. Bagheri, A, Hasani, HR, Karimian, F, Abrishami, M, Yazdani, S. Effect of chalazion excision on refractive error and corneal topography. *Eur J Ophthalmol*. 2009; 19:521-526.
6. Mueller, JB, McStay, CM. Ocular Infection and Inflammation. *Emerg Med Clin N Am*. 2008; 26:57-72.
7. Johnson, S, Nerad, JA, Syed NA. Sebaceous Cell Carcinoma: A Masquerade Syndrome. *EyeRounds.org*. January 23, 2007; Available from: eyerounds.org/cases/62-Sebaceous-Cell-Carcinoma-A-Masquerade-Syndrome.htm.
8. Cottrell, DG, Bosanquet, RC, Fawcett, IM. Chalazions: the frequency of spontaneous resolution. *British Medical Journal*. 1983; 287:1595.
9. Goawalla, A, Lee, V. A prospective randomized treatment study comparing three treatment options for chalazia: triamcinolone acetonide injections, incision and curettage and treatment with hot compresses. *Clin Exp Ophthalmol*. 2007; 35(8):706 –712.
10. Garrett GW, Gillespie ME, Mannix BC. Adrenocorticosteroid injection vs. conservative therapy in the treatment of chalazia. *Am J Ophthalmol*. 1978; 85:818-821.
11. Perry, HD, Serniuk, RA. Conservative treatment of chalazia. *Ophthalmology*. 1980; 87(3):218-221.
12. Simon, GB, Rosen, N, Rosner, M, Spierer, A. Triamcinolone Acetonide Injection Versus Incision and Curettage for Primary Chalazia: A Prospective, Randomized Study. *Am J Ophthalmol*. 2011; 151:714-718.
13. Ahmad, S, Baig, MA, Khan, MA, Khan, IU, Janjua, TA. Intra-lesional corticosteroid injection vs surgical treatment of chalazia in pigmented patients. *J Coll Physicians Surg Pak* 2006; 16:42–44.
14. Vidaurri, LJ, Pe'er, J. Corticosteroid Treatment of Chalazia. *Ann Ophthalmol*. 1986; 18:339-340.
15. Watson, AP, Austin, DJ. Treatment of chalazions with injection steroid suspension. *Br J Ophthalmol* 1984; 68:833–835.
16. Jacobs, PM, Thaller, VT, Wong, D. Intralesional corticosteroid therapy of chalazia: a comparison vs. incision and curettage. *Br J Ophthalmol*. 1984; 68:836-837.
17. Sendrowski, DP, Maher, JF. Thermal Cautery After Chalazion Surgery and Its Effect on Recurrence Rates. *Optom Vis Sci*. 2000; 77(11): 605-607.
18. Tesluk, G. Eyelid lesions: incidence and comparison of benign and malignant lesions. *Ann Ophthalmol*. 1985; 17:704-707.

Suggested Citation format

Kuiper J, Vislisel J, Oetting T. Chalazion: Acute presentation and recurrence in a 4-year-old female. *EyeRounds.org*. August 25, 2014; available from <http://EyeRounds.org/cases/193-Chalazion.htm>

last updated: 08/25/2014

Bell's Palsy Treated with Facial Nerve Decompression

Nicholas S Andresen, BA; Thomas JE Clark, MD; Daniel Q Sun, MD; Marlan R Hansen, MD; Erin M Shriver, MD

posted August 1, 2017

Initial Presentation

Chief Complaint

Facial droop and slurred speech

History of Present Illness

A 68-year-old man presented to the eye clinic with five days of right-sided facial droop, which was associated with the inability to fully close the right eye and slurred speech. Approximately two to three days before the onset of the facial droop, he noted a sharp, severe, retroauricular pain with intermittent radiation into the right side of his face. He also noted altered and diminished taste on the right side of his tongue. He denied any other preceding symptoms. He was evaluated at an outside hospital, where a head computed tomography (CT) was negative. He was then transferred to the University of Iowa Hospitals and Clinics (UIHC) with concern for acute cerebrovascular accident. Upon evaluation in the UIHC Emergency Department, an isolated facial nerve palsy was identified. He was diagnosed with Bell's palsy and started on oral prednisone (60 mg daily), lubricating eye drops, and ophthalmic ointment with a plan for outpatient follow-up with Ophthalmology and Otolaryngology.

Upon evaluation in the Oculoplastics clinic, he reported using tape to keep his right eye closed. He denied eye pain or diplopia but stated that the vision in his right eye was slightly blurred.

Past Ocular History

- ◆ Metallic, non-penetrating, corneal foreign body, Left eye

Past Medical History

- ◆ Non-contributory

Medications

- ◆ Prednisone, oral, 60 mg daily
- ◆ Erythromycin 0.5% ophthalmic ointment, 3 times daily, Right eye
- ◆ Preservative free artificial tears, 3 times daily, Right eye

Allergies

- ◆ No known allergies

Family History

- ◆ Non-contributory

Social History

- ◆ Non-contributory

Review of Systems

- ◆ Negative, except for as described in the history of present illness. No recent tick bites or rash. No vestibular symptoms.

Ocular Examination

Visual Acuity with correction (Snellen)

- ◆ Right eye: 20/30
- ◆ Left eye: 20/40 -1

Manifest Refraction

- ◆ Right eye: +1.50 sphere
- ◆ Left eye: +1.25 sphere

Ocular Motility and Alignment

- ◆ Full, both eyes
- ◆ Orthotropic

Intraocular Pressure (IOP)

- ◆ Right eye: 13 mmHg
- ◆ Left eye: 14 mmHg

Pupils

- ◆ Right eye: 3 mm in dark, 2 mm in light. Briskly reactive. No relative afferent pupillary defect (RAPD).
- ◆ Left eye: 3 mm in dark, 2 mm in light. Briskly reactive. No RAPD.

Confrontation Visual Fields

- ◆ Full, Both eyes

External Exam (figure 1)

- ◆ Right eye: complete right-sided facial paralysis, incomplete blink, strong Bell's phenomenon
- ◆ Left eye: normal

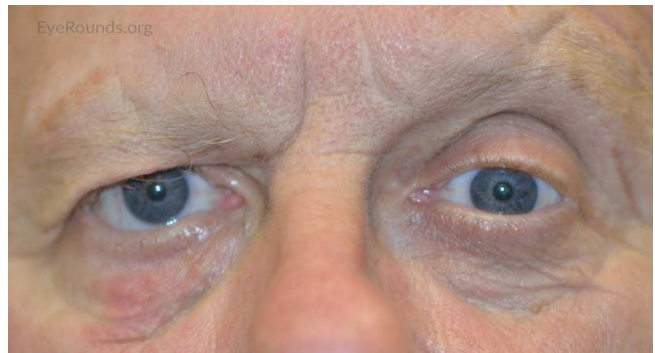

Figure 1. External photo demonstrates right-sided facial droop, brow ptosis, and lower eyelid ectropion.

Slit Lamp Examination

- ◆ Lids/Lashes
 - Right eye: upper eyelid retraction with mild lower eyelid ectropion
 - Left eye: normal
- ◆ Conjunctiva/Sclera
 - Right eye: minimally injected
 - Left eye: clear and quiet
- ◆ Cornea
 - Right eye: decreased tear meniscus, irregular tear film, diffuse superficial punctate keratitis (SPK), worse inferiorly with mild, diffuse stromal haze
 - Left eye: inferior SPK, faint, circular, subepithelial scar in superonasal periphery
- ◆ Anterior Chamber
 - Deep and quiet, both eyes
- ◆ Iris
 - Normal architecture, both eyes
- ◆ Lens
 - 1+ nuclear sclerosis, both eyes

Dilated Fundus Examination (DFE)

- ◆ Unremarkable, both eyes

Clinical Course

Upon evaluation in the Oculoplastics clinic, a video demonstrating the complete nature of the patient's facial nerve dysfunction was sent to the Otolaryngology resident on-call. The Otolaryngology team asked to see the patient immediately and electroneuronography (ENoG) and electromyography (EMG) were ordered to evaluate candidacy for surgical decompression of the facial nerve. ENoG revealed 100% loss of facial nerve function and EMG showed absent motor unit potential of the orbicularis oris and orbicularis oculi despite maximal effort. Right facial nerve decompression via a middle cranial fossa (MCF) approach was performed 12 days after the onset of symptoms. Following decompression, the facial nerve was found to be anatomically intact but it did not respond to electrical stimulation.

3 Month Post-Operative Visit

Figures 2 and 3

The patient continued to experience a significant degree of lagophthalmos and had to continue eyelid taping. He remained incapable of producing a complete blink or fully closing his right eye. Lower eyelid ectropion secondary to laxity was also present. Despite significant lagophthalmos, only minimal exposure keratopathy was present. At this point, the patient chose to defer placement of an eyelid weight so an external, stick-on weight was ordered instead.

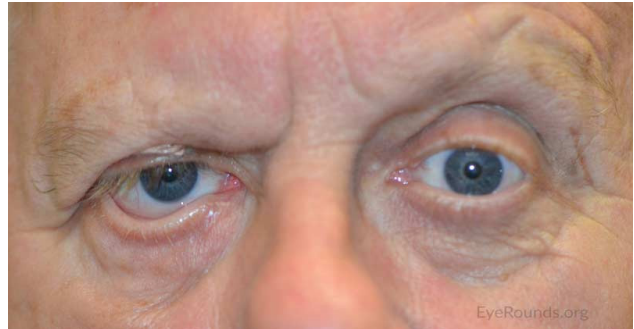

Figure 2. External photo at 3 month post-operative visit showing right brow ptosis and lower eyelid ectropion.

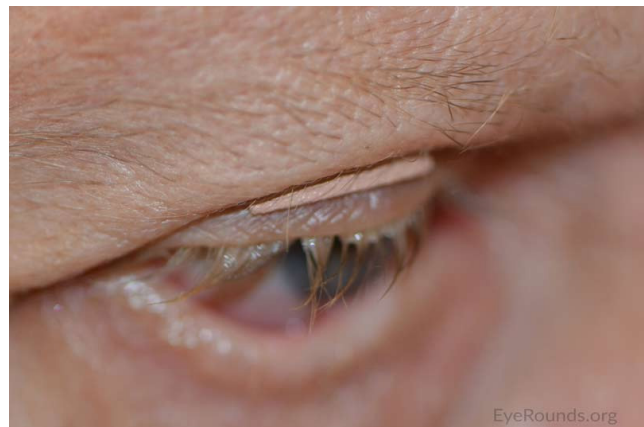

Figure 3. Lateral view of right eyelid with BlinkEze® eyelid weight in place.

6 Month Post-Operative Visit

When evaluated six months post-operatively, the patient had discontinued use of the weight as he felt his eyelid function had improved significantly. He also noted that he had begun to experience epiphora. On physical exam, lagophthalmos and ectropion were present but improved compared to his one month post-operative visit. No exposure keratopathy was present. The continued use of preservative-free artificial tears and lubricating eye gel at night was recommended.

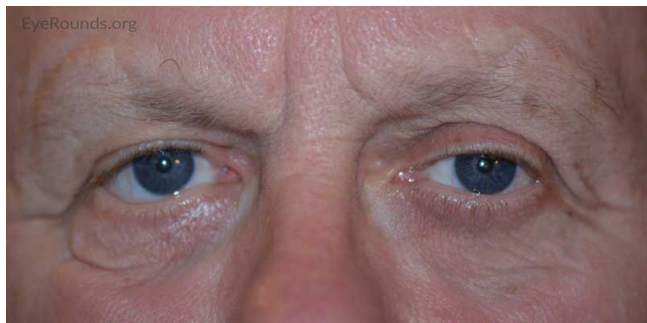

Figure 4. External photo at 6 month post-operative visit showing improved right brow ptosis and lower eyelid ectropion.

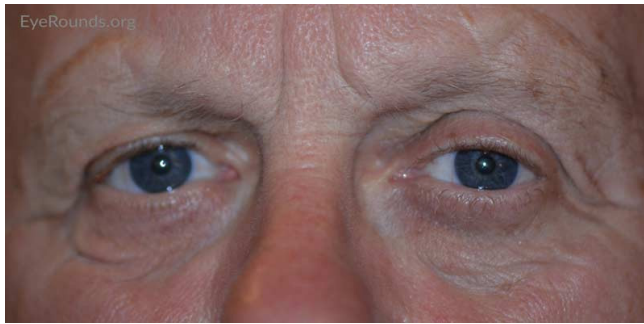

Figure 5. External photo at 10 month post-operative visit showing mild residual right brow ptosis and lower eyelid ectropion.

10 Month Post-Operative Visit

When asked, the patient was able to fully close the right eye, but he continued to have an incomplete reflexive blink. Lower eyelid laxity, ectropion, and epiphora were still present. No exposure keratopathy was noted.

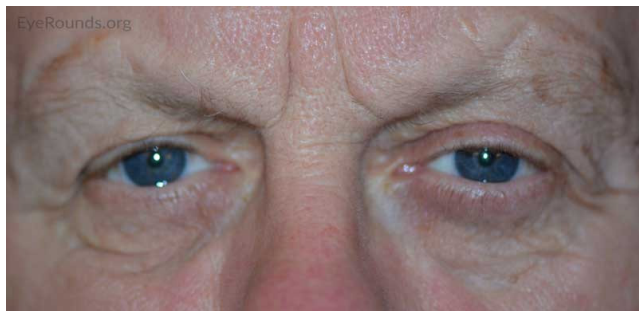

Figure 6. External photo at 18 month post-operative visit showing resolution of right brow ptosis and lower eyelid ectropion, as well as an increased tear lake height

18 Month Post-Operative Visit

The patient continued to experience epiphora. He demonstrated a full reflexive blink with good orbicularis oculi tone. There was only mild eyelid laxity remaining, with a high tear lake and no ectropion. No keratopathy was noted.

Diagnosis

Bell's palsy, status post (s/p) facial nerve decompression. Complete facial nerve paralysis was present upon presentation that improved to House-Brackmann Grade II paralysis one year post-operatively.

Discussion

Etiology and Clinical Features

For detailed information regarding the etiology and clinical features of Bell's palsy, please refer to the EyeRounds article Facial Nerve Palsy: Ocular Complications and Management[1] at eyerounds.org/cases/215-facial-nerve.htm

Care should be taken to differentiate Bell's palsy from Ramsey Hunt syndrome, which is characterized by otalgia and the presence of a vesicular rash on the postauricular skin, ear canal, or tympanic membrane [2]. Ramsey Hunt syndrome may also involve other cranial nerves, particularly the auditory and vestibular nerves leading to acute, unilateral, sensorineural hearing loss or vertigo, respectively. The natural history of Ramsey Hunt syndrome is different from that of Bell's palsy and requires different management.

Management of Bell's Palsy

Imaging and Initial Work-up

Patients with a history and physical exam highly suggestive of Bell's palsy may not always require magnetic resonance imaging (MRI) or computed tomography (CT). However, patients with otorrhea, vestibular complaints, or hearing loss should be evaluated with both MRI and high-resolution CT [2]. An atypical presentation, such as a slow onset of symptoms, recurrent episodes of acute paralysis, evidence of synkinesis, or a preceding facial twitch should also prompt imaging studies, as these symptoms may suggest an alternative diagnosis (e.g. tumor) [3]. Planned surgical decompression or persistent, severe paralysis after 6 months are also indications for imaging [2].

Further steps should be taken during the initial evaluation depending upon individual patient characteristics. For patients living in areas endemic for Lyme disease, serologic testing (IgM, IgG) should be obtained [2]. Patients with vestibular complaints require evaluation with an electronystagmogram (ENG), and those with complete facial nerve paralysis require electrophysiologic testing (EMG, ENoG) in order to assess candidacy for facial nerve decompression. Further details regarding these tests are beyond the scope of this discussion.

Steroids

The mainstay of acute treatment for Bell's palsy is early treatment with oral glucocorticoids for all patients [4-7]. Several double-blind, placebo-controlled, randomized trials support the effectiveness of early, short-term, oral glucocorticoid therapy for all patients within 3-7 days of symptom onset, demonstrating a quicker and more complete recovery of facial nerve function [8-13]. Patients in these trials were treated with 10-day courses of oral prednisone 50-80 mg daily, with or without a taper after day five of treatment. There is no evidence to support one particular steroid-dosing regimen over another. At our institution, patients who present within 7 days of symptom onset are treated with a 10-14-day course of 60-80 mg/day of oral prednisone.

Antivirals

Bell's palsy was first described as a facial nerve palsy without a known etiology [14]. However, recent studies indicate that herpes simplex virus (HSV) may play a role in the pathogenesis of Bell's palsy. Evidence of HSV type 1 (HSV-1) infection has been found in patients with Bell's palsy, [15-18] and HSV-1 inoculation has been shown to cause

facial paralysis in mice [19 ,20]. Consequently, antiviral therapy has been proposed as one potential treatment for Bell's palsy.

Antiviral therapy may be used alone or in addition to glucocorticoid therapy. Data supporting the use of antiviral therapy are mixed. Two large clinical trials have been performed that randomized 496 and 829 patients, respectively, to receive placebo, steroids alone, antivirals alone (acyclovir or valacyclovir), or steroids and antivirals [11 ,12]. Both studies showed no significant difference in the recovery of facial nerve function between groups that received placebo or antivirals alone. Similarly, no difference was found between groups that received steroids alone or steroids and antivirals. However, both of these studies included patients with all degrees of facial weakness. It is known that patients with mild facial paresis have a high rate of recovery without treatment. Thus, any benefit of antiviral therapy for patients with more severe paresis or paralysis may have been masked by the subset of patients with mild degrees of weakness expected to demonstrate recovery even without treatment.

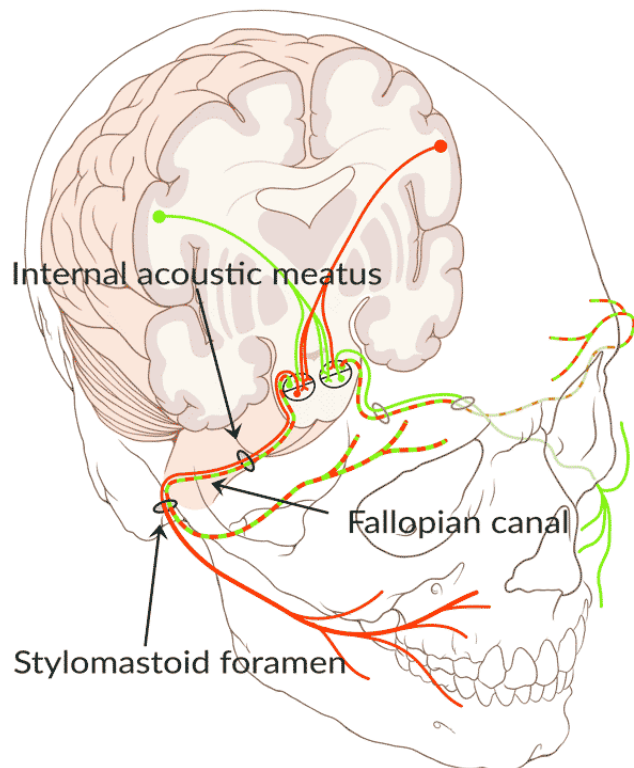
Several smaller trials have demonstrated a trend towards benefit with antiviral therapy [8 ,13], and one trial showed a benefit to receiving both antiviral (valacyclovir) and steroid therapy compared to steroids alone [9]. Furthermore, a 2015 Cochrane review that pooled results from 10 trials, including all of the studies mentioned above, found antiviral and steroid therapy to be superior to steroid therapy alone [21]. Importantly, no serious adverse effects have been documented in any study using antivirals for Bell's palsy to date. Patients who present to our institution within 7 days of symptom onset are treated with valacyclovir 500 mg orally 3 times per day for 10 days in addition to steroid therapy.

Physical Therapy

Physical therapy is another potential treatment for facial paresis that includes exercises, massage, electrical stimulation, acupuncture, and biofeedback. A recent Cochrane review found only twelve low to moderate quality studies that evaluated the efficacy of physical therapy for facial paresis due to Bell's palsy [22]. One of these studies showed that facial exercises reduce the rate of synkinesis (involuntary facial movement that occurs with voluntary movement of a different facial muscle group) at three months [23]. Another trial showed some benefit for facial exercises for patients that have had persistent nerve palsy for nine months or longer [24]. While physical therapy may provide some benefit for patients, the evidence supporting its use remains relatively weak, and it should only be considered as an adjuvant therapy. At our institution, practice patterns vary in term of the use of physical therapy. Electrical physical therapy is not used, as it may cause an increased rate of complications [22].

Facial Nerve Decompression

The facial nerve enters the temporal bone through the internal acoustic meatus and travels through Fallopian canal of the temporal bone before exiting the skull via



By Patrick J. Lynch, medical illustrator (Patrick J. Lynch, medical illustrator) [CC BY 2.5 (<http://creativecommons.org/licenses/by/2.5>)], via Wikimedia Commons

Figure 7. Route of the facial nerve as it enters the temporal bone through the internal acoustic meatus, travels through the Fallopian canal, and exits via the stylomastoid foramen. The Fallopian canal can be further divided into labyrinthine, tympanic, and mastoidal segments (not shown here). Image by Patrick J. Lynch, medical illustrator [CC BY 2.5 (creativecommons.org/licenses/by/2.5)], via Wikimedia Commons

the stylomastoid foramen (Figure 7). The Fallopian canal contains labyrinthine, tympanic, and mastoidal segments. It is believed that Bell's palsy is related to neural edema and compression within the labyrinthine segment of the Fallopian canal. Thus, decompression of the labyrinthine and perigeniculate segments of the facial nerve has been proposed as one potential treatment for Bell's palsy (Figure 8).

Controversy currently exists as to the role of surgical decompression due to good outcomes with observation alone in patients with incomplete paralysis, the lack of large trials, and the complications associated with surgical intervention [5]. Consequently, surgical therapy is not currently recommended for the majority of patients with Bell's palsy [5 ,25 ,26].

Surgical intervention is reserved for patients who have a poor prognosis with observation or medical therapy alone. One study found that patients with complete loss of facial nerve function, 90% or greater loss on ENoG testing, and absent volitional nerve activity on EMG have a 58% chance of a poor outcome (House-Brackmann III or IV [27]) at 7 months [28]. Several other studies have also supported the prognostic value of ENoG testing and the association

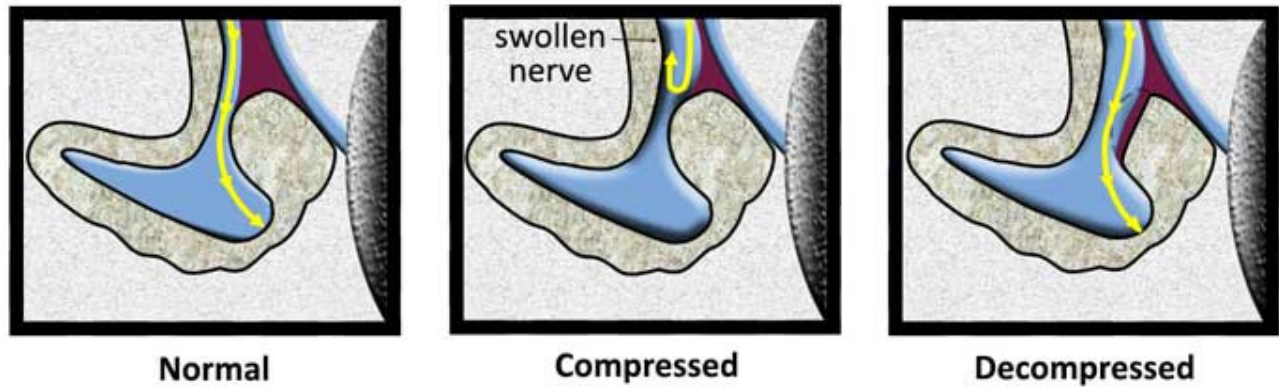


Figure 8. Schematic showing facial nerve decompression. Panel A shows a normal facial nerve within the Fallopian canal of the temporal bone. Panel B shows the facial nerve compressed within the labyrinthine segment of the Fallopian canal. Panel C shows the facial nerve after decompression of the labyrinthine segment of the Fallopian canal.

of 90% or greater functional loss on ENoG testing with poor outcomes with medical management alone [29, 30]. Surgical intervention may be beneficial for these patients in improving the likelihood of recovery of good facial nerve function.

Facial nerve decompression has been described via either a transmastoid or middle cranial fossa (MCF) approach. The MCF approach has demonstrated the greatest promise, [28] as it provides access for decompression of the labyrinthine segment of the facial nerve. Transmastoid approaches do not provide access to this region of the Fallopian canal and are not currently used for the treatment of Bell's palsy. One

multi-center, case-control study demonstrated near complete recovery of facial nerve function (House-Brackmann I-II) for 31 of 34 (91%) patients treated with facial nerve decompression via an MCF approach as compared to 15 of 36 (42%) patients treated with steroids alone [28]. All patients who underwent surgery had >90% reduction in amplitude on ENoG, absent voluntary facial nerve activity, and were able to undergo surgery within 3-14 days of symptom onset. The efficacy of a MCF approach has also been validated by an additional report [31].

Awareness of the window of opportunity for facial nerve decompression is critical. Providers in primary care clinics,

<p>Epidemiology [36-38]</p> <ul style="list-style-type: none"> ◆ Incidence (estimated) 20–42 per 100,000 annually ◆ Lifetime risk, 1 in 65 ◆ Highest incidence in ages 39 and 50 years ◆ Higher incidence in summer ◆ Recurrence more likely in first 1.5 years after first incidence occurrence 	<p>Signs and Symptoms of Bell's Palsy</p> <ul style="list-style-type: none"> ◆ Acute onset (<24-48 hours) of unilateral facial weakness or paralysis ◆ Loss of forehead wrinkling ◆ Brow ptosis ◆ Incomplete eyelid closure with possible exposure keratopathy ◆ Drooping of the mouth with possible drooling ◆ Absence of pain, vesicles, dizziness or hearing loss
<p>Work-up for Facial Nerve Paralysis</p> <p>Imaging (CT or MRI)</p> <ul style="list-style-type: none"> ◆ Clinical course, signs, and symptoms inconsistent with classic Bell's palsy ◆ Waxing and waning course ◆ Presence of otorrhea, vestibular complaints, or hearing loss ◆ Severe paralysis for >6 months ◆ Planning for surgical decompression <p>Electrophysiologic testing (ENG, EMG, or ENoG)</p> <ul style="list-style-type: none"> ◆ Vestibular symptoms or complete paralysis <p>Serologic Lyme disease testing</p> <ul style="list-style-type: none"> ◆ Vestibular symptoms or complete paralysis 	<p>Treatment Recommendations</p> <ul style="list-style-type: none"> ◆ For patients presenting 7-10 days after symptom onset with stable or improving motor function: no treatment ◆ For patients presenting within 7 days of symptom onset: Steroid (oral prednisone, 60-80 mg/day, 10-14 days) and antiviral (oral valacyclovir, 500 mg, 3 times per day for 10 days) ◆ Electrodiagnostic testing is unnecessary for patients with voluntary facial movements (paresis) ◆ Patients with complete paralysis should be referred for electrodiagnostic testing in order to evaluate candidacy for facial nerve decompression

emergency departments, and eye clinics must recognize that patients with complete or near-complete facial nerve paralysis need urgent referral so that appropriate diagnostic testing (ENoG and EMG) may be attained and surgical intervention completed within 14 days of symptom onset [28].

All patients with complete facial nerve paralysis should be referred to a center with expertise in MCF surgery [2]. Identifying and maintaining appropriate referral pathways is important as the number of neuro-otologists who regularly perform procedures via the MCF approach remains limited [32]. Additionally, the MCF approach is a technically demanding procedure that can be associated with severe complications (e.g. cerebrospinal fluid leak, hearing loss, facial nerve injury) [33-35]. These factors should be considered and discussed when choosing to proceed with facial nerve decompression.

References

- Welder JD, Allen RC, Shriver EM. Facial Nerve Palsy: Ocular Complications and Management. EyeRounds.org. Posted July 14, 2015; Available from: www.EyeRounds.org/cases/215-facial-nerve.htm. 2015.
- Gantz BJ, Sun DQ, Roche JP. Idiopathic Facial Paralysis and Herpes Zoster Oticus. *Glasscock-Shambaugh Surgery of the Ear*. 7th ed; 2017.
- Gilden DH. Clinical practice. Bell's Palsy. *N Engl J Med* 2004;351(13):1323-1331. PubMed.gov/15385659
- Gronseth GS, Paduga R, American Academy of N. Evidence-based guideline update: steroids and antivirals for Bell palsy: report of the Guideline Development Subcommittee of the American Academy of Neurology. *Neurology* 2012;79(22):2209-2213. PubMed.gov/23136264
- Baugh RF, Basura GJ, Ishii LE, Schwartz SR, Drumheller CM, Burkholder R, Deckard NA, Dawson C, Driscoll C, Gillespie MB, Gurgel RK, Halperin J, Khalid AN, Kumar KA, Micco A, Munsell D, Rosenbaum S, Vaughan W. Clinical practice guideline: Bell's palsy. *Otolaryngol Head Neck Surg* 2013;149(3 Suppl):S1-27. PubMed.gov/24189771
- de Almeida JR, Guyatt GH, Sud S, Dorion J, Hill MD, Kolber MR, Lea J, Reg SL, Somogyi BK, Westerberg BD, White C, Chen JM, Bell Palsy Working Group CSOH, Neck S, Canadian Neurological Sciences F. Management of Bell palsy: clinical practice guideline. *CMAJ* 2014;186(12):917-922. PubMed.gov/24934895
- Schwartz SR, Jones SL, Getchius TS, Gronseth GS. Reconciling the clinical practice guidelines on Bell's palsy from the AAO-HNSF and the AAN. *Neurology* 2014;82(21):1927-1929. PubMed.gov/24793182
- Adour KK, Ruboyianes JM, Von Doersten PG, Byl FM, Trent CS, Quesenberry CP, Jr., Hitchcock T. Bell's palsy treatment with acyclovir and prednisone compared with prednisone alone: a double-blind, randomized, controlled trial. *Ann Otol Rhinol Laryngol* 1996;105(5):371-378. PubMed.gov/8651631
- Hato N, Yamada H, Kohno H, Matsumoto S, Honda N, Gyo K, Fukuda S, Furuta Y, Ohtani F, Aizawa H, Aoyagi M, Inamura H, Nakashima T, Nakata S, Murakami S, Kiguchi J, Yamano K, Takeda T, Hamada M, Yamakawa K. Valacyclovir and prednisolone treatment for Bell's palsy: a multicenter, randomized, placebo-controlled study. *Otol Neurotol* 2007;28(3):408-413. PubMed.gov/17414047
- Kawaguchi K, Inamura H, Abe Y, Kosu H, Takashita E, Muraki Y, Matsuzaki Y, Nishimura H, Ishikawa H, Fukao A, Hongo S, Aoyagi M. Reactivation of herpes simplex virus type 1 and varicella-zoster virus and therapeutic effects of combination therapy with prednisolone and valacyclovir in patients with Bell's palsy. *Laryngoscope* 2007;117(1):147-156. PubMed.gov/17202945
- Sullivan FM, Swan IR, Donnan PT, Morrison JM, Smith BH, McKinstry B, Davenport RJ, Vale LD, Clarkson JE, Hammersley V, Hayavi S, McAteer A, Stewart K, Daly F. Early treatment with prednisolone or acyclovir in Bell's palsy. *N Engl J Med* 2007;357(16):1598-1607. PubMed.gov/17942873
- Engström M, Berg T, Stjernquist-Desatnik A, Axelsson S, Pitkäranta A, Hultcrantz M, Kanerva M, Hanner P, Jonsson L. Prednisolone and valaciclovir in Bell's palsy: a randomised, double-blind, placebo-controlled, multicentre trial. *Lancet Neurol* 2008;7(11):993-1000. PubMed.gov/18849193
- Yeo SG, Lee YC, Park DC, Cha CI. Acyclovir plus steroid vs steroid alone in the treatment of Bell's palsy. *Am J Otolaryngol* 2008;29(3):163-166. PubMed.gov/18439948
- Bell C. On the Nerves; Giving an Account of Some Experiments on Their Structure and Functions, Which Lead to a New Arrangement of the System. *Philosophical Transactions of the Royal Society of London* 1821;111:398-424.
- Burgess RC, Michaels L, Bale JF, Jr., Smith RJ. Polymerase chain reaction amplification of herpes simplex viral DNA from the geniculate ganglion of a patient with Bell's palsy. *Ann Otol Rhinol Laryngol* 1994;103(10):775-779. PubMed.gov/7944168
- Murakami S, Mizobuchi M, Nakashiro Y, Doi T, Hato N, Yanagihara N. Bell palsy and herpes simplex virus: identification of viral DNA in endoneurial fluid and muscle. *Ann Intern Med* 1996;124(1 Pt 1):27-30. PubMed.gov/7503474
- Furuta Y, Fukuda S, Chida E, Takasu T, Ohtani F, Inuyama Y, Nagashima K. Reactivation of herpes simplex virus type 1 in patients with Bell's palsy. *J Med Virol* 1998;54(3):162-166. PubMed.gov/9515763
- Lazarini PR, Vianna MF, Alcantara MP, Scalia RA, Caiaffa Filho HH. Herpes simplex virus in the saliva of peripheral Bell's palsy patients. *Braz J Otorhinolaryngol* 2006;72(1):7-11. PubMed.gov/16917546
- Liston SL, Kleid MS. Histopathology of Bell's palsy. *Laryngoscope* 1989;99(1):23-26. PubMed.gov/2642582
- Sugita T, Murakami S, Yanagihara N, Fujiwara Y, Hirata Y, Kurata T. Facial nerve paralysis induced by herpes simplex virus in mice: an animal model of acute and

- transient facial paralysis. *Ann Otol Rhinol Laryngol* 1995;104(7):574-581. [PubMed.gov/7598372](https://pubmed.ncbi.nlm.nih.gov/7598372)
21. Gagyor I, Madhok VB, Daly F, Somasundara D, Sullivan M, Gammie F, Sullivan F. Antiviral treatment for Bell's palsy (idiopathic facial paralysis). *Cochrane Database Syst Rev* 2015;10.1002/14651858.CD001869. pub8(11):CD001869. [PubMed.gov/26559436](https://pubmed.ncbi.nlm.nih.gov/26559436)
 22. Teixeira LJ, Valbuza JS, Prado GF. Physical therapy for Bell's palsy (idiopathic facial paralysis). *Cochrane Database Syst Rev* 2011;10.1002/14651858.CD006283. pub3(12):CD006283. [PubMed.gov/22161401](https://pubmed.ncbi.nlm.nih.gov/22161401)
 23. Wen C-M, Zhang B-C. [Effect of rehabilitation training at different degree in the treatment of idiopathic facial palsy: a randomized controlled comparison] (in Chinese). *Zhongguo Linchuang Kangfu [Chinese Journal of Clinical Rehabilitation]* 2004;8(13):2446-2447.
 24. Beurskens CH, Heymans PG. Positive effects of mime therapy on sequelae of facial paralysis: stiffness, lip mobility, and social and physical aspects of facial disability. *Otol Neurotol* 2003;24(4):677-681. [PubMed.gov/12851564](https://pubmed.ncbi.nlm.nih.gov/12851564)
 25. Grogan PM, Gronseth GS. Practice parameter: Steroids, acyclovir, and surgery for Bell's palsy (an evidence-based review): report of the Quality Standards Subcommittee of the American Academy of Neurology. *Neurology* 2001;56(7):830-836. [PubMed.gov/11294918](https://pubmed.ncbi.nlm.nih.gov/11294918)
 26. McAllister K, Walker D, Donnan PT, Swan I. Surgical interventions for the early management of Bell's palsy. *Cochrane Database Syst Rev* 2013;10.1002/14651858.CD007468.pub3(10):CD007468. [PubMed.gov/24132718](https://pubmed.ncbi.nlm.nih.gov/24132718)
 27. House JW, Brackmann DE. Facial nerve grading system. *Otolaryngol Head Neck Surg* 1985;93(2):146-147. [PubMed.gov/3921901](https://pubmed.ncbi.nlm.nih.gov/3921901)
 28. Gantz BJ, Rubinstein JT, Gidley P, Woodworth GG. Surgical management of Bell's palsy. *Laryngoscope* 1999;109(8):1177-1188. [PubMed.gov/10443817](https://pubmed.ncbi.nlm.nih.gov/10443817)
 29. Takemoto N, Horii A, Sakata Y, Inohara H. Prognostic factors of peripheral facial palsy: multivariate analysis followed by receiver operating characteristic and Kaplan-Meier analyses. *Otol Neurotol* 2011;32(6):1031-1036. [PubMed.gov/21725266](https://pubmed.ncbi.nlm.nih.gov/21725266)
 30. Byun H, Cho YS, Jang JY, Chung KW, Hwang S, Chung WH, Hong SH. Value of electroneurography as a prognostic indicator for recovery in acute severe inflammatory facial paralysis: a prospective study of Bell's palsy and Ramsay Hunt syndrome. *Laryngoscope* 2013;123(10):2526-2532. [PubMed.gov/23918352](https://pubmed.ncbi.nlm.nih.gov/23918352)
 31. Kim IS, Shin SH, Kim J, Lee WS, Lee HK. Correlation between MRI and operative findings in Bell's palsy and Ramsay Hunt syndrome. *Yonsei Med J* 2007;48(6):963-968. [PubMed.gov/18159587](https://pubmed.ncbi.nlm.nih.gov/18159587)
 32. Smouha E, Toh E, Schaitkin BM. Surgical treatment of Bell's palsy: current attitudes. *Laryngoscope* 2011;121(9):1965-1970. [PubMed.gov/22024853](https://pubmed.ncbi.nlm.nih.gov/22024853)
 33. Glasscock ME, McKennan KX, Levine SC. Acoustic neuroma surgery: the results of hearing conservation surgery. *Laryngoscope* 1987;97(7 Pt 1):785-789. [PubMed.gov/3600130](https://pubmed.ncbi.nlm.nih.gov/3600130)
 34. Shelton C, Brackmann DE, House WF, Hitselberger WE. Middle fossa acoustic tumor surgery: results in 106 cases. *Laryngoscope* 1989;99(4):405-408. [PubMed.gov/2927217](https://pubmed.ncbi.nlm.nih.gov/2927217)
 35. Brackmann DE, House JR, 3rd, Hitselberger WE. Technical modifications to the middle fossa craniotomy approach in removal of acoustic neuromas. *Am J Otol* 1994;15(5):614-619. [PubMed.gov/8572061](https://pubmed.ncbi.nlm.nih.gov/8572061)
 36. Campbell KE, Brundage JF. Effects of climate, latitude, and season on the incidence of Bell's palsy in the US Armed Forces, October 1997 to September 1999. *Am J Epidemiol* 2002;156(1):32-39. [PubMed.gov/12076886](https://pubmed.ncbi.nlm.nih.gov/12076886)
 37. Rowlands S, Hooper R, Hughes R, Burney P. The epidemiology and treatment of Bell's palsy in the UK. *Eur J Neurol* 2002;9(1):63-67. [PubMed.gov/11784378](https://pubmed.ncbi.nlm.nih.gov/11784378)
 38. Zhao H, Zhang X, Tang YD, Zhu J, Wang XH, Li ST. Bell's Palsy: Clinical Analysis of 372 Cases and Review of Related Literature. *Eur Neurol* 2017;77(3-4):168-172. [PubMed.gov/28118632](https://pubmed.ncbi.nlm.nih.gov/28118632)

Citing this Article

Andresen NS, Clark TJE, Sun DQ, Hansen MR, Shriver EM. Bell's Palsy Treated With Facial Nerve Decompression, EyeRounds.org. posted August 1, 2017; Available from: [EyeRounds.org/cases/256-Bells-Palsy.htm](https://www.eyerounds.org/cases/256-Bells-Palsy.htm)

last updated: 08/10/2017

Vertical Oscillopsia: A Case of Superior Oblique Myokymia

Lucas T. Lenci MD, Elizabeth A. Thompson, Matthew J. Thurtell MBBS

January 4, 2016

INITIAL PRESENTATION

Chief Complaint: "Shaking vision in my left eye"

History of Present Illness (HPI)

A 39-year-old male presents to our general ophthalmology clinic for a third opinion regarding intermittent episodes of objects bouncing up and down in his vision in his left eye. The episodes have been occurring for the past two months and last for several seconds to minutes. Bright lights, caffeine, and looking down to read seem to exacerbate these episodes. At times, these symptoms have made it difficult for him to work. He recalls having similar difficulties with his vision 3 years prior, but his symptoms resolved within a week after their onset. He denies double vision, redness, or pain with eye movement.

Past Ocular History

- ◆ Refractive error, contact lens wearer since age 14
- ◆ No eye trauma or surgeries

Past Medical History

- ◆ Guillain-Barré Syndrome (GBS) and subsequent pulmonary embolism, which required hospitalization for 4 months, 15 years prior to presentation
- ◆ Obstructive sleep apnea

Past Surgical History

- ◆ Cholecystectomy
- ◆ Motorcycle accident in 1994 with significant trauma to his leg and several orthopedic reconstructions of the left hip and leg

Medications: Fluticasone 50 mcg nasal spray

Allergies: None

Family History: Brother with Charcot-Marie-Tooth syndrome

Social History

- ◆ Significant smoking history; typically smoked 1-1.5 packs per day for 20-25 years, but at times, up to 3 packs per day; currently smoking 4-5 cigarettes per day
- ◆ No alcohol or illicit drug use

Review of Systems: Negative except as listed in HPI

OCULAR EXAMINATION

Visual Acuity

- ◆ Right eye (OD): 20/15
- ◆ Left eye (OS): 20/20-2

Ocular Motility

Full, no ocular misalignment on cross cover testing. No nystagmus. Intermittent, low-amplitude, vertical-torsional movements were observed at the slit lamp in the left eye. [Video 1, see vimeo.com/149334342]

Intraocular Pressure (IOP)

- ◆ OD: 12
- ◆ OS: 10

Pupils

- ◆ OD: 5 mm in dark → 4 mm in light, no afferent pupillary defect (RAPD)
- ◆ OS: 5 mm in dark → 3 mm in light, no RAPD

Confrontation visual fields: Full to counting fingers both eyes (OU)

Slit lamp exam

Both eyes (OU)

- ◆ External/Eyelid: Meibomian gland dysfunction, no blepharospasm, no facial spasms
- ◆ Conjunctiva: Clear and quiet
- ◆ Cornea: Clear
- ◆ Anterior chamber: Deep and quiet
- ◆ Iris: Normal architecture
- ◆ Lens: Clear

Dilated fundus examination (DFE)

OU: Normal apart from intermittent vertical-torsional movements of fundus OS

DIAGNOSIS

Superior oblique myokymia

CLINICAL COURSE

Based on the patient's history of intermittent, brief episodes of vertical oscillopsia and the low-amplitude vertical-torsional movements of the left eye on examination, the patient was diagnosed with superior oblique myokymia. Since the patient had previously sought the opinion of two other eye care providers, he was particularly pleased to learn of a diagnosis and to hear that treatment options were available. He was started on carbamazepine 100 mg orally three times a day and scheduled to follow-up in the neuro-ophthalmology clinic.

He returned 1 month later with significant improvement of his symptoms. He experienced several side effects (drows-

iness, dizziness, and upset stomach) while taking carbamazepine 100 mg three times a day, so he had reduced the dose. When he returned for his follow-up, he was taking 50 mg two times a day, which he felt provided 70% relief of symptoms. There was further discussion with the patient regarding other treatment options and he expressed interest in trying a topical agent. He was started on 1 drop of timolol in the left eye twice a day. He was told that if the timolol was effective, the carbamazepine could be tapered to an even lower dose or perhaps discontinued. An MRI of the brain with contrast and an MRA of the head were recommended to evaluate for an underlying structural lesion—most commonly, a small vascular loop compressing the left fourth nerve. The MRI and MRA were normal and did not show any vascular abnormalities. The patient was scheduled to return for routine follow-up in 4-6 months.

DISCUSSION

Superior oblique myokymia (SOM) is an uncommon disorder characterized by rapid, low-amplitude, high frequency contractions of the superior oblique muscle, which results in monocular vertical-torsional oscillopsia. Duane first described the disease in 1906 and he termed it a 'unilateral rotatory nystagmus' (1). In 1970, Hoyt and Keane were the first to use the term superior oblique myokymia after describing the clinical presentations of five patients (2). Affected patients are typically healthy, young to middle-aged adults without ocular or neurologic disease. Patients may report visual disturbances such as spontaneous image tilt, a fluttering or trembling sensation, and recurrent episodes of vertical-torsional oscillopsia, often described as "shaking," "shimmering," "vibrating," "jiggling," "dancing," or "jumping" (1, 2, 3, 4). The episodes are brief, only lasting a few seconds to minutes, and recur sporadically. A patient may experience multiple episodes in one day for several weeks and then have symptoms disappear suddenly. The symptoms may recur weeks, months, or even years later, with a different frequency and duration (2). The characteristic symptoms allow for the diagnosis to be strongly suspected based on the history alone. The pathognomonic eye movements can often be observed with mild to moderate magnification at the slit lamp, although it is relatively uncommon to see these movements in clinic. The movements can occasionally be elicited by having the patient gaze in the direction of action of the superior oblique muscle—down and in (3, 5, 6).

The pathogenesis of SOM remains uncertain, although several mechanisms have been proposed (2, 7, 8, 9). At present, the pathogenesis is thought to be similar to that of other paroxysmal cranial nerve disorders (such as trigeminal neuralgia and hemifacial spasm) and due to compression of the nerve by a vascular loop near the nerve root exit zone (10). Vascular compression is defined by the absence of a detectable layer of cerebrospinal fluid between the fourth nerve and an adjacent blood vessel (typically a branch of the superior cerebellar or posterior cerebral artery) most easily seen on thinly sliced (1-2 mm) MRI images (6, 10). SOM can occasionally be caused by a structural lesion (e.g., tumor) or brainstem demyelination

(8, 10, 11, 12, 13, 14). Although an underlying structural lesion is not often identified, most neuro-ophthalmologists will recommend an MRI with and without contrast and, if available, an MR angiogram with contrast to evaluate for an underlying structural lesion and possible vascular compression of the fourth nerve (3).

Treatment

The vast majority of SOM cases follow a benign, relapsing and remitting course (2, 3, 4, 8, 15). In the setting of normal neuro-imaging, observation and reassurance may be appropriate for patients with mild or infrequent symptoms. For patients with persistent or bothersome symptoms, a variety of oral and topical medications may be considered (4). Carbamazepine provides symptomatic improvement in the majority of patients (5, 15). However, it is often poorly tolerated and has potentially severe adverse effects including leukopenia, acute renal failure, thromboembolism, and arrhythmias (4, 5, 7, 16). For this reason, some have proposed using gabapentin as a first line therapy, given the improved tolerability and safer side-effect profile (6, 17). Many other drugs, including oxcarbazepine, phenytoin, clonazepam, baclofen, oral and topical beta-blockers, mirtazapine, and memantine have been tried with varying degrees of success (3, 4, 5, 6, 7, 8, 16, 17, 18, 19). Botulinum toxin injection into the superior oblique muscle has also been proposed as a treatment, but provides only temporary relief and carries a risk of affecting other extraocular muscles (20).

Surgical intervention is reserved for patients with intolerable symptoms who fail to get an adequate response to medical management (5, 20). The first surgical treatments attempted were tenotomy or complete severance of the superior oblique tendon with subsequent recession (reattachment of the eye muscle at a different location to weaken its action) and myectomy—removal of a portion of the muscle belly of the ipsilateral inferior oblique to weaken its action (1, 2, 5, 21). Other studies report a benefit from tenectomy or partial severance of the superior oblique tendon followed by myectomy of the ipsilateral inferior oblique. While this approach is typically very successful in eliminating oscillopsia, it may produce an iatrogenic superior oblique palsy in about a third of patients. Prism correction may alleviate this complication (8, 21, 22, 23). The Harada Ito procedure has also been used to treat SOM (24). In patients with intractable symptoms who have evidence of vascular compression of the fourth nerve on imaging, microvascular decompression of the fourth nerve could be considered as a last resort (25, 26, 27, 28).

Summary

A 39-year-old healthy male reported having episodic oscillopsia lasting for seconds to minutes for the previous two months. He recalled having similar episodes three years prior to presentation with spontaneous resolution. On slit-lamp examination, low amplitude and high frequency vertical-torsional movements were noted in the left eye, consistent with superior oblique myokymia. In most patients, superior oblique myokymia is a benign, relapsing

and remitting condition. Neuroimaging is usually obtained to evaluate for an underlying structural lesion. Superior oblique myokymia often responds to oral medications, such as carbamazepine. Topical beta-blockers have also been used with varying degrees of success. Surgical treatments, such as strabismus surgery and microvascular decompression of the fourth nerve, are reserved for patients with severe and intractable symptoms.

Differential Diagnosis

- ◆ Monocular nystagmus
- ◆ Heimann-Bielschowsky phenomenon
- ◆ Voluntary nystagmus
- ◆ Blepharospasm

<p>EPIDEMIOLOGY</p> <ul style="list-style-type: none"> ◆ Typically, young to middle-aged otherwise healthy adults ◆ Men and women appear to be equally affected ◆ May have a history of mild ocular, orbital, or head trauma 	<p>SIGNS</p> <ul style="list-style-type: none"> ◆ Unilateral, intermittent, vertical-torsional eye movements that occur for seconds to minutes at a time ◆ Not always seen in clinic, but may be appreciated using magnification with a slit lamp or 20 D lens ◆ Movements classically precipitated by downward and inward movement of affected eye
<p>SYMPTOMS</p> <ul style="list-style-type: none"> ◆ Recurrent brief episodes of vertical-torsional oscillopsia, often described as "shaking", "shimmering", "quivering", "vibrating", "jiggling", or "jumping" images ◆ Episodic image tilt in one eye ◆ Intermittent vertical or mixed vertical-torsional diplopia ◆ Reported trigger factors and associations: stress, fatigue, alcohol, caffeine, nicotine, fluorescent lighting 	<p>TREATMENT</p> <p>Observation and reassurance</p> <p>Consider obtaining MRI brain and MRA head</p> <p>Medical management</p> <ul style="list-style-type: none"> ◆ Carbamazepine <ul style="list-style-type: none"> ○ Start at 100 mg orally twice daily ○ Titrate up to 200 mg orally three times daily, as tolerated ◆ Gabapentin <ul style="list-style-type: none"> ○ Starting at 100 mg orally daily or twice daily ○ Effective dose range: 300-600 mg daily, but 600-900 mg may be required in some cases ◆ Topical beta-blocker <ul style="list-style-type: none"> ○ 1-2 drops daily in the affected eye ◆ Others: Oxcarbazepine, phenytoin, clonazepam, baclofen, mirtazapine, and memantine <p>Surgical Intervention</p> <ul style="list-style-type: none"> ◆ Strabismus surgery ◆ Microvascular decompression of fourth nerve

References

1. Duane A. Unilateral rotary nystagmus. *Trans Am Ophthalmol Soc* 1906;11(Pt 1):63-67.
2. Hoyt WF, Keane JR. Superior Oblique Myokymia. *Arch Ophthalmol* 1970;84(4):461-467.
3. Foroozan R, Buono LM, Sergott RC, and Kawasaki A. Jumping Jack Flash. *Surv Ophthalmol* 2006;51(1):63-67.
4. Williams PE, Purvin VA, and Kawasaki A. Superior oblique myokymia: Efficacy of medical treatment. *J AAPOS* 2007;11(3):254-257.
5. Susac JO, Smith JL, Schatz NF. Superior oblique myokymia. *Arch Neurol* 1973;29(6):432-434.
6. Kattah JC and FitzGibbon EJ. Superior Oblique Myokymia. *Current Neurology and Neuroscience Reports* 2003;3(5):395-400.
7. Wu L, Tsai T, Hu F. Treatment of superior oblique myokymia with oxcarbazepine. *Taiwan J Ophthalmol* 2014;4:49-51.
8. Brazis PW, Miller NR, Henderer JD, and Lee AG. The Natural History and Results of Treatment of Superior Oblique Myokymia. *Arch Ophthalmol* 1994;112(8):1063-1067.

9. Breen LA, Gutman L, Riggs JE. Superior Oblique myokymia. A misnomer. *J Clin Neuroophthalmol* 1983;3(2):131-32.
10. Hashimoto M, Ohtsuka K, and Hoyt WF. Vascular Compression as a Cause of Superior Oblique Myokymia Disclosed by Thin-Slice Magnetic Resonance Imaging. *Am J Ophthalmol* 2001;131(5):676-677.
11. Mehta AM, Demer JL. Magnetic resonance imaging of the superior oblique muscle in superior oblique myokymia. *J Pediatr Ophthalmol Strabismus* 1994;31(6):378-383.
12. Geis TC, Newman NK, Dawson RC. Superior oblique myokymia associated with a dural arteriovenous fistula. *J Neuroophthalmol* 1996;16(1):41-43.
13. Meyers C, Murphy MA. Superior oblique myokymia following endoscopic arterial ligation for epistaxis. *J Neuroophthalmol* 2010;30(2):169.
14. Abhinav K, Park ND, Patel NK. Trochlear myokymia secondary to cerebellopontine angle arachnoid cyst. *Br J Neurosurg* 2012;26(5):754-755.
15. Rosenberg ML, Glaser JS. Superior oblique myokymia. *Ann Neurol* 1983;13(6):667-669.
16. Jain S, Farooq SJ, and Gottlob I. Resolution of superior oblique myokymia with memantine. *J AAPOS* 2008;12(1):87-88.
17. Tomsak RL, Kosmorsky GS, and Leigh RJ. Gabapentin Attenuates Superior Oblique Myokymia. *Am J Ophthalmol* 2002;133(5):721-723.
18. Tyler TD, Ruiz RS. Propranolol in the treatment of superior oblique myokymia. *Arch Ophthalmol* 1990;108(2):175-176.
19. Bibby K, Deane JS, Farnworth, and Cappin J. Superior oblique myokymia—a topical solution? *Br J Ophthalmol* 1994;78(11):882.
20. Ruttum MS, Harris GJ. Superior oblique myectomy and trochlectomy in recurrent superior oblique myokymia. *Graefes Arch Clin Exp Ophthalmol* 1988;226(2):145-147.
21. Agarwal S, Kushner BJ. Results of extraocular muscle surgery for superior oblique myokymia. *J AAPOS* 2009;13:472-476.
22. de Sa LC, Good WV, Hoyt CS. Surgical management of myokymia of the superior oblique muscle. *Am J Ophthalmol* 1992;114(6):693-696.
23. Ruttum MS., Harris GJ. Superior oblique myectomy and trochlear resection for superior oblique myokymia. *Am J Ophthalmol* 2009;148(4):563-565.
24. Kosmorsky GS, Ellis BD, Fogt N, Leigh RJ. The treatment of superior oblique myokymia utilizing the Harada-Ito procedure. *J Neuroophthalmol* 1995;15(3):142-146.
25. Samii M, Rosahl SK, Carvalho GA, Krzizok T. Microvascular decompression for superior oblique myokymia: first experience. Case report. *J Neurosurg* 1998;89(6):1020-4.
26. Scharwey K, Krzizok T, Samii M, Rosahl SK, Kaufmann H. Remission of superior oblique myokymia after microvascular decompression. *Ophthalmologica* 2000;214(6):426-8.
27. Mikami T, Minamida Y, Ohtsuka K, Houkin K. Resolution of superior oblique myokymia following microvascular decompression of trochlear nerve. *Acta Neurochir (Wien)* 2005;147(9):1005-1006.
28. Fam MD, Scott C, Forster A, Kamel MH. Microvascular decompression for superior oblique myokymia: case report. *Br J Neurosurg* 2014;28(4):552-555.

Citing this article

Lenci LT, Thompson EA, Thurtell MJ. Vertical Oscillopsia: A Case of Superior Oblique Myokymia. *EyeRounds.org*. January 4, 2016; Available from: EyeRounds.org/cases/228-SOM.htm

last updated: 01/04/2016

Case Presentations

Pediatric Ophthalmology & Strabismus

Orbital Cellulitis in a Child

Esther S. Hong, MD, Richard C. Allen, MD, PhD

January 12, 2010

Chief Complaint: Swollen left eye and sinus infection

History of Present Illness: 9-year-old female with left nasal pain 4 days prior to presentation. Her left eye was swollen and red and seemed to be worsening. The patient also stated that it had been more difficult to open her left eye and there had been some matting on her eyelids. She also noticed diplopia in all gazes.

She initially presented to her pediatrician who thought she had a preseptal cellulitis and started her on amoxicillin.

However, after one day on amoxicillin, the patient returned to her pediatrician because her symptoms were worsening. She was switched to Augmentin and had 5 doses when she presented to our institution.

The patient's pediatrician also ordered a maxillofacial CT at her return visit. (see below)

Past Ocular History: none

Medical History: none

Medications

- ◆ Augmentin[®] (amoxicillin with clavulanate potassium)
- ◆ Tylenol[®] (acetaminophen) as needed
- ◆ Tylenol #3[®] (acetaminophen and codeine) as needed

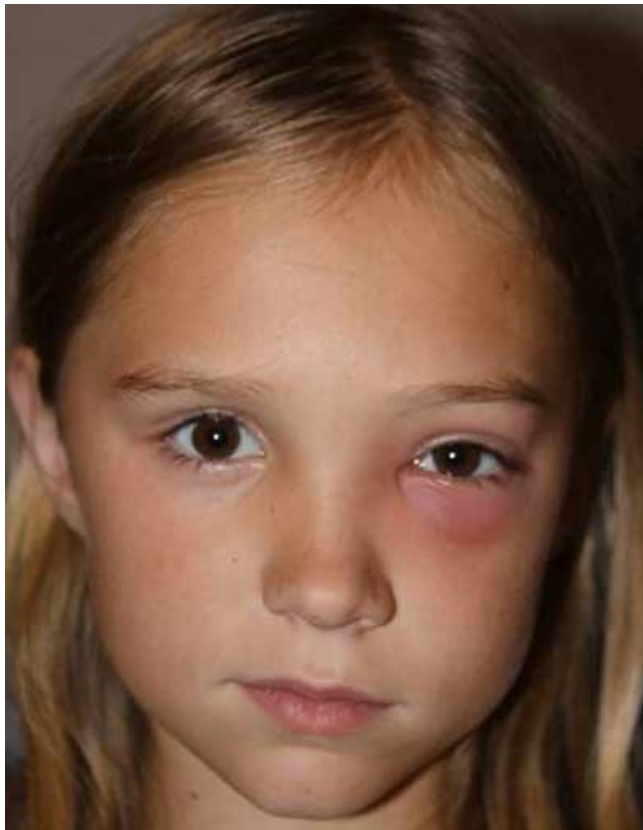

Figure 1. Photo of patient

Allergies: none

Family History: Noncontributory.

Review of Systems: Afebrile, mild headache, clear mild rhinorrhea, no neck stiffness

Ocular Exam

- ◆ Visual Acuity, with best correction
 - OD 20/20
 - OS 20/20
- ◆ Pupils: 4mm → 2mm, brisk, equal, no RAPD OU
- ◆ Motility
 - OD — normal
 - OS — -0.5 adduction and superior gaze, -1.5 abduction
 - (Notes diplopia in all field of gaze)
- ◆ Intraocular pressure applanation: OD — 23, OS — 14
- ◆ Confrontational visual fields: Full OD/OS

External Exam

- ◆ Hertels: OD 13mm, OS 15mm, base 93mm
- ◆ Palpebral Fissure: OD 9mm, OS 7mm
- ◆ Marginal Reflex Distance: OD 5mm, OS 3mm

EXTERNAL/SLIT LAMP EXAM

- ◆ Lids/Lashes
 - OD normal
 - OS erythematous/edematous upper and lower lids, proptosis
- ◆ Conjunctiva/Sclera: normal OD/OS
- ◆ Cornea: normal OD/OS
- ◆ AC: formed, no cell/flare OD/OS
- ◆ Lens: normal OD/OS
- ◆ Vitreous: No cell OD/OS

Vital signs: BP 115/68, Pulse 76, T 36.9

Laboratory tests

- ◆ CBC
 - **WBC 11.6 K/mm³**
- ◆ Differential
 - **Neutrophils 8050/mm³**
 - Lymphocytes 2010/mm³
 - **Monocytes 880/mm³**
 - Eosinophils 60/mm³
 - Basophils 40/mm³
- ◆ Hgb: 12.5 G/DL
- ◆ Platelets: 294 K/mm³
- ◆ **ESR: 65**
- ◆ **CRP: 4.6**

(Elevated abnormal values are *in ITALICS*)

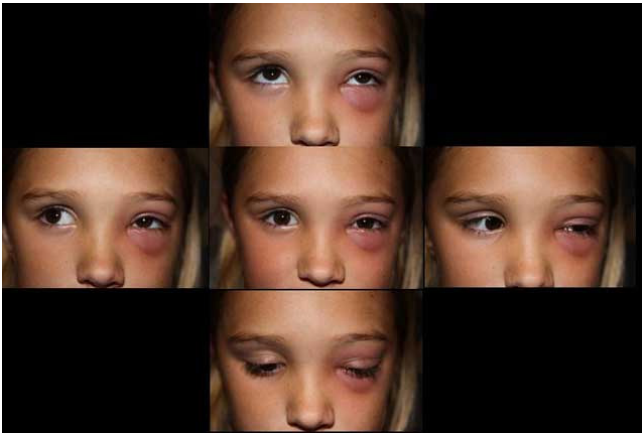

Figure 2: Motility Assessment on presentation

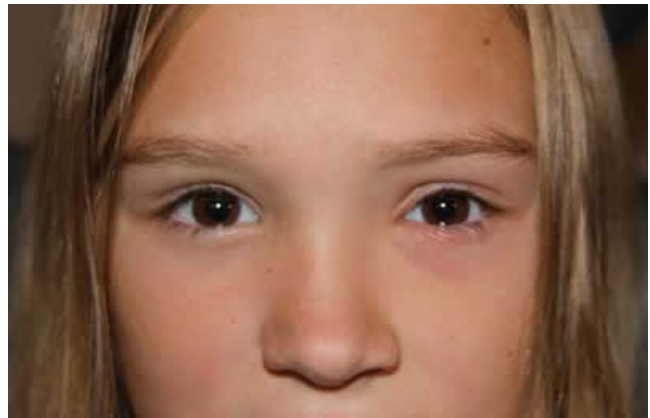

Figure 5. Post treatment photo

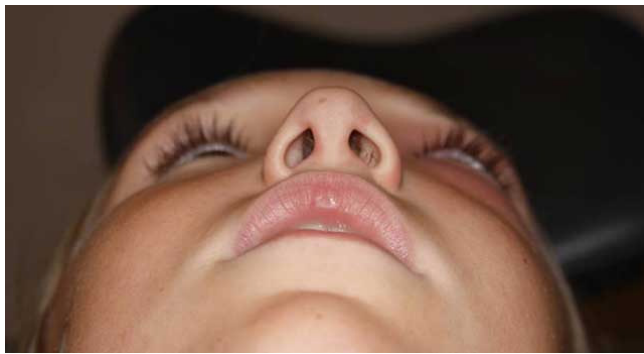

Figure 3. 2mm Proptosis OS



Figure 6. Post treatment motility assessment

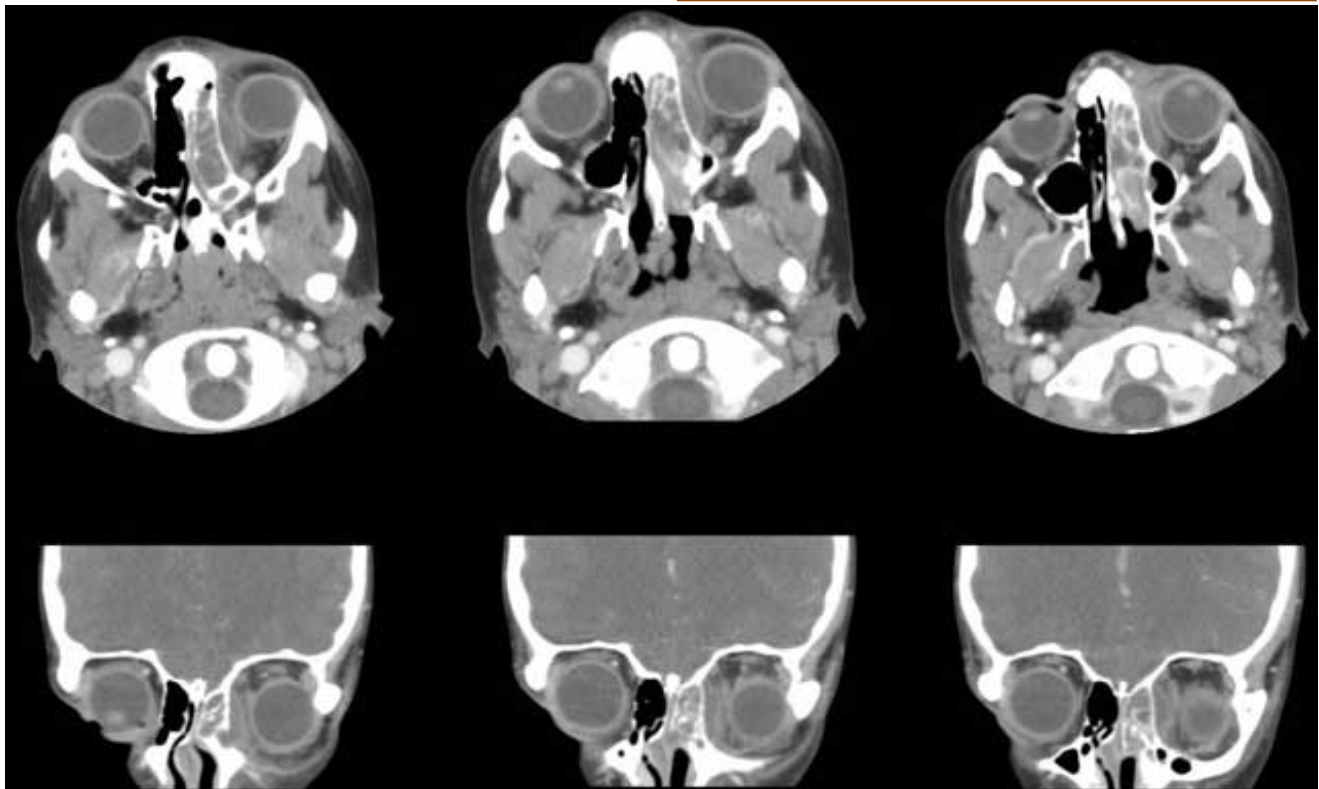


Figure 4. CT max/face: Subperiosteal abscess formation adjacent to the lamina papyracea of the left orbit with extensive sinusitis involving the left ethmoid sinus

Hospital Course: The patient was admitted into the hospital and treated with IV ceftriaxone and clindamycin. She was also treated with Afrin® (oxymetazoline) spray. Otolaryngology was consulted to address the sinusitis.

Her symptoms improved quickly after the initiation of IV antibiotics treatment. Her motility was almost full after one day of treatment. The patient was monitored every 12 hours by ophthalmology. By admission day 3, the patient was feeling better with full motility and much improved erythema and edema of her left eye. Diplopia was resolved.

Her sinus symptoms had also improved.

The patient was discharged home on hospital admission day 4 with a two-week course of clindamycin and nasal steroids.

Discussion

Orbital cellulitis is an infection of the soft orbital tissue posterior to the orbital septum. This is in contrast to preseptal cellulitis which is a soft tissue infection of the eyelids anterior to the orbital septum. If a diagnosis of preseptal cellulitis is entertained, a well-defined event should be elicited from the patient (e.g. injury, stye, bug bite, etc). If a convincing event cannot be elicited, an orbital etiology should always be investigated with orbital imaging. The patient in this case was diagnosed initially with a preseptal cellulitis with no predisposing event.

The most common bacterial organisms in orbital cellulitis include *Streptococcus* species, *Staphylococcus aureus*, *Pseudomonas*, *Enterococcus*, *Klebsiella*, and *Haemophilus influenzae* type B. Methocillin-resistant staph aureus is becoming more common in orbital cellulitis. If a fungal infection is suspected, consider *Mucor* and *Aspergillus* species.

90% of cases occur as a secondary extension of acute or chronic bacterial sinusitis, especially the ethmoid sinuses. Other extensions of periorbital structures include the face/eyelids, dacryocystitis and dental infections. Exogenous causes include trauma and orbital/periorbital surgery. An orbital foreign body (specifically organic) should always be entertained in the setting of an orbital cellulitis that is not responding to antibiotic therapy. Endogenous causes include septic embolization from bacteremia. There may also be intraorbital causes including endophthalmitis and dacryoadenitis.

Orbital clinical findings include proptosis, ptosis, restriction of ocular motility, ocular pain, and chemosis. If there is decreased visual acuity, or a visual field or relative afferent pupillary defect, one must consider compressive optic neuropathy which warrants urgent aggressive management.

Systemic clinical findings are essential in the workup of possible orbital cellulitis. Pertinent findings include leukocytosis and fever. In this patient, she had already been treated with a four day course of antibiotics which explains her afebrile state as well as her normal WBC count. However she still exemplified elevated neutrophils, monocytes, ESR and CRP which also demonstrate an infectious etiology.

CT of the orbits and the paranasal sinuses is essential. Evidence of sinusitis mandates otolaryngology involvement. Lumbar puncture is necessary if meningeal signs and symptoms develop. Conjunctival cultures add very little information. Nasal cultures may be appropriate if there is significant nasal discharge in the setting of sinusitis. Blood cultures are appropriate in the setting of septicemia. If surgical drainage of the orbita and/or sinus is performed, cultures should be obtained.

Surgical intervention is less likely in orbital cellulitis in children (≤ 9 years old) because the infection is caused by a single gram positive organism. IV antibiotic therapy is the initial treatment of choice. Progression (worsening motility deficit, pain, optic nerve dysfunction) in a child after 24-48 hours of IV antibiotic therapy would lead one to drain the abscess. However, if this were an adult patient, with evidence of an abscess formation, early surgical intervention to drain the involved sinus and orbital abscess is usually indicated along with medical therapy given that the infection is more likely to be polymicrobial.

Consider surgical management if the patient has any of the following

- ◆ > 9 years old
- ◆ Frontal sinusitis
- ◆ Non medial location of the subperiosteal abscess
- ◆ Large subperiosteal abscess
- ◆ Presence of gas in the abscess on CT suggesting an anaerobic etiology
- ◆ Recurrent episode of subperiosteal abscess
- ◆ Nasal polyps which suggest chronic sinusitis
- ◆ Evidence of acute optic neuropathy
- ◆ Dental infection (likely an anaerobic infection)

Clinical improvement does not correlate accurately with repeat CT scan analysis. It may take 48-72 hrs for the abscess to improve on imaging.

The majority of patients respond well to medical and/or surgical treatments. Rarely, orbital cellulitis may spread posteriorly to the cavernous sinus, meninges and the brain parenchyma.

Diagnosis: Orbital Cellulitis

Differential Diagnoses

Infectious orbital inflammation

- ◆ Preseptal cellulitis
- ◆ Orbital cellulitis
 - Bacterial
 - Fungal
- ◆ Dacryocystitis
- ◆ Dacryoadenitis
- ◆ Endophthalmitis

Non-infectious orbital inflammation

- ◆ Thyroid eye disease
- ◆ Wegener 's granulomatosis
- ◆ Sarcoidosis
- ◆ Churg-Strauss
- ◆ Malignancy
- ◆ Idiopathic orbital inflammatory syndrome

<p>EPIDEMIOLOGY</p> <ul style="list-style-type: none"> ◆ Increased incidence during the winter due to the increased incidence of sinusitis ◆ No ethnic preferences ◆ Blindness occurs in up to 11% of cases ◆ In children, twice as common in males ◆ More common in children than adults: mean age 7-12 years old. 	<p>SIGNS</p> <ul style="list-style-type: none"> ◆ Proptosis ◆ Ptosis ◆ Chemosis ◆ Lid erythema/edema ◆ Motility restriction
<p>SYMPTOMS</p> <ul style="list-style-type: none"> ◆ Ocular/periorbital pain ◆ Decreased vision ◆ Diplopia ◆ Nasal discharge ◆ Worsening pain on eye movement ◆ Nasal tenderness 	<p>TREATMENT</p> <p>In children</p> <ul style="list-style-type: none"> ◆ Inpatient - broad spectrum IV antibiotics which is narrowed or tailored to the most likely or documented organism. Consider covering for MRSA. If the patient is afebrile and improving x 48hrs, may switch to oral antibiotics. ◆ Outpatient oral antibiotics for 2-3 weeks ◆ Consider surgical management if worsening on IV antibiotics or have the special conditions listed above in the Discussion section <p>In adults</p> <ul style="list-style-type: none"> ◆ Inpatient - surgical debridement of orbital abscess and associated sinus along with IV antibiotics. ◆ Outpatient oral antibiotics for 2-3 weeks

References

1. Garcia GH., et al. Criteria for nonsurgical management of subperiosteal abscess of the orbit. *Ophthalmology*. 2000;107:1454-1458. PubMed.gov/10919887
2. Harris GJ. Subperiosteal abscess of the orbit: age as a factor in the bacteriology and response to treatment. *Ophthalmology*. 1994;101:585-595. hPubMed.gov/8127580
3. Basic and Clinical Science Course, Section 6. Orbit, Eyelids and Lacrimal System. American Academy of Ophthalmology. 2009, pp.231-233.
4. McKinley SH., et al. Microbiology of pediatric orbital cellulitis. *Am J Ophthalmol*. 2007;144:497-501 PubMed.gov/17698020
5. Nageswaran S., et al. Orbital cellulitis in children. *Pediatr Infect Dis J*. 2006;25:695-699. PubMed.gov/16874168

Citing this Article

Hong ES, Allen RC. Orbital Cellulitis in a Child. *EyeRounds.org*. January 12, 2010; Available from: <http://www.EyeRounds.org/cases/103-Pediatric-Orbital-Cellulitis.htm>

last updated: 01-12-2010

Congenital dacryocystocele with spontaneous resolution

Elizabeth H. Gauger, MD and Susannah Q. Longmuir, MD

March 7, 2013

Chief complaint: Full-term 10 day-old female referred to the pediatric ophthalmology clinic by dermatologist for a bluish mass inferior to the right medial canthus.

History of present illness: Initially a cystic lesion was noted on the fetus' face on a 28-week ultrasound. At birth, an elevated, bluish lesion was noted just inferior to the right medial canthus. The lesion did not seem to bother the patient, and it had not changed in size or appearance since birth. The local pediatrician was concerned it was a hemangioma and referred the patient to dermatology. Dermatology subsequently evaluated the patient and referred her to pediatric ophthalmology for further management.

Past Ocular History: Unremarkable

Past Medical History: Unremarkable

Medications: None

Allergies: No known drug allergies

Family History: No known eye disease

Ocular Exam

- ◆ **External Exam** (Figure 1):
 - **Right eye (OD):** 12mm horizontal by 15mm vertical elevated, bluish cystic lesion at medial canthus below medial canthal tendon. Punctum present inferiorly. Punctum not visualized superiorly.
 - **Left eye (OS):** Normal
- ◆ **Visual Acuity:** Winces to light OD and OS
- ◆ **Pupils:** Reactive. No anisocoria and no relative afferent pupillary defect
- ◆ **Intraocular pressure:** Physiologic by palpation

- ◆ **Alignment:** Ortho by Hirschberg
- ◆ **Anterior segment exam:** Within normal limits
- ◆ **Dilated funduscopy exam:** Deferred until examination under anesthesia (EUA)

Clinical Course

The clinical exam features were felt to be classic for and consistent with a congenital dacryocystocele. An examination under anesthesia and probing of the lacrimal system on the right side was planned for three days later. The patient was started on oral Augmentin (amoxicillin/clavulanate), due to concern for early infection of the dacryocystocele.

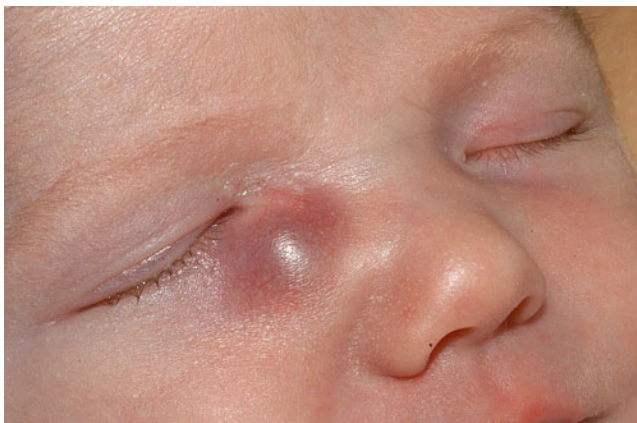On the morning of the procedure, the child was seen in the pre-operative area. The mother reported that the prior evening, there had been a large amount of discharge from the medial canthal area, and the swollen, blue cystic area had spontaneously decompressed.

Given that the dacryocystocele had spontaneously decompressed, probing of the nasolacrimal system was deferred. Tobradex (tobramycin/dexamethasone ophthalmic suspension) drops four times a day to the right eye were prescribed for prophylaxis. The child was to follow-up in clinic in one week for further evaluation. No further complications or problems occurred in this infant.

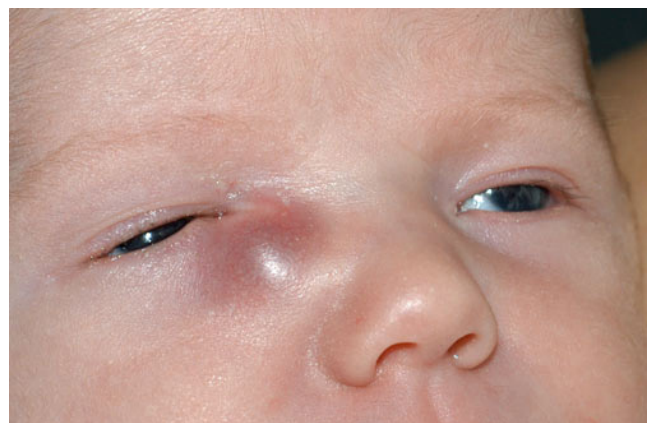Discussion

Presentation of congenital dacryocystocele

Congenital dacryocystocele, also known as a *dacryoceles*, often presents shortly after birth. It is an infrequent variant



A. External exam of infant. Note the purplish swelling inferior to the medial canthal tendon. Figure 1: External exam of infant.



B. The mass is causing upward slanting/displacement of the palpebral fissure nasally.

of nasolacrimal duct obstruction (NLDO) and found in only about 1.0% of infants with congenital NLDO.[1]

Congenital dacryocystocele often presents as a bluish, cystic, firm mass inferior to the medial canthus. One study cited the median age of presentation as 7 days of life.[2] It is most commonly unilateral but may be bilateral. Multiple studies have found that the condition is more common in females than in males, secondary to females having a more narrow nasolacrimal duct than males.[2]

Patients with a dacryocystocele may have difficulty breathing or develop infection of the site. Parents may notice that the child has difficulty breastfeeding and develops respiratory difficulty when feeding on the breast ipsilateral to the dacryocystocele.[2]

Diagnosis

Often, the diagnosis of congenital dacryocystocele can be made based on clinical findings alone. However, if the diagnosis is in question, a computed tomography (CT) scan or magnetic resonance imaging (MRI) can be used to confirm the diagnosis. Interestingly, the diagnosis can also be made prenatally with ultrasonography.[3] Items that should be considered in the differential diagnosis include: encephalocele, meningocele, and encephalomeningocele. These generally occur superior to the medial canthus, however. These are potentially life-threatening diagnoses that should be promptly evaluated.

Congenital dacryocystocele can be considered a subcategory of congenital NLDO. In both, there is improper drainage of tears; however, they differ in the site of the blockage. In NLDO, the blockage generally occurs distally at the valve of Hasner. Thus, there is backlog of the drainage system leading to a watery eye and epiphora. With a dacryocystocele, there is a functional blockage proximally as well as a blockage distally. This leads to fluid accumulation (amniotic fluid and mucous produced by the lacrimal sac glands) causing distention (Figure 2). The proximal blockage is thought to be caused by failure of the mesoderm to properly canalize during development.[2]

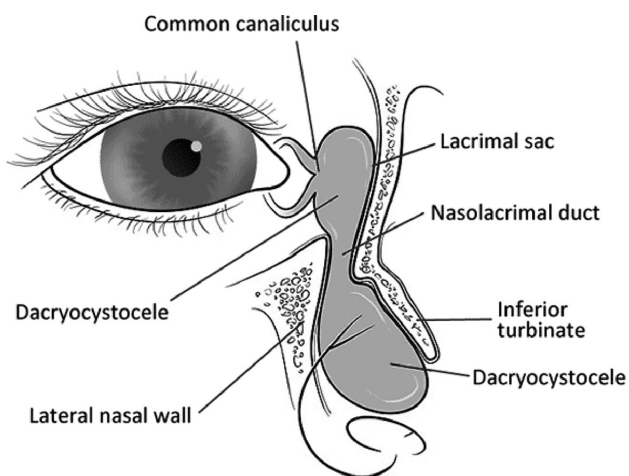


Figure 2: Schematic drawing of a congenital dacryocystocele. (Used with permission)[3]

Treatment

Treatment options for dacryocystocele range from conservative, non-surgical management (massage, observation) to surgical (probing of nasolacrimal system).[3] Initially conservative measures should be tried. This includes digital massage over the area of elevation and prophylactic topical antibiotics. If no response to treatment is seen within 1-2 weeks, probing and irrigation of the lacrimal system either in the clinic or operating room is recommended (Figures 3 and 4). One study reported that approximately 22% of cases spontaneously resolved, while the remainder required surgical intervention.[2]

Should the dacryocystocele progress to dacryocystitis, antibiotics are indicated.[2] As children who develop dacryocystitis are often one month of age or younger, admission to the hospital may be recommended depending on age, medical co-morbidities, and follow-up. Sepsis is a life threatening complication if the infection goes without treatment. If there is an intranasal component (endonasal cyst), marsupialization of the cyst is recommended, and an otolaryngology consult may be appropriate depending on the surgeons experience.[4]

Complications

There are several complications that can occur as a result of a dacryocystocele. These include: dacryocystitis, cellulitis, and respiratory compromise. In cases of infection, the child may experience life-threatening sepsis. Therefore, it is important if the child develops concurrent dacryocystitis and cellulitis that they be hospitalized for observation and administration of intravenous antibiotics.[3] Once the infection subsides, probing with or without stent placement is advised.

Rarely, dacryocystocele can be associated with an intranasal cyst. If one opts to try conservative management initially, these children must be monitored for signs of infection or breathing difficulty. Consultation with an otolaryngologist or endoscopic nasal endoscopy should be performed at the time of probing. Should any of the above complications occur, prompt management (antibiotics, probing, surgery) is required.[2]

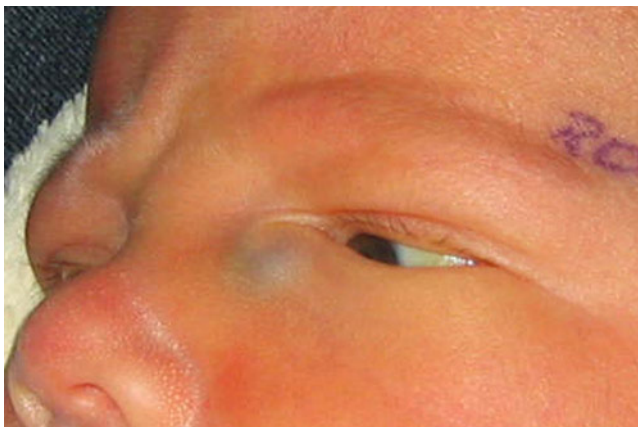
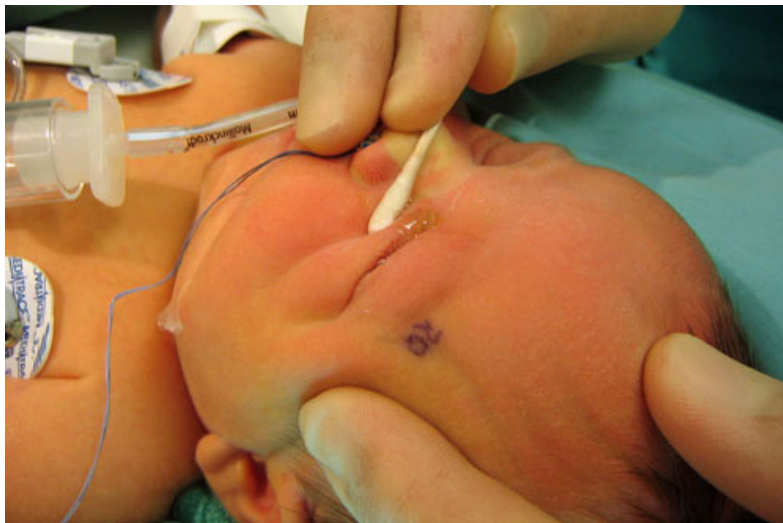
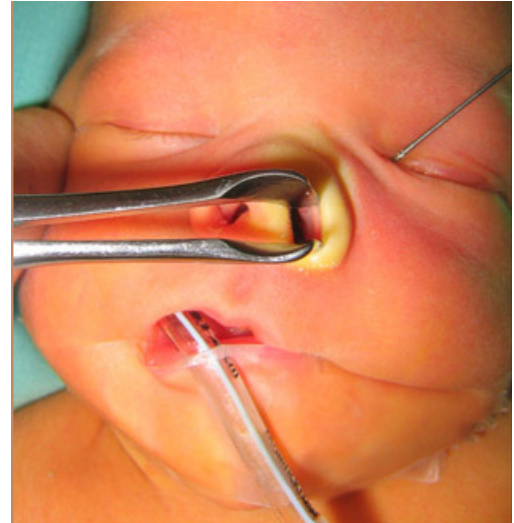Figure 3: Example of a congenital dacryocystocele in a newborn.



A. Decompression of dacryocystocele in the operating room.



B. Subsequent probing and irrigation.

Figure 4

<p>Epidemiology</p> <ul style="list-style-type: none"> ◆ Presents within first several days to weeks of life (median age = 7 days of life)[2] ◆ Usually unilateral 	<p>Signs</p> <ul style="list-style-type: none"> ◆ Elevated purplish mass <i>inferior</i> to medial canthal tendon ◆ Epiphora, matting (generally unilateral)
<p>Symptoms</p> <ul style="list-style-type: none"> ◆ Tearing ◆ Matting 	<p>Treatment</p> <ul style="list-style-type: none"> ◆ Conservative: Digital massage, ◆ Surgical: Probing and irrigation
<p>Differential Diagnosis</p> <ul style="list-style-type: none"> ◆ Hemangioma: Usually presents later, softer to touch ◆ Encephalocele: Usually <i>superior</i> to medial canthal tendon ◆ Dermoid: Usually <i>superior</i> to medial canthal tendon ◆ Nasal glioma 	<p>Complications</p> <ul style="list-style-type: none"> ◆ Dacryocystitis ◆ Cellulitis ◆ Respiratory compromise ◆ Sepsis <p>CT or MRI should be performed if more serious etiology suspected</p>

Diagnosis: Congenital Dacryocystocele

References

1. MacEwen CJ, Young JD. Epiphora during the first year of life. *Eye (Lond)* 1991;5(Pt 5):596-600.
2. Wong RK, VanderVeen DK. Presentation and management of congenital dacryocystocele. *Pediatrics* 2008;122:e1108-12.
3. Becker BB. The treatment of congenital dacryocystocele. *Am J Ophthalmol* 2006;142:835-8.
4. Lueder GT. Endoscopic treatment of intranasal abnormalities associated with nasolacrimal duct obstruction. *J AAPOS* 2004;8:128-32.

Citing this Article

Gauger EH, Longmuir SQ. Congenital dacryocystocele with spontaneous resolution. *EyeRounds.org*. March 7, 2013; available from: <http://www.EyeRounds.org/cases/166-dacryocystocele.htm>

last updated: 03/07/2013

Phlyctenular Keratoconjunctivitis

12-year-old Female with Staphylococcal Blepharitis

Arpitha Muthialu, MD; Lauren E. Jensen; Michael Wagoner, MD, PhD

February 27, 2009

Chief Complaint: Blurry vision and discomfort in the right eye.

History of Present Illness: A 12-year-old female complains of blurry vision, foreign body sensation, and photophobia in her right eye. While she has had chronic problems for years in both eyes, she has noted the acute onset and progressive worsening of the symptoms in the right eye for one week.

Past Ocular History: Since the age of 6, the patient has struggled with meibomian gland dysfunction and chronic staphylococcal blepharoconjunctivitis, as well as seasonal allergic conjunctivitis. She has been treated with topical corticosteroids, antibiotics, and antihistamines since age 8 and systemic doxycycline since age 9.

Medical History: Otherwise healthy.

Medications: Since her last exam 8 months prior to this presentation, she was completely asymptomatic on a regimen of

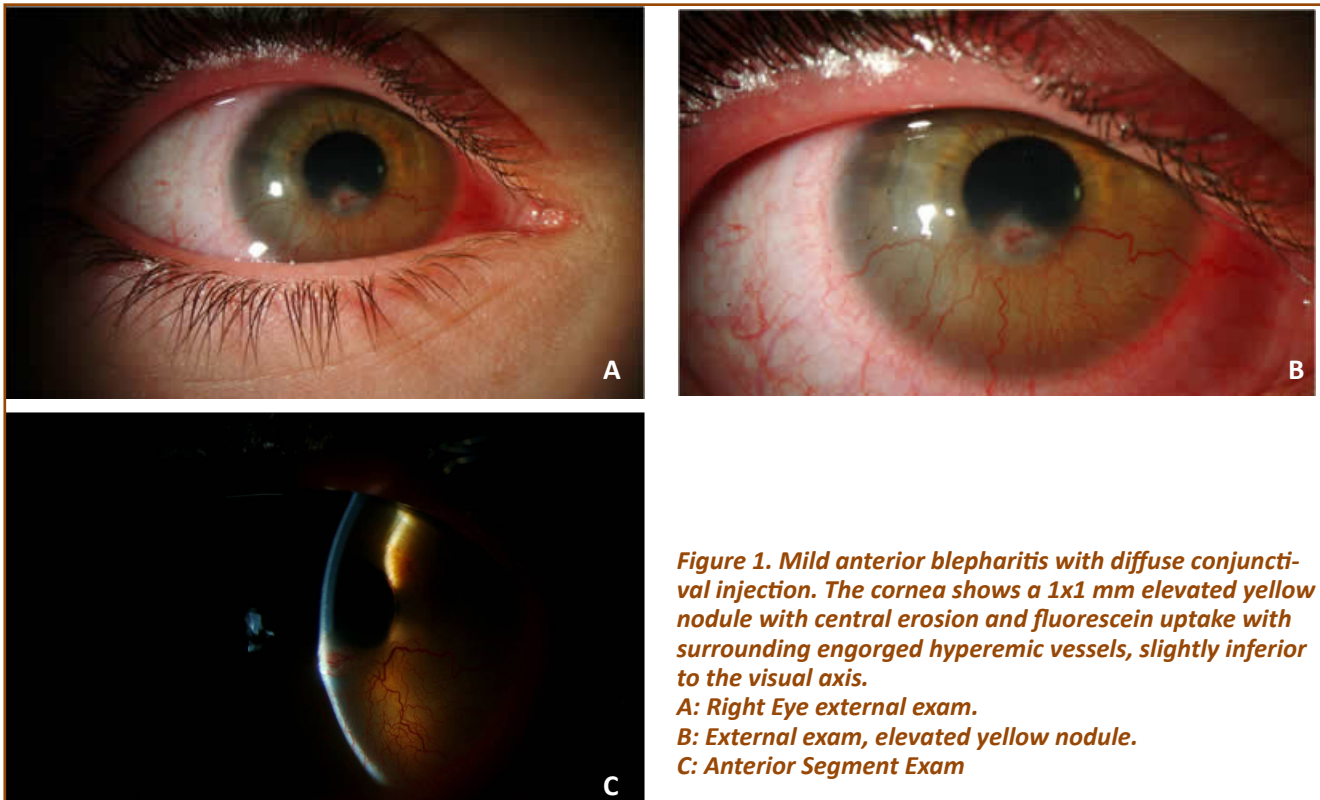
- ◆ Doxycycline (100mg orally once daily)
- ◆ Prednisolone acetate 1.0% (twice daily drops)
- ◆ TobraDex (Tobramycin and Dexamethasone) ointment nightly

The patient had discontinued all of these systemic and topical medications one month prior to the current episode upon the suggestion of a maternal aunt who recommended adoption of a “holistic and naturalistic” approach to the management of her chronic ocular disorders.

Family History: Noncontributory

Physical and Ocular Examination

- ◆ General: healthy-appearing young female
- ◆ Visual Acuity, without correction
 - Right eye (OD)--20/80 (with pinhole improves to 20/50)
 - Left eye (OS)--20/20
- ◆ Extraocular Motility: Full, both eyes (OU)
- ◆ Intra-ocular pressure: OD -- 17mmHg; OS -- 14 mmHg
- ◆ External and anterior segment examination (see Figure 1A-C and Figure 2A-B)
 - Right eye
 - Lids/adnexa: mild anterior blepharitis
 - Conjunctiva/sclera: 2+ diffuse conjunctival injection



- Cornea: 1x1 mm elevated yellow nodule with central erosion and fluorescein uptake with surrounding engorged hyperemic vessels, slightly inferior to the visual axis; there is 360 degree limbal pannus
 - Anterior chamber: deep and quiet
 - Iris is normal and lens is clear
 - Left eye
 - Lids/adnexa: mild anterior blepharitis
 - Conjunctiva/sclera: quiet and white
 - Cornea: 360 degree limbal pannus
 - Anterior chamber: deep and quiet
 - Iris is normal and lens is clear
 - ◆ Dilated fundus exam (DFE): No pallor or edema of either disc. Normal macula, vessels, and periphery, OU
- Mild anterior blepharitis with diffuse conjunctival injection. The cornea shows a 1x1 mm elevated yellow nodule with central erosion and fluorescein uptake with surrounding engorged hyperemic vessels, slightly inferior to the visual axis.

Discussion

Phlyctenular keratoconjunctivitis (PKC) is a localized noninfectious inflammatory/ hypersensitivity disorder of the ocular surface characterized by subepithelial nodules of the conjunctiva and/or cornea. These “phlyctenules,” are derived from “phlyctena,” the Greek word for “blister.” The blister characterization was likely chosen due to the tendency for the nodules to ulcerate once necrosis occurs. Histopathologically, phlyctenules are subepithelial inflammatory nodules containing histiocytes, lymphocytes, plasma cells, and neutrophils. Mononuclear phagocytes, dendrites Langerhans cells, and neutrophils make up the majority of the inflammatory cells in the epithelium overlying the phlyctenule.

The pathogenesis of PKC is thought to be a hypersensitivity reaction to an antigen of bacterial origin. PKC has been classically associated with *M. tuberculosis* (especially in developing countries). However, *Staphylococcus aureus* is the cause in majority of cases in the United States. A number of other organisms are also associated with PKC (Table 1).

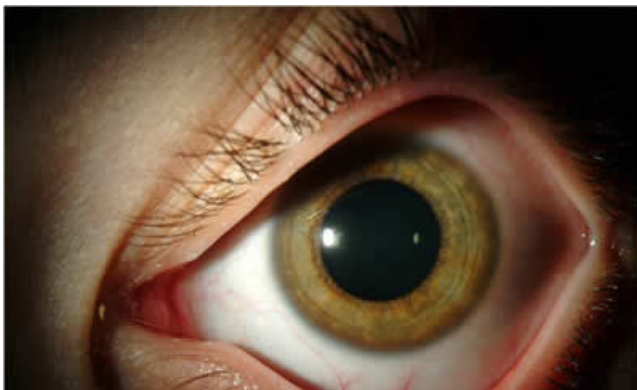

Figure 2A: External Exam. Left eye.

Table 1: Organisms Implicated in the Pathogenesis of Phlyctenular Keratoconjunctivitis

- ◆ *Mycobacterium tuberculosis*
- ◆ *Staphylococcus aureus*
- ◆ *Chlamydia trachomatis*
- ◆ *Neisseria gonorrhoea*
- ◆ *Coccidioides immitis*
- ◆ *Bacillus* spp.
- ◆ Herpes simplex virus
- ◆ Leishmaniasis *Ascaris lubricoides*
- ◆ *Hymenolepis nana*
- ◆ *Candida* spp.

Most often, phlyctenulosis is a corneal sequelae of chronic Staphylococcal blepharitis, a disorder that often presents in the clinic as chronic conjunctivitis or keratitis characterized by punctate epithelial keratopathy, and/or marginal corneal infiltrates (Table 2). When present, symptoms of PKC depend upon the location of the lesion. Conjunctival lesions usually present with mild to moderate symptoms, including foreign body sensation, tearing, photophobia, burning, and itching. Corneal lesions typically present with more severe symptoms of the same variety.

Corneal phlyctenules usually begin at the limbus and spread centrally, perpendicular to the limbus, leaving no clear zone between the lesion and the limbus. The vessels run in a straight course from the limbus. They can become necrotic and ulcerate centrally or spontaneously involute within 2 to 3 weeks. Upon resolution, a wedge-shaped fibrovascular scar may remain. Centripetal migration of successive inflammatory lesions may develop as in this case. Rarely, inflammation associated can lead to keratolysis and perforation.

Treatment

Management of PKC requires both anti-inflammatory and anti-bacterial management, as well as management of chronic blepharitis. Control of inflammation can be achieved with topical corticosteroids, which should be tapered very slowly to avoid recurrences. Antibacterial measures may include a several week course of application of topical antibiotics to the eyelid margin and conjunctiva,

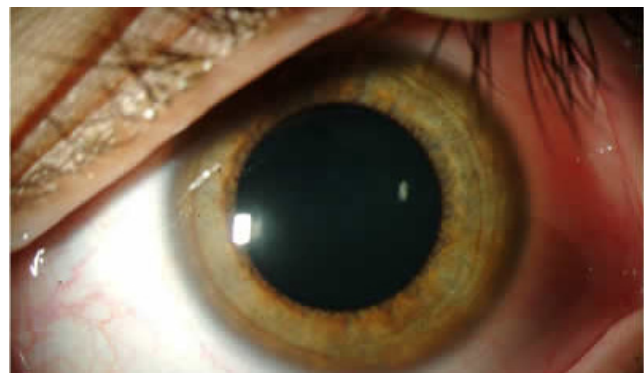


Figure 2B: External Exam of left eye shows mild anterior blepharitis

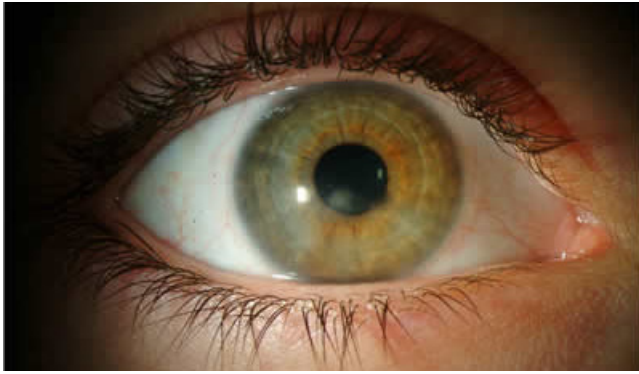

Figure 3A: Right eye, post-treatment

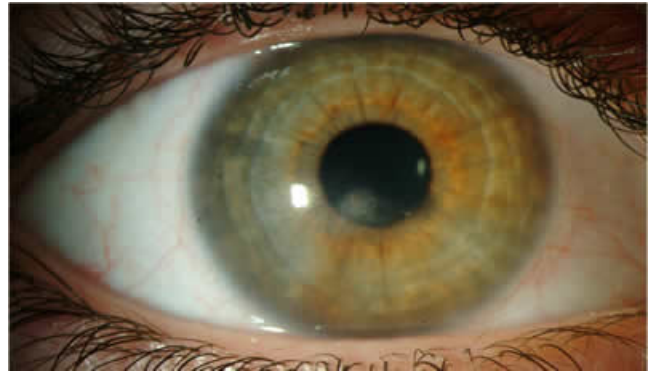


Figure 3B: Right eye, post-treatment



Figure 3C: post-treatment

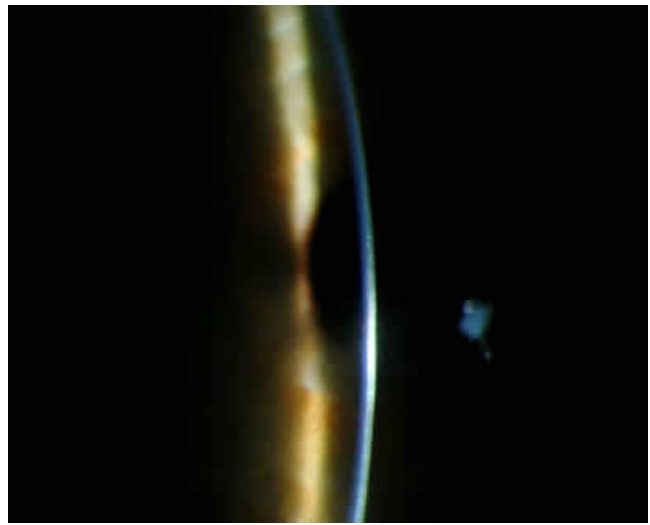


Figure 3D: post-treatment anterior eye exam.

especially at bedtime. Management of chronic blepharitis requires a consistent regimen of lid hygiene and warm compresses, as well as systemic administration of tetracycline derivatives, such as Doxycycline for patients without contraindications. Tetracyclines should not be used in children under age 8 because permanent tooth discoloration can occur. In addition, tetracycline is teratogenic and should be avoided in pregnant women, as well as in nursing mothers.

Follow-up Course

Our patient responded dramatically to topical prednisolone acetate 1% which was initially used every 2 hours while awake. She was treated with a 1 week course of topical gatifloxacin drops four times daily (to prevent infection at the epithelial defect) and a 3 week course of Tobradex[®] ointment at bedtime. Management of chronic blepharitis was achieved by reinstating a strict program of lid hygiene and warm compresses, along with reinstating doxycycline 100 mg orally twice daily for one month and then once daily thereafter. Within 1 week, she responded readily to this treatment with improved vision and decreased discomfort (post-treatment images Figure 3A-D), after which topical corticosteroid therapy was gradually tapered.

Diagnosis

Phlyctenular keratoconjunctivitis

Differential Diagnoses for Corneal nodule and irritation

- ◆ Staphylococcal marginal keratitis with phlyctenule
- ◆ Microbial keratitis
- ◆ Inflamed pseudopterygium
- ◆ Salzmann's nodule
- ◆ Corneal foreign body

<p>EPIDEMIOLOGY</p> <ul style="list-style-type: none"> ◆ Predominantly young individuals 	<p>SIGNS</p> <ul style="list-style-type: none"> ◆ Staphylococcal blepharitis ◆ Inflammation of cornea or conjunctiva ◆ Wedge-shaped nodular lesion and engorged hyperemic vessels at or near the limbus, bulbar conjunctiva, or cornea
<p>SYMPTOMS</p> <ul style="list-style-type: none"> ◆ Redness, foreign body sensation, morning crusting, photophobia, itching ◆ Decreased vision 	<p>TREATMENT</p> <ul style="list-style-type: none"> ◆ Antibacterial <ul style="list-style-type: none"> • Eyelid hygiene • Ointment to lid margin (i.e. TobraDex) • Topical antibiotics initially (i.e. gatifloxacin) ◆ Anti-inflammatory <ul style="list-style-type: none"> • Topical corticosteroids (i.e. prednisolone 1% q2-q4 hours) ◆ Treat the blepharitis <ul style="list-style-type: none"> • Eyelid hygiene • Warm compresses • Oral doxycycline (100mg Daily to BID)

References

1. Albert DM, Jakobiec FA, eds. Principles and Practice of Ophthalmology. 2nd ed. Philadelphia: Saunders; 2000. p. 1093-1099.
2. Gokhale J et al. Etiology of Phlyctenulosis. Indian Journal of Ophthalmology. 1965. Vol 13 (2): 65-67.
3. Jackson WB. Blepharitis: Current strategies for diagnosis and management. Can J Ophthalmol. 2008; 43(2):170-9.
4. Krachmer JH, Mannis MJ, Holland EF, eds. Cornea. 2nd ed. Philadelphia: Elsevier Mosby; 2005. p. 1235-1238.
5. Rapuano CJ, Luchs JI, Kim T. Anterior Segment: The Requisites in Ophthalmology. St. Louis: Mosby; 2000. p. 165-168.

Additional Reading

Wagoner MD, Bajart AM, Allansmith MR. Phlyctenulosis. In: Fraunfelder FT, Roy FH *Current Ocular Therapy* 3. Philadelphia, PA; W.B. Saunders Co. 1990. p. 454-445

Citing this article

Muthialu A, Jensen LE, Wagoner M. Phlyctenular Keratoconjunctivitis: 12-year-old Female with Staphylococcal Blepharitis. EyeRounds.org. February 27, 2009; Available from: http://www.eyerounds.org/cases/89_Phlyctenular-Keratoconjunctivitis-Staphylococcal-Blepharitis.htm

last updated: 02-27-2009

Case Presentations

Retina & Vitreous

Intraocular Foreign Body

A Classic Case of Metal on Metal Eye Injury

Paul Abrams, B.S. (M4), Emily S. Birkholz M.D., Ryan M. Tarantola M.D., Thomas A. Oetting M.D., Stephen R. Russell M.D.

May 24, 2011

Chief Complaint: Acute right eye pain

History of Present Illness: A 36-year-old male presented with right eye pain immediately after he had been pounding a metal object with a metal chisel. He was not wearing safety glasses and felt something strike his right eye. This was followed by tearing and blurred vision. He continued working for a few hours, but when the vision and tearing did not improve he went to a local emergency room. He was diagnosed with a corneal abrasion and sent home on topical antibiotics. An appointment with a local ophthalmologist was made for the following morning where his vision was found to be hand motions, a traumatic cataract had developed, and there was suspicion of an intraocular foreign body (IOFB). He was then referred emergently to the University of Iowa Ophthalmology On Call Service.

Past Ocular History: The patient had no previous eye trauma, disease, or surgery.

Medical History: Unremarkable

Medications: Moxifloxacin eye drops

Family and Social History: Noncontributory

Review of Systems: Negative

OCULAR EXAMINATION

Visual acuity

- ◆ Right eye (OD) HM
- ◆ Left eye (OS) 20/20

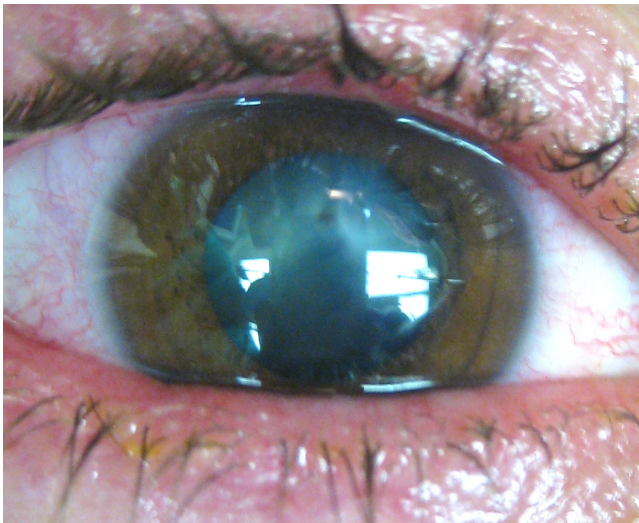


Figure 1: Right eye at presentation. Note the traumatic cataract

Intraocular pressure

- ◆ OD 16 mmHg
- ◆ OS 17 mmHg

Pupils: Dilated upon arrival by outside ophthalmologist

External and anterior segment examination (see Figure 1)

- ◆ OD: Conjunctiva mildly injected, no conjunctival lacerations, no subconjunctival hemorrhage. Cornea with central 1 mm Seidel-negative full-thickness laceration. Anterior chamber formed, 1+ cell, no hypopyon or hyphema. Dense traumatic cataract with disruption of anterior lens capsule. No view of the anterior vitreous.
- ◆ OS: Normal

Dilated fundus exam (DFE)

- ◆ OD: No view due to cataract
- ◆ OS: Normal

Since there was no view to the posterior pole and we suspected an IOFB due to the presence of the cataract and the mechanism of injury, the patient underwent echography of the right globe. (See Figure 2.)

CLINICAL COURSE

The patient was diagnosed with a corneal laceration, traumatic cataract, and a metallic IOFB. He was brought to the

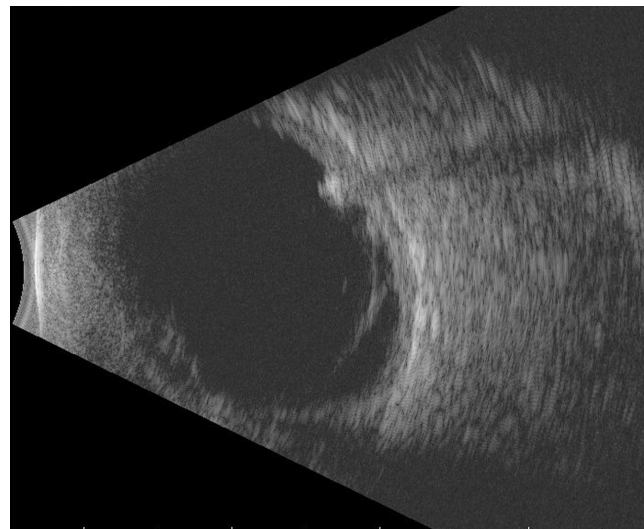


Figure 2: Ultrasound imaging revealed a dense cataract, mild vitreous hemorrhage with a tract-like membrane extending posteriorly, and a highly reflective mobile-appearing opacity lying posteriorly near the optic nerve with shadowing. There was no retinal detachment and no choroidal hemorrhage. The posterior scleral wall was intact. A posterior vitreous detachment was also present.

operating room urgently for corneal laceration repair, pars plana vitrectomy, lensectomy, and removal of the metallic IOFB. Prior to surgical repair, the patient received one dose of intravenous antibiotics (cefazolin 1000 mg and vancomycin 1250 mg) and had his tetanus shot updated.

Please View Video at: vimeo.com/258087704

Creating a water-tight globe was the first priority, which was accomplished by closing the corneal laceration with 2 10-0 nylon sutures (see Figure 3A). A peritomy was performed, followed by scleral incisions for 20-gauge vitrectomy. Using the vitrector, the cataract and posterior capsule were removed with care to preserve the anterior capsule for future intraocular lens placement. A core and periph-

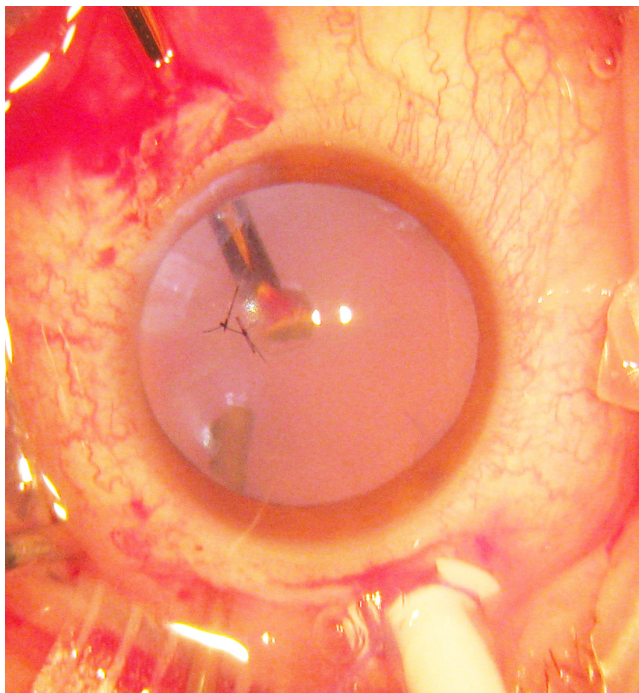
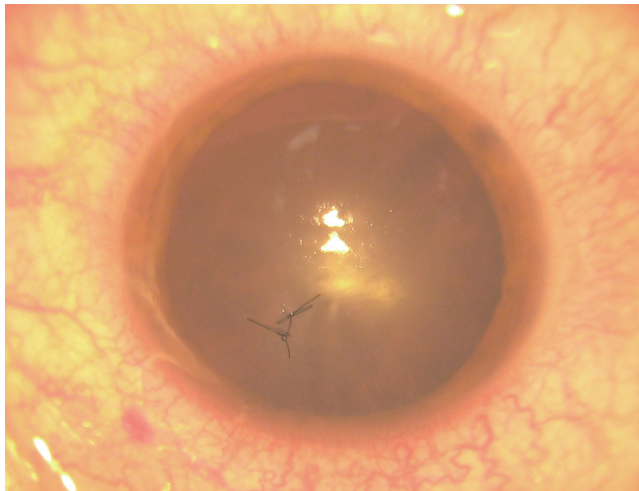


Figure 3. A. Photo in the operating room showing the 10-0 nylon sutures sealing the corneal laceration. B. Photo in the operating room of the intraocular rare earth magnet holding the metallic IOFB

eral vitrectomy were then performed. The retina was then examined and a metallic object with a surrounding inflammatory capsule was found embedded in the retina, temporal to the macula. Laser demarcation of the retina surrounding the metallic IOFB was performed using an endolaser. An intraocular rare earth magnet was inserted into the eye and used to engage and lift the IOFB anteriorly into the vitreous cavity (see Figure 3B). Forceps were then inserted to grab the IOFB from the magnet and remove it from the eye. A careful indented peripheral retinal examination was performed, which did not reveal any other retinal breaks or impact sites. The scleral and conjunctival incisions were closed with 7-0 Vicryl suture. Fifty mg of cefazolin and 10 mg of dexamethasone were injected beneath the conjunctiva.

Post-operatively the patient was instructed to use scopolamine twice daily and tobramycin-dexamethasone ointment 4 times daily in the operative eye. At the first post-operative week, vision in the right eye had improved to 20/60-1 with a +10.00 diopter (D) lens. At his 8 week follow-up, the patient's vision improved to 20/25-3 with a +10.0D lens.

He is to undergo secondary intraocular lens placement after all inflammation has subsided and his corneal stitches are removed. Until his secondary intraocular lens is placed, he will continue to wear a +13.00D contact lens in this aphakic right eye.

DISCUSSION

This case illustrates the stereotypical history for a metallic IOFB--a young male who is hammering or chiseling metal on metal and feels something strike the eye. Based on the history alone, the possibility of an IOFB should be thoroughly investigated, or the diagnosis can easily be missed due to the sometimes underwhelming external clinical appearance. Although he was evaluated in the emergency room on the day of his injury, this patient did not undergo a dilated exam, an ophthalmologist was not consulted the day of his injury, nor did he have any imaging to evaluate for the possibility of an IOFB. He was diagnosed with a corneal abrasion and no further work-up was done. The possibility of IOFB was not considered until the follow up visit with an ophthalmologist more than 16 hours after the injury. This delay in diagnosis can lead to a worse prognosis depending upon the location of the IOFB and the development of associated endophthalmitis, particularly if the IOFB is organic material or if the injury is sustained in a rural environment (Boldt 1989).

Epidemiology: Foreign bodies are one of the most common causes for ophthalmologic emergencies, which represent 3% of all United States emergency room visits (Babineau 2008). Risk factors include being male, not wearing eye protection, and performing a metal-on-metal task (hammering or chiseling a metal object) (Ehlers 2008, Babar, 2007, Napora 2009). The mean age at which injury occurred was 33 years. The foreign body most frequently enters the cornea, and approximately 65% of them land in the posterior segment (Ehlers 2008).

Treatment: Treatment depends on the location and scope of the injury but usually involves emergent removal of the IOFB with repair of any damaged structures. This may involve an anterior approach if the IOFB is located in the anterior chamber and may include corneal laceration repair, lensectomy, and/or anterior vitrectomy. A very careful retinal examination must be performed to identify an IOFB, the impact site of the IOFB, the presence of multiple IOFBs, and any other retinal damage including tears or detachments that may have occurred. If visualization of the retina is not possible due to a cataract or vitreous hemorrhage, imaging via a CT of the orbits or ultrasound of the globe is essential to evaluate for an IOFB. If the posterior segment is involved, a pars plana approach is utilized. The IOFB can be removed (if metallic) using an external or internal magnet or forceps. Typically, a pars plana vitrectomy is also performed. If a retinal tear or detachment is identified it is often repaired at the time of IOFB removal. If the IOFB is organic, or if the injury occurs in a rural setting, one may choose to culture the vitreous and IOFB and inject intravitreal antibiotics at the time of surgery as well.

Complications: One of the most common complications of an IOFB is a retinal detachment (14-26%). Other complications include: endophthalmitis (4-6%), corneal scar, cataract, angle recession glaucoma, vitreous hemorrhage, retained IOFB, blind/painful eye, and sympathetic ophthalmia (Ehlers 2008).

Prognostic factors: Patients with smaller wound lengths (under 2mm), IOFBs that are located in the anterior segment only, and those with a normal lens at presentation have the best prognosis. Negative prognostic factors include a longer wound length (greater than 3.5mm), posterior segment IOFB, poor initial visual acuity, and the presence of complications arising from IOFB (retinal detachment, endophthalmitis) (Ehlers 2008, Bai 2010, Unver 2009).

Endophthalmitis: Endophthalmitis is a concern with any type of IOFB. If the foreign body contains organic matter, intravitreal injection of gentamycin and either vancomycin or clindamycin was previously suggested (Boldt 1989); however, the use of ceftazidime has now largely replaced that of gentamycin in order to avoid aminoglycoside toxicity. Foreign bodies that result from metal-on-metal activity are less likely to contain organic material or bacterial contamination. In theory, the heat of the object as well as the anti-bacterial nature of ionized metals makes it difficult for bacteria to survive. It is still reasonable, however, to culture and treat with intravitreal antibiotic injections at the conclusion of the surgery.

DIAGNOSIS: Intraocular Foreign Body

<p>EPIDEMIOLOGY</p> <ul style="list-style-type: none"> ◆ Mean age 33 years ◆ Male ◆ Metal on metal mechanism of injury ◆ No eye protection 	<p>SIGNS</p> <ul style="list-style-type: none"> ◆ Penetrating corneal or scleral injury ◆ Traumatic cataract ◆ Iris defect, peaked pupil ◆ Vitreous hemorrhage ◆ Retinal tear/detachment ◆ Commotio retinae ◆ Ultrasound or CT showing highly reflective/hyperintense object
<p>SYMPTOMS</p> <ul style="list-style-type: none"> ◆ Decreased vision ◆ Eye pain ◆ Eye redness 	<p>TREATMENT</p> <ul style="list-style-type: none"> ◆ Complete ocular examination including detailed retinal examination ◆ Suture of corneal or scleral entrance wound ◆ IOFB removal using magnet or forceps, anterior or posterior approach depending on location of IOFB ◆ Possible pars plana vitrectomy ◆ Possible lensectomy if traumatic cataract ◆ Possible repair of retinal detachment

References

- Babar TF, Khan MT, Marwat MZ, Shah SA, Murad Y, Khan MD. Patterns of ocular trauma. *J Coll Physicians Surg Pak* 2007;17(3):148-153. [PubMed.gov/17374300](https://pubmed.ncbi.nlm.nih.gov/17374300/). DOI: 03.2007/JCPSP.148153
- Babineau MR, Sanchez LD. Ophthalmologic procedures in the emergency department. *Emerg Med Clin North Am* 2008;26(1):17-34, v-vi. [PubMed.gov/18249255](https://pubmed.ncbi.nlm.nih.gov/18249255/). DOI: 10.1016/j.emc.2007.11.003
- Bai HQ, Yao L, Meng XX, Wang YX, Wang DB. Visual outcome following intraocular foreign bodies: a retrospective review of 5-year clinical experience. *Eur J Ophthalmol* 2011;21(1):98-103. [PubMed.gov/20544679](https://pubmed.ncbi.nlm.nih.gov/20544679/)
- Boldt HC, Pulido JS, Blodi CF, Folk JC, Weingeist TA. Rural endophthalmitis. *Ophthalmology* 1989;96(12):1722-1726. [PubMed.gov/2622617](https://pubmed.ncbi.nlm.nih.gov/2622617/)
- Ehlers JP, Kunimoto DY, Ittoop S, Maguire JI, Ho AC, Regillo CD. Metallic intraocular foreign bodies: characteristics, interventions, and prognostic factors for visual outcome and globe survival. *Am J Ophthalmol* 2008;146(3):427-433. [PubMed.gov/18614135](https://pubmed.ncbi.nlm.nih.gov/18614135/). DOI: 10.1016/j.ajo.2008.05.021
- Napora KJ, Obuchowska I, Sidorowicz A, Mariak Z. [Intraocular and intraorbital foreign bodies characteristics in patients with penetrating ocular injury]. *Klin Oczna* 2009;111(10-12):307-312. [PubMed.gov/20169884](https://pubmed.ncbi.nlm.nih.gov/20169884/)
- Unver YB, Acar N, Kapran Z, Altan T. Prognostic factors in severely traumatized eyes with posterior segment involvement. *Ulus Travma Acil Cerrahi Derg* 2009;15(3):271-276. [PubMed.gov/19562551](https://pubmed.ncbi.nlm.nih.gov/19562551/)

Additional Reading

- Bourraoui R, Bouladi M, Mghaieth F, Chaker N, Sammouda T, El Matri L. A metallic intraocular foreign body discovered 26 years after ocular injury. *Tunis Med* 2016;94(3):245-246. [PubMed.gov/27575512](https://pubmed.ncbi.nlm.nih.gov/27575512/)
- Bypareddy R, Sagar P, Chawla R, Temkar S. Intraocular metallic foreign body causing branch retinal vein occlusion. *BMJ Case Rep* 2016;2016. [PubMed.gov/26994054](https://pubmed.ncbi.nlm.nih.gov/26994054/). DOI: 10.1136/bcr-2016-214745
- Ishii K, Nakanishi M, Akimoto M. Removal of intracamerular metallic foreign body by encapsulation with an intraocular lens injector. *J Cataract Refract Surg* 2015;41(12):2605-2608. [PubMed.gov/26796440](https://pubmed.ncbi.nlm.nih.gov/26796440/). DOI: 10.1016/j.jcrs.2015.10.046
- Lawrence DA, Lipman AT, Gupta SK, Nacey NC. Undetected intraocular metallic foreign body causing hyphema in a patient undergoing MRI: a rare occurrence demonstrating the limitations of pre-MRI safety screening. *Magn Reson Imaging* 2015;33(3):358-361. [PubMed.gov/25523608](https://pubmed.ncbi.nlm.nih.gov/25523608/). DOI: 10.1016/j.mri.2014.12.009
- Sindal MD, Sengupta S, Vasavada D, Balamurugan S. Retained intraocular iron foreign body presenting with acute retinal necrosis. *Indian J Ophthalmol* 2017;65(10):1036-1038. [PubMed.gov/29044081](https://pubmed.ncbi.nlm.nih.gov/29044081/). DOI: 10.4103/ijo.IJO_363_17

Citing this article

- Abrams P, Birkholz ES, Tarantola RM, Oetting TA, Russell SR. Intraocular Foreign Body: A Classic Case of Metal on Metal Eye Injury. EyeRounds.org. May 24, 2011; Available from: EyeRounds.org/cases/132-intraocular-foreign-body.htm

last updated: 05-24-2011

Idiopathic Juxtafoveal Telangiectasia Type II (Macular Telangiectasia type 2)

John J Chen, MD, PhD; Angela R McAllister, MD; Elliott H Sohn, MD
February 17, 2014

Chief complaint: Decreased vision and a central scotoma in both eyes (OU)

History of Present Illness: The patient is a 43-year-old male who presented with decreased vision and a central scotoma OU for the past 10 years, which has been getting progressively worse. He describes the vision as having a blurred spot in central of his vision bilaterally. The patient saw an optometrist two years ago and could not be refracted better than 20/40 in either eye. The patient has had intermittent photopsias in both eyes over the past two years. He denies floaters.

Past Ocular History: None

Past Medical History: Depression

Medications: sertraline, fish oil

Allergies: None

Family History: Non-contributory

Social History: The patient works as a chef. He does not smoke or drink alcohol.

Review of systems: All negative except for HPI

Ocular exam

Visual Acuity

- ◆ Right eye (OD): 20/60
- ◆ Left eye (OS): 20/60

Pupils: 5→3, no RAPD OU

Extraocular movements: Full OU

Confrontation visual fields: Full OU

Intra-ocular pressure:

- ◆ OD: 21 mmHg
- ◆ OS: 19 mmHg

External

Slit Lamp Exam

- ◆ Lid/Lashes: Normal OU
- ◆ Conjunctiva/Sclera: Normal OU
- ◆ Cornea: Clear OU
- ◆ Anterior Chamber: Deep and quiet OU
- ◆ Iris: Normal OU
- ◆ Lens: Clear OU
- ◆ Vitreous: Normal OU

Dilated Fundus Exam

The optic nerves have a cup-to-disc ratio of 0.2 OU. The macula of both eyes have a greyish sheen with superficial crystals, right angle venules, and telangiectatic vessels that are more prominent temporally. The vessels and peripheral retina are normal OU. There is no posterior vitreous detachment (Figure 1).

Ancillary Tests

Fundus photos demonstrate a greyish sheen with superficial crystals, right angle venules, and telangiectatic vessels that are more prominent temporally in the macula of both the right (A) and left (B) eyes (Figure 1).

Fluorescein angiography (FA) demonstrates telangiectatic vessels surrounding the fovea more prominent temporally with leakage OU (Figure 2).

Spectral domain optical coherence tomography (OCT) demonstrates small foveal cystoid cavities in both the right (A) and left (B) eyes. The central macular thickness is 331 microns OD and 320 microns OS (Figure 3).

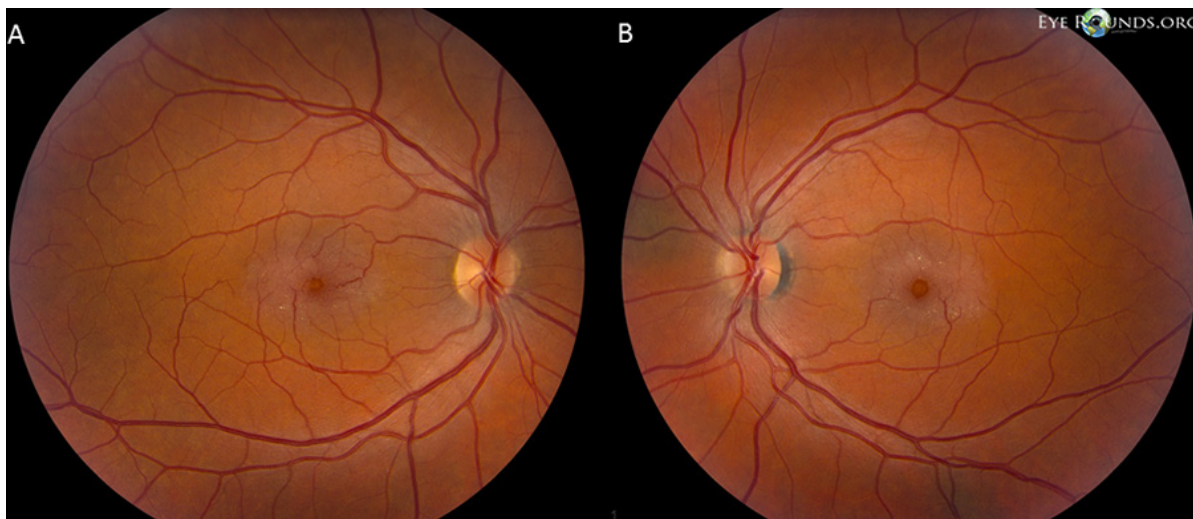


Figure 1. Fundus photos demonstrate a greyish sheen with superficial crystals, right angle venules, and telangiectatic vessels that are more prominent temporally in the macula of both the right (A) and left (B) eyes.

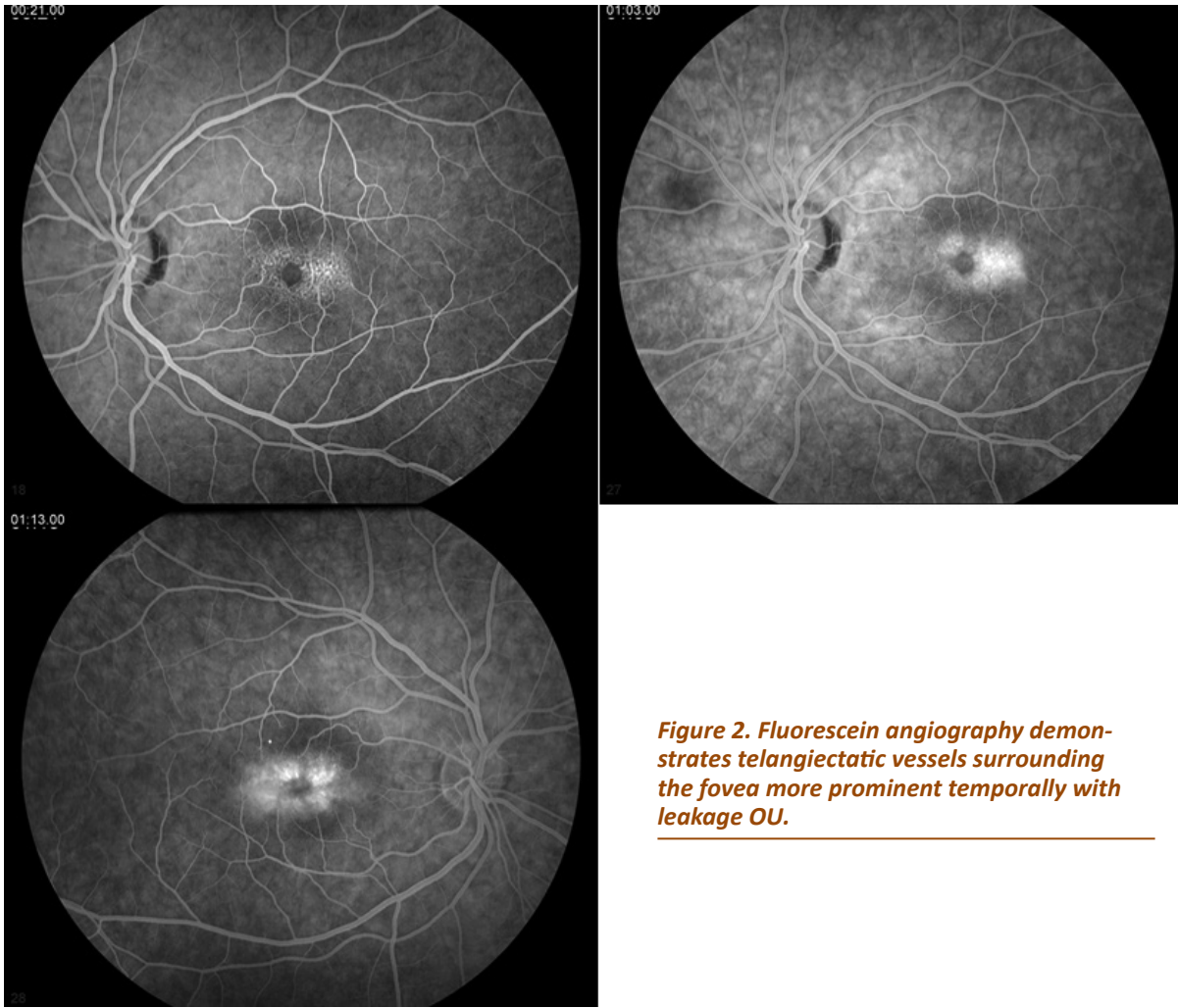


Figure 2. Fluorescein angiography demonstrates telangiectatic vessels surrounding the fovea more prominent temporally with leakage OU.

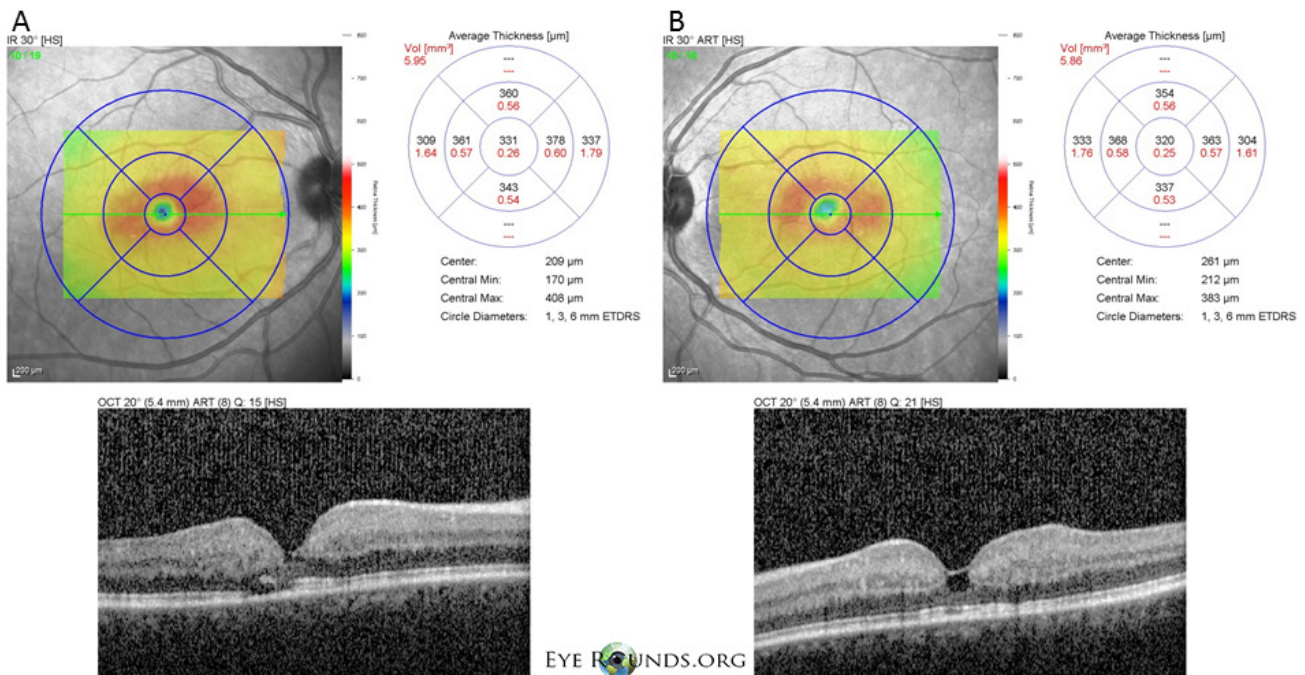


Figure 3: Spectral domain optical coherence tomography (OCT) demonstrates small foveal cystoid cavities in both the right (A) and left (B) eyes. The central macular thickness is 331 μm OD and 320 μm OS.

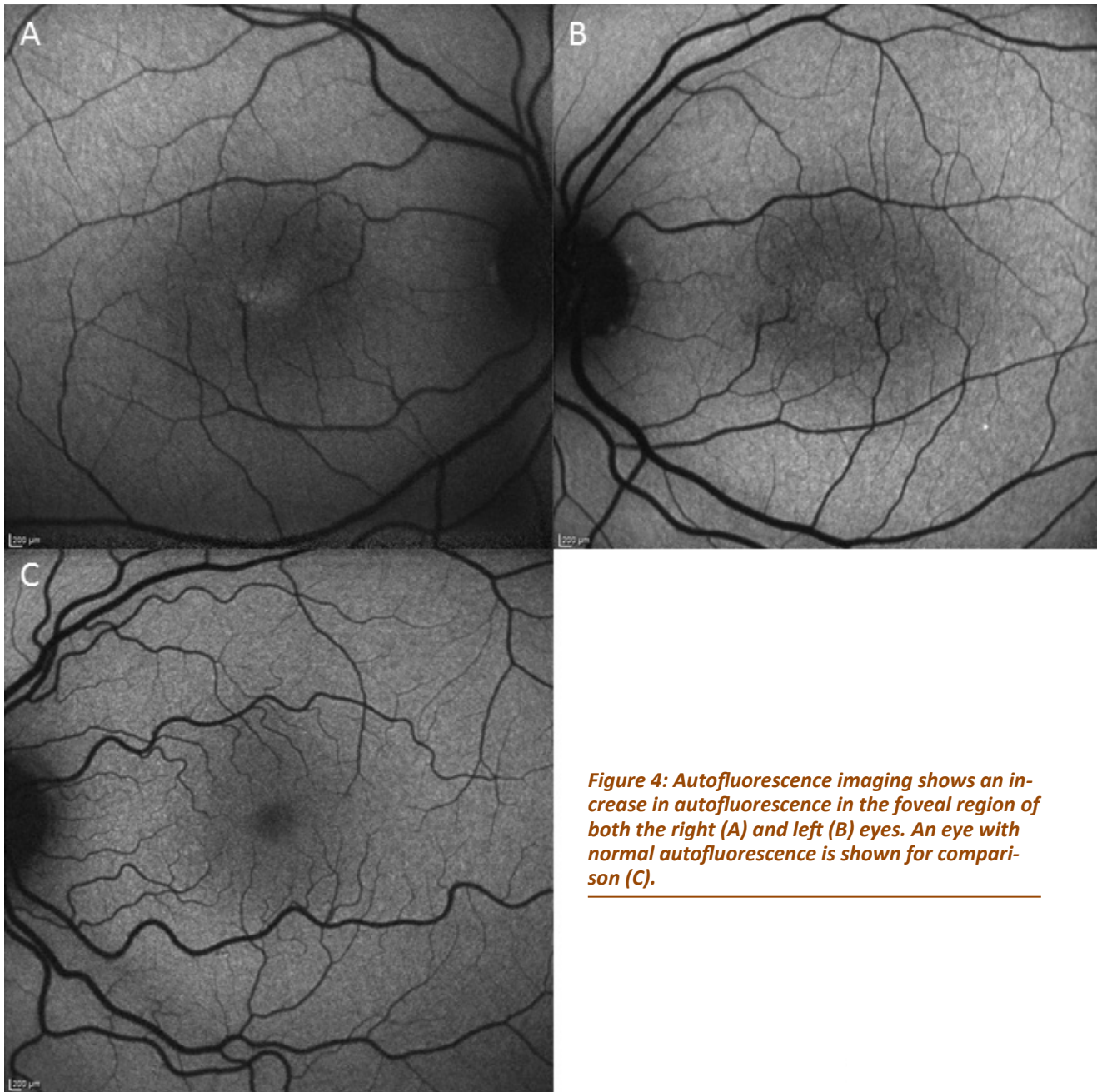


Figure 4: Autofluorescence imaging shows an increase in autofluorescence in the foveal region of both the right (A) and left (B) eyes. An eye with normal autofluorescence is shown for comparison (C).

Autofluorescence imaging shows a mild increase in autofluorescence in the foveal region of both the right (A) and left (B) eyes (Figure 4).

Diagnosis

Idiopathic Juxtafoveal telangiectasia, type II (Macular Telangiectasia type 2 or Mac Tel 2)

Discussion

Idiopathic juxtafoveal telangiectasia (IJFT), also known as idiopathic macular telangiectasia[1], is an uncommon

disorder characterized by telangiectatic vessels in the juxtafoveal region of one or both eyes. According to Gass, IJFT can be divided into three groups based upon phenotype:[2] type I is typically a unilateral disease characterized by parafoveal dilation of capillaries, microaneurysms, leakage, and lipid deposition; type II is the most common form of IJFT and typically presents with bilateral juxtafoveal telangiectasias with minimal exudate; type III is extremely rare and is characterized by occlusive telangiectasia. This review will focus on IJFT type II (macular telangiectasia type 2 or Mac Tel 2).

The prevalence of IJFT type II is not entirely known, but one large study estimated a prevalence of 1-5 in 22,062 while another study estimated it may be as high as 0.1%

in some populations.[3 ,4] Although IJFT can occur at any age, the mean age of onset is 55 years old. There is no predilection for gender and no known racial predilection. Although there are a few case reports of monozygotic twins with IJFT type II raising the possibility of genetic component, there is currently insufficient evidence from population studies to support genetic association. Several studies suggest that smoking may worsen disease.

IJFT type II is a bilateral disease, but can be asymmetric and may appear as a unilateral process early in the disease. Patients often present with complaints of blurred vision, metamorphopsia, or paracentral scotomas.

Early changes seen with IJFT type II include parafoveal graying of the retina, superficial crystalline deposits, subfoveal cystoid cavities, parafoveal telangiectasias, and right-angle vessels. Visual acuity decreases slowly and is often associated with hyperplasia of the retinal pigment epithelium (RPE). In approximately one-third of patients, deep retinal neovascularization with retinal feeders, subretinal neovascularization (SRNV), may occur as an acute complication and is then called the proliferative form.[1 ,5] The natural progression of the disease results in significant visual loss in the majority of patients with IJFT type II.[5] In a paper by Watzke et al., 15 or 20 eyes developed either central RPE hyperplasia or SRNV with decreased vision of 20/70 or worse over 15 years.[5]

Fundus findings of IJFT type II on biomicroscopy can be subtle, especially early in the disease process, and therefore imaging with FA, OCT, and fundus autofluorescence are important in making the diagnosis. FA highlights the parafoveal telangiectatic vessels, which demonstrate early hyperfluorescence with leakage. These are often more prominent temporal to the fovea. OCT demonstrates subfoveal cystoid spaces, usually without cystoid macular edema.[6 ,7] In more advanced disease, photoreceptor disruption and outer retinal atrophy are present on OCT.[7] Fundus autofluorescence findings are pathognomonic for MacTel II, showing a loss of the physiologic hypoautofluorescence—i.e. increased autofluorescence—in the fovea. [8 ,9]

The pathogenesis of IJFT type II is unclear, but may involve abnormalities in the parafoveolar Muller cells rather than a primary abnormality of retinal capillaries.[10] Muller cells are important for the health of the retinal capillary endothelium and the surrounding retina.[11 ,12] It has been postulated that Muller cell dysfunction in IJFT type II results in endothelial degeneration, which may lead to retinal capillary proliferation and telangiectasia.[6 ,7] In support of this, perifoveal depletion of Muller cells has been seen on histopathology of patients with IJFT type II.[13] The superficial crystals seen in patients with IJFT type II are thought to represent to footplates of degenerated Muller cells.[7 ,14] In addition, it has been speculated that the spaces seen on OCT in IJFT type II represent tissue loss from retinal degeneration, specifically due to the dysfunction or loss of Muller cells, rather than fluid filled cystic spaces.[1,12,13]

A better understanding of the disease mechanism in IJFT type II is important because there remains no definitive treatment for the visual loss seen in the nonproliferative form of IJFT II. Bevacizumab has been shown to be effective in the treatment of the SRNV associated with IJFT type II, but does not appear to consistently affect the course or cystic changes in nonproliferative IJFT.[15-19] Similarly, ranibizumab failed to show a functional benefit in a prospective interventional trial of patients with nonproliferative IJFT type II, although was shown to cause a significant reduction in retinal thickness and a decrease in leakage on FA.[20] Oral carbonic anhydrase inhibitors were also shown to cause a significant reduction in retinal thickness, but did not significantly improve visual acuity.[21] Multiple other interventions have been tried, including focal grid laser,[22] photodynamic therapy,[23] and intravitreal triamcinolone,[24] with no clear improvement in either the cystoid cavities or the visual acuity in patients with IJFT type II. Finding an effective treatment is important because the majority of patients with IJFT type II develop a significant decline in vision over time.

Our patient highlights all of the early findings of non-proliferative IJFT type II, including parafoveal graying of the retina, superficial crystalline retinal deposits, right angle vessels, and parafoveal telangiectasias (Figure 1). FA further highlighted the parafoveal telangiectasias, which demonstrated prominent leakage and staining of the retina (Figure 2). OCT demonstrated characteristic subfoveal cystoid spaces (Figure 3). Finally, fundus autofluorescence showed a mild increase in foveal autofluorescence consistent with IJFT type II (Figure 4). Fortunately, our patient did not show signs of more advanced disease, including no evidence of retinal pigment epithelium hyperplasia or SRNV. The patient was initially started on PO methazolamide 50mg bid and demonstrated a decrease in macular thickness within 1.5 months of treatment (Figure 5). He was then changed to PO acetazolamide secondary to insurance and had a continued decrease in macular thickness and subfoveal cysts over the next year despite only tolerating 125mg bid (Figure 5). There was also a mild non-significant improvement in visual acuity to 20/50 OD and 20/40 OS at the most recent follow-up.

Differential Diagnosis

- ◆ diabetic macular edema
- ◆ pseudophakic macular edema
- ◆ lamellar/macular hole
- ◆ Coats disease
- ◆ retinal vein occlusion
- ◆ radiation retinopathy
- ◆ Eales disease
- ◆ ocular ischemic syndrome
- ◆ crystalline retinopathy
- ◆ IJFT type I and III (see table).
- ◆ Proliferative disease can be mistaken for choroidal neovascularization from age-related macular degeneration.

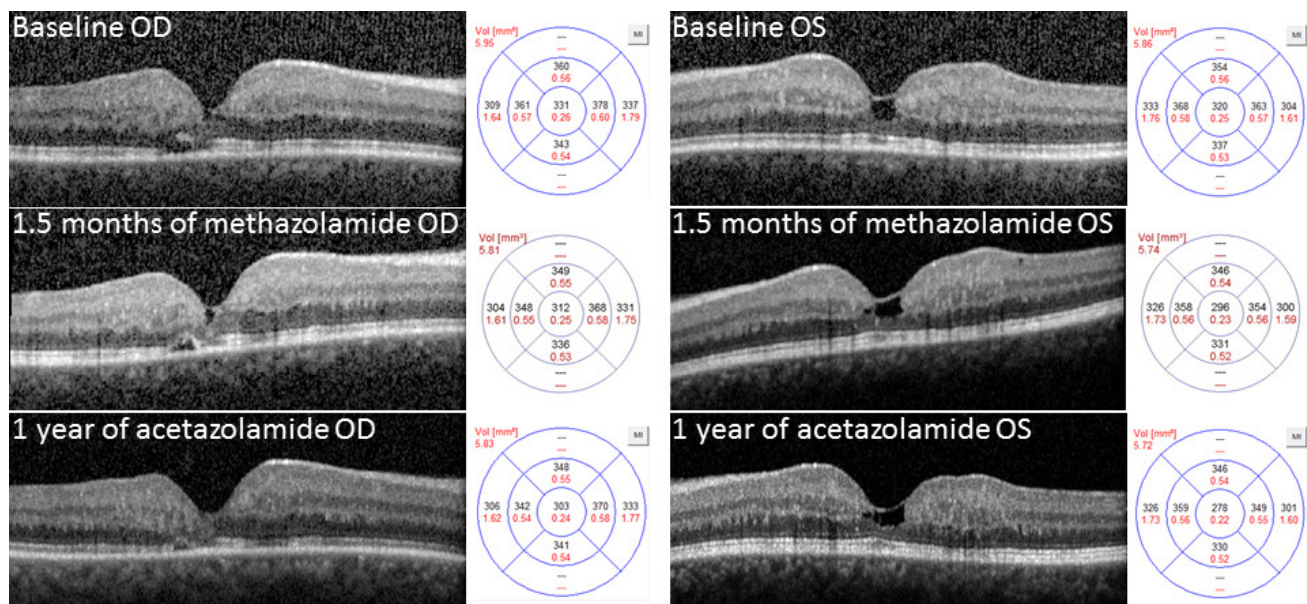


Figure 5: Spectral domain optical coherence tomography (OCT) demonstrates subfoveal cyst-like spaces OU at baseline. The retinal thickness map is shown to the right (CMT = 331 µm OD, CMT = 320 µm OS). After 1.5 months of methazolamide, there was a reduction in the macular thickness (CMT = 312 µm OD, CMT = 296 µm OS). After one year of treatment with acetazolamide, there was a further decrease in the cystic spaces and macular thickness (CMT = 303 µm OD, CMT = 278 µm OS). Images were obtained in the same meridian and registered to the original visit.

Types of IJFT*	Epidemiology	Signs and symptoms	Treatment	Prognosis
IJFT type I	Predominantly male. Mean age 40yo.	Unilateral prominent visible telangiectatic retinal capillaries with macular edema and lipid deposition/exudate.	Laser photocoagulation may reduce exudation and stabilize vision.	Variable, majority progress to 20/70 or worse if untreated
IJFT type II	Equal gender predilection. Mean age 55yo.	Bilateral parafoveal graying of the retina, superficial crystalline deposits, subfoveal cystoid cavities, parafoveal telangiectasias (more evident on FA), right-angle vessels, hyperplasia of the RPE. SRNV develops in approximately 1/3 of patients.	No known treatment for non-proliferative IJFT type II. Intravitreal anti-VEGF for SRNV.	Variable, 2/3 of eyes will progress to 20/70 or worse associated with RPE hyperplasia or SRNV.
IJFT type III	Very rare	Bilateral perifoveal capillary obliteration, capillary telangiectasia, and minimal exudation, associated with systemic or cerebral disease.	Unknown due to its rarity	Variable, mostly unknown due to its rarity

* Idiopathic juxtafoveal telangiectasia (IJFT) is also known as idiopathic macular telangiectasia. According to the idiopathic macular telangiectasia classification, IJFT type I is named aneurysmal telangiectasia and IJFT type II is named perifoveal telangiectasia. Because of its rarity, IJFT type III has been omitted from the idiopathic macular telangiectasia classification.[1]

Table: Characteristics of the three types of idiopathic juxtafoveal telangiectasia

<p>Epidemiology (IJFT type II)</p> <ul style="list-style-type: none"> ◆ Prevalence: 1-5 in 22,062, but may be as high as 0.1%. ◆ Mean age of presentation is 55 years old ◆ Equal gender predilection ◆ Bilateral disease 	<p>Symptoms</p> <ul style="list-style-type: none"> ◆ Decreased vision ◆ Central or parafoveal scotoma ◆ Metamorphopsia
<p>Signs</p> <ul style="list-style-type: none"> ◆ Non-proliferative IJFT type II: bilateral parafoveal graying of the retina, superficial crystalline deposits, subfoveal cystoid cavities, parafoveal telangiectasias (more evident on FA), right-angle vessels, hyperplasia of the retinal pigment epithelium. Findings are often more prominent in the temporal parafoveal region, especially early in the disease. <ul style="list-style-type: none"> • FA demonstrates parafoveal telangiectatic capillaries with leakage, often more prominent temporally. • OCT demonstrates subfoveal cystoid cavities. In more advanced disease, photoreceptor disruption and outer retinal atrophy are present. • Fundus autofluorescence demonstrates increased foveal autofluorescence. ◆ Proliferative IJFT type II: subretinal neovascularization. 	<p>Treatment</p> <ul style="list-style-type: none"> ◆ For the non-proliferative form with macular cystoid cavities, oral carbonic anhydrase inhibitors have been shown to cause a significant reduction in retinal thickness, but did not significantly improve visual acuity.[21] Otherwise, no proven treatment exists. ◆ Anti-VEGF therapy, ranibizumab or bevacizumab, are effective in the treatment of subretinal neovascularization seen in the proliferative form of IJFT type II. ◆ Smoking may be a modifiable risk factor.

References

1. Yannuzzi LA, Bardal AM, Freund KB, Chen KJ, Eandi CM, Blodi B. Idiopathic macular telangiectasia. Arch Ophthalmol 2006;124(4):450-60.
2. Gass JD, Blodi BA. Idiopathic juxtafoveal retinal telangiectasis. Update of classification and follow-up study. Ophthalmology 1993;100(10):1536-46.
3. Aung KZ, Wickremasinghe SS, Makeyeva G, Robman L, Guymer RH. The prevalence estimates of macular telangiectasia type 2: the Melbourne Collaborative Cohort Study. Retina 2010;30(3):473-8.
4. Klein R, Blodi BA, Meuer SM, Myers CE, Chew EY, Klein BE. The prevalence of macular telangiectasia type 2 in the Beaver Dam eye study. Am J Ophthalmol 2010;150(1):55-62 e2.
5. Watzke RC, Klein ML, Folk JC, Farmer SG, Munsen RS, Champfer RJ, Sletten KR. Long-term juxtafoveal retinal telangiectasia. Retina 2005;25(6):727-35.
6. Nowilaty SR, Al-Shamsi HN, Al-Khars W. Idiopathic juxtafoveal retinal telangiectasis: a current review. Middle East Afr J Ophthalmol 2010;17(3):224-41.
7. Cohen SM, Cohen ML, El-Jabali F, Pautler SE. Optical coherence tomography findings in nonproliferative group 2a idiopathic juxtafoveal retinal telangiectasis. Retina 2007;27(1):59-66.
8. Schmitz-Valckenberg S, Fan K, Nugent A, Rubin GS, Peto T, Tufail A, Egan C, Bird AC, Fitzke FW. Correlation of functional impairment and morphological alterations in patients with group 2A idiopathic juxtafoveal retinal telangiectasia. Arch Ophthalmol 2008;126(3):330-5.
9. Wong WT, Forooghian F, Majumdar Z, Bonner RF, Cunningham D, Chew EY. Fundus autofluorescence in type 2 idiopathic macular telangiectasia: correlation with optical coherence tomography and microperimetry. Am J Ophthalmol 2009;148(4):573-83.
10. Gass JD. Histopathologic study of presumed parafoveal telangiectasis. Retina 2000;20(2):226-7.
11. Tout S, Chan-Ling T, Hollander H, Stone J. The role of Muller cells in the formation of the blood-retinal barrier. Neuroscience 1993;55(1):291-301.
12. Newman E, Reichenbach A. The Muller cell: a functional element of the retina. Trends Neurosci 1996;19(8):307-12.
13. Powner MB, Gillies MC, Tretiach M, Scott A, Guymer RH, Hageman GS, Fruttiger M. Perifoveal muller cell depletion in a case of macular telangiectasia type 2. Ophthalmology 2010;117(12):2407-16.
14. Gass JDM. Stereoscopic atlas of macular diseases : diagnosis and treatment. 4th ed. St. Louis: Mosby, 1997.
15. Roller AB, Folk JC, Patel NM, Boldt HC, Russell SR, Abramoff MD, Mahajan VB. Intravitreal bevacizumab for treatment of proliferative and nonproliferative type 2 idiopathic macular telangiectasia. Retina 2011;31(9):1848-55.

16. Mandal S, Venkatesh P, Abbas Z, Vohra R, Garg S. Intravitreal bevacizumab (Avastin) for subretinal neovascularization secondary to type 2A idiopathic juxtafoveal telangiectasia. *Graefes Arch Clin Exp Ophthalmol* 2007;245(12):1825-9.
17. Konstantinidis L, Mantel I, Zografos L, Ambresin A. Intravitreal ranibizumab as primary treatment for neovascular membrane associated with idiopathic juxtafoveal retinal telangiectasia. *Graefes Arch Clin Exp Ophthalmol* 2009;247(11):1567-9.
18. Matsumoto Y, Yuzawa M. Intravitreal bevacizumab therapy for idiopathic macular telangiectasia. *Jpn J Ophthalmol* 2010;54(4):320-4.
19. Kovach JL, Rosenfeld PJ. Bevacizumab (avastin) therapy for idiopathic macular telangiectasia type II. *Retina* 2009;29(1):27-32.
20. Charbel Issa P, Finger RP, Kruse K, Baumuller S, Scholl HP, Holz FG. Monthly ranibizumab for nonproliferative macular telangiectasia type 2: a 12-month prospective study. *Am J Ophthalmol* 2011;151(5):876-886 e1.
21. Chen JJ, Sohn EH, Folk JC, Mahajan VB, Kay CN, Boldt HC, Russell SR. Decreased Macular Thickness in Nonproliferative Macular Telangiectasia Type 2 with Oral Carbonic Anhydrase Inhibitors. *Retina* 2014;34(7):1400-6. doi: 10.1097/IAE.0000000000000093
22. Park DW, Schatz H, McDonald HR, Johnson RN. Grid laser photocoagulation for macular edema in bilateral juxtafoveal telangiectasis. *Ophthalmology* 1997;104(11):1838-46.
23. De Lahitte GD, Cohen SY, Gaudric A. Lack of apparent short-term benefit of photodynamic therapy in bilateral, acquired, parafoveal telangiectasis without subretinal neovascularization. *Am J Ophthalmol* 2004;138(5):892-4.
24. Wu L, Evans T, Arevalo JF, Berrocal MH, Rodriguez FJ, Hsu M, Sanchez JG. Long-term effect of intravitreal triamcinolone in the nonproliferative stage of type II idiopathic parafoveal telangiectasia. *Retina* 2008;28(2):314-9.

Suggested Citation Format

Chen JJ, McAllister, AR, Sohn EH. Idiopathic Juxtafoveal Telangiectasia Type II (Macular Telangiectasia type 2). *EyeRounds.org*. February 17, 2014; Available from: EyeRounds.org/cases/185-JXT.htm

last updated: 2/17/2014

Vitreous Syneresis: An Impending Posterior Vitreous Detachment (PVD)

Elizabeth Gauger, MD; Eric K. Chin, MD; Elliott H. Sohn, MD

Nov 17, 2014

Chief Complaint

New flashing lights and floating "spots"

History of Present Illness

A 60-year-old female presented to the eye clinic with flashing lights and new floaters in the left eye for the past four days. The floaters were described as "large and stringy", and the flashing lights occurred in the temporal periphery "like a camera flash going off repeatedly". The flashes of light were also worse in a dimly lit environment. She denied any "shades" or "curtains" in her peripheral vision. She denied any recent head trauma or falls. She had no known personal or family history of retinal tears or detachment, and she had no complaints in her right eye. She had no other complaints at presentation.

Past Ocular History

- ◆ Glaucoma suspect based on mild optic nerve cupping
- ◆ Myopia, recent manifest refraction = -3.75 right eye, -2.75 left eye
- ◆ No prior ocular surgeries

Eye Drops: None

Past Medical History: Unremarkable

Medications: None

Allergies: No known drug allergies

Family History: No known eye disease

Ocular Exam

Visual Acuity (Snellen) at distance with correction

- ◆ Right eye (OD): 20/25, no improvement with pinhole
- ◆ Left eye (OS): 20/20, no improvement with pinhole

Ocular motility: Full both eyes (OU)

Intraocular Pressure (IOP), via Tonopen: 21 mm Hg OD, 20 mm Hg OS

Pupils: Equally reactive in each eye from 4 mm in the dark to 2 mm in the light. No relative afferent pupillary defect in either eye.

Slit Lamp Exam

- ◆ **OD:** Mild nuclear sclerosis.
- ◆ **OS:** Mild nuclear sclerosis. Vitreous syneresis, but negative Shafer's sign/no "tobacco dust" (Figure 1).

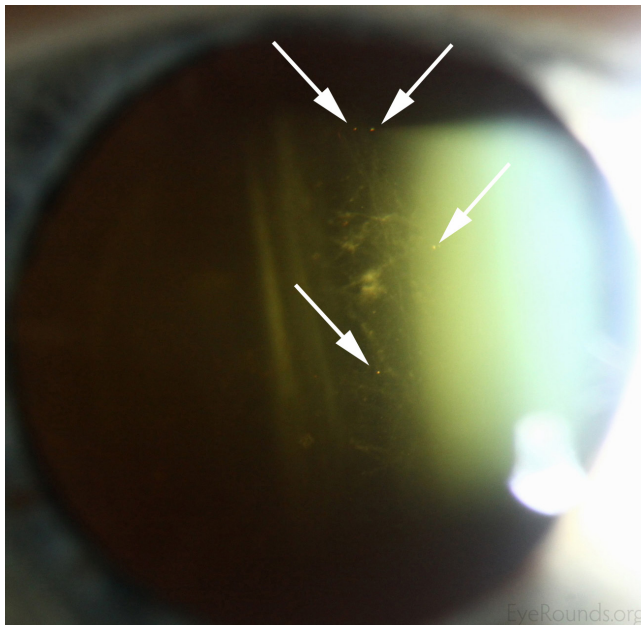


Figure 1: White arrows demonstrate a positive Shafer's sign in a different patient. This patient had strands of vitreous syneresis, which are seen as wispy material just below the white arrows. Our patient did not have Shafer's sign.

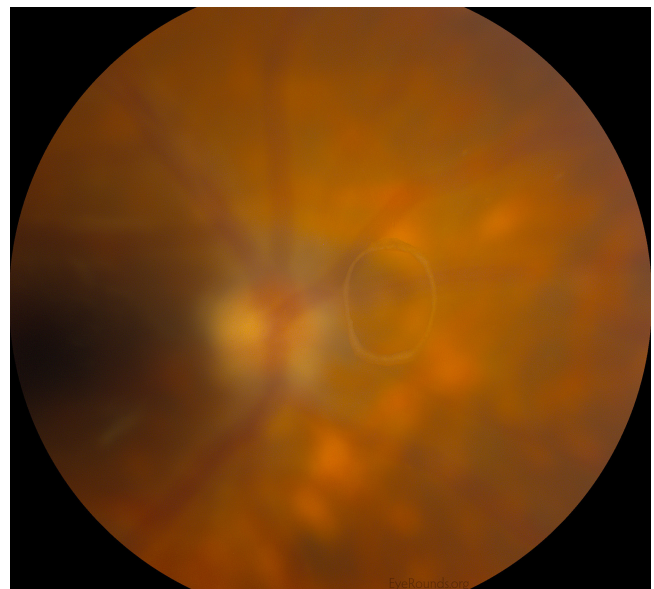


Figure 2: Example of a Weiss ring, indicating detachment of the vitreous from the optic nerve. The optic nerve, retina, and retinal vessels are purposely out of focus because the Weiss ring is located more anteriorly in the vitreous. Photo Credit: Matt Weed, MD.

Dilated Fundus Exam

- ◆ OD
 - Vitreous: Normal; no Weiss ring
 - Optic nerve: 0.5 cup:disc ratio
 - Macula: Normal
 - Vessels: Normal
 - Periphery: No holes, tears, or subretinal fluid on 360 degree scleral depressed examination
- ◆ OS
 - Vitreous: syneresis; no Weiss ring (Figure 2).
 - Optic nerve: 0.5 cup:disc ratio
 - Macula: Normal
 - Vessels: Normal
 - Periphery: No holes, tears, or subretinal fluid on 360 degree scleral depressed examination

Clinical Course

The patient had no evidence of a retinal tear or detachment in either eye on 360 degree scleral depressed examination. There was suggestion of an evolving posterior vitreous detachment based on the vitreous syneresis seen in the anterior vitreous and symptoms consistent with separation of the vitreous from the retina. The patient was instructed to monitor her symptoms closely. She was instructed to specifically watch for an increase in amount of severity of her flashes and floaters, or the development of new "curtains" in the periphery of her vision. Follow-up was scheduled for one month for repeat scleral depressed examination in both eyes, sooner if needed.

Discussion

A posterior vitreous detachment (PVD) is defined as the separation of the posterior hyaloid face from the neurosensory retina. At birth, the vitreous "gel" fills the back of the eye and normally has Jello-like consistency. As one ages, the vitreous undergoes "syneresis," in which it becomes more fluid or liquid-like. The pockets of fluid in the vitreous cavity give the patient a sensation of "floaters" or "cobwebs." As the pockets of fluid collapse on themselves, they gently pull on the retina giving the patient a sensation of "flashes of light" or photopsias. Eventually, the vitreous may completely separate from the neurosensory retina, which is called a *posterior vitreous detachment* or "PVD" that is confirmed clinically with observation of Weiss ring on fundoscopic examination. This usually occurs in one eye at a time, but a PVD in the contralateral eye often occur 6 to 24 months later (6). In high myopia, PVD develops increasingly with age and the degree of myopia (7). As the vitreous gel separates, it may cause a tear in the neurosensory retina which is fragile and thin like a piece of tissue paper. A retinal tear can allow the liquid part of the vitreous to escape behind the retina and separate the retina from its underlying attachments (and blood supply). This is known as a rhegmatogenous retinal detachment. Typically, however, the vitreous separates without any ill effects on the retina.

Risk Factors

Patients are at greatest risk for a symptomatic PVD in the 5th to 7th decade of life, although it can occur much earlier. Most often patients are myopic (near-sighted). High myopes (i.e. refraction of -6.00 or greater) are at increased risk of complications related to a PVD due to thinning of the retina as it is stretched along a longer eye. Other predisposing risk factors for a PVD include a family history of retinal tears or detachments, intraocular inflammation (uveitis), trauma, and previous eye surgery.

Signs and Symptoms

The patient in this case exhibited the typical signs and symptoms of an acutely evolving posterior vitreous detachment, including new onset of flashes and floaters. The flashes of light (or photopsias) are often described as a camera flash going off repeatedly in the patient's peripheral vision. The photopsias tend to be more noticeable in dimly lit environments. They are caused by mechanical traction on the retina, caused by the vitreous gel "tugging" on the underlying neurosensory retina.

Patients may also endorse new floaters. Generally these are described by patients as large, wispy objects moving around when they move their eye in different directions of gaze. Sometimes, they will even describe it as something "running" across their vision, like a small mouse, fly, or cobweb in the central or peripheral vision. These are generally a nuisance to the patient, but benign and require only reassurance when in isolation.

Worrisome signs suggestive of a complication related to a retinal tear or detachment may include many, new, *tiny* floaters often described as "gnats" or "pepper" in the patient's vision. Often these new floaters are "too many to count." This is a worrisome sign, because this may indicate pigment released from the retina and surrounding structures, or red blood cells from a broken retinal vessel. This may indicate that the part of the retina has been torn or detached. Other worrisome signs include a shade or a curtain of vision, which may indicate a retinal detachment where the neurosensory retina has been detached from its underlying connections.

Causes

An acute PVD is most commonly caused by the natural process of vitreous shrinkage and liquefaction over time. As mentioned above, as the gel liquefies, the vitreous body collapses and peels off areas of adhesion to the neurosensory retina. The vitreous is normally most strongly adherent to the vitreous base (peripherally and anteriorly), optic nerve, retinal vessels, and fovea center. Other areas of strong adherence are to retinal scars or lattice degeneration. With an acute PVD, symptoms often develop without warning or inciting event. However, in cases of ocular or head trauma, a "traumatic PVD" may occur.

Types of PVD

Generally, an acute PVD develops suddenly, but becomes complete within weeks of onset of symptoms. A PVD is considered "partial" when the vitreous jelly is still attached at the macula/optic nerve head and "complete" once total separation of the jelly from the optic nerve head has occurred. Figure 3 shows a horizontal cross section of the neurosensory retina through the fovea center with partial separation of the vitreous gel from the underlying retina. Notice that it is still attached to the optic nerve (right).

Accurate staging of this PVD would require evaluation of the peripheral retina; however, OCT confirms that it is only a partial PVD and a complete Weiss ring is unlikely to be present. When a PVD is "complete," the examiner will classically observe a Weiss ring on exam (Figure 2). A "Weiss ring" is the circular peripapillary attachment that is visible within the vitreous after it has become detached from the optic nerve head.

PVDs can also be associated with vitreous hemorrhage. The presence of blood in the vitreous cavity can make the patient's vision quite poor, and some patients will describe seeing "tiny red floaters" from the red blood cells. It usually is caused by the tearing of a retinal vessel at the time of the vitreous gel peeling off the retina. Spontaneous vitreous hemorrhage in the setting of an acute PVD strongly suggests there may be a retinal tear or detachment. While the blood will likely clear slowly over time, the clinician should have a high index of suspicion for a retinal tear or detachment. The patient should be followed closely to ensure that this is not the case. B-scan ultrasonography may be necessary to assess for retinal tears and detachments if the vitreous hemorrhage is severe enough to obscure the examiner's view.

Complications

Retinal Tear/Detachment

Retinal tears (Figure 4) occur in 10-15% of patients with acute, symptomatic PVDs. For this reason, it is important to have a dilated scleral depressed examination. If a retinal tear occurs, this in and of itself does not have a poor prognosis. Complications arise when the liquefied vitreous escapes through the tear and behind the retina resulting in a neurosensory retinal detachment. If a tear is discovered early, laser demarcation (i.e. "laser barricade" or "laser retinopexy") is a procedure that can be performed in the clinic to prevent progression to a retinal detachment. However, if a rhegmatogenous retinal detachment (Figure 5) results, the patient may need to undergo a more involved surgery to reattach the retina. In addition to being a more involved procedure that often warrants going to the operating room, the prognosis may be worse depending on the detachment's severity.

Vitreous hemorrhage

A hemorrhagic PVD (i.e. vitreous hemorrhage secondary to a PVD) can occur in about 7.5% of PVDs. This occurs when a retinal blood vessel is torn during vitreous separation. The risk of having an underlying retinal tear increases to nearly 70% in the case of a hemorrhagic PVD. Symptoms of a hemorrhagic PVD may include a more significant decrease in vision secondary to the blood dispersed throughout the vitreous cavity.

Recommendations

If one experiences similar symptoms as the patient above (e.g. sudden onset of many new floaters and/or flashes of lights), it is recommended the patient undergo a dilated fundus examination with complete 360 degree scleral

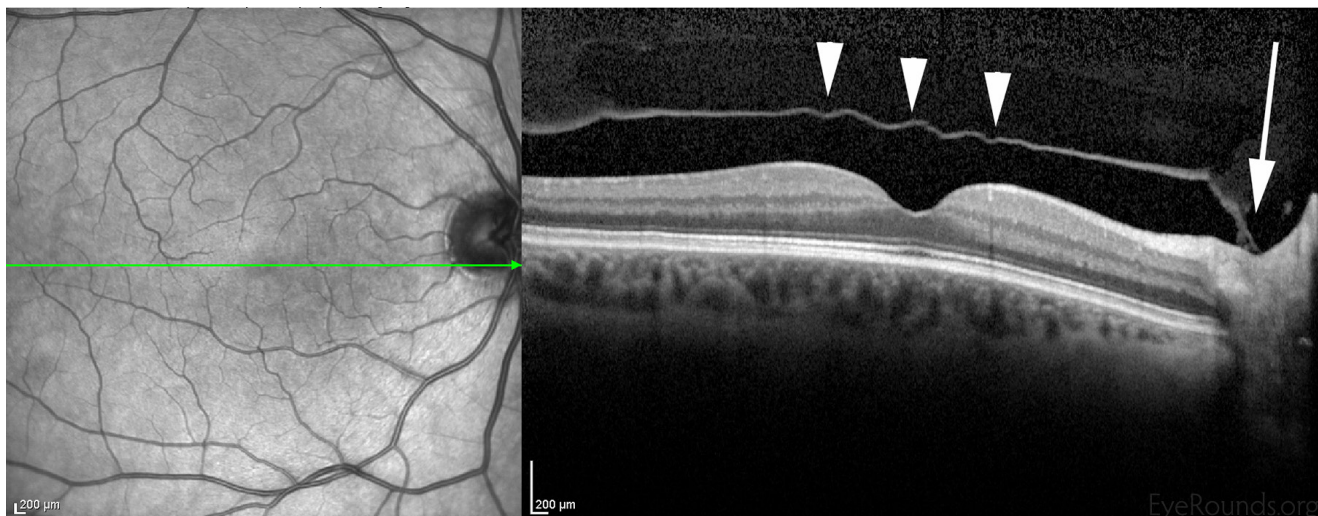


Figure 3: Optical coherence tomography (OCT) of the macula from a patient who had complete separation of the vitreous (arrowhead) from the fovea center. Note that the vitreous is still attached at the optic nerve (right side, large arrow), indicating only a partial PVD has occurred.

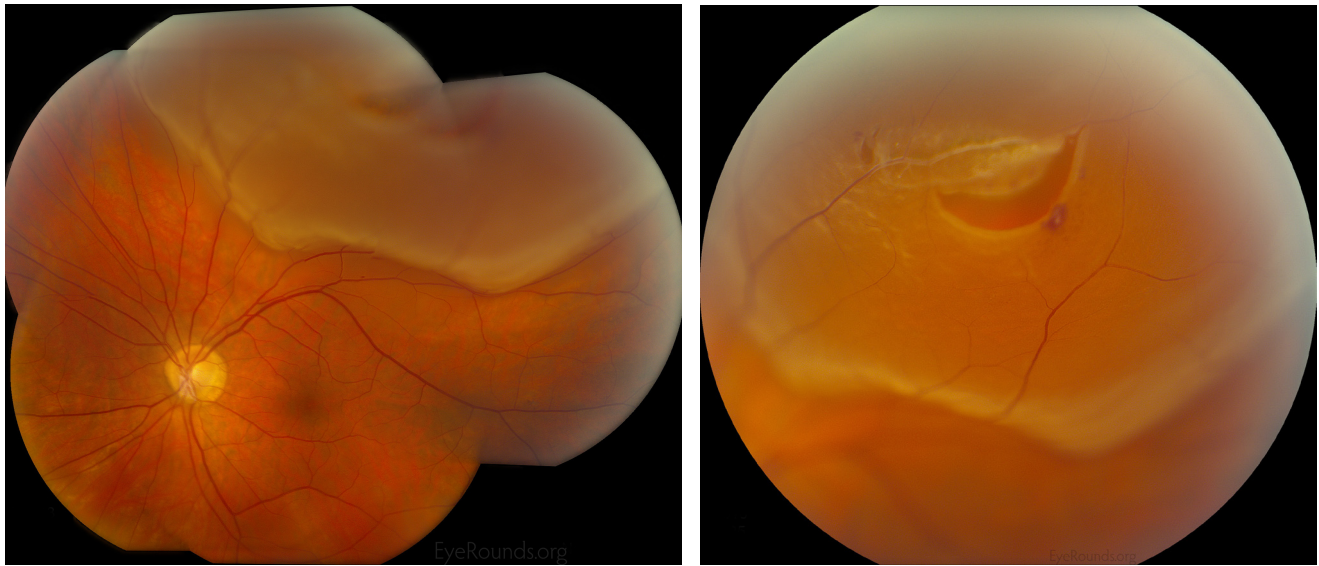


Figure 4: High magnification of a peripheral horseshoe retinal tear adjacent to lattice degeneration, a retinal vessel, and specks of intraretinal hemorrhage. Photo credit: Jesse Vislisel, MD.

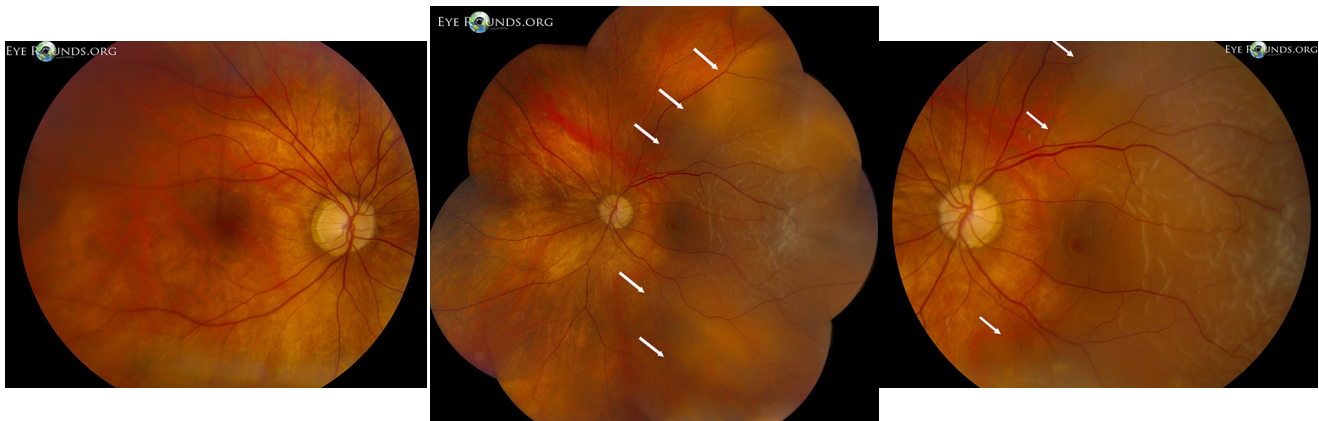


Figure 5: Low magnification montage, rhegmatogenous macula-off retinal detachment (temporal to the white arrows). Photo Credit: Eric Chin, MD.

depressed examination within 12-24 hours. The examiner should be an eye physician who feels confident in examining the peripheral retina, as this is typically where retinal tears and detachments originate. The examiner will likely examine both eyes thoroughly, even the asymptomatic eye, to ensure no pathology exists. Often times, having a tear in one eye may suggest a predisposition to having additional tears or retinal pathology in the same or contralateral eye. If an isolated retinal tear is found, laser demarcation will likely be advised. If a retinal detachment is present, immediate referral to a retina specialist is warranted.

If an evolving acute PVD is found without any retinal tears or detachments, it is commonly advised to have a follow-up scleral depressed examination approximately one month later. Follow-up varies based on severity, symptoms, and other risk factors. If the PVD is hemorrhagic, or other more concerning signs are present on exam, the examiner may recommend follow-up at more frequent intervals. Although there are no preventative measures, it is gener-

ally recommended that the patient avoids heavy exertion, lifting, or bending over in the setting of acute PVD with vitreous hemorrhage so that the blood in the vitreous cavity can settle inferiorly away from the center vision. Elevating the head of the bed will allow gravity to settle the blood inferiorly, out of the visual axis. Patients may continue their blood-thinning medications, as there is no evidence that the discontinuation of antiplatelet or anticoagulant agents speeds the recovery of vitreous hemorrhage.

When to call your eye doctor

After the initial examination, the symptoms may persist but hopefully diminish with time. Follow-up at one month is typically adequate barring any new or changing symptoms. Symptoms which would require a more urgent follow-up exam, include many, new, tiny floaters (like "gnats" or "pepper") in the vision, new or increasing frequency of flashes in the vision, or a new shade or curtain of darkness in the visual field.

Table 1. Acute Posterior Vitreous Detachment (PVD)

Risk factors	Older age (5th and 7th decades of life) Myopia Intraocular inflammation Trauma Previous intraocular surgery (such as cataract extraction)
Symptoms	Photopsias (flashes of light), generally unilateral New floaters
Examination	Dilated fundus exam with 360 degree scleral depression to assess for presence retinal tears or detachments.
Treatment	No treatment warranted for an isolated PVD If a retinal tear is found, laser retinopexy is often indicated If rhegmatogenous retinal detachment is present, surgery is often required
Complications	Vitreous hemorrhage Retinal tear(s) Rhegmatogenous retinal detachment
Follow up	Repeat dilated fundus examination within 4-6 weeks for an uncomplicated, non-hemorrhagic PVD, sooner as needed. Call your eye doctor earlier for repeat examination if you experience many, new, tiny floaters, new or increasing flashes, or a shade or curtain obscuring your vision.

References

1. Hayreh SS, Jonas JB. Posterior vitreous detachment: clinical correlations. *Ophthalmologica* 2004;218:333-43.
2. Hollands H, Johnson D, Brox AC et al. Acute-onset floaters and flashes: is this patient at risk for retinal detachment? *JAMA* 2009;302:2243-9.
3. Margo CE, Harman LE. Posterior vitreous detachment: How to approach sudden-onset floaters and flashing lights. *Postgrad Med* 2005;117:37-42.
4. Ryan SJ. *Ryan: Retina*, 5th ed. Saunders/Elsevier. 2012.
5. Sarrafzadeh R, Hassan TS, Ruby AJ et al. Incidence of retinal detachment and visual outcome in eyes presenting with posterior vitreous separation and dense fundus-obscuring vitreous hemorrhage. *Ophthalmology* 2001;108:2273-8.
6. Hikichi T, Yoshida A. Time course of development of posterior vitreous detachment in the fellow eye after development in the first eye. *Ophthalmology* 2004;111:1705-7.
7. Akiba J. Prevalence of posterior vitreous detachment in high myopia. *Ophthalmology* 1993;100:1384-8.

Suggested Citation Format

Gauger E, Chin EK, Sohn EH. Vitreous Syneresis: An Impending Posterior Vitreous Detachment (PVD). Oct 16, 2014; Available from: EyeRounds.org/cases/196-PVD.htm

last updated: 11/17/2014

Fungal endophthalmitis

Hematogenous seeding in an immune suppressed patient with positive fungal and bacterial blood cultures

Aaron M. Ricca MD, Elaine M. Binkley MD, H. Culver Boldt MD

posted December 15, 2017

INITIAL PRESENTATION

Chief Complaint

Floaters and blurred vision of the right eye

History of Present Illness

A 23-year-old male was referred to the University of Iowa Hospitals and Clinics Department of Ophthalmology and Visual Sciences for evaluation of possible ocular extension of T-cell lymphoma to the right eye. The patient had a history of T-cell lymphoblastic lymphoma with associated CNS disease, actively being treated with systemic chemotherapy. He reported that 3 days prior to presentation to an outside ophthalmologist he noted an acute onset of new floaters and blurred vision in the right eye. He denied photopsias but reported photophobia and eye pain. The referring ophthalmologist noted a white lesion nasal to the disc and started prednisolone drops every 1-hour to the right eye while awake due to concern for ocular extension of his lymphoma. The patient's vision continued to decline in the right eye prompting referral for further evaluation.

While on chemotherapy, the patient had a history of opportunistic infections such as *Aerococcus* and *Acinetobacter*, in addition to thrombocytopenia, which required platelet transfusions. Additionally, he had a Hickman catheter placed, which is a chronic indwelling central venous line. He denied fevers, chills, or night sweats.

Past Ocular History

- ◆ Refractive error

Past Medical History

- ◆ T-cell acute lymphoblastic lymphoma (NOTCH1-mutated; RAS/PTEN-wt)
- ◆ Atrial flutter with RVR
- ◆ Leukemic meningitis
- ◆ Recurrent pulmonary embolism, chronically anti-coagulated
- ◆ Non-ischemic cardiomyopathy
- ◆ Hypogammaglobulinemia
- ◆ Pancytopenia secondary to chemotherapy
- ◆ MRSA (Methicillin Resistant *Staph aureus*) and VRE (Vancomycin Resistant *Enterococcus*) colonization

Medications

- ◆ Chemotherapy with delayed intensification (model arm D of COG AALL0434 -Clinicaltrials.Gov Identifier: NCT00408005- see bit.ly/2talmm7) including pegaspargase, cyclophosphamide, cytarabine, nelarabine, thioguanine, intrathecal methotrexate, and dexamethasone
- ◆ Acyclovir 400mg by mouth twice daily
- ◆ Bupropion 100mg by mouth twice a day
- ◆ Dronabinol 2.5-5mg by mouth daily
- ◆ Lovenox 120mg subcutaneously daily
- ◆ Fluconazole 100mg by mouth daily
- ◆ Furosemide 40mg by mouth daily
- ◆ Gabapentin 600mg by mouth twice a day
- ◆ Hydrocortisone 10mg by mouth twice a day
- ◆ Hydromorphone 2mg by mouth as needed
- ◆ Levofloxacin 500mg by mouth daily
- ◆ Lisinopril 2.5mg by mouth daily
- ◆ Metoprolol succinate 100mg by mouth daily
- ◆ Ondansetron 4-8mg by mouth every 8 hours as needed
- ◆ Sildenafil 25mg by mouth as needed
- ◆ Thiamine 100mg by mouth daily
- ◆ Trazodone 50mg by mouth every evening as needed

Allergies

Sulfonamides

Family History

No family history of lymphoma, leukemia, heart disease, or lung disease

Social History

Rarely uses cigarettes, occasionally uses chewing tobacco, social alcohol use, and no illicit drug use

Review of Systems

Negative except for what is detailed in the history of present illness

OCULAR EXAMINATION

Visual Acuity with/without correction (Snellen)

- ◆ Right eye (OD): 20/100 -1 with eccentric fixation
- ◆ Left eye (OS): 20/20

Ocular Motility/Alignment

- ◆ OD: Full, Orthotropic
- ◆ OS: Full, Orthotropic

Intraocular Pressure (IOP) by Goldmann Applanation

- ◆ OD: 8 mmHg
- ◆ OS: 9 mmHg

Pupils

- ◆ OD: 8mm in dark, 7mm in light, minimally reactive and no relative afferent pupillary defect
- ◆ OS: 6mm in dark, 5mm in light, no relative afferent pupillary defect

Confrontation visual fields

- ◆ OD: Total superotemporal and partial inferotemporal defects
- ◆ OS: Full to count fingers

Slit lamp exam

Right eye

- ◆ Lids/lashes: Normal
- ◆ Conjunctiva/sclera: Trace injection
- ◆ Cornea: Fine white blood cell on the inferior 25% of the corneal endothelium
- ◆ Anterior chamber: 4+ white blood cells, 2+ flare
- ◆ Iris: Dilated, no lesions, no neovascularization
- ◆ Lens: Clear

Left eye

- ◆ Lids/lashes: Normal
- ◆ Conjunctiva/sclera: Clear and quiet
- ◆ Cornea: Clear
- ◆ Anterior chamber: Deep and quiet
- ◆ Iris: Dilated, normal architecture
- ◆ Lens: Clear

Dilated fundus examination (DFE)

Right eye

- ◆ Vitreous: 3+ anterior vitreous cell
- ◆ Disc: Poor view, obscured by white infiltrate and hazy vitreous
- ◆ Cup-to-disc ratio: Poor view
- ◆ Macula: Poor view
- ◆ Vessels: Poor view

- ◆ Periphery: There was a 20/100 view with vitreous opacities. White infiltrates obscured the optic nerve. The white infiltrates extended nasally into the mid-periphery. There were retinal hemorrhages superonasal to the optic nerve. There was a white, pre-retinal opacity measuring 4 x 3 x 2 mm in the inferior mid-periphery. The temporal retina appeared grossly normal.

Left eye

- ◆ Vitreous: No anterior vitreous cell
- ◆ Disc: Pink and sharp
- ◆ Cup-to-disc ratio: 0.1
- ◆ Macula: Normal, no heme, good foveal reflex
- ◆ Vessels: Normal in course and caliber
- ◆ Periphery: Normal, no heme, no cotton wool spots

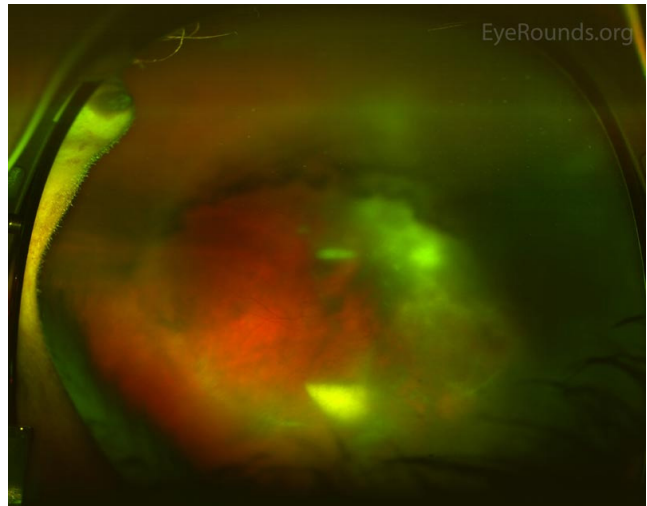


Figure 1. Optos photo of the right eye on presentation demonstrated the significant anterior vitreous cell, dense white vitreous opacities, and very poor view of most of the fundus.

Additional testing

Standardized echography (figure 2)

Differential Diagnosis

- ◆ T-cell leukemic infiltrate
- ◆ Bacterial endophthalmitis eyerounds.org/cases/45-Endophthalmitis-After-Cataract-Surgery.htm
- ◆ Fungal endophthalmitis EyeRounds.org/cases/264-fungal-endophthalmitis.htm
- ◆ Viral endophthalmitis
- ◆ Tuberculosis eyerounds.org/cases/case6.htm
- ◆ Toxoplasma Chorioretinitis eyerounds.org/cases/74-Acquired-Toxoplasmosis-Retina.htm
- ◆ Sarcoidosis eyerounds.org/cases/248-unilateral-optic-nerve-granuloma.htm
- ◆ Syphilis eyerounds.org/cases/157-Ocular-Syphilis.htm

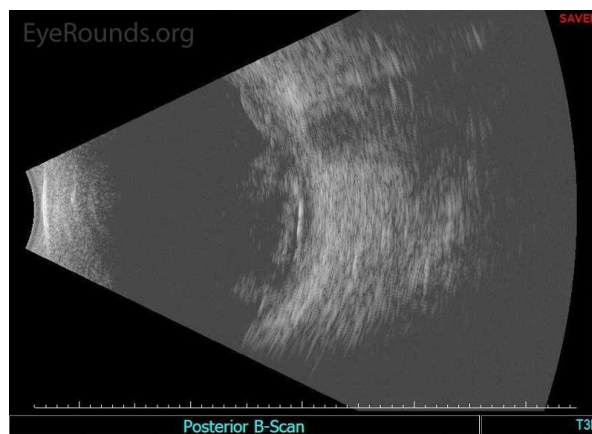
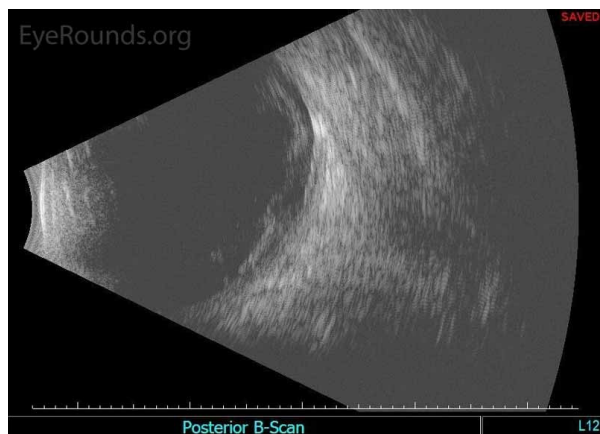


Figure 2. Echography of the right eye demonstrated dense irregular vitreous opacities that were concentrated posteriorly along the fundus and surrounding the optic disc. There was irregular retinochoroidal layer thickening. The retina was attached.

CLINICAL COURSE

(Figures 3-5)

Given the high concern for infectious endophthalmitis due to the patient's immune suppression and indwelling catheter, on the day of presentation, the patient was taken to the operating room for urgent pars plana vitrectomy with injection of intravitreal antibiotics (vancomycin and ceftazidime), antivirals (foscarnet), and antifungals (amphotericin B). A vitreous biopsy was obtained and sent for cytology, culture, and polymerase chain reaction (PCR).

The patient had daily follow up immediately post operatively. On post-operative day 2 the pathology from the vitreous biopsy returned with hyphae on the aerobic smear. Vitreous cultures were still pending and blood cultures showed no-growth. At this time, a repeat vitreous tap and inject of amphotericin B was performed. The patient was started on nightly intravenous amphotericin B managed in coordination with the hematology/oncology team. By the

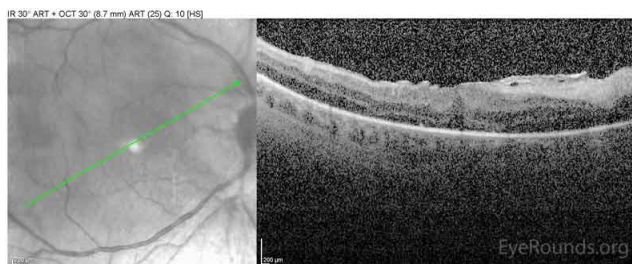


Figure 4. Spectral-domain OCT obtained the same day as the above photograph demonstrating development of an epiretinal membrane with distortion of the foveal contour.

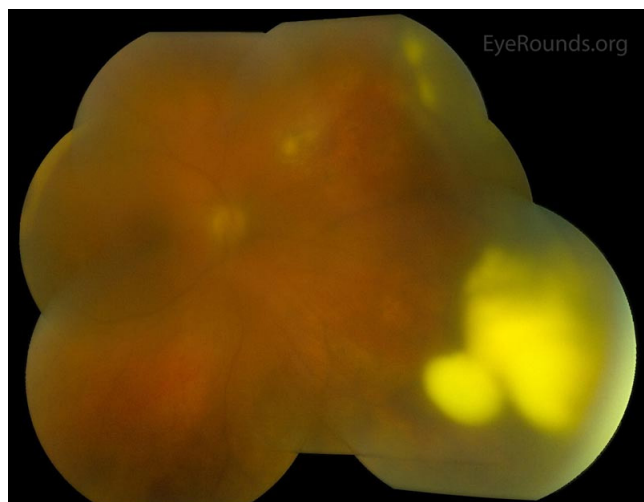


Figure 3. Color fundus photo montage demonstrating consolidation of the nasal vitreous opacities with resolution of the opacities overlying the optic disc.

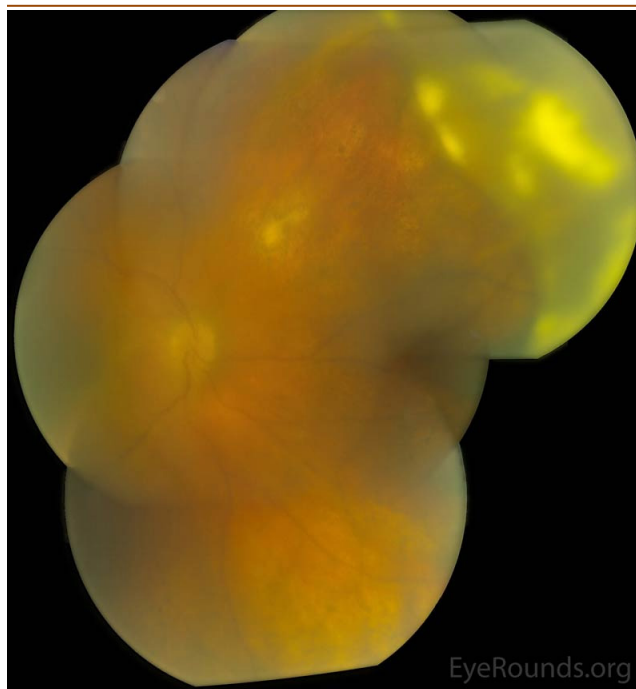


Figure 5. Color fundus photo montage part-way through the treatment course demonstrating improved media opacity and yellow-white colored pre-retinal opacities nasally and inferiorly

following day, vitreous biopsy cultures grew *Aspergillus fumigatus* and the intravenous medication was switched to voriconazole. Repeat intravitreal tap and injections of amphotericin B, then eventually voriconazole, were continued every other day for a total of 3 weeks. Throughout this time, echography was used for serial monitoring given the poor view to the posterior pole due to the vitreous debris. The Hickman catheter was presumed to be the source for the infection and was removed, as is standard of care for source control with presumed colonization of the catheter. The infection cleared and vitreous debris slowly improved. Unfortunately, the vision did not improve beyond counting fingers. After several months of follow-up the vision has remained stable and the inflammation and infection have not recurred.

DIAGNOSIS

Fungal endophthalmitis due to *Aspergillus fumigatus* in the setting of T-cell lymphoblastic lymphoma

DISCUSSION

Etiology/Epidemiology

Endophthalmitis is the disease process where the vitreous and/or the aqueous humors are infected by bacteria or fungi. Endophthalmitis can be exogenous, due to an external penetrating source via trauma or surgery, or endogenous, due to hematogenous seeding of the microbe. Fungal endophthalmitis is overall much less common than bacterial endophthalmitis, however endogenous endophthalmitis is due to a fungus over half of the time with *Candida* being the most common and *Aspergillus* the second most common causative species.[1-3] Males and females are equally effected and the disease is initially unilateral in 75% of patients, although a quarter of that population progresses to develop bilateral disease.[4] Predisposing factors include those commonly associated with the development of fungemia such as central venous catheters, history of gastrointestinal (GI) trauma or surgery, use of broad-spectrum antibiotic therapy, hyperalimentation, neutropenia, IV drug abuse, corticosteroid therapy, and diabetes mellitus.[1,5] The presence of candida endophthalmitis in patients with multiple comorbidities is thought to be an indicator of high mortality risk.[1]

Endogenous endophthalmitis due to a mold is relatively rare; the two most common causative molds are *Aspergillus* and *Fusarium*. [5] *Aspergillus* is a saprophytic mold and is present in the soil across the globe. Humans are ubiquitously exposed to conidia (spores) via inhalation. Immunocompetent individuals rarely develop infection. [6] *Aspergillus fumigatus* is the most common subspecies of *Aspergillus* responsible for causing endophthalmitis as in this case. Other species known to cause infections include *A. flavus*, *A. terreus*, *A. niger*, and *A. nidulans*. [6] One large collection of 84 patients with *Aspergillus* endophthalmitis found that over 90% of the time there was at least one un-

derlying condition leading to immunodeficiency, and often there were multiple conditions present. [4] In this same study there was no significant difference in infection rates between males and females and all ages were involved.

The most common risk factor for developing *Aspergillus* endophthalmitis is IV drug abuse; other factors strongly associated with developing this disease include recent hospitalizations, immunosuppression due to organ transplants, malignancy, and lung disease. [2,4,6] *Aspergillus* is also known cause keratitis and orbital cellulitis.

Pathophysiology

Aspergillus endophthalmitis is typically endogenous and acquired by hematogenous seeding in most cases. The most common sources of hematogenous seeding are the lungs or via IV drug abuse. [4] The conidia travel via the blood to the choroid where they seed and then migrate to infect multiple tissues in the eye.

Signs/Symptoms

The presenting symptoms of fungal endophthalmitis are often non-specific, with the most common complaint being decreased vision. [5] Other symptoms commonly reported include severe eye pain, ipsilateral headache, redness, eye swelling, photophobia, and floaters. [2,4] The presenting vision can be relatively preserved but is often decreased to counting fingers or light perception. [4,6] Anterior chamber reaction with cells in the aqueous plus/minus a hypopyon is often present. [4,6] On dilated fundus exam one sees vitritis; followed by yellowish, fluffy exudative chorioretinal infiltrates with ill-defined borders. These lesions are commonly located in the macula. The vitreous also often contains fluffy, irregular, yellowish exudative masses. [4,6,7] Intraretinal hemorrhages are frequently present, as is often the case in any form of endophthalmitis. [6] *Aspergillus* endophthalmitis is associated with infection of other organs, such as the lungs and heart. For this reason a thorough review of systems is crucial and often elicits other positive symptoms suggestive of systemic involvement. [4]

Testing/Laboratory work-up

The appropriate workup is patient dependent and based on the clinical picture at the time of presentation. Cultures of the aqueous or vitreous fluid can prove useful in confirming the diagnosis as well as establishing antimicrobial sensitivities. [4,6] Histological analysis and evaluation by polymerase chain reaction (PCR) can also be helpful in identifying the causative organism faster than routine cultures. [7] Several papers document the benefit of performing a pars plana vitrectomy for diagnostic as well as therapeutic purposes. [2,6] Should medical or surgical correction prove futile, diagnosis can be made via histological analysis of enucleated eyes with stain and culture. [4] Blood and sputum cultures can also prove useful. Most commonly, a full systemic workup is required to screen for other areas of infection or causes of immunodeficiency, to be coordinated with colleagues in internal medicine.

Imaging

B-scan echography is useful for monitoring patients, as in this case where the view to the posterior pole was limited by vitreous opacities. Color fundus photography is an additional modality that may be used to document the diagnosis and to monitor the patients' progress at subsequent visits, as was evident in this patient. Spectral-domain OCT (optical coherence tomography) imaging of fungal endophthalmitis demonstrates a diffusely thick choroid with subretinal exudation in the presence of a mostly normally organized neurosensory retina.[8] Many infectious or malignant causes of chorioretinal infiltrates with similar appearance to *Aspergillus* show disruption and loss of the normal retinal layers on OCT, further enhancing diagnostic yield.[8] It has been shown that *Aspergillus* produces a predominantly choroidal infiltrate, which is contrary to common viral or protozoal uveitides where there is widespread involvement of the neurosensory retina. [8] Wide-field angiography can assist in ruling out viral or autoimmune diseases that present with diffuse vasculitis, as the vasculitis present in *Aspergillus* infection is localized to near the chorioretinal lesions.[8]

Treatment/Management/Guidelines

Given the rarity of this disease process, there are no well-executed randomized controlled trials comparing early vitrectomy versus intravitreal injection with or without systemic therapy. As such, the management of endophthalmitis secondary to *Aspergillus* is approached in a case-by-case basis with some combination of the aforementioned interventions. In the presence of vitritis, chorioretinitis involving the macula, or endophthalmitis it is advantageous to treat with intravitreal antifungal medications with or without early vitrectomy.[9] Many providers attempt treatment with intravitreal antifungals initially. Amphotericin B has traditionally been the intravitreal antifungal of choice with an initial dose of 5-10 mcg, with some clinicians giving as much as 20 mcg, however there are risks of adverse effects at higher concentrations, such as retinal toxicity.[2,6] Intravenous and intravitreal voriconazole is well tolerated by patients with few adverse effects. The recommended dose for intravitreal voriconazole is 100 mcg and the number of injections depends on the patients response.[10] The use of topical or oral corticosteroids is controversial. Some providers feel that they are not indicated while others use them once the infection is being adequately treated. Steroids should never be used as first line therapy without adequate anti-microbial coverage as this can worsen the infection. These patients require frequent follow up as repeat injections are often warranted and performed within days to weeks, again depending on patient response.[6] One study documented the efficacy of intravitreal voriconazole in treating patients with culture

proven, fluconazole and amphotericin resistant fungal endophthalmitis with complete resolution of the disease. [11] Several recent manuscripts have documented the benefits and efficacy of treating *Aspergillus* with intravitreal voriconazole with or without early vitrectomy with good outcomes.[12,13] A recent study in a guinea pig model of *Aspergillus* endophthalmitis showed greater efficacy with intravitreal voriconazole therapy over intravitreal amphotericin B.[14] If the anterior segment is involved the patient may benefit from intracameral voriconazole and anterior segment washout.[11]

Historically, many patients were initially treated first with intravenous amphotericin B.[4] However, the significant adverse effects of systemically administered amphotericin B, such as hypertension and nephrotoxicity, limited the management potential with this drug.[9] Prior to the advent of new-generation triazoles including posaconazole, voriconazole, and ravuconazole, intravenous and intravitreal amphotericin B was the preferred therapy.[10] Currently, systemic anti-fungal therapy often involves a newer generation azole with amphotericin B being used less frequently. Voriconazole has good oral bioavailability as well as excellent ocular penetration. This, combined with the limited systemic side effect profile when compared to other antifungals, often makes it the first-line when oral therapy is pursued.[7] It has also been suggested that oral antifungal therapy with second generation azoles can be used as monotherapy in cases of limited fungal chorioretinitis not involving the macula.[10] Recommended dosing with oral voriconazole for systemic therapy is 6 mg/kg for 2 doses, then 4 mg/kg twice daily. The duration of treatment should last for approximately 4-6 weeks, or longer depending on the observed response by funduscopy exam. [10] The infectious disease service is often consulted to assist with dosing and medication administration as well as laboratory monitoring.

Careful observation of the clinical course is warranted and the importance of a multidisciplinary approach to the overall management of the patient should be emphasized.[10] Treatment plans are adjusted throughout the course of the disease and largely depend on changes in visual acuity and clinical exam findings. Fundus photography and B-scan ultrasonography can be used to track disease process and document response to therapy. Late complications, such as retinal detachment from tears at the edge of the chorioretinal scars, epiretinal membranes, and cataract have been described.[15] Despite the various effective treatment modalities for fungal endophthalmitis, infections due to *Aspergillus* are some of the most severe and have poorer visual outcomes than infections due to other fungi such as *Candida*. [3]

See Summary Table, next page

<p>EPIDEMIOLOGY</p> <ul style="list-style-type: none"> ◆ Fungal endophthalmitis is less common than bacterial, however >50% of endogenous endophthalmitis is due to a fungus[1-3] ◆ <i>Candida</i> is the most common and <i>Aspergillus</i> the second most common causative organism[1-3] ◆ The 2 most common causative molds are <i>Aspergillus</i> and <i>Fusarium</i> [5] ◆ Males and females are equally affected[4] ◆ 75% of the time patients present with unilateral disease; 25% of that population progresses to develop bilateral disease[4] 	<p>RISK FACTORS</p> <ul style="list-style-type: none"> ◆ >90% of the time there is at least one cause of immunodeficiency, and often there are multiple causes[4] ◆ Risk factors for fungemia include central venous catheters, history of GI trauma or surgery, use of broad-spectrum antibiotic therapy, hyperalimentation, neutropenia, IV drug abuse, corticosteroid therapy, and diabetes mellitus[1,5] ◆ Risk factors associated specifically with <i>Aspergillus</i> include IV drug abuse, recent hospitalizations, immunosuppression, and lung disease[2,4,6]
<p>SIGNS/SYMPTOMS</p> <ul style="list-style-type: none"> ◆ Most common presenting complaint is decreased vision[5] ◆ Other common symptoms include severe eye pain, ipsilateral headache, redness, eye swelling, photophobia, and floaters[2,4] ◆ Vision is frequently very poor at initial presentation ◆ Anterior chamber reaction plus/minus hypopyon is frequently present[4,6] ◆ Vitritis present in almost all cases[4,6,7] ◆ Yellowish, fluffy exudative chorioretinal infiltrates with ill-defined borders that are commonly located in the macula[4,6,7] ◆ Vitreous masses appear as fluffy, irregular, yellowish exudative masses[4,6,7] ◆ Intraretinal hemorrhages are frequently present[6] ◆ Review of systems is almost always positive, suggestive of comorbidities or systemic involvement 	<p>TREATMENT/MANAGEMENT</p> <ul style="list-style-type: none"> ◆ Fundus photographs and B-scan for monitoring of disease progression and efficacy of treatment ◆ Vitreous tap or diagnostic and therapeutic vitrectomy with gram stain and culture is beneficial in determining chorioretinitis vs. endophthalmitis ◆ Intravitreal injection with voriconazole (recommended dose is 100 mcg) or amphotericin B with or without early vitrectomy in cases of endophthalmitis or chorioretinitis involving the macula is warranted [10] ◆ Systemic antifungal therapy (fluconazole, amphotericin, or voriconazole) can be used as adjuvant, or sole therapy in limited chorioretinitis not involving the macula. Recommended dosing with oral voriconazole for systemic therapy is 6 mg/kg for 2 doses, then 4 mg/kg twice daily for 4-6 weeks, or longer as needed[10] ◆ AC washout and intracameral anti-fungal therapy in cases of AC involvement[11]

References

1. Khan FA, Slain D, Khakoo RA. Candida endophthalmitis: focus on current and future antifungal treatment options. *Pharmacotherapy* 2007;27(12):1711-1721. www.ncbi.nlm.nih.gov/pubmed/18041891
2. William A, Spitzer MS, Deuter C, Blumenstock G, Partsch M, Voykov B, Ziemssen F, Bartz-Schmidt KU, Doycheva D. Outcomes of Primary Transconjunctival 23-Gauge Vitrectomy in the Diagnosis and Treatment of Presumed Endogenous Fungal Endophthalmitis. *Ocul Immunol Inflamm* 2017;25(2):239-245. www.ncbi.nlm.nih.gov/pubmed/26829468
3. Essman TF, Flynn HW, Jr., Smiddy WE, Brod RD, Murray TG, Davis JL, Rubsamen PE. Treatment outcomes in a 10-year study of endogenous fungal endophthalmitis. *Ophthalmic Surg Lasers* 1997;28(3):185-194. www.ncbi.nlm.nih.gov/pubmed/9076791
4. Riddell J, McNeil SA, Johnson TM, Bradley SF, Kazanjian PH, Kauffman CA. Endogenous *Aspergillus* endophthalmitis: report of 3 cases and review of the literature. *Medicine (Baltimore)* 2002;81(4):311-320. www.ncbi.nlm.nih.gov/pubmed/12169886
5. Durand ML. Bacterial and Fungal Endophthalmitis. *Clin Microbiol Rev* 2017;30(3):597-613. www.ncbi.nlm.nih.gov/pubmed/28356323
6. Weishaar PD, Flynn HW, Jr., Murray TG, Davis JL, Barr CC, Gross JG, Mein CE, McLean WC, Jr., Killian JH. Endogenous *Aspergillus* endophthalmitis. Clinical features and treatment outcomes. *Ophthalmology* 1998;105(1):57-65. www.ncbi.nlm.nih.gov/pubmed/9442779

7. Gruener AM, Allen F, Stanford MR, Graham EM. Aspergillus fumigatus Endophthalmitis with Necrotizing Scleritis following Pars Plana Vitrectomy. *Case Rep Ophthalmol Med* 2016;2016:9289532. www.ncbi.nlm.nih.gov/pubmed/27379189
8. Adam CR, Sigler EJ. Multimodal imaging findings in endogenous Aspergillus endophthalmitis. *Retina* 2014;34(9):1914-1915. www.ncbi.nlm.nih.gov/pubmed/24695061
9. Shah CP, McKey J, Spirn MJ, Maguire J. Ocular candidiasis: a review. *Br J Ophthalmol* 2008;92(4):466-468. www.ncbi.nlm.nih.gov/pubmed/18369061
10. Riddell J, Comer GM, Kauffman CA. Treatment of endogenous fungal endophthalmitis: focus on new antifungal agents. *Clin Infect Dis* 2011;52(5):648-653. www.ncbi.nlm.nih.gov/pubmed/21239843
11. Sen P, Gopal L, Sen PR. Intravitreal voriconazole for drug-resistant fungal endophthalmitis: case series. *Retina* 2006;26(8):935-939. www.ncbi.nlm.nih.gov/pubmed/17031296
12. Kramer M, Kramer MR, Blau H, Bishara J, Axer-Siegel R, Weinberger D. Intravitreal voriconazole for the treatment of endogenous Aspergillus endophthalmitis. *Ophthalmology* 2006;113(7):1184-1186. www.ncbi.nlm.nih.gov/pubmed/16713628
13. Ferreira TB, Vaz F, Rodrigues A, Donato S. Intravitreal voriconazole as primary treatment for endogenous Aspergillus endophthalmitis. *BMJ Case Rep* 2009;2009:bcr1020081110. www.ncbi.nlm.nih.gov/pubmed/21687050
14. Zhao J, Cheng Y, Song X, Wang C, Su G, Liu Z. A Comparative Treatment Study of Intravitreal Voriconazole and Liposomal Amphotericin B in an Aspergillus fumigatus Endophthalmitis Model. *Invest Ophthalmol Vis Sci* 2015;56(12):7369-7376. www.ncbi.nlm.nih.gov/pubmed/26574795
15. Dave VP, Pathengay A, Relhan N, Sharma P, Jalali S, Pappuru RR, Tyagi M, Narayanan R, Chhablani J, Das T, Flynn HW, Jr. Endophthalmitis and Concurrent or Delayed-Onset Rhegmatogenous Retinal Detachment Managed With Pars Plana Vitrectomy, Intravitreal Antibiotics, and Silicone Oil. *Ophthalmic Surg Lasers Imaging Retina* 2017;48(7):546-551. www.ncbi.nlm.nih.gov/pubmed/28728182
16. Perlmutter Cancer Center. Clinical Trials and Research Studies. "COG-AALL0434: Intensified Methotrexate Nelarabine (Compound 506U78; IND# 52611) and Augmented BFM Therapy for Children and Young Adults with Newly Diagnosed T-cell Acute Lymphoblastic Leukemia (ALL) or T-cell Lymphoblastic." Available at clinicaltrials.med.nyu.edu/cancer/clinicaltrial/107/cog-aall0434-intensified-methotrexate/

Citing this article

Ricca AM, Binkley EM, Boldt HC. Fungal endophthalmitis: Hematogenous seeding in an immune suppressed patient with positive fungal and bacterial blood cultures. EyeRounds.org. posted December 15, 2017; Available from EyeRounds.org/cases/264-Fungal-Endophthalmitis.htm

last updated: 12/15/2017

Tutorials

Cornea and External Disease

Corneal Imaging: An Introduction

Miles F. Greenwald, BS, Brittini A. Scruggs, MD, PhD, Jesse M. Vislisel, MD, Mark A. Greiner, MD

October 19, 2016

Introduction

Imaging techniques for assessing the structure and function of the cornea and anterior segment are crucial for diagnosing and treating a wide variety of ocular diseases. There is a huge variety of diagnostic testing available to ophthalmologists, and learning how to interpret these tests can seem daunting. For those beginning training in ophthalmology, the utilization of common diagnostic tests provides quicker and more accurate diagnosis and management of corneal diseases. The goal of this tutorial is to explain the basics of the most commonly used corneal imaging techniques at the University of Iowa, including an overview of how they work and how each modality is used in clinical practice.

Corneal Topography and Tomography

Basic Principles

Corneal topography is used to characterize the shape of the cornea, similar to how one would characterize a mountain using a topographic map. Originally, corneal topography was only used to describe the anterior surface of the cornea. Devices now are able to characterize both the anterior and posterior corneal surfaces, creating a three dimensional map. Advances in digital photography and computer processing have vastly increased the utility of corneal topography (1).

The first advancement in assessing the shape of the anterior corneal surface was made in the late 1800s with the development of the Placido disc (Figure 1A) (1-2). This technique characterizes the corneal surface by assessing the reflection of a set of concentric rings off the anterior corneal surface. As the image from the Placido disc is projected on the cornea, some of the light is reflected off the tear film-air interface like a mirror. The pattern of light reflection reveals the shape of the anterior surface of the cornea (1). Similarly, hand-held keratoscopes (Figure 1B-C) are practical instruments that display concentric rings at the slit lamp for quick assessment of topographical changes (e.g., astigmatism induced by sutures). The posterior corneal surface cannot be characterized using Placido disc technology or a hand-held keratoscope. Many topography machines rings (e.g., Atlas, NIDEK OPD-Scan) still utilize Placido discs but take the technique a step further, providing a computerized quantitative assessment of the corneal surface to provide more detailed information than one can appreciate by simply looking at the reflected.




Figure 1. Qualitative corneal topography. A. Placido disc with concentric white circles. B-C. The Van Loenen cylindrical hand-held keratoscope when placed in front of a patient's eye at the slit lamp will reflect seven rings onto the corneal surface to quickly assess for qualitative topographical changes

A second technique for corneal topographic assessment is the scanning slit technique (e.g., Orbscan). This method uses rapidly scanning projected slit beams of light and a camera to capture the reflected beams to create a map of the anterior and posterior corneal surface. A third technique, known as Scheimpflug imaging, uses a rotating camera to photograph corneal cross-sections illuminated by slit beams at different angles (e.g., Pentacam). This method corrects for the non-planar shape of the cornea and, thus, allows greater accuracy and resolution in creating a 3-D map of the cornea (2-3).

Placido disc interpretation

Placido disc images can be interpreted both qualitatively and quantitatively. The projected concentric rings are referred to as "mires." The shape of the corneal surface can be inferred by inspection of these mires. Similar to a topographic map of a mountain, areas where the mires appear closer together correspond to steeper corneal curvature. Areas where the mires are more widely spaced are flatter. The mires can also give information regarding the quality of the surface. Distinct, well-formed mires are referred to as "crisp" and suggest the underlying corneal surface to be regular and smooth.

As an ideal sphere, the cornea should have mires equally spaced over its entire surface (Figure 2A). Minor, insignificant variations are present in every cornea but may not be detectable on qualitative inspection of a Placido disc image. For example, distorted or wavy mires suggest surface irregularities, such as those caused by surface dryness (Figure 2B). Regular astigmatism results in mires that appear ovoid (Figure 2C). If irregular astigmatism is present, this may be seen as an irregularly distorted reflection of the

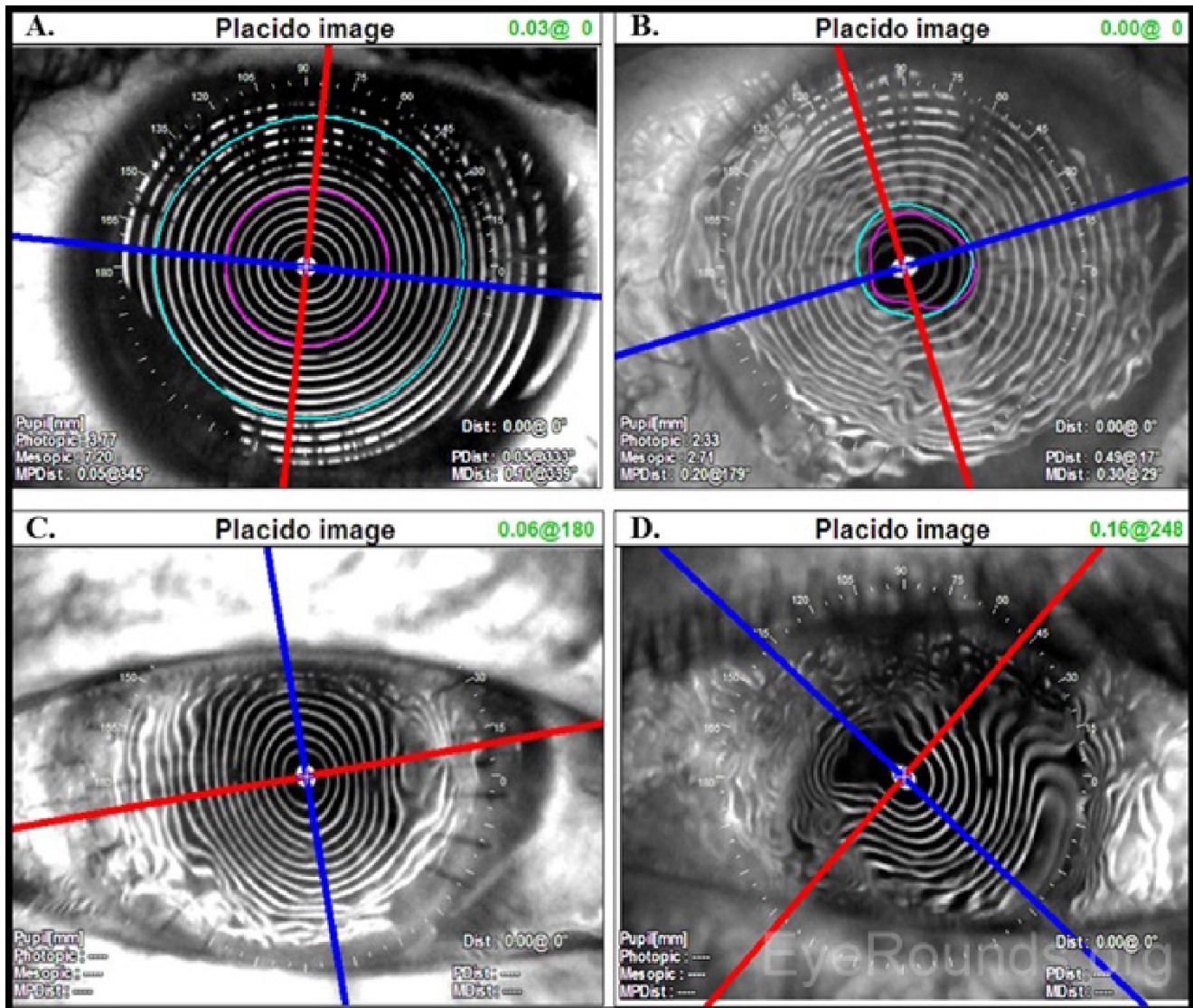


Figure 2. Projection of Placido disc mires on (A) a normal cornea with crisp mires and minimal astigmatism, (B) a cornea with surface dryness, (C) a cornea with regular against-the-rule astigmatism within a full-thickness corneal transplant, and (D) a cornea with irregular astigmatism within a full-thickness corneal transplant. Placido images can help guide selective suture removal; for example, the sutures in (C) could be removed at 3 o'clock and 9 o'clock, clinical course permitting, to reduce the post-operative astigmatism.

mires (Figure 2D). Placido disc evaluation can also be used to guide suture removal following penetrating keratoplasty. Selectively removing sutures can reduce post-operative astigmatism (Figure 2C).

Zeiss Atlas and NIDEK OPD-Scan Interpretation

The Zeiss Atlas and NIDEK OPD-Scan are Placido disc-based topographers. As shown in Figure 3, the Zeiss Atlas report includes a Placido disc image and several maps that provide information regarding tangential curvature, axial curvature, and elevation. A tangential, or instantaneous, map is very similar to an axial map. It is a slightly more accurate way of characterizing the corneal curvature but appears more "noisy" and irregular. Axial maps are less

sensitive at measuring the corneal curvature and, thus, are used mainly for screening purposes (4-5).

Similar to a Zeiss Atlas report, the NIDEK imaging report (figure 4) provides an axial curvature map and a Placido disc image. The NIDEK instrument also provides keratometry data, which are simulated measurements providing the dioptric refractive power in the two primary meridians. The patient's refractive error is approximated using both the autorefraction (REF) and wavefront (WF) measurements, and this refraction estimate is available in the auto-refraction window of the NIDEK report. Two additional maps are included from the NIDEK testing that are not available by other modalities: the Optical Path Difference (OPD) and the Internal OPD maps. The OPD specifically detects the total refractive error (in diopters) in the eye, including aberrations in the cornea, lens and other

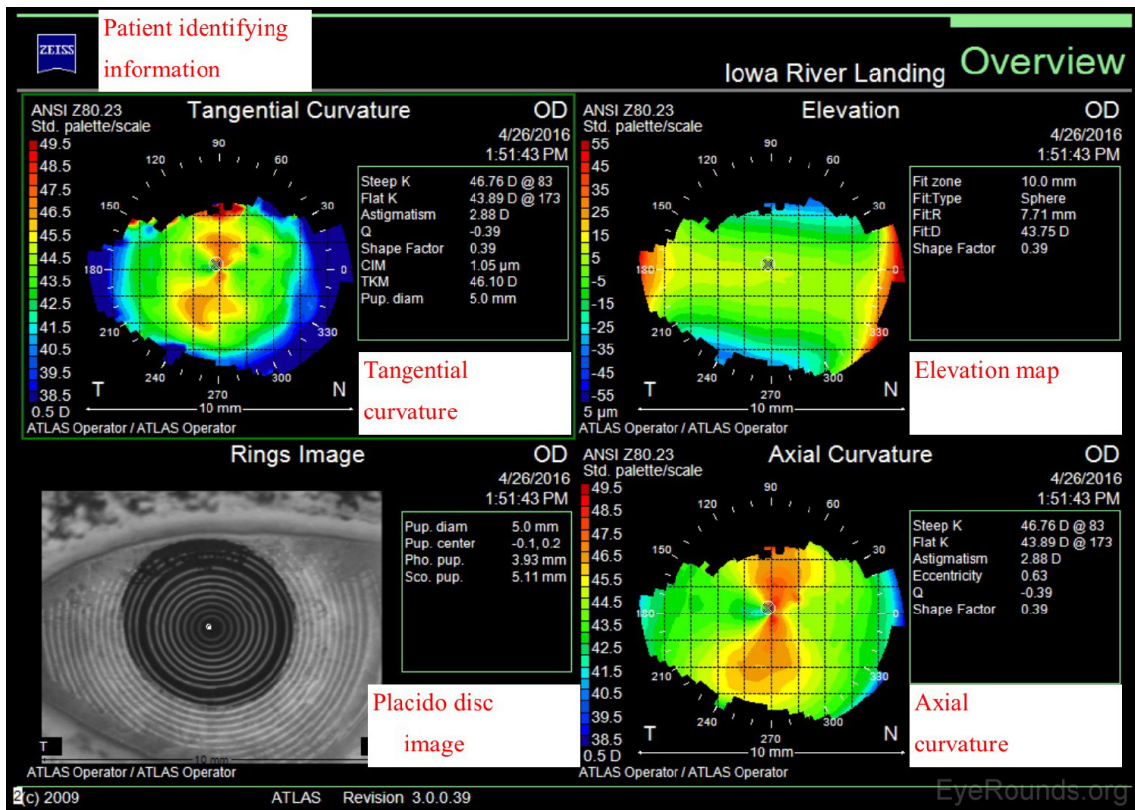


Figure 3. Zeiss Atlas Report. The tangential and axial curvature maps both show with-the-rule corneal astigmatism with more plus power in the vertical meridian. Specifically, the steepest meridian is at 083 degrees, and there are 2.88 diopters of astigmatism. The Placido disc image shows regular, concentric mires, indicating a healthy corneal surface.

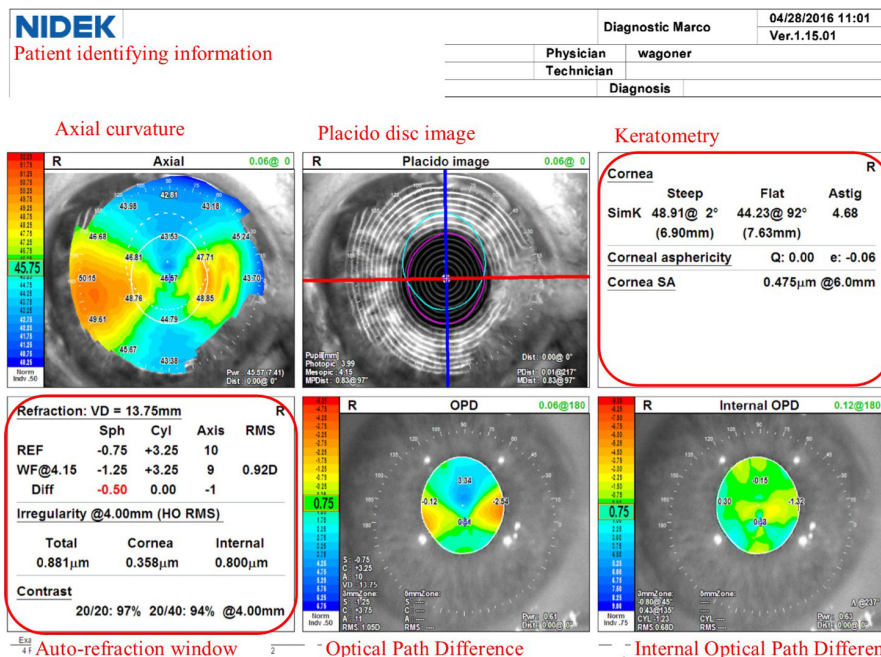


Figure 4. NIDEK Report. Upper panes: The axial curvature map shows against-the-rule corneal astigmatism with more plus power in the horizontal meridian. The Placido disc image shows concentric mires with some irregularity in the inferonasal region of the cornea. The steepest meridian is at 002 degrees, and there are 4.68 diopters of astigmatism. Lower panes: Both the autorefraction (REF) and wavefront (WF) measurements estimate the patient having mild myopia (-0.75 to -1.25) with significant astigmatism correction (+3.25) in the horizontal meridian (009 to 010 degrees). The total refractive error is estimated using the optical path difference (OPD) to be -0.75 diopters with +3.25 of astigmatism at axis 010.

structures, whereas the Internal OPD map captures the refractive error contributed by *internal* structures of the eye by subtracting the corneal refractive power from the total OPD. Also measured in diopters, this measurement helps differentiate the effects of corneal and surface refractive error from internal aberrations (e.g., lenticular anomalies).

Pentacam Interpretation

The Oculus Pentacam utilizes Scheimpflug technology to create topographic reports. The reports contain a great deal of information, and samples of the overview report and the 4 maps report are provided below (Figure 5A-B). Specifically, the overview report provides the Scheimpflug image, which is a cross-sectional image showing the cornea, anterior chamber, iris, and lens. A 3-D representation of the patient's corneal shape is also provided. The density of the cornea is evaluated using densitometry, which is an objective measurement of light scatter in the cornea. Any densitometry value less than ~30 is considered normal; thus, a condition resulting in decreased corneal clarity (e.g., corneal edema) will increase the densitometry value. There is also a convenient summary of the keratometry, pachymetry, and other numeric measurements in this report. A pachymetry color map indicates corneal thickness.

The Pentacam 4 maps report also provides a summary of keratometry, pachymetry with map, and other numeric measurements. Similar to the NIDEK report, the Pentacam report includes an axial map that depicts the curvature of the anterior corneal surface in dioptic values for each point.

Anterior float and posterior float images, which are elevation maps, are generated on the Pentacam report. Instead of displaying the refractive power of the cornea, elevation maps display the shape of the cornea by comparing it to a computer-generated best-fit sphere (*i.e.*, a perfect sphere that best approximates the corneal shape on average). Posterior float, similar to the anterior float, shows the shape of the posterior cornea compared to a best-fit sphere.

Clinical Uses of Corneal Topography

Screening for corneal ectasia

Keratoconus [EyeRounds.org/atlas/pages/keratoconus/index.htm](https://www.eyeforall.org/atlas/pages/keratoconus/index.htm), the most common corneal ectasia, is a progressive corneal condition characterized by central thinning and steepening of the cornea. Early keratoconus often looks normal on slit lamp examination, and manual keratometry, which assesses the central 3 mm, may give an insufficient assessment. Because of this, topography has become the gold standard for screening patients for keratoconus and other corneal ectasias (Figures 6-8).

Corneal ectasia monitoring and treatment

Once an ectasia (e.g., keratoconus, Pellucid marginal corneal degeneration [EyeRounds.org/atlas/pages/Pellucid-marginal-degeneration/](https://www.eyeforall.org/atlas/pages/Pellucid-marginal-degeneration/)) is diagnosed, topography may be

useful for monitoring disease progression. With regular surveillance topography, it can be determined when patients are at risk for progression and complications, and this precise monitoring allows early intervention with treatments such as collagen cross-linking or keratoplasty. Topographic warning signs include high central corneal power, a large difference between the two corneas of a patient, and a large disparity between the refractive power at the apex and the periphery (Figures 6-8) (5).

Refractive surgery screening and monitoring

Laser refractive surgeries such as photorefractive keratectomy (PRK) [EyeRounds.org/video/Cornea/PRK.htm](https://www.eyeforall.org/video/Cornea/PRK.htm) and laser assisted in situ keratomileusis (LASIK) [EyeRounds.org/video/Cornea/LASIK.htm](https://www.eyeforall.org/video/Cornea/LASIK.htm) use excimer laser to ablate tissue and reshape the cornea to correct an individual's refractive error. Not every patient, however, can safely undergo these procedures. Screening must be performed to determine corneal shape and patterns of astigmatism on topography before refractive surgery can safely be performed. Topography can also be used post-operatively to evaluate etiology for unsatisfactory visual outcome such as decentered or incomplete ablations.

Pre-operative intraocular lens selection

During cataract surgery, an intraocular lens is placed in the eye to achieve the desired refractive outcome. Standard intraocular lenses only contain spherical correction. If a patient has regular corneal astigmatism, however, an astigmatism-correcting toric lens may be used. Corneal topography is a useful pre-operative test to assess the magnitude and regularity of corneal cylinder when selecting an intraocular lens implant prior to cataract surgery.

Post-keratoplasty astigmatism evaluation and management

After keratoplasty, corneal astigmatism can be evaluated with topography. This technology guides selective suture removal and other interventions to reduce levels of astigmatism.

Ocular surface disorder evaluation

Ocular surface disorders, such as pterygia [EyeRounds.org/atlas/pages/Pterygium.html](https://www.eyeforall.org/atlas/pages/Pterygium.html) corneal scars, and Salzmann nodules [EyeRounds.org/cases/180-Salzmann-Nodular-Corneal-Degeneration.htm](https://www.eyeforall.org/cases/180-Salzmann-Nodular-Corneal-Degeneration.htm), can induce irregular corneal astigmatism. Corneal topography can be used to evaluate the refractive effects of these problems and to aid in disease monitoring and surgical planning.



OCULUS - PENTACAM Overview

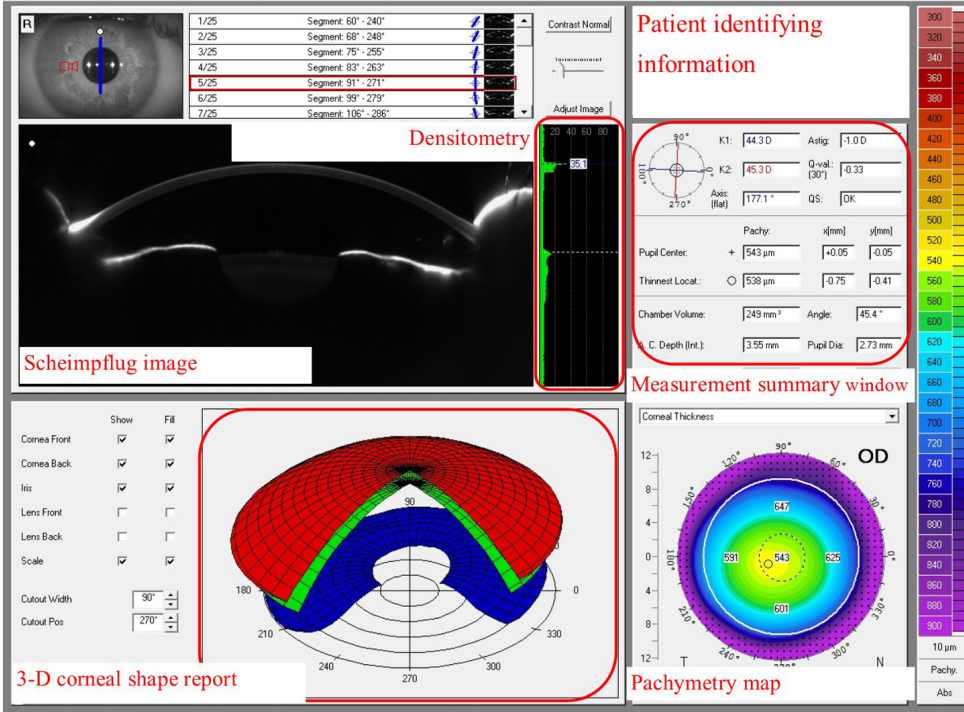


Figure 5A. Pentacam Overview Report. Upper panes: the Scheimpflug image is a cross-sectional image showing the cornea, anterior chamber, iris, and lens. Densitometry measurement estimates corneal clarity; any value greater than 30 may indicate decreased corneal clarity. Lower panes: A 3-D representation of the patient's corneal shape is provided; the anterior corneal surface is shown in red, posterior corneal surface in green, and iris in blue. A pachymetry map is a color map that indicates corneal thickness; cooler colors are thicker and warmer colors are thinner (numeric scale on right).



OCULUS - PENTACAM 4 Maps Refractive

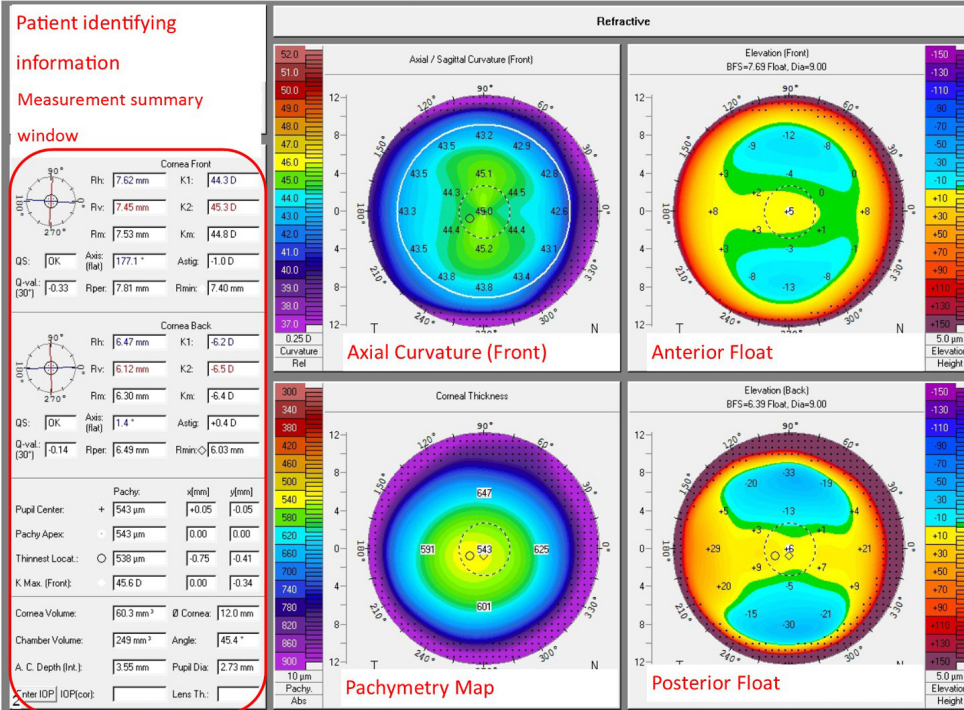


Figure 5B. Pentacam 4 Map Report. The axial curvature map, also known as a sagittal map, depicts the curvature of the anterior corneal surface in dioptric values for each point. The color scale represents the power in diopters at each particular point. Warmer colors represent steeper corneal curvature while cooler colors represent flatter areas. For the elevation maps (anterior and posterior float), warmer colors denote where the cornea is elevated above the best fit sphere and cooler colors denote where the cornea is depressed below the best fit sphere. A pachymetry map is a color map that indicates corneal thickness; cooler colors are thicker and warmer colors are thinner.

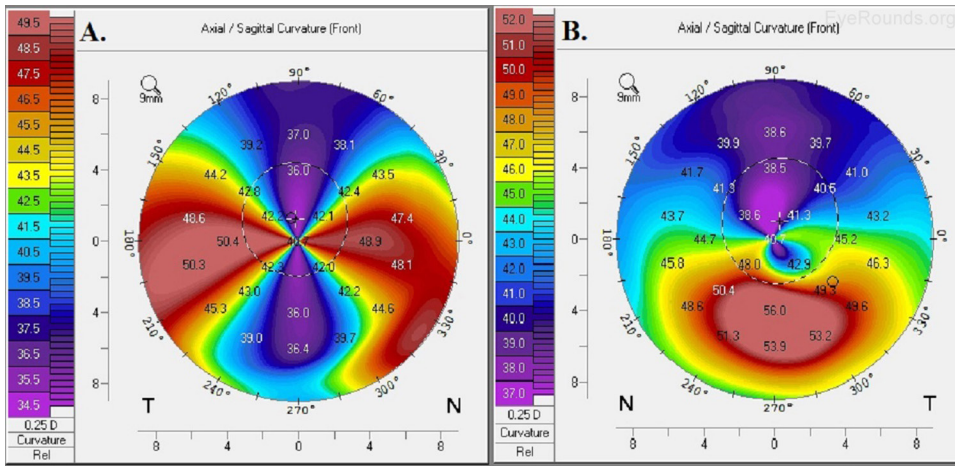


Figure 6. Pellucid marginal corneal degeneration (A) and keratoconus (B). Anterior axial maps generated with Oculus Pentacam technology shows the high against the rule astigmatism in a “crab claw” pattern of pellucid marginal corneal degeneration and the inferior steepening pattern of keratoconus.

Figure 7. Progression of keratoconus. Frequently the topography will show progression of keratoconus from symmetric astigmatism to asymmetric astigmatism, followed by asymmetric astigmatism pattern with a skewed radial axis. With progressive keratoconus, inferior steepening can ultimately develop.

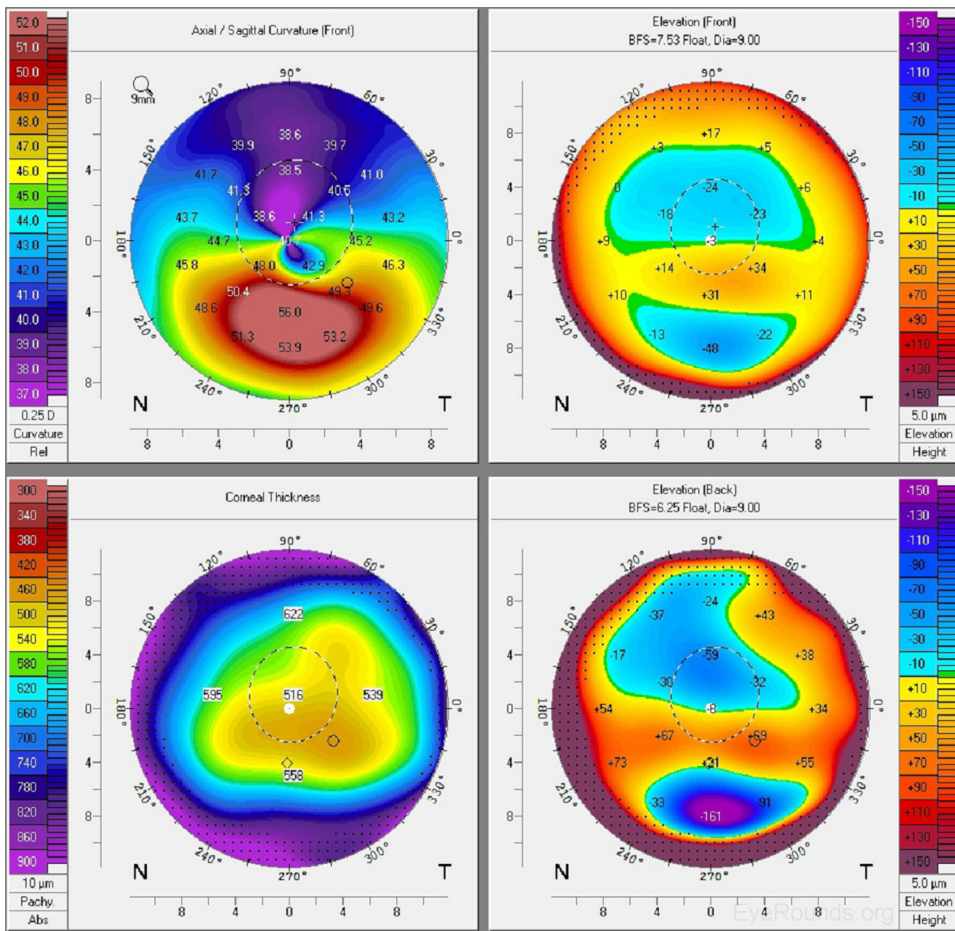
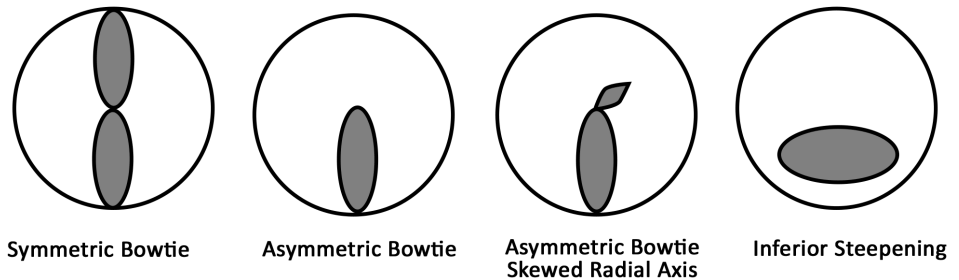


Figure 8. Keratoconus on Pentacam. The anterior axial map shows significant inferior paracentral steepening, while the pachymetry map shows thinning in the area of steepening. The anterior and posterior floats reveal a paracentral bulge, which suggests focal elevation compared to an ideal, spherical surface.

Anterior Segment Optical Coherence Tomography (AS-OCT)

Basic Principles

Anterior segment optical coherence tomography (AS-OCT) produces high-resolution imaging of the cornea, iris, and anterior chamber (e.g., Visante). It is analogous to ultrasound, but it utilizes light waves instead of sound to pro-

duce extremely high-resolution images of very small ocular structures (Figures 9 and 10). AS-OCT uses two scanning beams of light that are reflected off an ocular structure and then detected and compared to a reference beam to create a cross-sectional image (6).

Interpretation Guide

See figures 9 and 10.

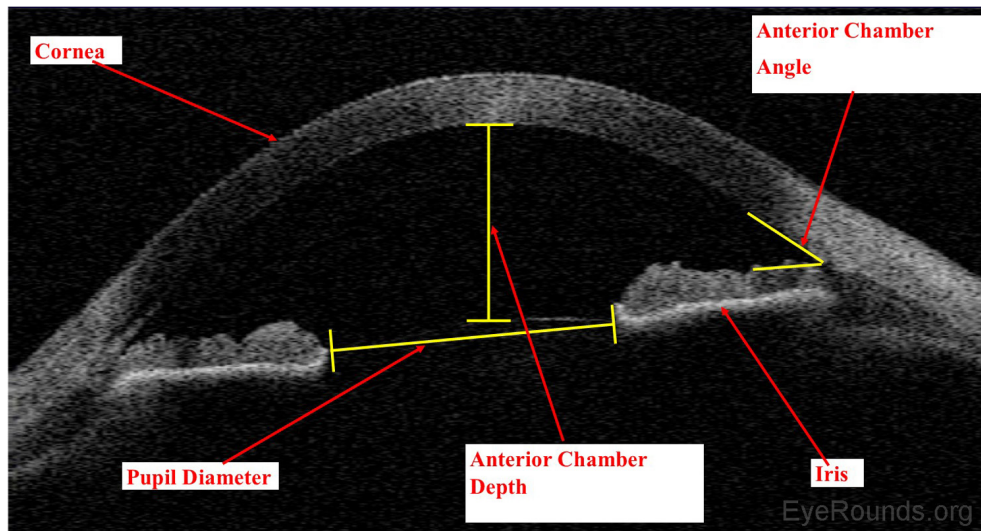


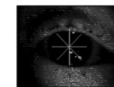
Figure 9. Visante AS-OCT showing normal anterior chamber anatomy, including the cornea, iris, iridocorneal angle, anterior chamber depth and pupil diameter.

Figure 10. Visante report showing a poorly-adherent Descemet's Membrane Endothelial Keratoplasty (DMEK) graft. The graft successfully adhered after another air bubble was placed within the anterior chamber. Each OCT image is a two-dimensional slice through the anterior chamber. The four orientation arrows, which are located above every OCT image, indicate the left side (arrow tail) and the right side (arrowhead) of the image. The angle of orientation is also displayed.

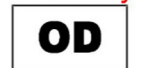Image Analysis Report



Patient identifying information

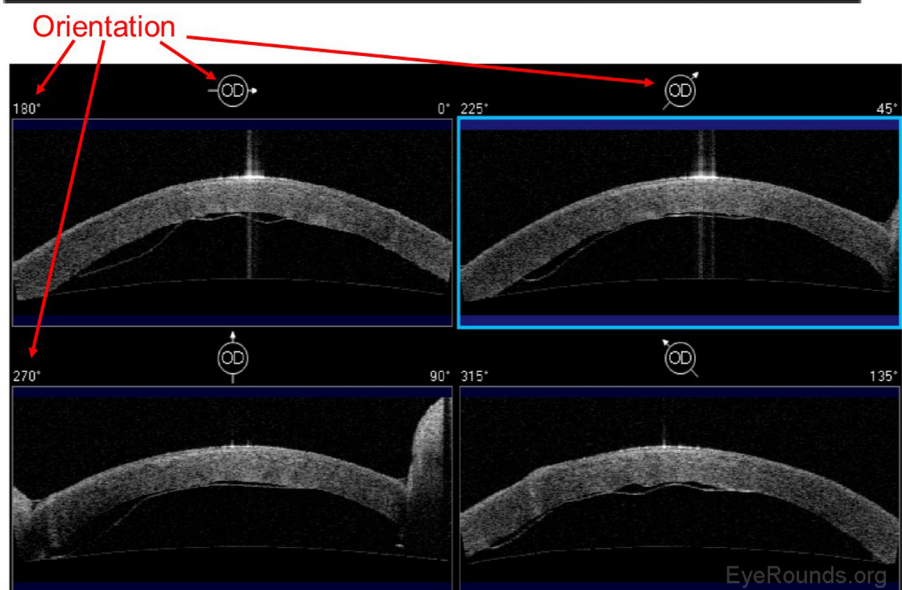


Laterality



Visante™ OCT
ANTERIOR SEGMENT IMAGING

Protocol: All Scans
Scan: High Res. Corneal Quad



Clinical Uses

Anterior chamber angle assessment

AS-OCT allows both qualitative and quantitative assessment of the iridocorneal angle. It can be used as an adjunct to gonioscopy for glaucoma diagnosis and management.

Surgical planning for LASIK enhancements

AS-OCT can be used to measure the residual stromal bed beneath a LASIK flap when determining whether or not there is sufficient stroma remaining to perform a flap lift and enhancement (Figure 11).

Surgical planning for phakic IOL implants

Phakic intraocular lens (IOL) implants EyeRounds.org/video/Cornea/verisyse.htm (e.g., Verisyse™) can be placed in

series with the natural crystalline lens for correction of high myopia. The AS-OCT allows detailed measurements of the anterior chamber dimensions to assess whether or not sufficient anterior chamber space is available for one of these lens implants (Figure 12) (7).

Assessment of graft position after keratoplasty

AS-OCT is a useful adjunct to slit lamp examination for the assessment of endothelial graft adherence during the immediate postoperative period.

Keratoprosthesis post-surgical management

AS-OCT can provide additional information regarding structural integrity of prosthetic corneas, such as the Type I Boston keratoprosthesis EyeRounds.org/tutorials/Cornea-Transplant-Intro/6-kprosth.htm (Figure 13).

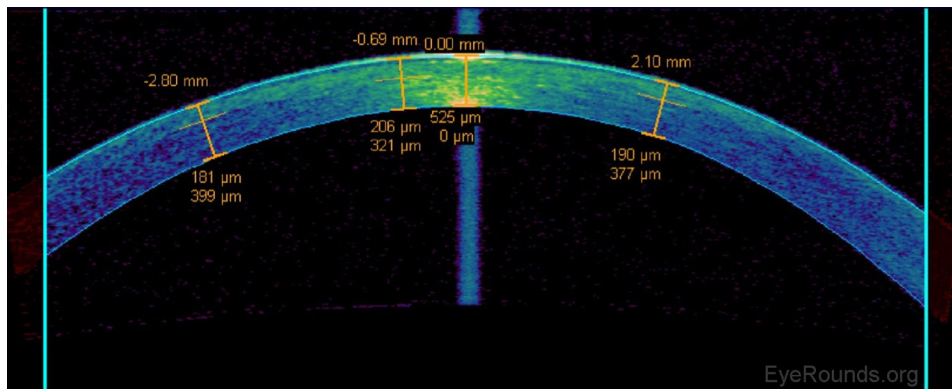


Figure 11. Measurement of the residual stromal bed beneath a LASIK flap on AS-OCT. The central corneal thickness is estimated to be 525μm, and the residual stromal bed is measured to be 321μm centrally and 377-399μm toward the peripheral cornea. At the University of Iowa, a patient is deemed not a candidate for LASIK or enhancement if the final calculated residual stromal bed is less than 300μm.

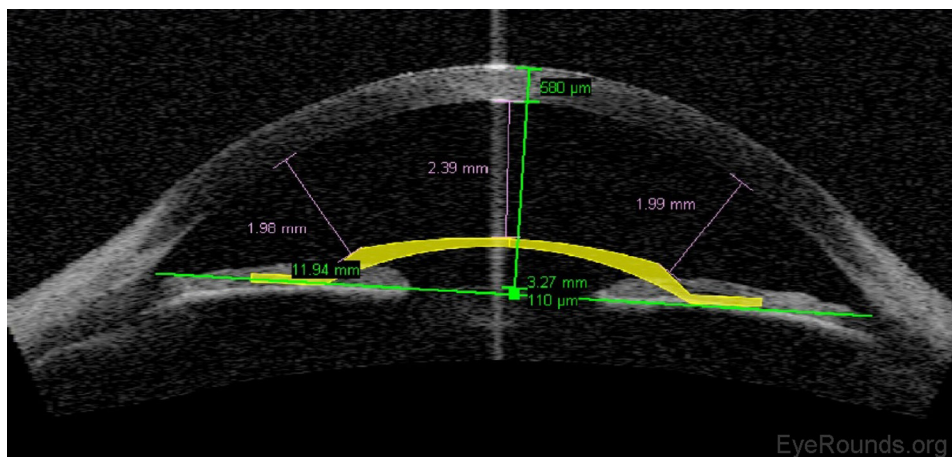


Figure 12. Phakic intraocular lens (IOL) surgical planning on AS-OCT. The Visante device is able to superimpose a digital phakic IOL into the anterior chamber to ensure there is adequate space for safe implantation of the device.

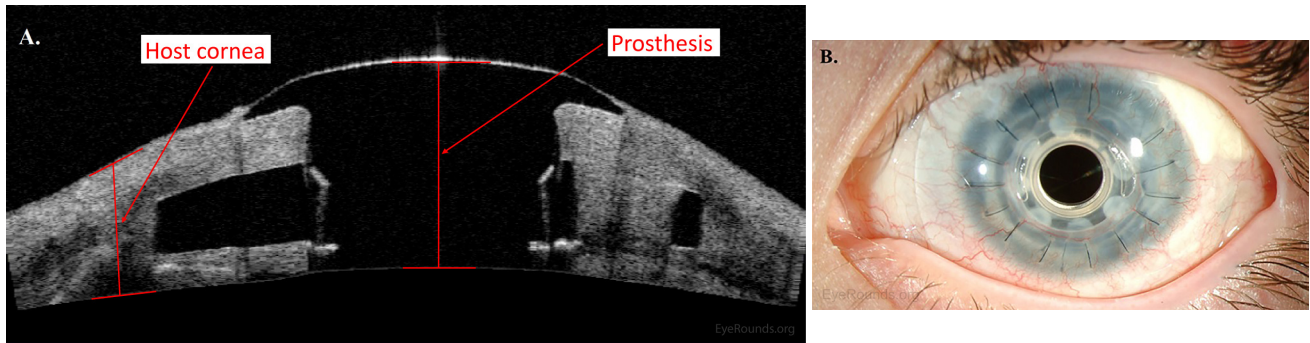


Figure 13. Type I Boston keratoprosthesis device as examined using (A) AS-OCT and (B) a slit lamp (8).

Confocal Microscopy

Basic principles

Confocal microscopy is an imaging technique that allows *in vivo* examination of corneal structures at high magnification and resolution. Building off of imaging principles developed for neuronal imaging, confocal microscopy was first used to study the cornea in the 1990s (9-10). The device (e.g., NIDEK Confoscan, Heidelberg HRTII) allows characterization of each of the five corneal layers

by simultaneously illuminating and imaging a single point of tissue (Figure 14) (11). The point light source and the camera are in the same plane, hence the name "confocal." Modern confocal microscopes scan small regions of tissue, illuminating and imaging thousands of points of tissue to create the final confocal image (10). By scanning different thickness levels of certain tissues in the anterior segment, significant information about structure and function at the cellular level can be gained.

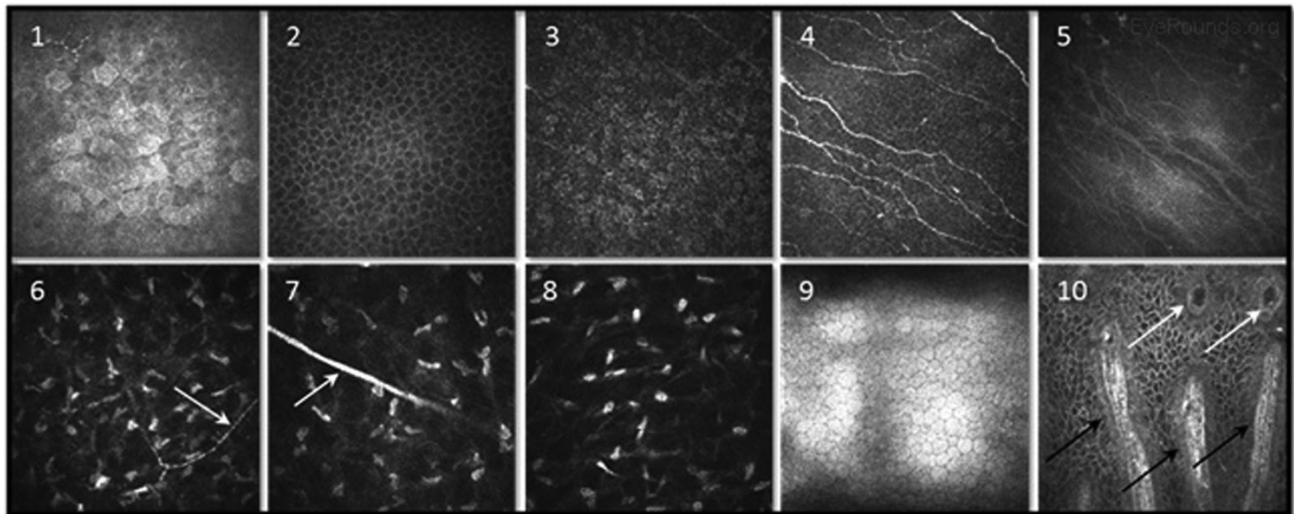


Figure 14. Confocal microscopy imaging of the various corneal layers using laser-scanning *in vivo* confocal technology. 1-3. Superficial epithelium, epithelial wing cell layer, and basal epithelium; 4. Subbasal nerve plexus; 5. Bowman's layer; 6-8. anterior stroma with nerve (arrow), mid stroma with nerve trunk (arrow), and posterior stroma; 9. Endothelium; and 10. Inferior limbal palisade ridges (black arrows) with focal stromal projections (white arrows). Image courtesy of Dr. Neil Lagali (Linköping University, Linköping, Sweden) (11).

Interpretation Guide

When used to assess endothelial cell health, both qualitative inspection of the endothelium and quantitative assessment of the endothelial cell density must be performed. Normal endothelial cells should appear small, hexagonal, and uniform. Pleomorphism is the presence of high varia-

tion in cell shape, while polymegathism is variation in cell size. Endothelial cell density can be obtained automatically or by manual counting and is expressed as cells/mm² (Figure 15).




Figure 15. Confocal microscopy showing normal corneal endothelium. Note the small, hexagonal cells with minimal variation in cell size or shape.

Clinical Uses

Corneal endothelial assessment

Examination of the corneal endothelium at a cellular level allows qualitative and quantitative evaluation of the cells. Endothelial cell size, shape, and density can all be characterized, which provides important information for diagnosing and managing posterior corneal

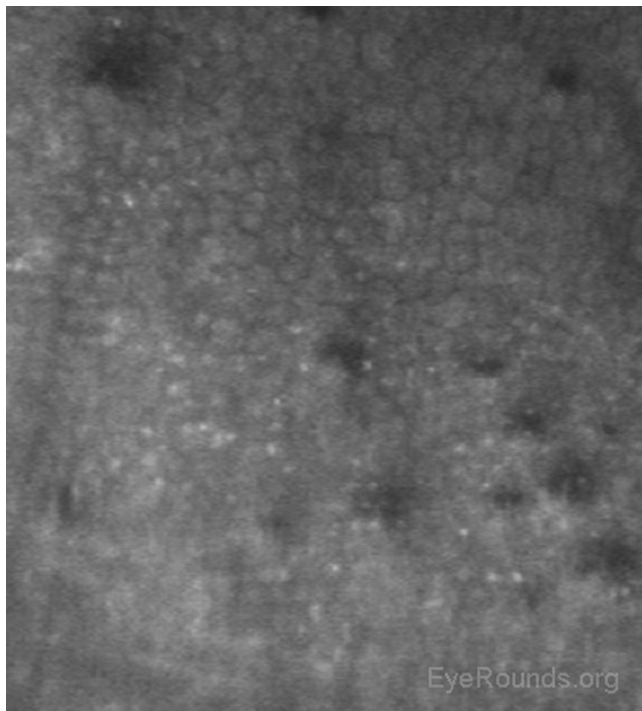


Figure 16. Fuchs endothelial dystrophy showing characteristic guttae (dark areas) and reduced endothelial cell density on confocal microscopy.

dystrophies, such as Fuchs dystrophy EyeRounds.org/cases/case5.htm (Figure 16), iridocorneal endothelial (ICE) syndrome EyeRounds.org/cases/case14.htm, and posterior polymorphous dystrophy EyeRounds.org/cases/208-PPMD.htm. The confocal microscope can help with diagnostic decisions, such as whether post-keratoplasty edema is due to corneal graft rejection (evidenced by inflammatory cells visualized) or endothelial decompensation (evidenced by low endothelial cell density) (Figure 17) (7, 10).

Identification of infectious keratitis

Infectious keratitis is a vision-threatening condition in which prompt diagnosis is imperative to preserve vision and the eye. Confocal microscopy is a useful adjunct to help rapidly identify the causative agent *in vivo*, such as fungi or *Acanthamoeba*, so appropriate treatment can be initiated. *Acanthamoeba* appear in their cystic form as highly-reflective ovoid structures (Figures 18 and 19). Fungi may appear as brightly reflective filaments and may have evidence of septations (Figure 20) (9).

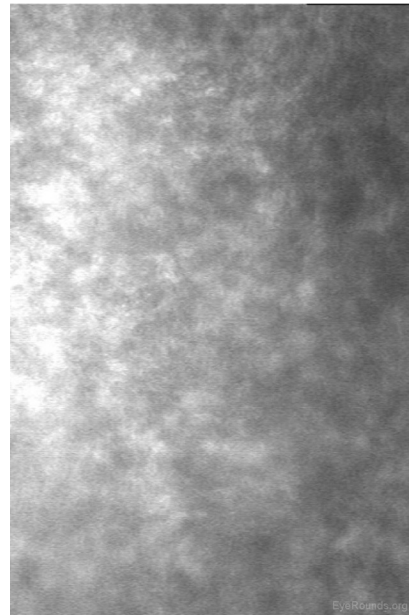


Figure 17. Endothelial decompensation within a penetrating keratoplasty graft. There are no identifiable endothelial cells on confocal microscopy.




Figure 18. Acanthamoeba keratitis as seen on confocal microscopy. The cysts appear as high-contrast round objects while the trophozoites appear as irregular forms.

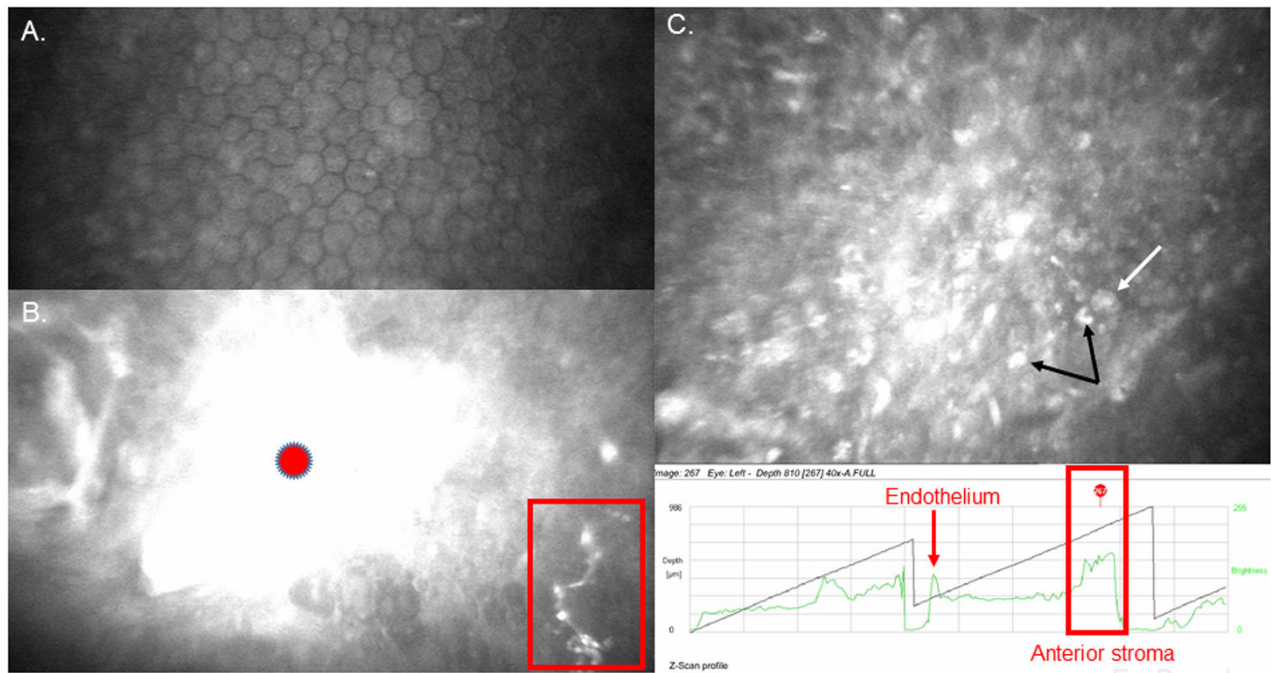


Figure 19. Confocal microscopy detection of Acanthamoeba and fungal keratitis in a contact lens user. A. Endothelial polymegathism, which is a sign of corneal stress, is likely a result of the patient’s long-term contact lens use. No cysts or trophozoites are present in the endothelial layer. B. White blood cell recruitment (red circle) is evident in the anterior stroma directly adjacent to both Acanthamoeba cysts (white arrow) and fungal elements (red box). The Acanthamoeba trophozoites feed on hyphae if both infections are not promptly treated. C. Acanthamoeba double-walled cysts (white arrow) and trophozoites (black arrows) are present throughout the anterior stroma. The Z-scan profile depicts the backscatter (i.e., brightness of the individual confocal scans), which allows quick assessment of corneal location (red box) and cell density in the specific region.

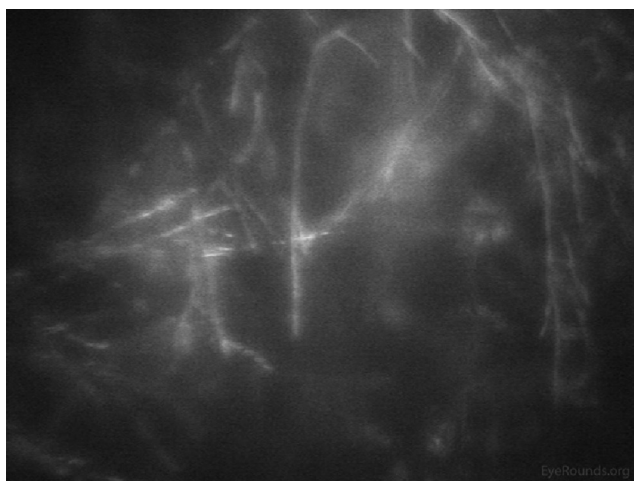


Figure 20. Fungal keratitis seen on confocal microscopy. Branching hyphae help confirm the diagnosis of Fusarium keratitis.

Corneal nerve morphology evaluation

Confocal microscopy can help quantify pathology of the subbasal nerve plexus in patients with neurotrophic keratopathy and diabetic neuropathy involving the cornea.

Corneal depth measurement

Similar to OCT, confocal microscopy can measure the depth of structures, such as deposits, scars, or LASIK flaps within the cornea to aid with surgical planning.

Summary

Ophthalmology is a rapidly advancing field with new technology for diagnosis and treatment being developed and implemented each year. As more advanced techniques (e.g., LASIK, endothelial keratoplasty) develop, the utility of advanced corneal imaging technique continues to grow. This tutorial has aimed to provide an overview of corneal imaging topics and to give trainees a foundation to build upon as they master the use of these fundamental tools of modern clinical ophthalmology.

References

1. Brody J, Waller S, Wagoner M. Corneal Topography: History, Technique, and Clinical Uses. *International Ophthalmology Clinics*. 1994;34(3):197-207. [PMID: 7960515]
2. Prakash G. Corneal topography. 2015. [Cited 2016 May 27]; Available from eyewiki.org/Corneal_topography
3. Hashemi H, Mehravaran S. Day to Day Clinically Relevant Corneal Elevation, Thickness, and Curvature Parameters Using the Orbscan II Scanning Slit Topographer and the Pentacam Scheimpflug Imaging Device. *Middle East Afr J Ophthalmol*. 2010;17(1):44-55. [PMID: 20543936]
4. Friedman N. Pearls for Interpreting Corneal Topography Maps. 2013. [Cited 2016 May 27]; Available from www.ophtalmologyweb.com/Featured-Articles/142292-Pearls-for-Interpreting-Corneal-Topography-Maps/
5. Lopes, B, Ramos, I, Dawson, D, et. al. Detection of Ectatic Corneal Diseases Based on Pentacam. *Z. Med. Phys.* 2016; 26(2): 136–142. [PMID: 26777318]
6. Radhakrishnana S. Anterior Segment Optical Coherence Tomography. 2014. [Cited 2016 May 27]; Available from eyewiki.aao.org/Anterior_Segment_Optical_Coherence_Tomography
7. Kent C. Making the Most of Anterior Segment OCT. 2011. [Cited 2016 May 27]; Available from www.reviewofophthalmology.com/content/i/1471/c/27717/
8. Goetz K, Vislisel JM, Raecker ME, Goins KM. Congenital Aniridia. March 10, 2015; Available from: EyeRounds.org/cases/211-Aniridia.htm [bit.ly/2CMwTHG]
9. Tavakoli M, Hossain P, Malik RA. Clinical applications of corneal confocal microscopy. *Clin Ophthalmol*. 2008;2(2):435-45. [PMID: 19668734]
10. Erie JC, McLaren JW, Patel SV. Confocal microscopy in ophthalmology. *Am J Ophthalmol*. 2009;148(5):639-46. [PMID 19674730]
11. Lagali N, Bourghardt Peebo B, Germundsson J, et. al. (2013). Laser-Scanning *in vivo* Confocal Microscopy of the Cornea: Imaging and Analysis Methods for Preclinical and Clinical Applications, Confocal Laser Microscopy. *Principles and Applications in Medicine, Biology, and the Food Sciences*, Neil Lagali (Ed.), InTech, Available from: bit.ly/2F6ETZD or www.intechopen.com/books/confocal-laser-microscopy-principles-and-applications-in-medicine-biology-and-the-food-sciences/laser-scanning-in-vivo-confocal-microscopy-of-the-cornea-imaging-and-analysis-methods-for-preclinical

Citing this article

Greenwald MF, Scruggs BA, Vislisel JM, Greiner MA. **Corneal Imaging: An Introduction**. EyeRounds.org. Posted October 19, 2016; Available from: EyeRounds.org/tutorials/corneal-imaging/index.htm

last updated: 10/19/2016

An Introduction to Corneal Transplantation

Christina L. Donaghy, BS, Jesse M. Vislisel, MD, Mark A. Greiner, MD

May 21, 2015

While full-thickness corneal transplant techniques have not changed much over the past century, lamellar corneal transplant techniques have evolved rapidly. To novices, the numerous acronyms that accompany the various corneal transplant techniques can easily become a disorienting alphabet soup. This article aims to introduce readers to the keratoplasty techniques that are most commonly used today (Figure 1).

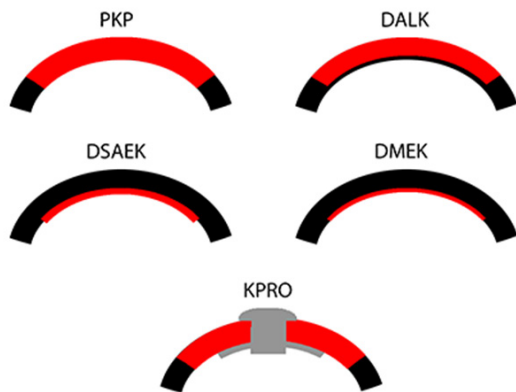


Figure 1: Schematic portraying the region of corneal tissue transplanted (red) for various modern keratoplasty techniques, including penetrating keratoplasty (PK), deep anterior lamellar keratoplasty (DALK), Descemet stripping automated endothelial keratoplasty (DSAEK), Descemet membrane endothelial keratoplasty (DMEK), and Boston Type I Keratoprosthesis (KPRO).

A Brief History of Keratoplasty

When Eduard Konrad Zirm performed the first successful full thickness penetrating keratoplasty in a human in 1905, he became the first person to perform a solid organ transplant. Ironically, he performed the surgery for one of the most challenging indications in ophthalmology – bilateral alkali burns (1-3). His donor was an 11-year-old boy whose eye was enucleated due to foreign body penetration and scleral injury. Emulating Zirm’s technique, surgeons began to perform corneal grafting over the subsequent 30 years using enucleated eyes of living donors (4). Vladimir Petrovich Filatov, a Russian ophthalmologist, became known for his work on eye banking in the early 1900s. He suggested using cadaver corneas as donor tissue and developed a method to do so (4).

Over the past century, keratoplasty techniques have evolved considerably. There were early efforts to devise selective tissue replacement techniques that might preserve healthy corneal tissue and avoid risks associated with full-thickness grafting. Anton Elschning performed the first anterior lamellar keratoplasty in 1914, for a case of interstitial keratitis. Charles Tillett performed the first successful endothelial keratoplasty (EK) case in 1956 for

corneal edema. However, the introduction of lamellar techniques actually propelled penetrating keratoplasty (PK) to the forefront of popularity after 1950 (1). Initially, anterior lamellar techniques were fraught with the problems of interface haze, scarring, and epithelial ingrowth. Tillett’s EK technique, although successful, was not repeated and no additional clinical cases were reported for decades.

It was not until the late 1990s that EK was reinvestigated, revised, and reintroduced into clinical practice, launching the modern era of lamellar keratoplasty. Gerrit Melles experimented with eye bank cadaver eyes and then with animal eyes to bring EK into the modern era. Melles described an approach called posterior lamellar keratoplasty (PLK), in which the posterior cornea was dissected out and replaced with posterior stroma and endothelium from donor corneal tissue (1, 5-7). Melles contributed the foundational concept of self-adherent graft tissue that required no sutures and could be supported initially by an air bubble. In 1999, Mark Terry introduced modifications to simplify Melles’ PLK technique, developed new instrumentation, and coined the technique deep lamellar endothelial keratoplasty (DLEK) (1, 8). However, these techniques were technically difficult to perform, required extensive manual lamellar dissection, and were not adopted widely. Patients healed rapidly compared to full-thickness transplants, but the presence of a deep stroma-to-stroma interface limited postoperative visual acuity typically to the 20/40-20/50 range.

In 2004, Melles made additional technical modifications, and introduced the idea of stripping and removing the patient’s Descemet membrane and endothelium with his Descemetorhexis technique. This new technique was renamed Descemet stripping endothelial keratoplasty (DSEK). After Mark Gorovoy introduced the microkeratome for automated preparation of donor cornea, manual lamellar dissection could be eliminated entirely, and the procedure was again renamed as Descemet stripping automated endothelial keratoplasty (DSAEK). Francis Price proposed additional technical modifications, and again, Terry introduced simplifications and new instrumentation. DSAEK allowed patients to achieve improved postoperative visual acuity results, to the 20/25-20/30 range, because its graft-host interface is more smooth (1, 9). With the advent of eye bank prepared donor tissue in 2006, financial and technical obstacles were removed, and DSAEK surgery became the most commonly performed method of endothelial keratoplasty and procedure of choice for the treatment of corneal edema.

In 2006, Melles went on to describe a technique known as Descemet membrane endothelial keratoplasty (DMEK) that allowed for transplantation of a pure Descemet membrane and endothelium graft, and exact anatomical replacement of diseased tissue in cases of endothelial dysfunction. Compared to DSAEK, DMEK allows even faster visual recovery, better postoperative visual acuity results, and greater overall patient satisfaction due to elimination of the stroma-to-stroma graft-host interface (10). However, the initial donor preparation failure rate and surgical learning curve prevented widespread application after introduction of this technique (1). Mirroring the evolution of DSAEK, as surgical techniques have become standardized and eye banks have begun to prepare DMEK graft tissue, DMEK is rapidly becoming the procedure of choice for endothelial keratoplasty for the treatment of Fuchs endothelial dystrophy and pseudophakic bullous keratopathy.

Additionally, anterior lamellar keratoplasty (ALK) techniques have been refined over the past 40 years. In the late 1970's Malbran and Gasset were performing deep anterior lamellar keratoplasty (DALK) to excise and replace the corneal tissue anterior to the deepest stromal lamellae with impressive results including 80% of keratoconus patients achieving 20/40 or better visual acuity (1, 11). However, obstacles remained that limited the popularity of this approach, including achievement of a reproducible separation plane between posterior stroma and, ideally, Descemet membrane. In 2002, Anwar and Teichmann introduced their "big bubble" pneumodissection technique in which a bubble of air is injected deep into the corneal stroma to establish separation of the posterior stroma from Descemet membrane (12). Their technique has allowed surgeons to achieve more consistent results than previous methods, but in some cases, intraoperative conversion to a full-thickness PK is still required. For patients with keratoconus or scarring that does not involve Descemet membrane or endothelium, DALK is considered by most to be the surgical treatment of choice (1), although extended operating times due to the need for careful lamellar dissection have limited its popularity.

Keratoprosthesis, the transplantation of an artificial cornea, was first performed in Italy by Benedetto Strampelli in the 1960s (1). Patients requiring repeat corneal transplantation highlighted the need for an alternative to corneal allograft treatment, as graft survival rates drop with each additional procedure. Historical options have included the osteo-odonto-keratoprosthesis (OOKP) and AlphaCor artificial cornea. These have since been largely replaced by the Boston Type I Keratoprosthesis (KPro), which became approved for use by the U.S. Food and Drug Administration in 1992 (1, 13). The device consists of a clear plastic optic and a prosthetic plate that are sandwiched around a donor allograft or the patient's own corneal tissue. The device is then sutured onto the recipient eye to replace a failed graft or the native cornea. Keratoprosthesis surgery is a procedure of last-resort, reserved for patients who are not candidates for other types of keratoplasty.

Penetrating Keratoplasty (PK)

PK is a full-thickness transplant procedure, in which a trephine of an appropriate diameter is used to make a full-thickness resection of the patient's cornea, followed by placement of a full-thickness donor corneal graft. Interrupted and/or running sutures are placed in radial fashion at equal tension to minimize post-operative astigmatism (Figure 2). Later, the sutures are removed selectively to reduce the amount of astigmatism present. A transplant can last decades with proper care (Figure 3). While once the most prominent type of corneal transplant, PK has been supplanted by partial thickness techniques for endothelial dysfunction without significant stromal scarring. PKs are performed primarily for visually significant stromal scarring, opacities with an uncertain status of the endothelium or significant posterior corneal involvement, corneal ectasia (such as keratoconus and pellucid marginal degeneration, especially if there is history of hydrops), combined stromal and epithelial disease (such as Peters anomaly), and infectious or non-infectious corneal ulcerations or perforations (1, 14). A variant of the procedure, the mini-PK, can be used to treat more focal defects in the cornea (Figure 4).

PK grants the ability to treat disease in the epithelial, stromal, and endothelial layers. A full-thickness graft also eliminates optical interface related visual problems that may exist with lamellar transplants with a stroma-stroma interface.

However, postoperative recovery time is relatively long, sometimes taking years to achieve best-corrected visual acuity. Frequently, there is substantial postoperative refractive error due to high regular or irregular astigmatism of the graft, and a higher chance of requiring rigid gas permeable contact lens wear to correct astigmatic error. There is a higher risk of allograft rejection compared with other keratoplasty types. Additionally, PKs carry a higher lifetime risk of wound dehiscence due to the compromised tectonic strength that comes from a full-thickness wound.

Video 1: SEE: vimeo.com/154371744 PK in a patient with severe corneal scarring after bacterial keratitis in the setting of HSV-related neurotrophic disease. Video contributed by Jesse Vislisel, MD

Basic procedure steps (Video 1)

1. Mark the center of the host cornea with a Sinsky hook. Use calipers to measure the corneal diameter to determine the appropriate size for donor trephine.
2. Trephinate the donor tissue, typically aiming for 0.25 or 0.5 mm larger than the planned host trephination.
3. Trephinate the host cornea to approximately 90% depth.
4. Create a paracentesis in the trephination groove or the corneal periphery, and inject Healon into the anterior chamber to preserve anterior chamber depth and stability.

5. After using a blade to enter the eye through the trephination groove, resect the host cornea tissue using curved corneal scissors.
6. Secure the donor graft to the host corneal tissue using interrupted and/or running 10-0 nylon sutures.
7. Rotate the sutures to bury the knots, assess the astigmatism using an intraoperative keratometer, and consider placing additional sutures to reduce astigmatic error.

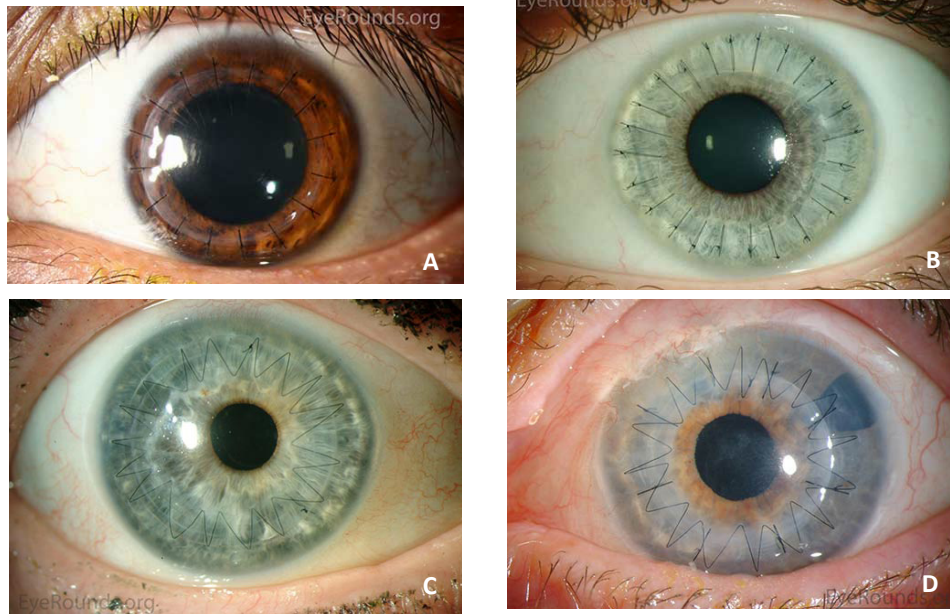

Figure 2: PK grafts with 16 (A) and 24 (B) interrupted sutures. Grafts can also be secured with a running suture (C) or a combination of running and interrupted sutures (D).

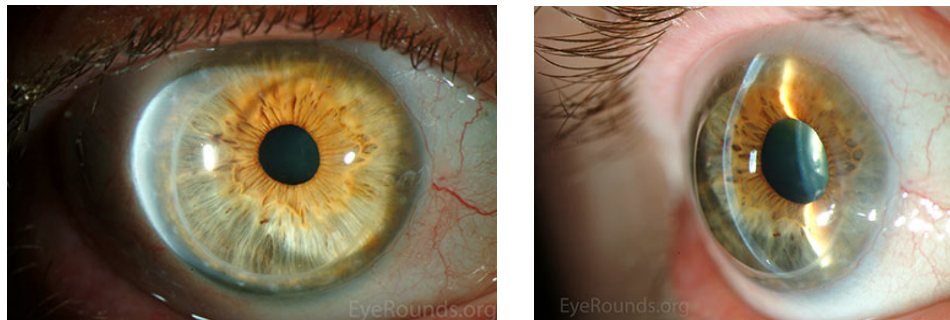


Figure 3: A PK graft, with all sutures removed, remains crystal clear 30 years after the procedure.

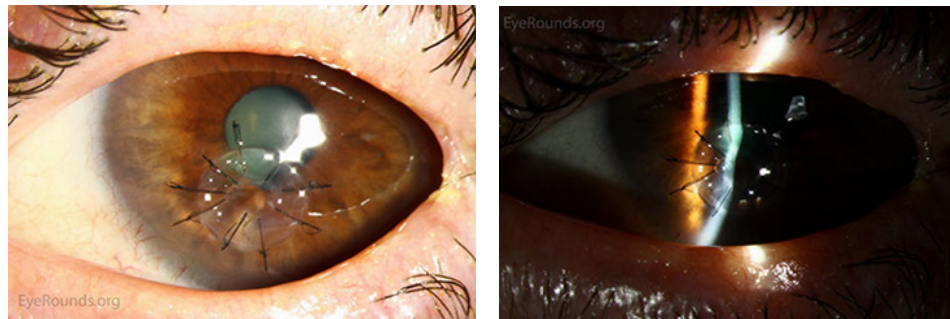


Figure 4: A mini-PK graft performed for a focal corneal perforation.

Deep Anterior Lamellar Keratoplasty (DALK)

DALK is a partial-thickness cornea transplant procedure that involves selective transplantation of the corneal stroma, leaving the native Descemet membrane and endothelium in place. A trephine of an appropriate diameter is used to make a partial-thickness incision into the patient's cornea, followed by pneumodissection or manual dissection of the anterior stroma. This is followed by placement of a graft prepared from a full-thickness punch in which the donor endothelium–Descemet membrane complex has been removed. The intention is to preserve the patient's Descemet membrane and endothelium. Similar to PK, the graft is secured with interrupted and/or running sutures (Figure 5) and these are then selectively removed post-operatively (Figure 6).

DALK is useful for processes involving the corneal stroma in the presence of healthy endothelium. Examples include corneal ectasia (such as keratoconus in the absence of hydrops), corneal scars that are not full-thickness, and corneal stromal dystrophies (1, 15, 16).

Because it is not a full-thickness procedure, the resultant wound is stronger than that of a PK. Leaving the host endothelium intact significantly decreases the risk of endothelial rejection.

The surgery is more complex and difficult to perform than PK. If the Descemet membrane is perforated intraoperatively, the surgeon must convert to a PK. The “big bubble” technique makes dissection more consistent and is the preferred technique at our institution (12).

Video 2: Big bubble DALK technique. Video contributed by Matt Ward, MD and Mark Greiner, MD
See youtu.be/Y7zqGnH6kZ4

Basic procedure steps (Video 2):

1. Mark the center of the host cornea with a Sinsky hook, and use a calipers to plan the host trephination.
2. Trephinate the host cornea to a depth of 90%.
3. Insert a 27-gauge needle, or a Fogla dissector followed by a Fogla 25-gauge cannula, into the posterior stroma.
4. Inject air to dissect Descemet membrane posteriorly with a large bubble.
5. Remove approximately 70% of the anterior stroma using a crescent blade or Devers dissector.
6. Create a paracentesis incision to release aqueous.
7. After marking the stroma and placing Healon over the mark, make an incision through the mark.
8. Inject Healon into the space between the posterior stroma and Descemet membrane. Complete the separation between these two layers using a cyclodialysis spatula.
9. Resect the remaining stroma using curved corneal scissors.
10. Remove the donor endothelium from the donor graft tissue by manually stripping Descemet membrane, then trephinate the donor tissue.
11. Secure the donor graft to the host corneal tissue using interrupted and/or running 10-0 nylon sutures.
12. Rotate the sutures to bury the knots, assess the astigmatism using an intraoperative keratometer, and consider placing additional sutures to reduce astigmatic error.

Additional Video Links

- DALK for post-LASIK Keratoconus
youtu.be/4z8P8aK1DR1

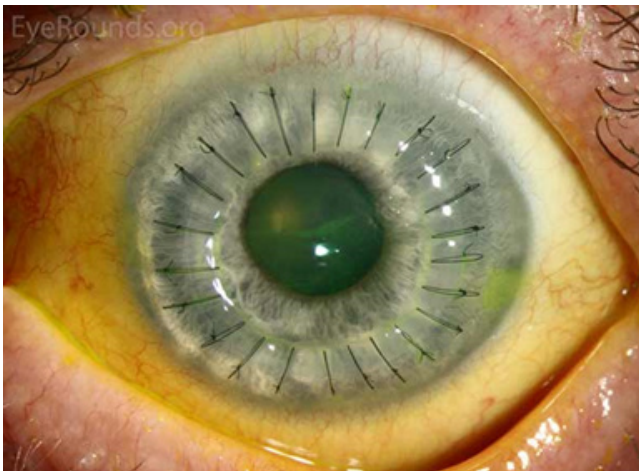


Figure 5: DALK performed for keratoconus.

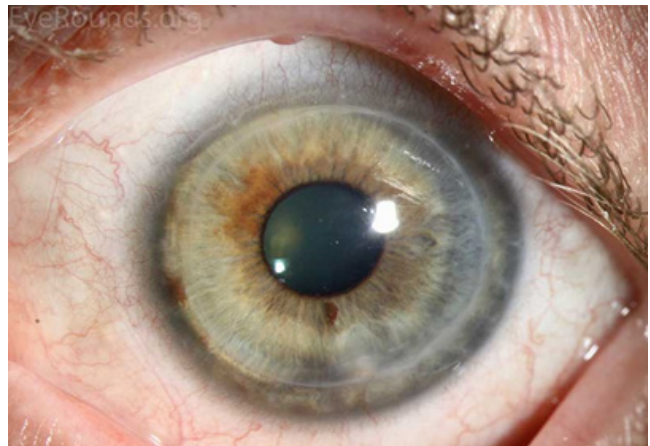


Figure 6: Clear DALK graft 3 years after transplant for keratoconus.

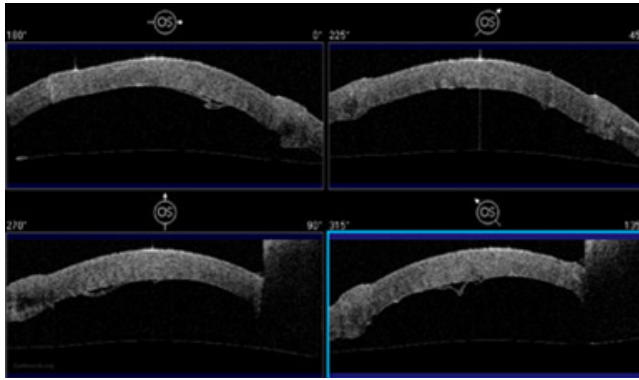


Fig 7a: Anterior segment optical coherence tomography demonstrating the redundant host Descemet membrane and endothelium in poor apposition to the graft tissue.

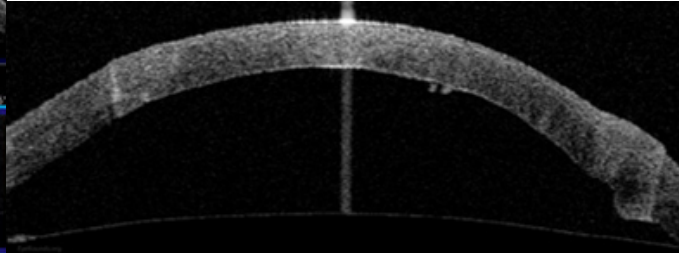


Fig 7b: Normal anatomy is restored with reattachment of Descemet membrane to the donor stroma after placement of an air bubble in the anterior chamber.

Descemet Stripping Automated Endothelial Keratoplasty (DSAEK)

DSAEK is a partial thickness cornea transplant procedure that involves selective removal of the patient's Descemet membrane and endothelium, followed by transplantation of donor corneal endothelium in addition to donor corneal stroma (Figure 8). The transplanted tissue is approximately 100-200 microns thick. If the endothelium of the graft makes contact with any surgical instruments, it will be damaged and the graft may fail; therefore, the surgical procedure is designed to avoid contacting the donor endothelium. A tunneled corneoscleral incision is created, the recipient endothelium and Descemet membrane is removed, the graft is folded and inserted with non-coapting forceps (forceps that do not meet at the tips), and an air bubble is placed in the anterior chamber to support graft adherence. The procedure is used to treat corneal edema in the setting of endothelial dystrophies (such as Fuchs corneal dystrophy and posterior polymorphous corneal dystrophy), pseudophakic bullous keratopathy, iridocorneal endothelial (ICE) syndrome, endothelial failure in the setting of prior intraocular surgery or of a previous PK graft, and other causes of corneal endothelial dysfunction (1, 17-20).

DSAEK offers the advantage of relatively rapid healing time and visual rehabilitation. Compared to PK and DALK, there is less risk of graft rejection and suture-related complications. There is minimal topographic change to the corneal curvature. A somewhat predictable hyperopic shift results (typically 0.8-1.5 D), making intraocular lens selection easier when performing staged or simultaneous cataract surgery.

Postoperative visual acuity can be very good, but there is some limitation from the effects of the stroma-to-stroma graft-host interface. There is also a risk of postoperative graft dislocation.

Video 3: vimeo.com/161469784 Descemet stripping automated endothelial keratoplasty (DSAEK) is an endothelial replacement procedure in which dysfunctional corneal endothelium is replaced with a graft consisting of donor endothelium and a thin layer of posterior stroma to facilitate handling of the tissue. This case was performed for severe corneal edema secondary to pseudophakic bullous keratopathy. Contributed by Jesse Vislisel, MD, and Mark A. Greiner, MD

Basic procedure steps (Video 3)

1. Perform temporal peritomy and achieve hemostasis.
2. Create a paracentesis and inject Healon into the anterior chamber.
3. Make a 5 mm sclerocorneal tunnel; do not enter the anterior chamber.
4. Use a bent 30-gauge needle and Sinsky hook to create an inferior peripheral iridotomy to prevent postoperative pupillary block.
5. Place a marked circular ring of the planned donor size on the surface of the cornea to mark a template for resection of the patient's corneal tissue.
6. Use a reverse Terry-Sinsky hook to score Descemet membrane just inside the ink marks previously made; strip it away from the stroma.
7. Pass a keratome through the corneoscleral tunnel and into the anterior chamber.
8. Remove the detached Descemet membrane using forceps.
9. Roughen the peripheral stromal bed, outside the visual axis, using a Terry scraper to promote graft adhesion.
10. Enlarge the wound to a full 5 mm width and then close it temporarily with a single interrupted 10-0 Vicryl suture.
11. Remove the Healon from the anterior chamber using the I/A handpiece.
12. Prepare the graft by trephinating the pre-cut donor tissue endothelial side up.
13. Fold the donor tissue into a taco shape.

14. Insert the donor tissue into the anterior chamber using non-coapting forceps.
15. Unfold and float the donor graft using balanced salt solution (BSS), followed by air.
16. Fill the anterior chamber with air to pressurize the eye.
17. Use a Cindy sweeper to perform external compression on the surface of the cornea, first to position the graft if needed, and then to remove any central interface fluid.
18. Close the temporal wound with 3 interrupted 10-0 Vicryl sutures.
19. Leave the tissue undisturbed for 10-15 minutes to allow for adherence.
20. Close the conjunctiva using cautery.
21. Perform an air-fluid exchange to remove enough air from the anterior chamber to ensure there is no air behind the iris.
22. Add air back into the anterior chamber to achieve a freely mobile bubble that covers the graft.

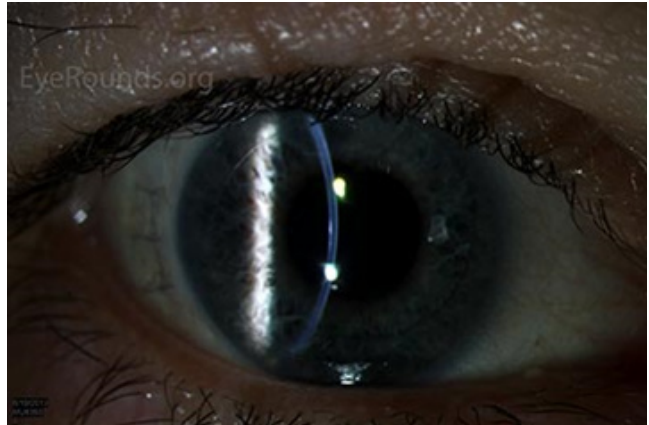
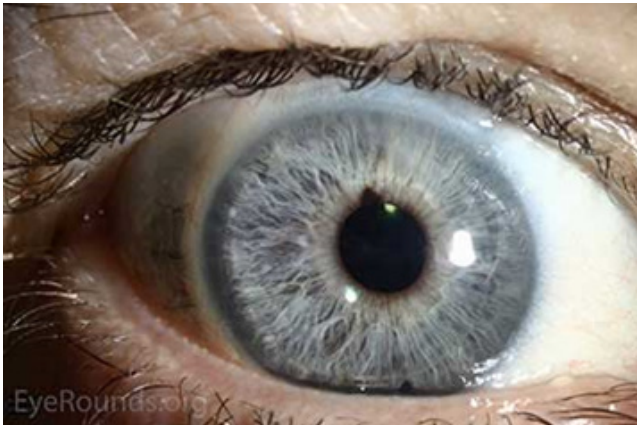
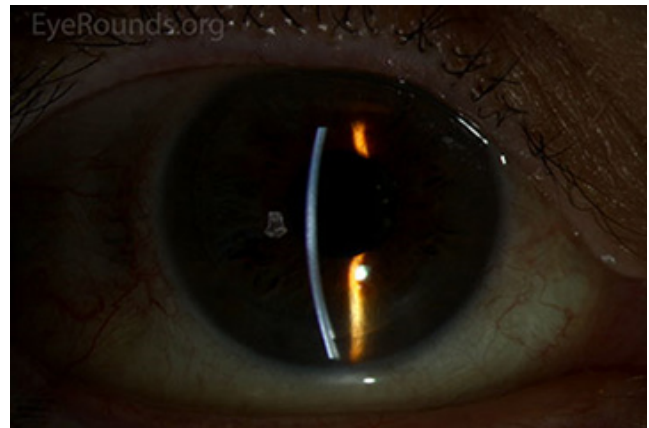
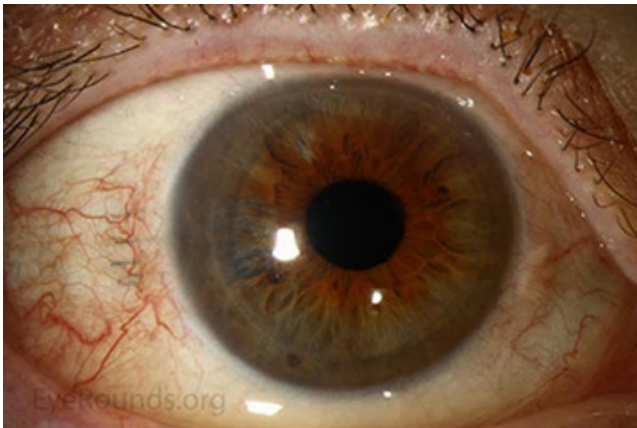


Figure 8: Post-operative appearance of two different patients after undergoing DSAEK for Fuchs endothelial corneal dystrophy.

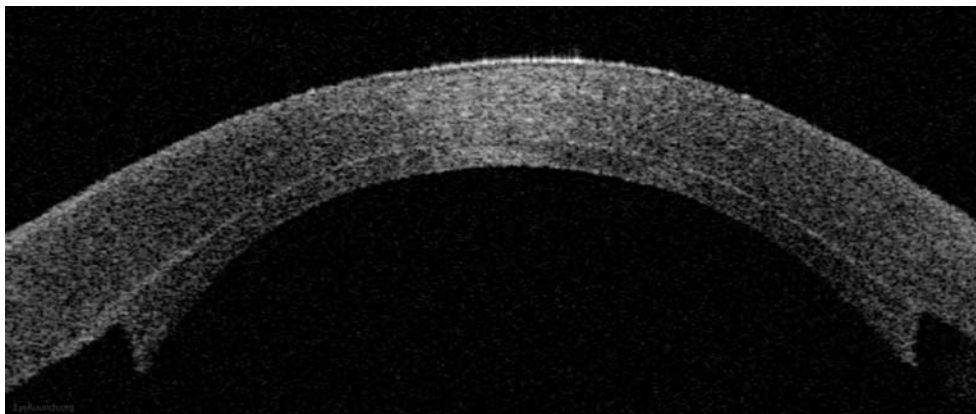


Figure 9: Anterior segment optical coherence tomography demonstrating an attached DSAEK graft one day after surgery.

Descemet Membrane Endothelial Keratoplasty (DMEK)

DMEK is a partial-thickness cornea transplant procedure that involves selective removal of the patient's Descemet membrane and endothelium, followed by transplantation of donor corneal endothelium and Descemet membrane without additional stromal tissue from the donor. The graft tissue is merely 10-15 microns thick. Similar to DSAEK, direct contact with the DMEK graft tissue should be avoided to prevent endothelial cell damage and graft failure. A clear corneal incision is created, the recipient endothelium and Descemet membrane are removed, and the graft is loaded into an inserter. After injecting the tissue into the anterior chamber, the surgeon orients and unscrolls the graft, and a bubble of 20% sulfur hexafluoride (SF6) is placed in the anterior chamber to support graft adherence

(Figure 10). A variation known as Descemet membrane automated endothelial keratoplasty (DMAEK) utilized an automated preparation of the donor tissue that left a rim of donor stroma peripherally for easier tissue handling (Figure 11), but the procedure is no longer performed due to advances in DMEK that have allowed for easier insertion and manipulation of the graft tissue.

The indications for DMEK are similar to those for DSAEK, including endothelial dystrophies (such as Fuchs corneal dystrophy and posterior polymorphous corneal dystrophy), pseudophakic bullous keratopathy, ICE syndrome, and other causes of corneal endothelial dysfunction (1, 10, 17).

DMEK offers the most rapid visual rehabilitation of any keratoplasty technique to date (Figure 12). Final visual acuity can be outstanding due to minimal optical interface effects. Because less tissue is transplanted, there is a lower

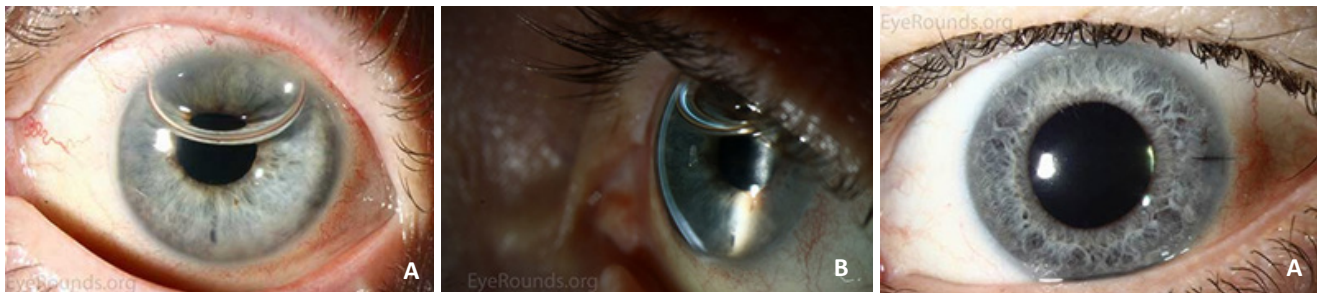

Figure 10: (A, B) Anterior chamber gas bubbles in 2 different patients each 1 week after DMEK for Fuchs dystrophy. (C) A third patient demonstrating complete resorption of the gas bubble 2 weeks after the operation.

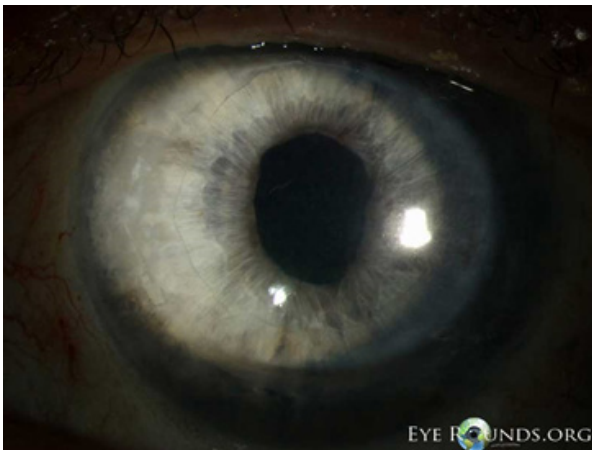

Figure 11: Post-operative appearance 1 month after DMAEK.

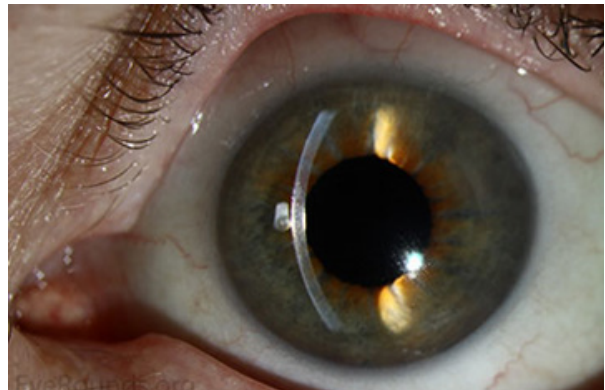
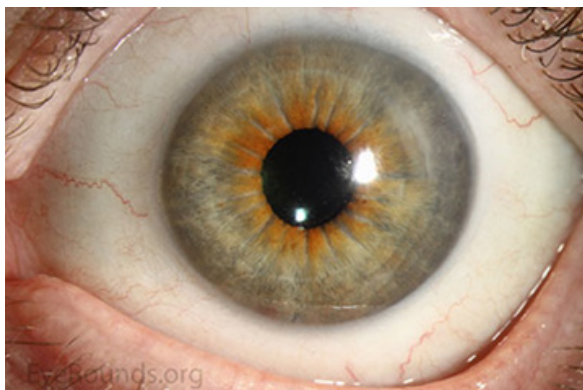

Figure 12: Clear cornea with 20/20 acuity 1 month after DMEK for Fuchs dystrophy

risk of allograft rejection and less long-term reliance on topical steroids compared with other types of keratoplasty. Discontinuation of topical steroids can be considered at or before 1 year after the procedure, especially for patients with elevated intraocular pressure.

Because of thinness, fragility, and its characteristic scrolling properties (with the endothelium facing outward), the donor tissue can be difficult to handle and contribute to technical difficulties with the procedure. There is a higher risk of graft edge lifts (Figure 13) compared with DSAEK, sometimes requiring a re-bubble procedure.

Video 4: vimeo.com/149335896 *Phakic DMEK*

Basic procedure steps (Video 4):

1. Create two to four paracentesis sites.
2. Fill the anterior chamber with Healon.
3. Create an inferior peripheral iridotomy using a bent 30-gauge needle and Sinskey hook to prevent post-operative pupillary block.
4. Mark the recipient's corneal epithelium with a circular ring slightly larger than the planned graft diameter to create a template for resection of the host tissue.
5. Score Descemet membrane peripherally using a reverse Terry-Sinskey hook, then peel Descemet membrane from the overlying stroma.
6. Create an incision temporally using a keratome, then remove the free Descemet membrane using forceps.
7. Remove the Healon using the irrigation/aspiration handpiece.
8. Inject Miochol to constrict the pupil and BSS to normalize the pressure.
9. Carefully lift the donor tissue by grasping the outermost edge with tying forceps and submerge it in trypan blue solution for 60 seconds to stain the tissue and make it more visible.
10. Place the tissue in a BSS-filled petri dish and it will scroll spontaneously. Aspirate it into a modified glass Jones tube.
11. Insert the tip of the glass tube into the clear corneal incision and inject the donor tissue into the anterior chamber.
12. Release fluid from a paracentesis to flatten the anterior chamber.
13. Gently tap and swipe on the anterior corneal surface until the graft is appropriately positioned and unscrolled.
14. Inject 20% SF6 into the anterior chamber to secure the graft and wait 10-15 minutes for adhesion.
15. Close the main incision with a 10-0 nylon suture.
16. Perform an air-fluid exchange to ensure there is no gas trapped behind the iris and assess for graft adhesion.
17. Injection another bubble of 20% SF6 to cover the graft, about 80-90% of the anterior chamber.

Additional Video Links

- DMEK for Fuchs dystrophy
eyerounds.org/atlas-video/DMEK.htm
- Descemet Membrane Endothelial Keratoplasty (DMEK)
eyerounds.org/atlas-video/DMEK.htm
- DMEK Democratized (ILEB pre-stripped graft/Jones tube injector/SF6 tamponade)
vimeo.com/149335896
- DMEK under PK Using a Modified Jones Tube Glass Injector
eyerounds.org/atlas-video/DMEK-PKP-modified-Jones-Tube.htm
- Iowa DMEK Technique Utilizing a Modified Jones Tube
eyerounds.org/atlas-video/Iowa-DMEK-mod-Jones-Tube.htm
- Phakic Descemet membrane endothelial keratoplasty (DMEK)
eyerounds.org/video/Cornea/Phakic-DMEK.htm

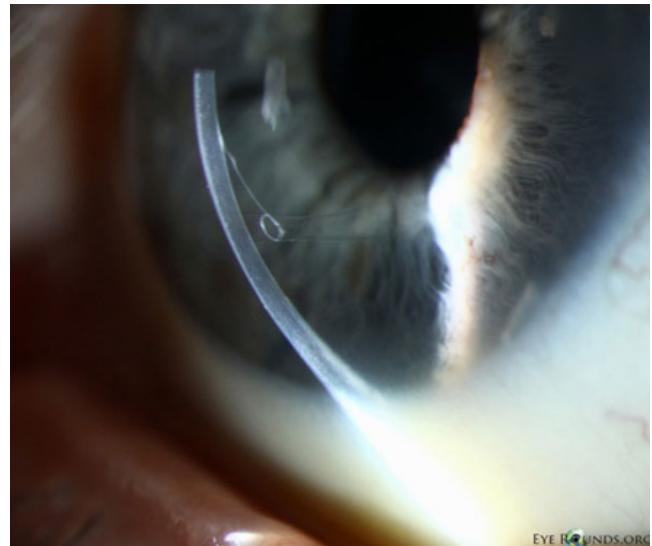


Figure 13: Chronic inferior edge lift of a DMEK graft. Notice the scrolling of the edge toward the stroma, indicating correct graft orientation, and the absence of stromal edema.

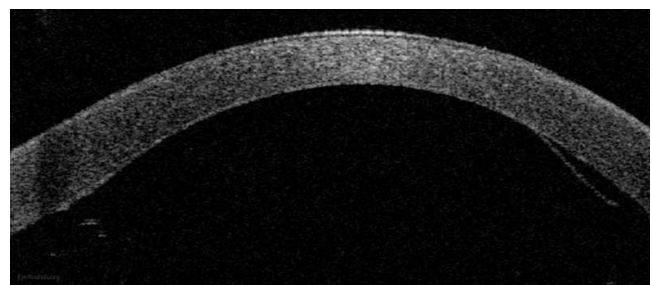


Figure 14: Anterior segment optical coherence tomography demonstrating a limited, peripheral graft edge lift one week after DMEK surgery (right side of image). The attached portion of the graft mimics normal anatomy due to the precise 1-to-1 replacement of tissue with DMEK.

Keratoprosthesis

Keratoprosthesis implantation is a procedure that involves full-thickness removal of the cornea and replacement by an artificial cornea. The Boston Type I Keratoprosthesis is currently the most commonly used keratoprosthesis device in the US. It consists of a clear plastic polymethylmethacrylate (PMMA) optic and back plate sandwiched around a corneal graft and secured with a titanium locking ring (Figure 15). After the device is assembled, a partial-thickness trephination is performed on the host cornea. Full-thickness resection of the patient's cornea is then completed using curved corneal scissors. The keratoprosthesis is then secured to host tissue using interrupted or running sutures. Generally, patients who have a history of multiple failed PKs are candidates for a keratoprosthesis transplant. Other indications include severe keratitis or ocular surface disease resulting from limbal stem cell failure, such as Stevens-Johnson syndrome (Figure 16), ocular cicatricial pemphigoid, aniridia (Figure 17) and chemical injury (1, 13). The Boston Type II Keratoprosthesis is a similar device with a longer optic designed to extend through an opening made in the upper eyelid (Figure 19). It is indicated for the most severe cicatrizing ocular surface diseases.

KPro placement offers relatively fast visual rehabilitation. The devices are amenable for use in many situations in which other types of keratoplasty are not an option.

There is significant long-term risk of complications for those with a keratoprosthesis. Because the KPro is a foreign body, there is risk of infection or extrusion of the device. Post-operative glaucoma is common and intraocular pressure is difficult to evaluate as the hard optic makes traditional tonometry impossible. For this reason, glaucoma tube shunts are typically placed at the time of the corneal transplant at the University of Iowa. The Diaton is currently the preferred way to measure intraocular pressure in these patients in our institution. Patients can form retroprosthetic

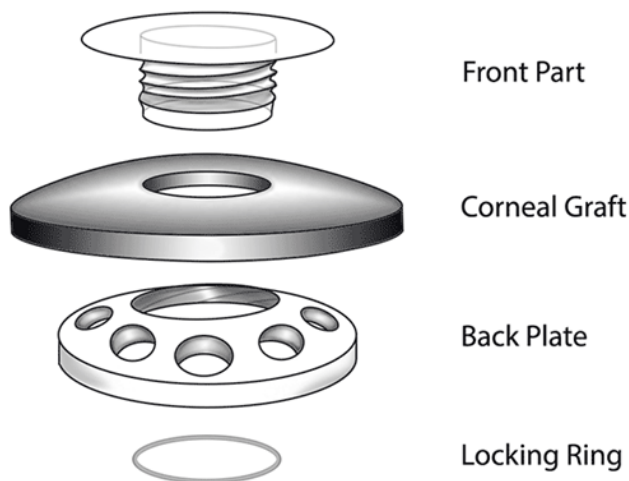


Figure 15: Assembly of the Boston Type I KPro device. Image courtesy of EyeWorld.org.

ic membranes requiring treatment with a Nd:YAG laser or surgical membranectomy (21).

Video 5: vimeo.com/161934772 Boston Type I Keratoprosthesis for aphakic bullous keratopathy following multiple failed corneal grafts

Basic procedure steps (Video 5):

1. Mark the center of the host cornea using a Sinsky hook and measure the cornea to determine the appropriate transplant size.
2. Trephine the donor cornea.
3. Assemble the keratoprosthesis by sandwiching the corneal graft between the front and back plates of the KPro device.
4. Trephinate the host cornea to approximately 90% depth.
5. Create a paracentesis, in the trephination groove or the corneal periphery, and inject Healon into the anterior chamber to preserve anterior chamber depth and stability.
6. After using a blade to enter the eye through the trephination groove, resect the host cornea tissue using curved corneal scissors.
7. Secure the donor tissue of the assembled KPro to the host corneal tissue using interrupted and/or running 9-0 nylon sutures.
8. Rotate the sutures to bury the knots.

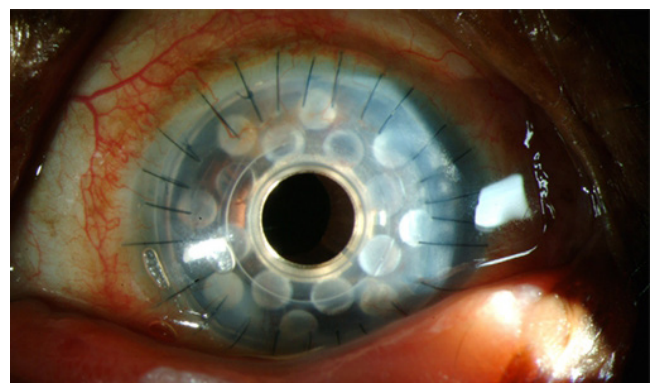
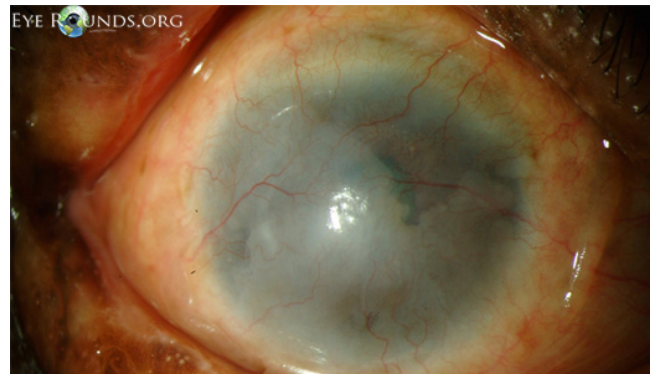


Figure 16: Pre- and post-operative appearance of a Boston Type I KPro device for Stevens-Johnson syndrome.

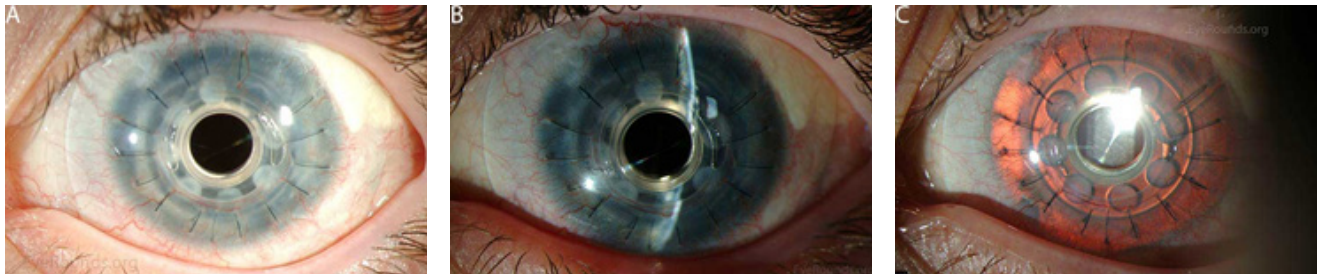


Figure 17: (A,B) Post-operative appearance of a Boston Type I KPro device for aniridia. (C) The back plate is visible on retroillumination.

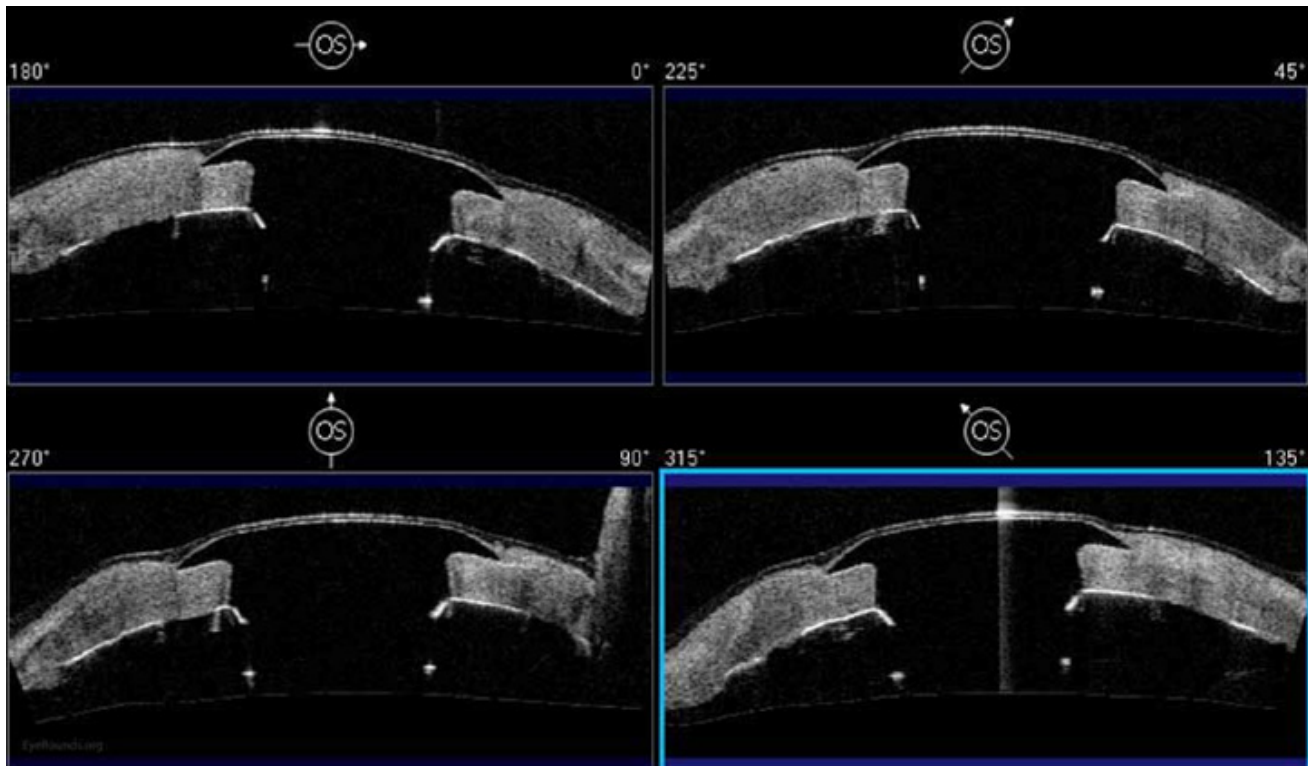


Figure 18: Anterior segment optical coherence tomography demonstrating the appearance of a Boston Type I Kpro with healthy corneal tissue surrounding the device.

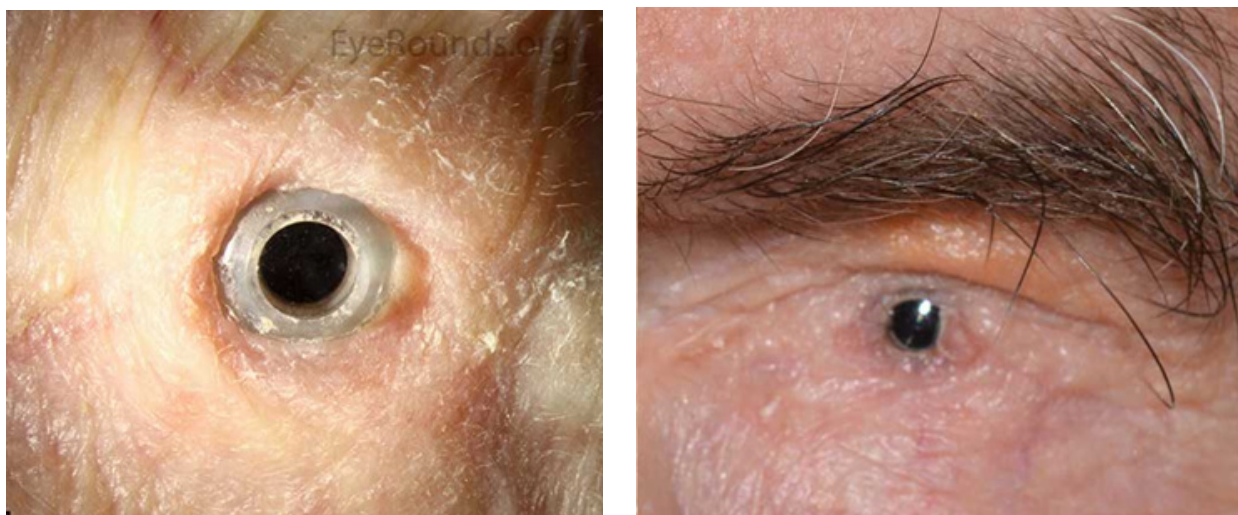

Figure 19: Boston Type II KPro for severe ocular cicatricial pemphigoid (left) and Stevens-Johnson syndrome (right)

Additional Keratoprosthesis Video Links

- Type 2 Boston Keratoprosthesis for Ocular Cicatricial Pemphigoid
eyerounds.org/cases-i/case122/122-OCP-QTvideo.htm
- Boston Keratoprosthesis Type I
eyerounds.org/atlas-video/Boston-keratoprosthesis-type-I.htm

A Note on Corneal Allograft Rejection

Corneal transplantation is regarded as the most successful solid organ transplantation procedure (1). Niziol et al. performed a study in 2013 with follow-up averaging 10 years and found that corneal rejection after PK for keratoconus occurred in 44% of grafts, but only 8% of grafts actually failed (22). While long-term rejection data is not yet available for the newer EK procedures, lesser rejection rates have been demonstrated after DMEK (0.7%) and DSAEK (9%) than PK (17%) at 2 years in patients on the same postoperative steroid regimen and treated for similar indications (23). This may be secondary to reduced antigen load in the thinner graft tissue. Modern treatment efforts can account for the vast difference between graft rejection and failure. However, graft rejection still remains a significant cause of corneal graft failure (Figure 16) (1). The most effective intervention is early recognition and prompt treatment with topical steroid drops. If the patient notices any redness, pain, or decreased vision, it is critical to seek prompt treatment to maximize chances of reversing the rejection episode.

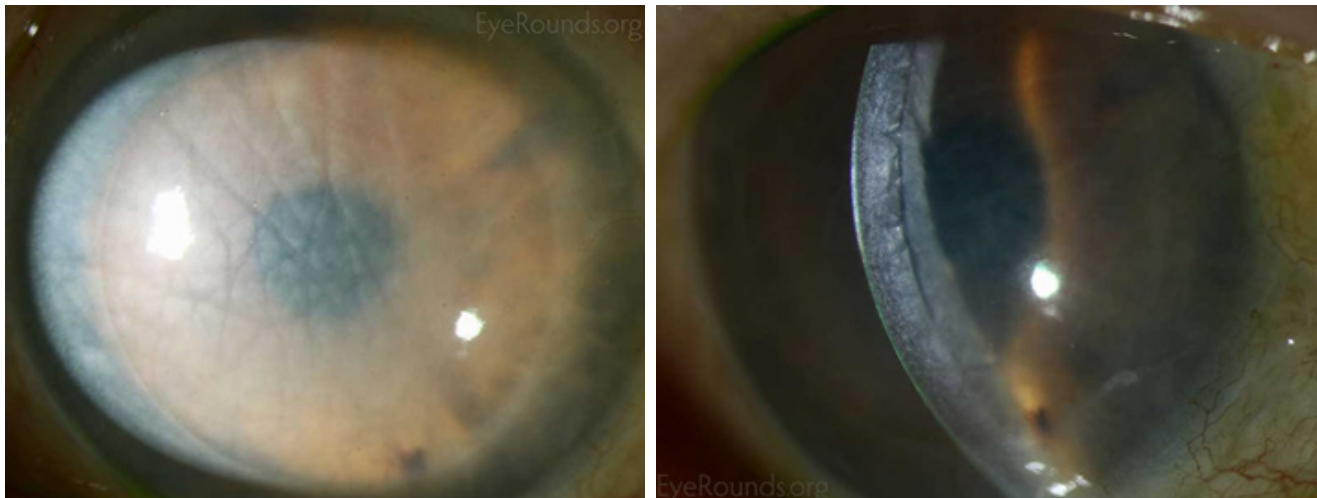


Figure 20: Massive corneal edema secondary to DSAEK allograft rejection. Accumulation of fluid is visible in the graft-host interface.

References

1. Krachmer JH, Mannis MJ, Holland EJ. Cornea: Fundamentals, Diagnosis, and Management: Mosby Elsevier; 2011.
2. Mannis MJ, Mannis AA. Corneal transplantation: a history in profiles. Oostende, Belgium: J.P. Wayenborgh; 1999.
3. Zirm EK. Eine erfolgreiche totale Keratoplastik (A successful total keratoplasty). 1906. Refractive & corneal surgery. Jul-Aug;5(4):258-61. PubMed PMID: 2488816.
4. Gupta V, Ray M, Ahuja R. Corneal Grafting Surgery: Historical Aspects. In: Vajpayee RB, editor. Corneal Transplantation. New Delhi: Jaypee Brothers Medical Publishers, Ltd.; 2002. p. 3-5.
5. Melles GR, Eggink FA, Lander F, Pels E, Rietveld FJ, Beekhuis WH, et al. A surgical technique for posterior lamellar keratoplasty. Cornea. 1998 Nov;17(6):618-26. PubMed PMID: 9820943.
6. Melles GR, Lander F, Beekhuis WH, Remeijer L, Binder PS. Posterior lamellar keratoplasty for a case of pseudophakic bullous keratopathy. American journal of ophthalmology. 1999 Mar;127(3):340-1. PubMed PMID: Melles GR, Lander F, van Dooren BT, Pels E, Beekhuis WH. Preliminary clinical results of posterior

- lamellar keratoplasty through a sclerocorneal pocket incision. *Ophthalmology*. 2000 Oct;107(10):1850-6; discussion 7. PubMed PMID: 11013184.
7. Terry MA, Ousley PJ. Deep lamellar endothelial keratoplasty in the first United States patients: early clinical results. *Cornea*. 2001 Apr;20(3):239-43. PubMed PMID: 11322409.
 8. Gorovoy MS. Descemet-stripping automated endothelial keratoplasty. *Cornea*. 2006 Sep;25(8):886-9. PubMed PMID: 17102661.
 9. Maier AK, Gundlach E, Gonnermann J, Klamann MK, Bertelmann E, Rieck PW, et al. Retrospective contralateral study comparing Descemet membrane endothelial keratoplasty with Descemet stripping automated endothelial keratoplasty. *Eye*. 2014 Nov 21. PubMed PMID: 25412715.
 10. Gasset AR. Lamellar keratoplasty in the treatment of keratoconus: conectomy. *Ophthalmic surgery*. 1979 Feb;10(2):26-33. PubMed PMID: 370707.
 11. Anwar M, Teichmann KD. Big-bubble technique to bare Descemet's membrane in anterior lamellar keratoplasty. *Journal of cataract and refractive surgery*. 2002 Mar;28(3):398-403. PubMed PMID: 11973083.
 12. Zerbe BL, Belin MW, Ciolino JB, Boston Type 1 Keratoprosthesis Study G. Results from the multicenter Boston Type 1 Keratoprosthesis Study. *Ophthalmology*. 2006 Oct;113(10):1779 e1-7. PubMed PMID: 16872678.
 13. Ing JJ, Ing HH, Nelson LR, Hodge DO, Bourne WM. Ten-year postoperative results of penetrating keratoplasty. *Ophthalmology*. 1998 Oct;105(10):1855-65. PubMed PMID: 9787355.
 14. Fontana L, Parente G, Tassinari G. Clinical outcomes after deep anterior lamellar keratoplasty using the big-bubble technique in patients with keratoconus. *American journal of ophthalmology*. 2007 Jan;143(1):117-24. PubMed PMID: 17188045.
 15. Vajpayee RB, Tyagi J, Sharma N, Kumar N, Jhanji V, Titiyal JS. Deep anterior lamellar keratoplasty by big-bubble technique for treatment corneal stromal opacities. *American journal of ophthalmology*. 2007 Jun;143(6):954-7. PubMed PMID: 17434435.
 16. Melles GR. Posterior lamellar keratoplasty: DLEK to DSEK to DMEK. *Cornea*. 2006 Sep;25(8):879-81. PubMed PMID: 17102659.
 17. Price MO, Price FW. Descemet's stripping endothelial keratoplasty. *Curr Opin Ophthalmol*. 2007 Jul;18(4):290-4. PubMed PMID: 17568204.
 18. Covert DJ, Koenig SB. Descemet stripping and automated endothelial keratoplasty (DSAEK) in eyes with failed penetrating keratoplasty. *Cornea*. 2007 Jul;26(6):692-6. PubMed PMID: 17592318.
 19. Price MO, Price FW, Jr. Descemet stripping with endothelial keratoplasty for treatment of iridocorneal endothelial syndrome. *Cornea*. 2007 May;26(4):493-7. PubMed PMID: 17457204.
 20. Greiner MA, Li JY, Mannis MJ. Longer-term vision outcomes and complications with the Boston type 1 keratoprosthesis at the University of California, Davis. *Ophthalmology* 2011;118(8):1543-50.
 21. Niziol LM, Musch DC, Gillespie BW, Marcotte LM, Sugar A. Long-term outcomes in patients who received a corneal graft for keratoconus between 1980 and 1986. *American journal of ophthalmology*. 2013 Feb;155(2):213-9 e3. PubMed PMID: 23111176.
 22. Anshu A, Price MO, Price FW Jr. Risk of corneal transplant rejection significantly reduced with Descemet's membrane endothelial keratoplasty. *Ophthalmology* 2012 Mar; 119(3):536-40. PubMed PMID 22218143.

last updated: 05/21/2015

Epithelial-Stromal and Stromal Corneal Dystrophies

A Clinicopathologic Review

Emily S. Birkholz, MD, Nasreen A. Syed, MD, and Michael D. Wagoner, MD, PhD - August 17, 2009

Major Revision: Chaunhi Van, MD and Nasreen Syed, MD - August 20, 2015

INTRODUCTION

Corneal epithelial-stromal and stromal dystrophies are a group of inherited disorders of the cornea that are caused by progressive accumulation of deposits within the layers of the cornea. These deposits are not caused by inflammation, infection, or trauma, but by genetic mutations that lead to transcription of aberrant proteins resulting in the accumulation of insoluble material within the cornea. The disorders may or may not affect vision and may or may not be symmetrical (1). The 2015 International Committee for Classification of Corneal Dystrophies (IC3D) classification system has divided corneal dystrophies into 4 categories: epithelial and subepithelial dystrophies, epithelial-stromal dystrophies, stromal dystrophies, and endothelial dystrophies. Most dystrophies previously considered stromal are now classified as either epithelial-stromal dystrophies or stromal dystrophies. Table 1 and 2 list the epithelial-stromal dystrophies and stromal dystrophies (2). The old classification for corneal stromal dystrophies is listed in Table 3.

Table 1: Epithelial-stromal Corneal Dystrophies

- ◆ Reis-Bücklers corneal dystrophy
- ◆ Thiel-Behnke corneal dystrophy
- ◆ Lattice corneal dystrophy, type 1 and variants
- ◆ Granular corneal dystrophy, type 1

Table 2: Stromal Corneal Dystrophies

- ◆ Macular corneal dystrophy
- ◆ Schnyder corneal dystrophy
- ◆ Congenital stromal corneal dystrophy
- ◆ Posterior amorphous corneal dystrophy
- ◆ Central cloudy dystrophy of Francois
- ◆ Pre-Descemet corneal dystrophy

Table 3. Old classification of corneal stromal dystrophies

- ◆ Lattice corneal dystrophy
- ◆ Granular corneal dystrophy
- ◆ Avellino corneal dystrophy
- ◆ Macular corneal dystrophy
- ◆ Gelatinous drop-like dystrophy
- ◆ Schnyder corneal dystrophy
- ◆ Francois-Neetans Fleck dystrophy
- ◆ Congenital hereditary stromal dystrophy

EPITHELIAL-STROMAL CORNEAL DYSTROPHIES

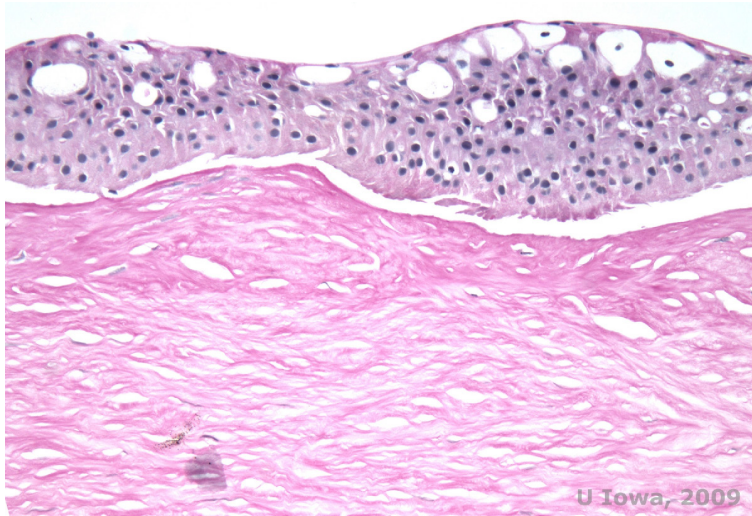
Epithelial-stromal dystrophies are caused by mutations in transforming growth factor beta-induced (TGFβ1) gene, also known as the BIGH3 gene. TGFβ1 is located on chromosome 5q31 and codes for keratoepithelin, a protein secreted by corneal epithelium. This protein acts as an adhesion protein and is present in normal stroma. Being a small protein roughly the size of albumin, it has the capability to diffuse through the corneal stroma. When a mutation in the TGFβ1 gene occurs, the keratoepithelin structure is abnormal and accumulation of the insoluble protein or its proteolytic fragments occurs in the cornea (1, 3). Interestingly, the TGFβ1 gene mutation was discovered in part at the University of Iowa. A group of researchers and clinicians including Edwin M. Stone, Robert Folberg, and Jay H. Krachmer mapped granular type I, granular type II, and lattice dystrophy to chromosome 5q in 1994 (4). To date, 63 different mutations have been identified in the TGFβ1 gene. No effective treatments to prevent or attenuate the deposition of the keratoepithelin have been identified. The dystrophies typically have an autosomal dominant inheritance and involve Bowman layer and stroma (3).

REIS-BUCKLERS CORNEAL DYSTROPHY

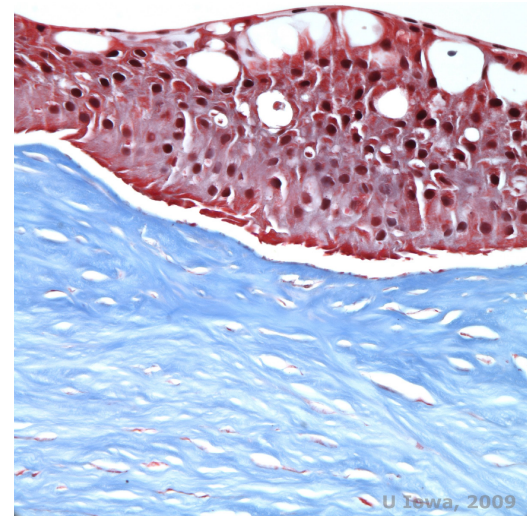
Reis-Bücklers, formerly known as Granular corneal dystrophy type III or Corneal Dystrophy of Bowman's type I, typically present with normal corneas at birth but develop painful recurrent erosions, opacification, and progressive vision loss within the first decade of life (1). Irregular, grey-white, geographic-like opacities are located in the Bowman layer and anterior stroma. In more advanced stages of the disease, the opacities can extend to the limbus and deeper stroma (2). Histopathology reveals anterior stromal and subepithelial deposits of hyaline-like material which disrupt and often replace Bowman's layer (See Figure 1A and 1B). The deposits stain red with Masson trichrome stain (2). The hyaline-like material consists of rod-like bodies ultrastructurally, which helps distinguish it from Thiel-Behnke corneal dystrophy (1, 2).

LATTICE CORNEAL DYSTROPHY

Lattice corneal dystrophy (LCD) is the most common of the corneal epithelial-stromal dystrophies. It is typically an autosomal dominant, bilateral disease that typically presents toward the end of the first decade of life with symptoms of recurrent corneal erosions and decreased vision. It is characterized by lattice lines which are linear, radially oriented, branching refractile opacities described as "glass



A: H&E of Reis Bückler showing destruction of Bowman's layer and irregular epithelium



B. Masson Trichrome stain demonstrating epithelial staining

Figure 1. Reis-Bückler corneal dystrophy

like" located in the anterior stroma (See Figure 2A and 2B). These lattice lines are initially found in the superficial central cornea. As the disease progresses, they spread deeper and peripherally in the stroma with sparing of the limbus (1, 2). Other exam findings include fleck-like opacities, subepithelial white dots, and "ground-glass" stromal haze, which starts centrally and become more diffuse (2). Many patients with LCD will require surgical intervention for treating recurrent erosions and decreased vision. If the disease is located anteriorly in the stroma, patients can often be successfully treated with phototherapeutic keratectomy (PTK). Some require corneal transplantation. Because keratoepithelin, the protein produced by the TGF β 1 gene, is produced mostly in the corneal epithelium, the disease tends to recur in corneal grafts (1).

In LCD, amyloid deposits accumulate between the epithelial basement membrane and Bowman layer as well as in the stroma, causing distortion of the lamellar architecture. The deposits stain positively with immunohistochemistry using antibodies against keratoepithelin (2). The deposits appear as amorphous pink deposits on hematoxylin and eosin (H&E) stain (See Figure 1C and 1D) and stain with Congo red stain demonstrating the classic apple green birefringence on cross-polarization (See Figure 2E and 2F) (1). Absence or thinning of Bowman layer, epithelial atrophy and basal epithelial degeneration can also be found on histopathology in LCD (2).

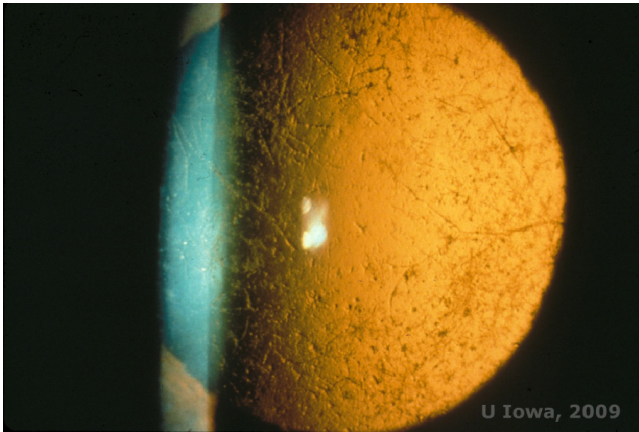
LCD type I is the classic form of LCD caused by a mutation in the TGF β 1 gene resulting in isolated amyloid deposition in the cornea. Four LCD variants had been identified: LCD type IIIA, type I/IIIA, type IV, and polymorphic amyloidosis. LCD variants present later in life than classic LCD. LCD type IIIA presents in the 5th-7th decade, usually with epithelial erosions. It has thicker lattice lines, described as "ropy-appearing", which extends to the limbus. LCD type I/IIIA has thin lattice lines. LCD type IV presents in the 7th-9th decade with small lattice lines. Amyloid deposits

in LCD type IV are found in the deep stroma and epithelial erosions rarely occur. Lattice lines are absent in polymorphic amyloidosis type [EyeRounds.org/cases/173-Polymorphic-amyloid-degeneration.htm] and rarely do epithelial erosions occur (2).

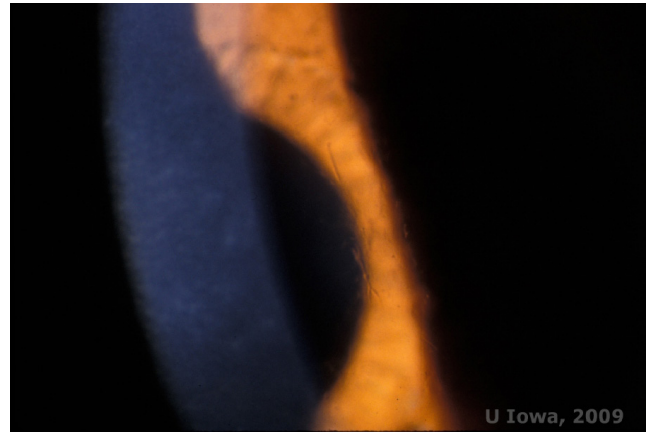
LCD type II is a systemic amyloidosis syndrome known as Meretoja syndrome [EyeRounds.org/cases/176-meretoja.htm] affecting the skin, cranial nerves and cornea. It presents in early adulthood with peripheral neuropathies, cranial neuropathies, hound-like facies, dry skin, blepharochalasis, protruding lips, and corneal lattice lines. This type has been linked to the gelsolin gene on chromosome 9, which encodes for an amyloid precursor protein which functions to remove actin from sites of injury and inflammation (1). The name is a misnomer and is not considered a variant of lattice corneal dystrophy (2).

GRANULAR CORNEAL DYSTROPHY, TYPE I

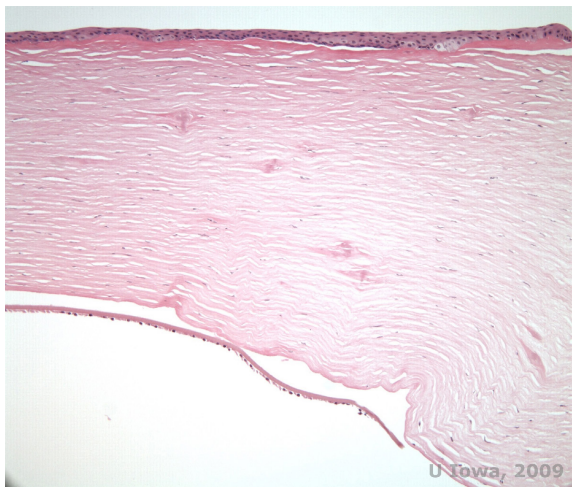Granular corneal dystrophy, type I (GCD1) is a bilateral, autosomal dominant disease associated with a mutation in the TGF β 1 gene that leads to the deposition of a hyaline material in the corneal stroma. It typically presents early in the first decade of life with gray-white, "crumb-like" opacities in the anterior to mid stroma, extending into the posterior stroma in advance disease (1, 2). These opacities are discrete deposits located centrally, with clear cornea located in the periphery and clear cornea between deposits (See Figure 3A and 3B). The disease is typically asymptomatic early on, but with time the opacities can coalesce and lead to decreased vision. Recurrent corneal erosions can occur in GCD but at a lower incidence than in LCD (1, 5). Patients can also experience glare and photophobia (2). Treatment early on in the disease process is often observation only. However, as the disease progresses, PTK and corneal transplantation may be needed to improve vision and erosion symptoms. Like LCD, the disease can recur in corneal grafts.



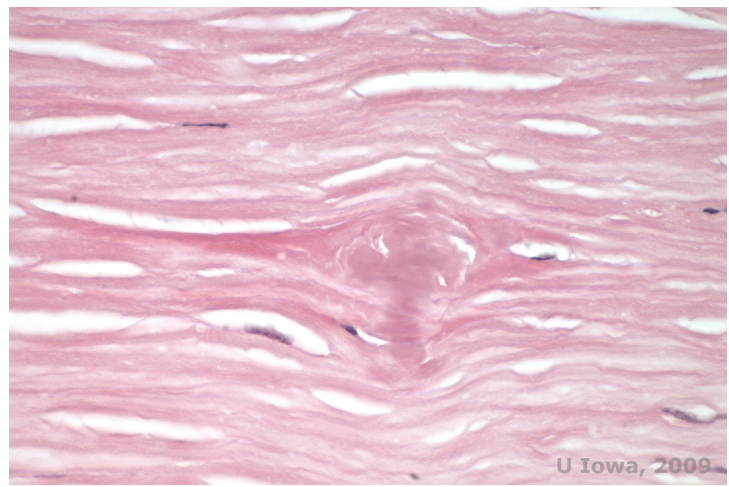
A: Left eye on retroillumination demonstrating anterior stromal deposits in lattice corneal dystrophy



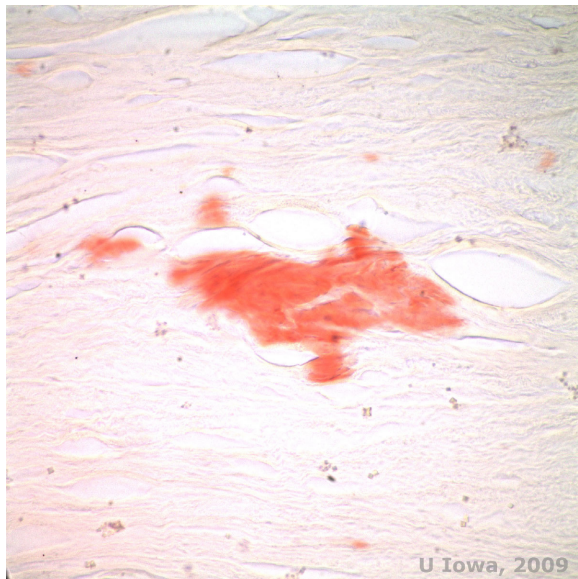
B: Left eye with higher power showing linear anterior stromal deposits.




C: H&E stain of cornea with lattice. Note pink amorphous deposits in stroma



D: A closer view of the pink, amorphous deposits

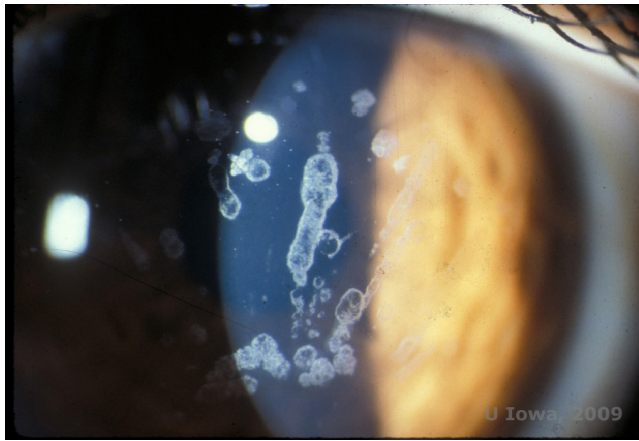


E: Congo red stain, highlighting amyloid

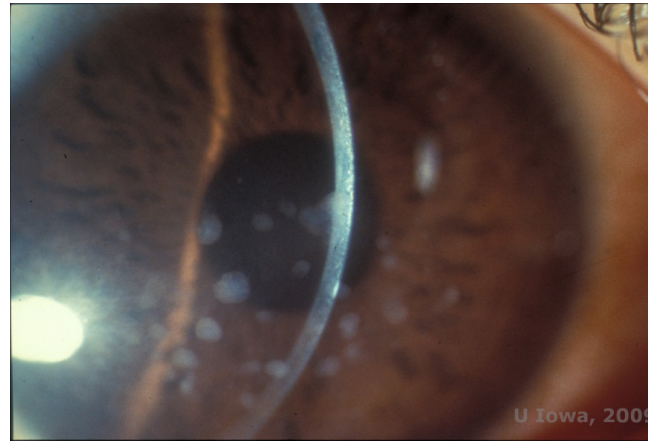


F: Apple-green birefringence of amyloid with cross-polarization.

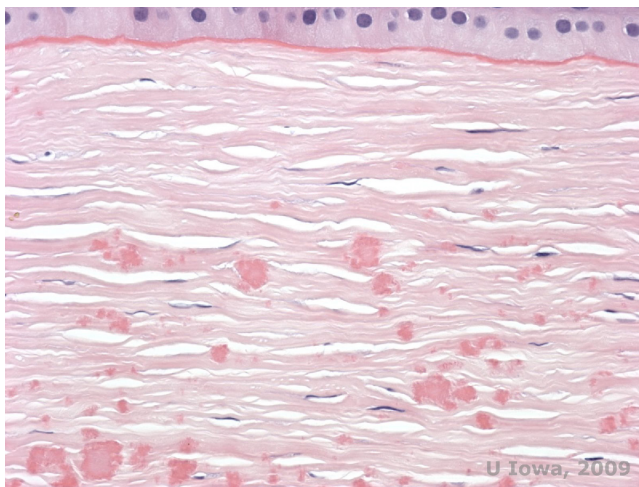
Figure 2. Lattice corneal dystrophy



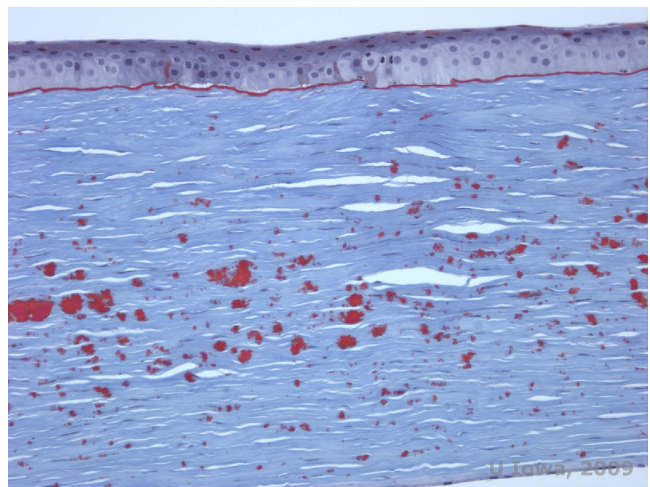
A: Slit lamp photo of Granular Corneal Dystrophy, Type I



B: Note the "crumb-like" stromal deposits with clear intervening stroma.



C: H&E stain of cornea showing eosinophilic "rock candy like" hyaline deposits in stroma



D: Hyaline material stains bright red with Masson-Trichrome

Figure 3. Granular corneal dystrophy, type I

Histopathologically the opacities are eosinophilic deposits often described as "rock candy like" in the anterior stroma made of a hyaline-like material. With time, the deposits progress into the deeper corneal stroma. The hyaline material stains bright red with Masson trichrome stain (See Figure 3C and 3D).

GRANULAR CORNEAL DYSTROPHY, TYPE II

Granular corneal dystrophy, type II (GCD2), formerly known as Avellino or combined granular-lattice corneal dystrophy, is an autosomal dominant disease linked to a mutation in the *TGFβ1* gene that leads to a deposition of both hyaline and amyloid in the corneal stroma. Typically, patients present in the second decade of life with small grey-white dots in the superficial stroma. The opacities can also appear thorn-like, ring, or stellate in shape. In retroillumination, they are partially translucent. Later in the disease process, they can develop lattice lines as well (See Figure 4A and 4B). These lines do not cross each other and appear whiter and less refractile than lattice lines. Symp-

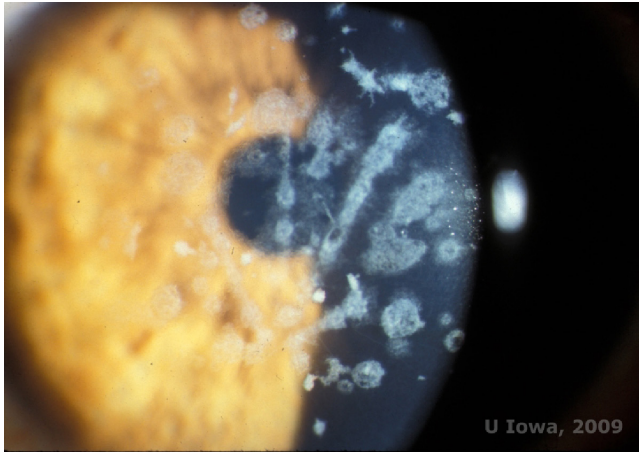
toms of GCD2 are pain with epithelial erosions and visual impairment (2).

Histopathologically, the cornea will have stromal deposits that stain red with Masson Trichrome, indicating the presence of hyaline (See Figure 4C). In addition, staining with Congo red will demonstrate apple-green birefringence on cross-polarization indicating the presence of amyloid (See Figure 4D). The disease was thought to have originated from a family in Avellino, Italy. However, GCD type II has now been reported in patients from many other countries as well (2,5), with the highest prevalence being in east Asia.

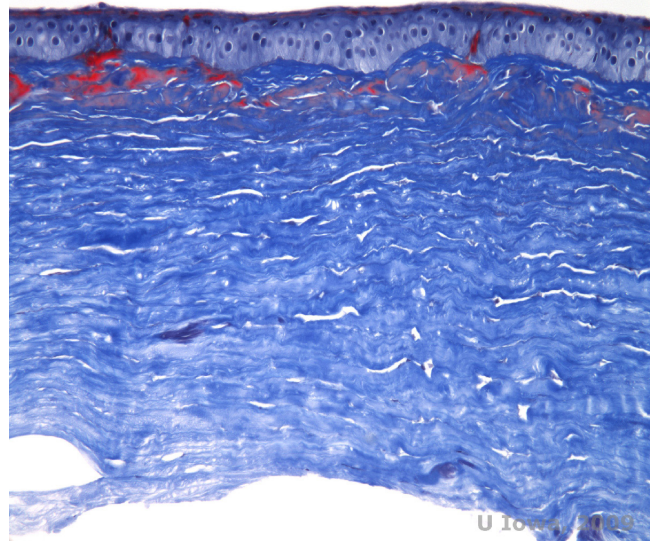
STROMAL CORNEAL DYSTROPHIES

MACULAR CORNEAL DYSTROPHY

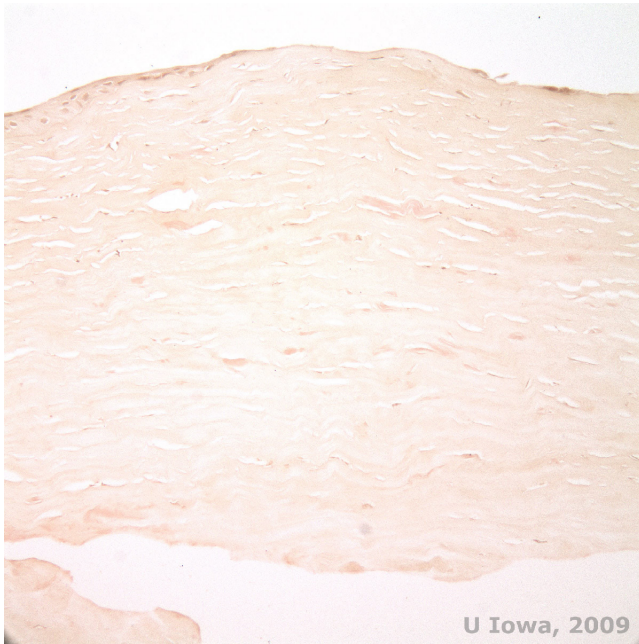
Macular corneal dystrophy (MCD) is an autosomal recessive disease caused by a mutation in carbohydrate sulfotransferase 6 gene (*CHST6*) on chromosome 16 that leads to a defect in the synthesis of keratan sulfate, the major




A: Avellino dystrophy showing lattice like and granular like deposits in corneal stroma



B. Masson Trichrome stain demonstrating anterior stromal hyaline deposits



C: Congo red stain showing pink, amorphous amyloid deposits in the same corneal specimen.



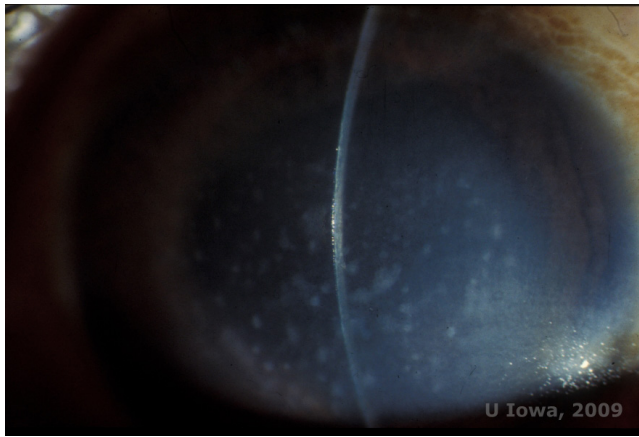
D: Cross-polarization reveals apple green birefringence indicating amyloid.

Figure 4. Type II granular corneal dystrophy Avellino dystrophy

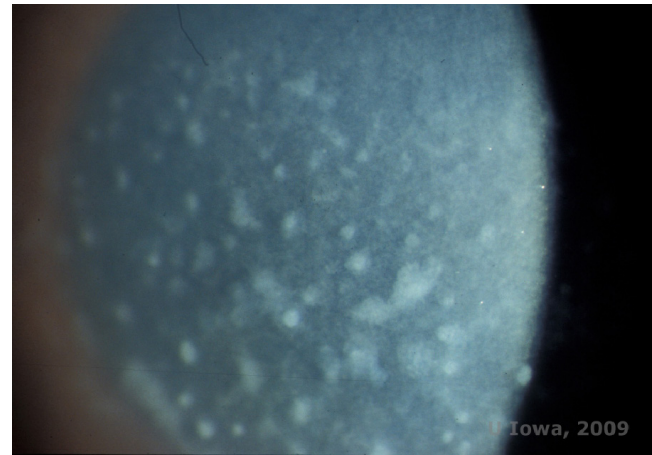
glycosaminoglycan of the cornea. It is the less common than LCD or GCD, but tends to impact vision more severely. Although MCD is less common worldwide than LCD or GCD, it is the most common of the corneal stromal dystrophies in places such as Iceland and Saudi Arabia (2,6). Gray-white, fleck-like anterior stromal lesions similar to GCD1 appear in the cornea in the first decade of life. Unlike GCD1, however, there is stromal haze between the deposits and the entire cornea from limbus to limbus is often involved (See Figure 5A and 5B). The cornea is thin and as the disorder progresses Descemet membrane becomes

grey and develops guttae. Epithelial erosions can occur, but less in MCD than in LCD. Patients typically develop severe visual loss by the second to third decade of life due to diffuse corneal haze. PTK can be performed in some early cases of MCD. However, this condition is generally not as amenable to PTK as lattice or granular dystrophy and often requires corneal transplantation for treatment (7). Recurrence in grafts is less common in MCD than with granular or lattice dystrophy (1,2,5,6,8).

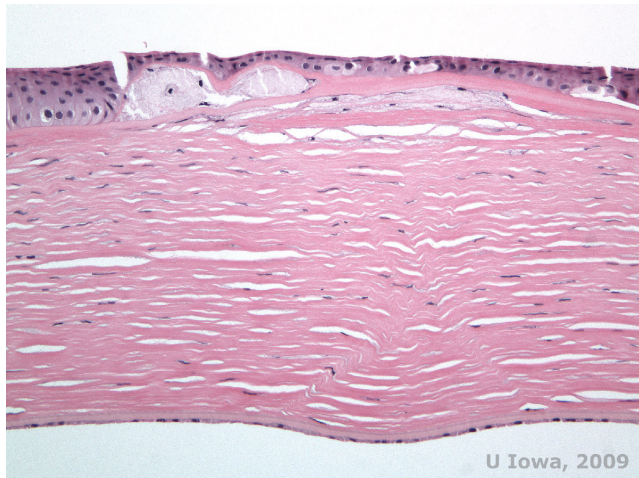The stromal deposits in MCD are composed of mucopolysaccharides that accumulate within the endoplasmic



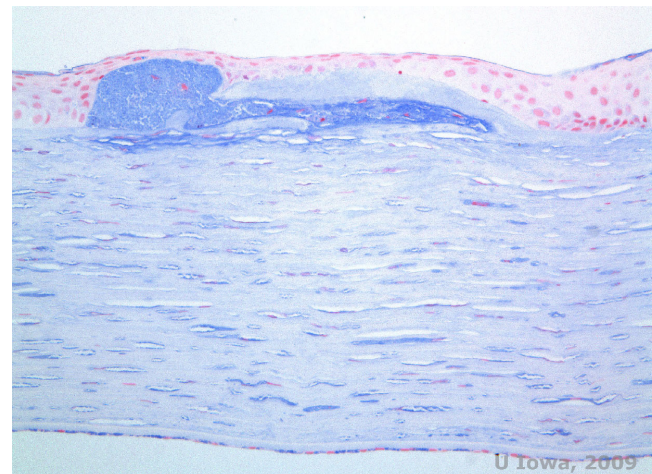
A: Slit lamp photo of macular corneal dystrophy.



B: Note the haze between the corneal stromal deposits



C: H&E of cornea with macular dystrophy. Note anterior stromal deposits and Bowman's layer disruption



D: Mucopolysaccharide deposits within keratocytes highlighted with Alcian Blue stain

Figure 5. Macular corneal dystrophy

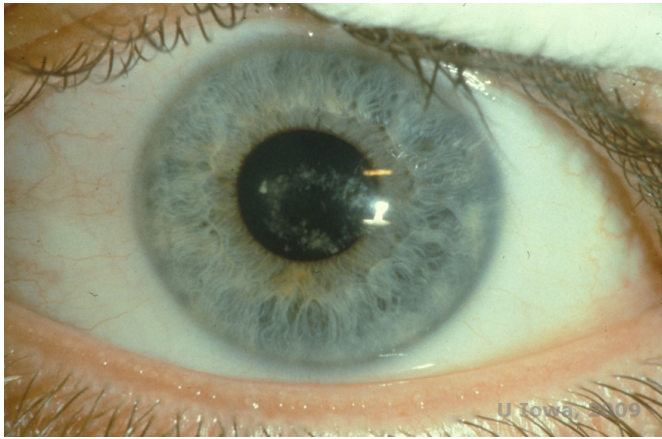
reticulum of keratocytes of the corneal stroma, extracellularly between stromal lamellae, and within the epithelium, Descemet membrane and endothelium. These deposits stain blue with Alcian blue (See figure 5C and 5D) (1). There are breaks in Bowman layer and guttae with thickening of Descemet membrane (2).

Three subtypes of MCD have been described based on the presence or absence of immunoreactive keratan sulfate within various tissues. Type I does not have immunoreactive keratan sulfate in the corneal stroma, keratocytes, sera or cartilage, and is the most common variant of MCD worldwide. Type IA lacks keratan sulfate in the stroma, sera, and cartilage, but has detectable levels inside keratocytes. Type II has keratan sulfate present at much reduced levels in the stroma, keratocytes, sera and cartilage (6).

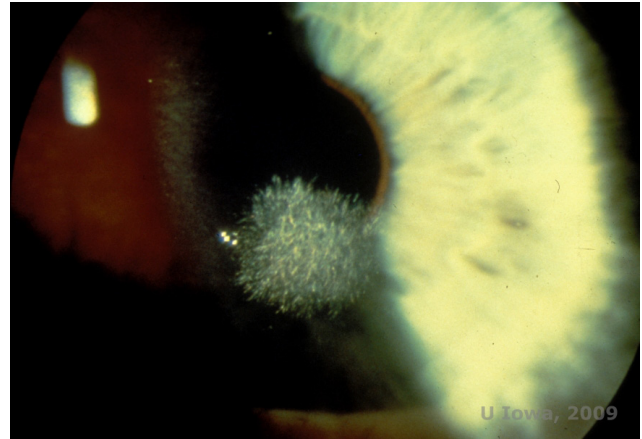
SCHNYDER CORNEAL DYSTROPHY (SCD)

Schnyder corneal dystrophy (SCD), previously known as Schnyder crystalline corneal dystrophy, is an autosomal

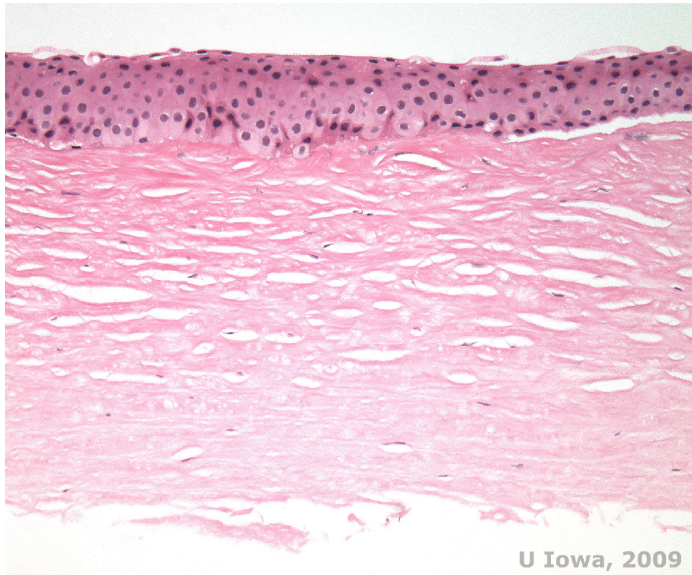
dominant, bilateral corneal stromal dystrophy linked to a genetic mutation in UbiA prenyltransferase domain containing 1 (UBIAD1) gene on chromosome 1. The resulting metabolic defect of corneal keratocytes leads to crystalline cholesterol deposition in the stroma. However, presence of crystals is not absolutely necessary for the diagnosis of SCD. In fact, only 54% of patients with SCD have corneal crystals. Typically, patients present in the second or third decade with a ring-shaped central corneal opacity with or without comma-shaped subepithelial crystals (See Figure 6A and 6B). Then, arcus lipoides appears between the ages of 23 and 38. After age 38, progressive corneal clouding results in a panstromal haze reaching the midperiphery. Most patients over 50 years of age have photopic vision loss, glare, and decreased corneal sensation, and therefore, may require surgical treatment including corneal transplantation or PKT. Recurrence in the graft may occur. The disease has been linked with hypercholesterolemia, hyperlipidemia and genu valgum in some patients (2,5,9,10).



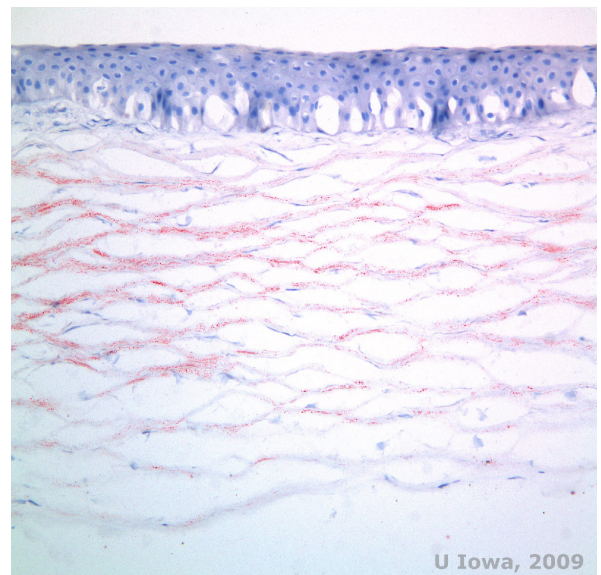
A: Slit lamp photo of Schnyder Corneal Dystrophy.



B. Centrally located crystalline deposits



C: H&E of cornea with SCCD



D. Oil Red O stain highlights cholesterol crystals that appear red.

Figure 6. Schnyder corneal dystrophy

Histopathologically, birefringent cholesterol crystals composed of phospholipids and cholesterol deposit within basal epithelial cells, keratocytes, Bowman's layer, and between stromal lamellae. Lipids dissolve in normal histologic processing, so frozen sections through the cornea must be obtained to demonstrate the presence of lipid with Oil-Red-O or Sudan black stains.

Table 4 provides a common mnemonic for memorizing some of the corneal dystrophies affecting the stroma, the composition of their deposit, and the method of staining these deposits is listed.

Table 4: Mnemonic for remembering corneal stromal dystrophies

- ◆ Marilyn—Macular Dystrophy
- ◆ Monroe—Mucopolysaccharide
- ◆ Always—Alcian Blue stain
- ◆ Gets—Granular Dystrophy
- ◆ Her—Hyaline
- ◆ Man in—Masson Trichrome stain
- ◆ Los—Lattice Dystrophy
- ◆ Angeles—Amyloid
- ◆ California—Congo Red

OVERVIEW: CORNEAL STROMAL DYSTROPHIES

<p>EPIDEMIOLOGY</p> <ul style="list-style-type: none"> ◆ Autosomal Dominant disease <ul style="list-style-type: none"> ○ Reis-Bucklers corneal dystrophy (RBCD) ○ Granular corneal dystrophy(GCD1) ○ Granular corneal dystrophy, type II (GCD2) ○ Lattice corneal dystrophy(LCD) ○ Schnyder corneal dystrophy(SCD) ◆ Autosomal Recessive <ul style="list-style-type: none"> ○ Macular corneal dystrophy(MCD) ◆ Present in 1st-3rd decade of life 	<p>SIGNS</p> <ul style="list-style-type: none"> ◆ Recurrent erosions ◆ Bilateral corneal stromal deposits in various patterns <ul style="list-style-type: none"> ○ Crumb-like deposits for GCD1, GCD2, RBCD ○ Lattice lines for LCD ○ Diffuse haze and stromal deposits for MCD ◆ Central corneal opacity or crystalline deposits with surrounding Arcus for SCD
<p>SYMPTOMS</p> <ul style="list-style-type: none"> ◆ Initially none ◆ Bilateral recurrent erosions causing pain, tearing, and foreign body sensation ◆ Over time can have decreased vision 	<p>TREATMENT</p> <ul style="list-style-type: none"> ◆ Early in course <ul style="list-style-type: none"> ○ Observation ○ Lubrication ○ Manage recurrent erosions with bandage contact lens and topical antibiotic (erythromycin ointment or 3rd-4th generation fluoroquinolone) ◆ Phototherapeutic Keratectomy ◆ Corneal Transplantation <ul style="list-style-type: none"> ○ If recurrent erosions severe or if decreased vision ○ Recurs in grafts

Related EyeRounds Entries

- ◆ Avellino Dystrophy EyeRounds.org/atlas/pages/Avellino-dystrophy
- ◆ Central cloudy dystrophy of Francois EyeRounds.org/atlas/pages/Central-cloudy-dystrophy-of-Francois.html
- ◆ Granular corneal dystrophy, type I EyeRounds.org/atlas/pages/Granular-corneal-dystrophy
- ◆ Granular corneal dystrophy, type II EyeRounds.org/atlas/pages/Avellino-dystrophy
- ◆ Lattice corneal dystrophy, type I EyeRounds.org/atlas/pages/lattice-corneal-dystrophy.htm
- ◆ Lattice corneal dystrophy, type II, Meretoja Syndrome webeye.ophth.uiowa.edu/eyeforum/cases/176-meretoja.htm
- ◆ Macular corneal dystrophy EyeRounds.org/atlas/pages/macular-corneal-dystrophy.htm
- ◆ Polymorphic Amyloidosis webeye.ophth.uiowa.edu/eyeforum/cases/173-Polymorphic-amyloid-degeneration.htm
- ◆ Reis-Bucklers corneal dystrophy (RBCD) EyeRounds.org/atlas/pages/Reis-Bucklers.htm
- ◆ Schnyder corneal dystrophy EyeRounds.org/atlas/pages/Schnyder-dystrophy
- ◆ Reis-Bucklers corneal dystrophy EyeRounds.org/atlas/pages/Reis-Bucklers.htm

References

1. Keefe KS, Milman T, Rodrigues MM, Hidayat AA. Conjunctival and Corneal Pathology. Albert and Jakobiec's Principles and Practice of Ophthalmology, 3rd edition. Saunders. 2008: 3592-3595.
2. Weiss JS, et al. IC3D classification of corneal dystrophies--edition 2. Cornea 2015; 34 (2): 117-159.
3. Lakshminarayanan R, et al. Clinical and genetic aspects of the TGFBI-associated corneal dystrophies. Ocul Surf 2014; 12 (4): 234-251.
4. Stone EM, et al. Three autosomal dominant corneal dystrophies map to chromosome 5q. Nature genet. 1994; 6: 47-51.
5. Bron AJ. Genetics of the Corneal Dystrophies: What we have learned in the past twenty five years. Cornea 2000; 19(5): 699-711.
6. Al-Swailem SA, Al-Rajhi AA, Wagoner MD. Penetrating Keratoplasty for Macular Corneal Dystrophy. Ophthalmology 2005;112: 220-224.
7. Badr IA, Wagoner MD. Phototherapeutic Keratectomy for Macular Corneal Dystrophy. J Refract Surg 1999;15:481-484.
8. Poulaki V, Colby K. Genetics of anterior and stromal corneal dystrophies. Seminars in Ophthalmology, 2008; 23: 1,9-17.

9. Weiss JS. Schnyder corneal dystrophy. *Curr Opin Ophthalmol* 2009; 20 (4): 292-298
10. Shearman AM, Hudson TJ, Andresen JM, et al. The gene for Schnyder's crystalline corneal dystrophy maps to human chromosome 1p34.1p36. *Hum Mol Genet* 1996;5:1667-72.

Citing this article

Van C, Syed NA. Epithelial-Stromal and Stromal Corneal Dystrophies: A Clinicopathologic Review. Revision of [Birkholz ES, Syed NA, Wagoner, MD. Corneal Stromal Dystrophies: A Clinicopathologic Review. Aug. 17, 2009]; EyeRounds.org. August 20, 2015. Available from: eyerounds.org/cases/43-Corneal-Stromal-Dystrophies.htm

last updated: 08-20-2015

Ocular Surface Tumors

Matthew Benage, MD; Austin R. Fox, MD; Michelle R. Boyce, MD; Mark A. Greiner, MD

Key contributor: Nasreen A. Syed, MD

December 20, 2017

Introduction

Ocular surface tumors are rare but potentially deadly diseases of the conjunctiva and/or cornea. It is important for ophthalmologists to recognize the characteristics of ocular surface tumors and to have an understanding of their management. Below, we will review the diagnosis, pathology, and treatment of the most common ocular surface tumors.

Conjunctival Melanoma

Epidemiology and Risk Factors

Conjunctival melanomas (CM) comprise approximately 2% of all ocular surface malignancies and 0.25% of all melanomas.[1] Non-Hispanic Caucasians are most commonly affected, with an incidence of 0.2-0.8 per million. Non-whites are rarely affected.[2] Studies have failed to show consistent predilection for sex.[3] The median age of presentation is approximately 60 years.[4] Risk factors have been difficult to ascertain due to the low incidence of disease. However, studies have reported risk for those with fair skin and hair, a family history, certain genetic syndromes (familial melanoma syndromes, xeroderma pigmentosum), and significant ultraviolet (UV) light exposure.[5-7]

The Surveillance, Epidemiology, and End Results (SEER) study reported an increased incidence of conjunctival melanoma in white males. The mechanism is hypothesized to be secondary to increased UV light exposure.[8] There is also a strong association between primary acquired melanosis (PAM) and conjunctival nevi with CM.[4,9] In particular, PAM with severe atypia transforms into CM in 13% of cases, with greater risk associated with more extensive circumferential spread of PAM.[9] PAM without atypia or with mild atypia does not demonstrate a predisposition for

progression to melanoma.[9] Conjunctival melanomas arise from three sources: PAM, de novo, and nevus; with PAM being most common and nevus being least common.[4]

Clinical Features

CM commonly presents as a raised, thick, pigmented lesion with surrounding feeder vessels. However, amelanotic lesions occur in approximately 15-20% of cases.[10] CM is typically unilateral and can occur at almost any anatomical location within the conjunctiva, with the most common location being on the bulbar conjunctiva (Figures 1 and 2).[10] Less commonly, CM occurs on the palpebral and forniceal conjunctiva, the plica semilunaris, caruncle, or cornea, with these locations portending a poorer prognosis.[10] Deep extension into the cornea is limited by Bowman's membrane, which acts as a barrier, though it can extend across the corneal epithelium (Figure 3).[1] CM has a propensity to metastasize, most commonly to the preauricular or anterior cervical lymph nodes.

Differential Diagnosis

Melanocytic tumors of the conjunctiva and cornea include benign conjunctival nevi, primary acquired melanosis (PAM), as well as the less common, but more dangerous, invasive melanoma. Therefore, an important task is differentiating CM from PAM and conjunctival nevi.

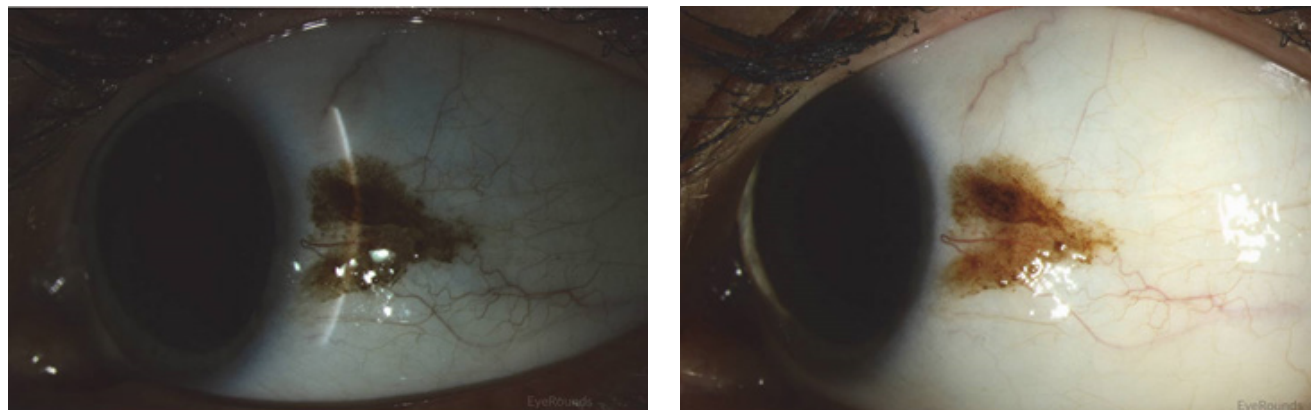


Figure 1: Conjunctival melanoma. Slit lamp photograph demonstrating a slightly elevated pigmented lesion with small feeder vessels. Clinically, there was recent growth noted, initiating biopsy and subsequent diagnosis of conjunctival melanoma

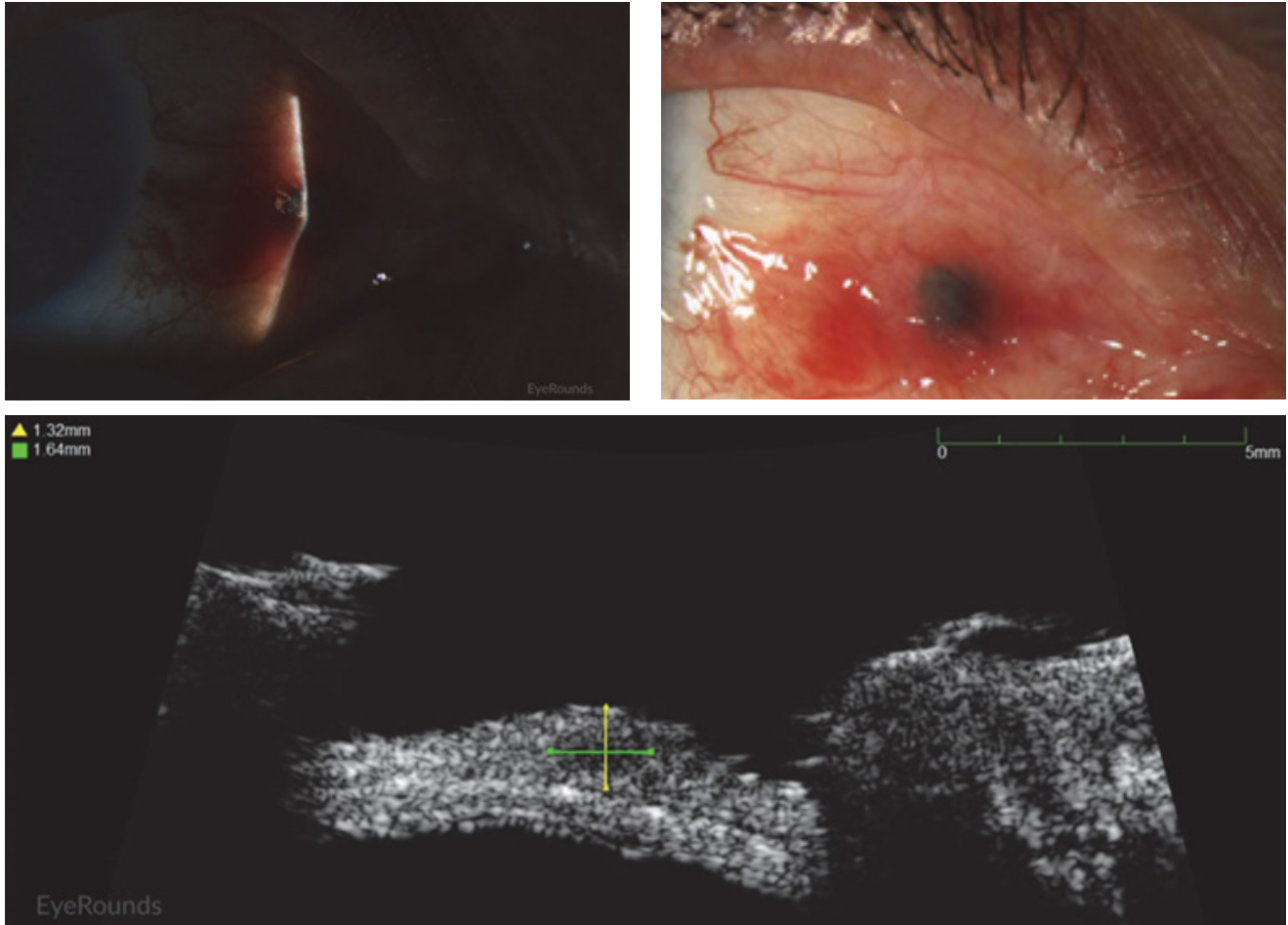


Figure 2: Conjunctival melanoma recurrence. Slit lamp photograph demonstrating recurrence of amelanotic melanoma with underlying scleral degeneration (upper images). High-frequency anterior segment ultrasound displaying elevation of conjunctival lesion without extension into sclera (bottom image).

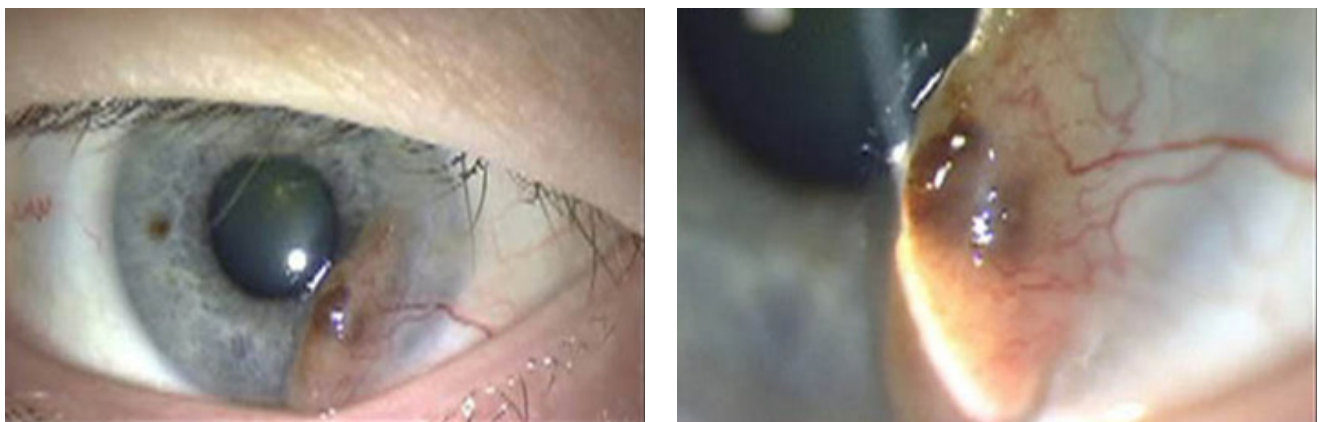


Figure 3: Conjunctival melanoma after resection. Slit lamp photo demonstrating the recurrence of a large raised, pigmented lesion extending onto the cornea with a prominent feeder vessel. see <http://eyerounds.org/cases/case15.htm>

Primary Acquired Melanosis (PAM)

PAM is a common entity, with one study of Caucasians displaying PAM in one-third of patients.[11] PAM typically presents as a unilateral, pigmented, flat, non-cystic lesion on the conjunctiva, often with pigment stippling extending beyond the main concentration of pigmentation (Figure 4). PAM involves the conjunctiva, unlike scleral pigmentation that occurs in ocular melanocytosis. Therefore, the overlying pigmented conjunctiva can be moved with a cotton tip over the underlying sclera.

While no consensus has been established for clinical characteristics that distinguish between benign PAM from premalignant PAM or malignant melanoma, suspicion should be high for lesions that display the following characteristics: extension of pigmentation greater than 3 clock hours of conjunctiva, large, raised, thickened, darkly melanotic, multifocal, or rapidly progressive lesions. In addition, lesions in unusual locations such as the fornix, semilunar fold, caruncle, or palpebral conjunctiva should be viewed with suspicion for malignant potential (Table 1). Importantly, an extension of pigmentation >3 clock hours portends a 20% risk of malignant transformation. Each clock hour increases relative risk of transformation to melanoma by 1.7 times.[9]

Conjunctival Nevi

Conjunctival nevi typically present as unilateral, pigmented, and oftentimes cystic lesions (figure 5). These lesions are typically located on the limbal or perilimbal conjunctiva in the interpalpebral fissure. An important distinguishing factor from invasive melanoma is the lack of prominent feeder vessels and presence of cysts. It is believed that some conjunctival nevi may rarely undergo malignant transformation.[12]

Pathology

Malignant conjunctival melanoma is composed of invasive anaplastic melanocytes, which invade the underlying basement membrane of the substantia propria (Figure 6). [14] Invasion may be noted within the vessels, lymphatics, sclera, or cornea. It is important to evaluate deep and peripheral margins for tumor invasion, which requires careful tissue handling at the time of biopsy. Adjacent areas of PAM with atypia or nevi can be noted.

Primary acquired melanosis (PAM) is identified as abnormal, prominent intraepithelial melanocytes secondary to increased melanin and/or hyperplasia of melanocytes within the conjunctiva. Further classification is based upon presence and growth pattern of melanocytic hyperplasia, as well as the presence of atypical melanocytes. PAM without atypia is characterized by minimal melanocytic hyperplasia with minimal atypia of melanocytes. PAM with atypia is characterized by nests of atypical melanocytes and melanocytic hyperplasia. Atypia of melanocytes is defined by abnormally large cells, high nuclear to cytoplasmic ratio, and prominent nucleoli with mitotic figures (Figure 7).

Table 1. PAM Risk Factors

Higher Risk	Lower Risk
>3 clock hours involvement of conjunctiva	Small, circumscribed without extensive involvement of conjunctiva
Extension onto cornea	Confinement to the conjunctiva
Nodular	Flat
Multifocal	One lesion
Highly vascular	Minimal vasculature
History of skin or conjunctival melanoma	No history of skin or conjunctival melanoma
Older age	Young age

The typical **melanocytic conjunctival nevus** displays conjunctival architecture composed of nests of benign melanocytes within the superficial substantia propria and epithelium. [13] Inclusion cysts are frequently noted in the conjunctiva (Figure 8 and 9). Nevi tend to migrate deeper as patients age.

While clinical characteristics may suggest a lesion is PAM or conjunctival nevi, any concern or uncertainty in diagnosis should be confirmed by biopsy.

Treatment

The surgical management of any suspicious pigmented conjunctival lesion is a complete excisional biopsy of the lesion with cryotherapy to the surrounding conjunctiva. At the University of Iowa, our preferred practice pattern is excisional biopsy with 4-5 mm of clear margins using a no-touch technique (topical absolute alcohol before and, if possible, after excision as long as not located over a muscle) with adjuvant cryotherapy, double freeze-thaw, and ocular surface reconstruction with amniotic membrane grafting. [15] Adjuvant post-excisional therapies include topical and/or subconjunctival injection of interferon alpha-2b, topical mitomycin C, brachytherapy, or external beam radiotherapy and proton beam radiotherapy, which are typically reserved for recurrent cases. No consensus exists regarding the best adjuvant treatment. Rarely, enucleation is indicated due to intraocular invasion or exenteration is indicated due to unresectable orbital invasion though there is no survival benefit. [16]

Video 1. Conjunctival Melanoma: "No Touch" Excisional Biopsy. See: youtu.be/ESETk1I5kfw

Video 2. Conjunctival Melanoma - Excisional Biopsy with Lamellar Sclerokeratectomy. See: youtu.be/znvJSwa9If0

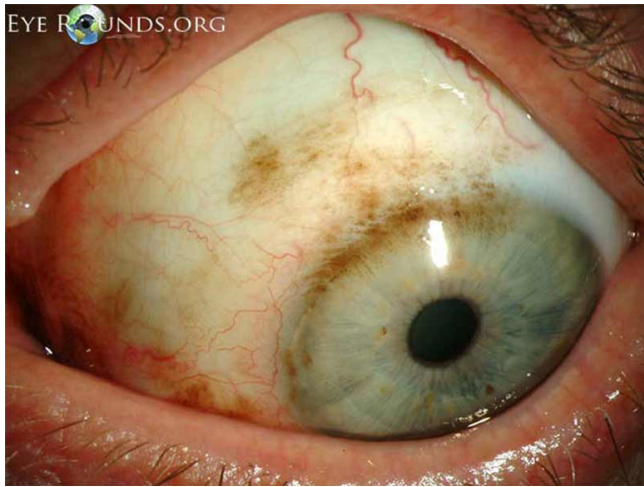


Figure 4: Primary acquired melanosis.
 Slit lamp photo displaying flat, non-cystic PAM that covers 2.5-3 clock hours of conjunctiva.
 (see: eyerounds.org/atlas/pages/primary-acquired-.htm)

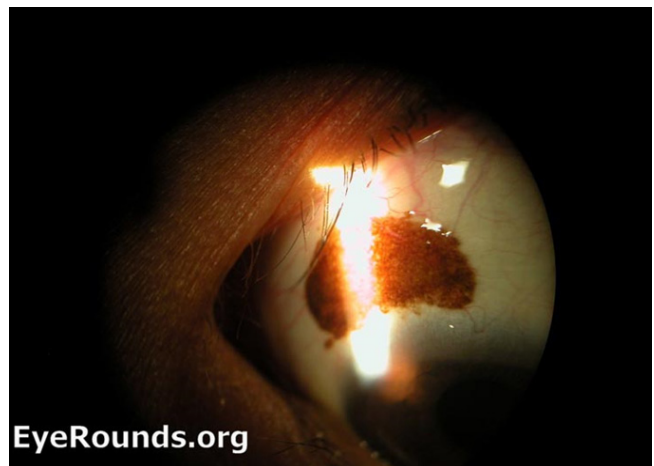

Figure 5: Conjunctival nevus . Slit lamp photograph displaying a well circumscribed, slightly elevated lesion. Note the small cysts medially.
 (see: eyerounds.org/atlas/pages/Pigmented-Conjunctival-Nevus.html)

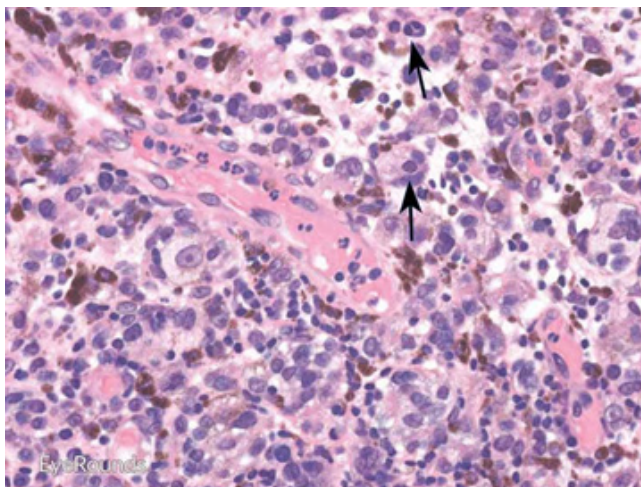
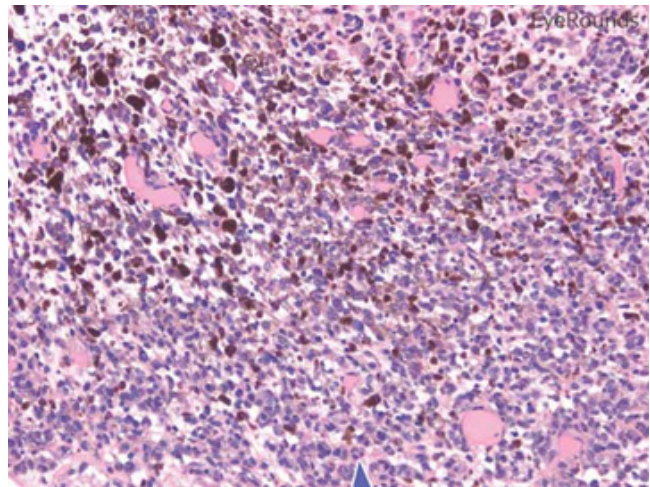
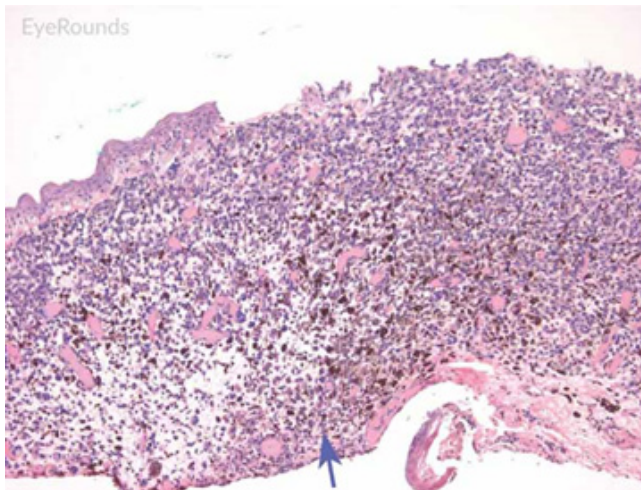


Figure 6: Invasive conjunctival melanoma.
 Hematoxylin and eosin stain displaying malignant melanoma invading the underlying substantia propria (blue arrow). Cytologically, the cells are notable for dysplastic features and prominent nucleoli with irregular shape and chromatin (black arrow).

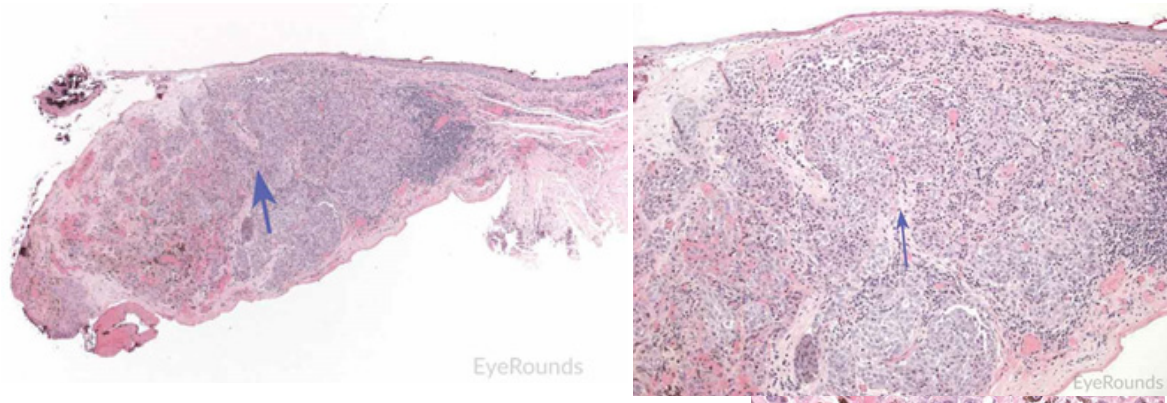


Figure 7: Primary acquired melanosis with severe atypia. Hematoxylin and eosin stain displaying PAM. The cells are characterized by abnormal melanocytes at the basal layer. Note abnormal melanocytes with dysplastic appearing nuclei (black arrow) and full thickness infiltration (blue arrow) of melanocytic cells.

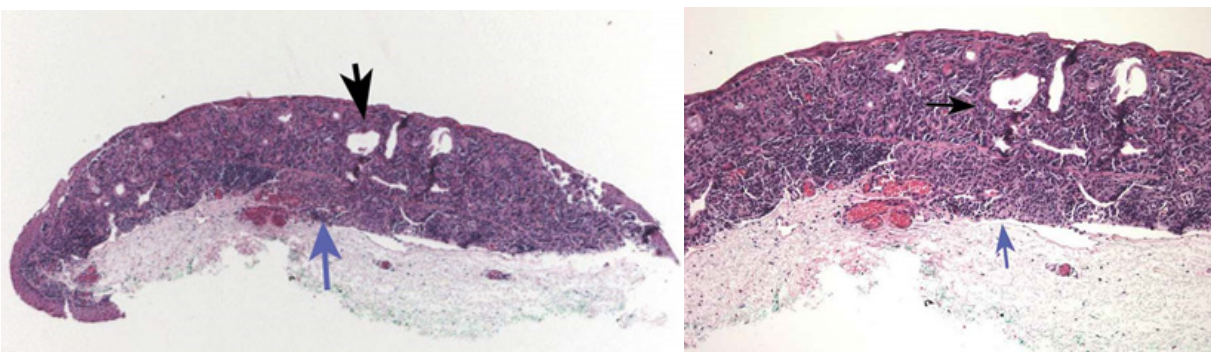


Figure 8: Junctional conjunctival nevus. Hematoxylin and eosin stain displaying conjunctival nevus from young patient at the border of the basal epithelial layer and underlying substantia propria (blue arrow). Note the cysts within the lesion (black arrow).

Follow-up and Prognosis

Currently, there are no guidelines for systemic evaluation for metastases, with different institutions following local practice patterns. In general, positron emission tomography/computed tomography (PET/CT) scans, chest x-ray, liver ultrasound and liver function tests (LFTs) can be performed. Sentinel lymph node biopsies may be performed for tumors greater than 2 mm in thickness or in cases in which there is a higher degree of suspicion for metastasis such as recurrent biopsy-proven melanoma. [17]

Ocular surface melanoma related mortality rates at 10 years are 25-30%. [4] The most common locations for metastases are the lungs, brain, liver, skin, and bones. [17] Local recurrence occurs in up to 40% of cases, with risk factors including: thickness of primary tumor (greater than 2 mm), incomplete excision at the time of surgery, non-limbal tumor location (fornix, semilunar fold, caruncle,

or tarsal conjunctiva), and older patient age. [6] Tumors at the caruncle portend the worst prognosis, with up to 50% mortality at 3 years (Table 2).

Table 2. Prognostic Indicators for Conjunctival Melanoma

Higher Risk	Lower Risk
Tarsus, caruncle, forniceal involvement	Localized
Deeper extension into tissue	Limbal or bulbar
Thickness >1.8 mm	Thin
Lymphadenopathy	
Lid margin involvement	

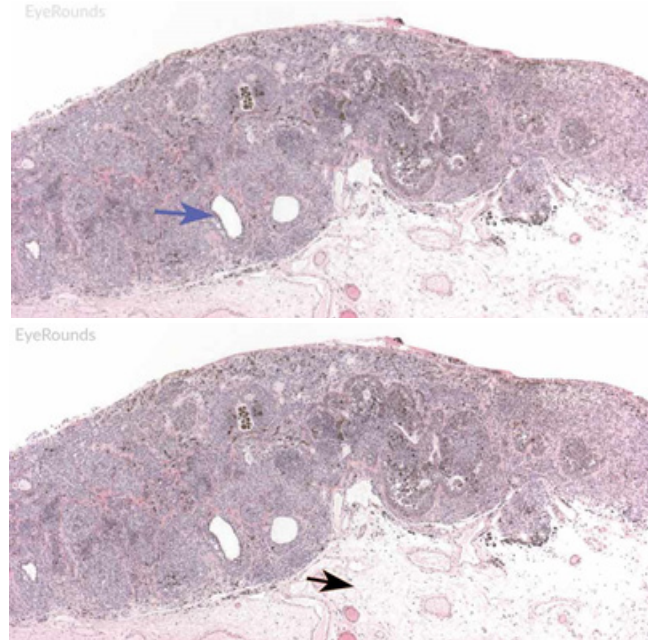
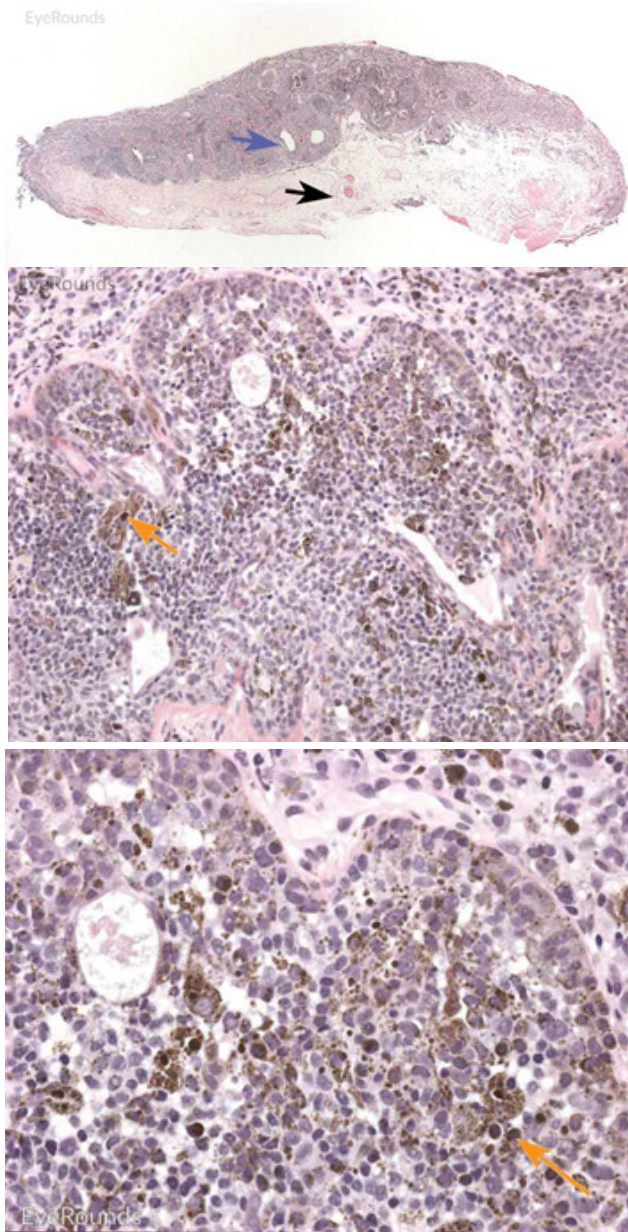


Figure 9: Conjunctival nevus. Hematoxylin and eosin stain displaying conjunctival nevus. Note the diffuse infiltration of melanocytes without atypia or dysplastic features (orange arrows). Note the cysts within the lesion (blue arrow) and intact substantia propria (black arrow).

Ocular Surface Squamous Neoplasia

Epidemiology and Risk Factors

Ocular surface squamous neoplasia (OSSN) is the most common type of primary ocular surface neoplasm. It consists of a broad range of pathologic squamous cell dysplasia including: conjunctival and corneal intraepithelial neoplasia (CIN), with mild, moderate, and severe atypia, carcinoma in situ, and invasive squamous cell carcinoma (SCC). [18] OSSN is rare, with incidence of 0.02-3.5 per 100,000, and most commonly affects older adults. There is greater incidence near the equator. [19] Risk factors include male gender, advanced age, exposure to tobacco smoke, ultraviolet B light, chemical exposure, human papillomavirus (HPV) infection types 16 and 18, and immunosuppression including human immunodeficiency virus (HIV). [20]

Clinical Features

OSSN clinical manifestations occurs on a spectrum. Most lesions are pathologically benign, such as papillomas or actinic keratosis. However, other lesions are more nefarious, such as carcinoma in situ and invasive squamous cell carcinoma.

OSSN appears on slit lamp biomicroscopy as a poorly defined gelatinous lesion, usually blending with surrounding conjunctiva. There is typically an abrupt transition from normal to dysplastic epithelium. [22] Conjunctival carcinoma in situ appears as a papillary mass, usually near the limbus, with minimal leukoplakia (Figure 10). Invasive squamous cell carcinoma, representing the final stage of malignancy (occurring in less than 2% of cases), manifests as a raised, poorly defined, gelatinous lesion with or without leukoplakia. Feeder vessels often supply invasive

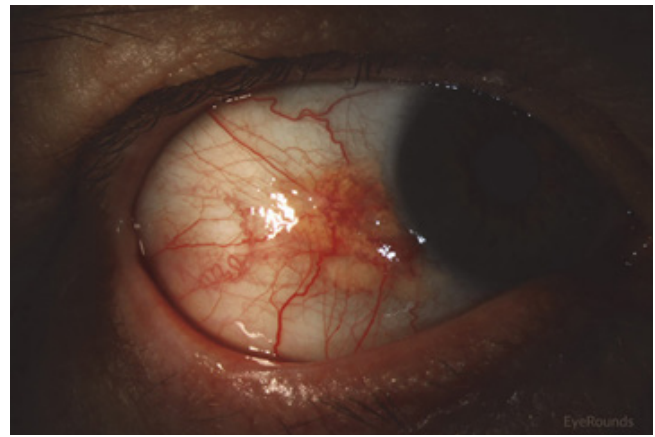
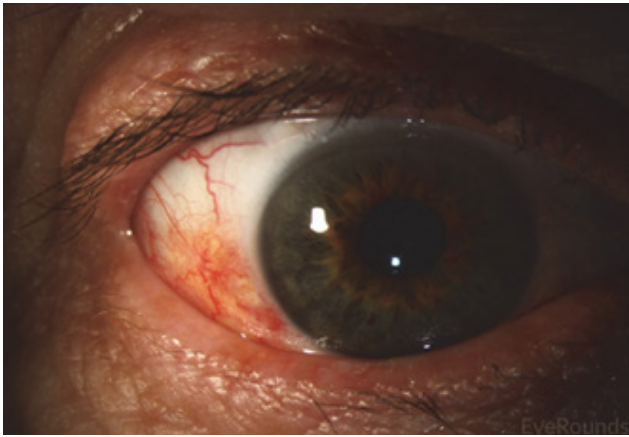


Figure 10: Conjunctival squamous cell carcinoma in situ. Slit lamp photograph displaying patchy, limbal-based gelatinous mass. Vascular engorgement is noted. This is an example of carcinoma in situ.

masses, and as the lesion becomes more advanced, there is decreasing mobility of the tumor due to the conjunctiva becoming fixed to the deeper sclera. It should be noted that carcinoma in situ and invasive squamous cell carcinoma can be very difficult to differentiate at the slit lamp. Thus, biopsy is very helpful in making the diagnosis.

Pathology

The gold standard for diagnosis is histopathological evaluation following biopsy. Carcinoma in situ is characterized by full-thickness replacement of the epithelium with anaplastic cells; however, the basement membrane remains intact and the underlying substantia propria is not affected. Histology displays a mixture of spindle and epidermoid cells, with disorganization of cells, increased nuclear to cytoplasm ratio, and abnormal polarity. There is generally a characteristic demarcation between diseased epithelium and adjacent normal tissue (Figure 11). [24] Invasive squamous cell carcinoma is characterized by severely anaplastic cells with penetration of the basement membrane and extension into the underlying stromal tissue (Figure 12). As

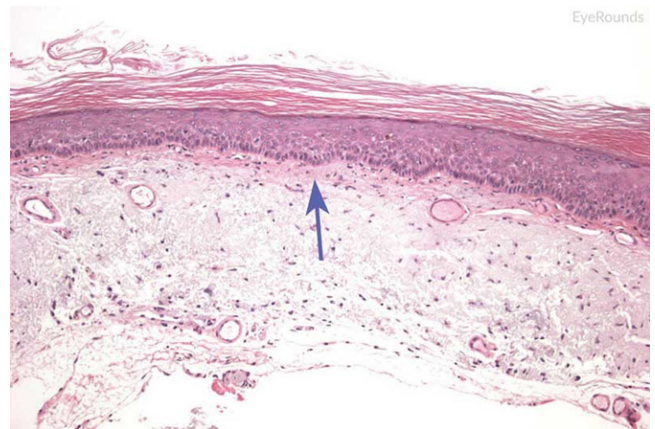


Figure 11: Carcinoma in situ. Hematoxylin and eosin stain displaying full thickness dysplastic changes, without extension below basal epithelial layer (blue arrow).

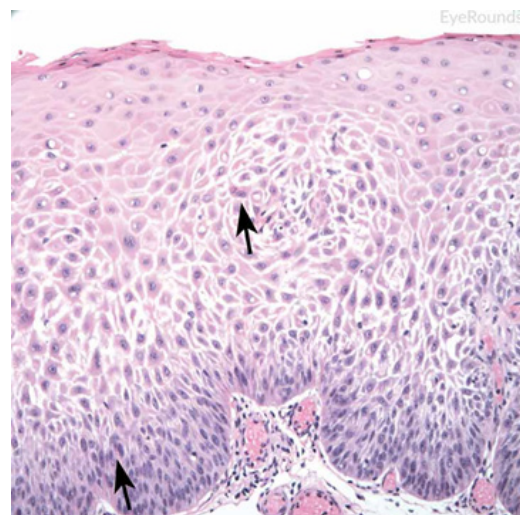
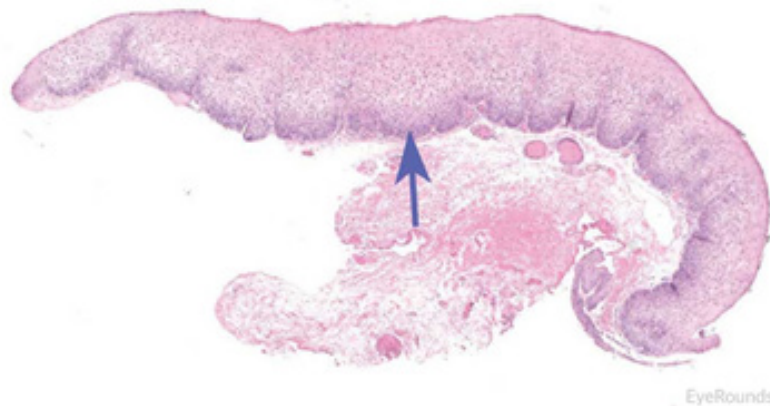


Figure 12: Invasive conjunctival squamous cell carcinoma. Hematoxylin and eosin stain displaying full thickness squamous cell carcinoma (blue arrow) with breakthrough of basement membrane. Image on right displays acanthosis, dyskeratosis, and bizarre cells (black arrow).

the tumor invades, it can appear as cords of invasive cells or as broad, expansive fronds. [24] Spindle cell carcinoma and mucoepidermoid cell carcinoma are variants representing more invasive tumors.

Treatment

Adequate treatment of squamous cell neoplasms depends upon the clinical characteristics of the lesions. Factors such as size, location, and invasiveness of the tumor influence the appropriate treatment of neoplasms. For discrete masses, complete excision with adequate margins is the treatment of choice, often aided by alcohol epitheliectomy. It is important to ensure adequate margins, which may include up to 3-4 mm of uninvolved conjunctiva. Most surgeons will apply double freeze thaw cryotherapy to the adjacent bulbar conjunctiva in order to provide better local control. Additionally, amniotic membrane grafts can be used to close a resection site. Other adjunctive therapies include interferon α 2b, mitomycin C, and 5-fluorouracil. No consensus exists for use of these therapies. [25] Interferon α 2b is commonly used due to its lower risk profile. Enucleation or exenteration may be required with invasive squamous cell carcinoma. Enucleation is necessary in cases of invasion through the cornea or sclera without orbital or regional spread. Exenteration is necessary when tumor has invaded the orbit. [26]

Video 3. Conjunctival Excisional Biopsy for Ocular Surface Squamous Neoplasia.

See: vimeo.com/169300308

Follow up and Prognosis

Outcomes for squamous cell tumors are related to the degree of aggressiveness of the tumors. For carcinoma in situ, patients with completely excised tumors have great outcomes, with risk of local recurrence around 2% and regional lymph node metastasis at around 1%. [27] If there is a recurrence, more aggressive resection as well as use of adjunctive therapies may be required. In cases of invasive squamous cell carcinoma with complete resection the rate of local recurrence is 5%, with approximately 2% displaying regional lymph node metastases. [28]

Lymphoid Tumors

Epidemiology and Risk Factors

Lymphoid tumors of the conjunctiva can present on a spectrum from benign to malignant disease. Benign tumors are reactive lymphoid hyperplasia, intermediate lesions present as atypical lymphoid hyperplasia, and malignant tumors are lymphomas. Lymphoid tumors of the conjunctiva are very rare, and the exact incidence is unknown. In a large series of conjunctival tumors, Shields et al. noted 128 lymphoid lesions out of 1634 total tumors. [29] Malignant lymphomas tend to occur in older adults, while benign lymphoid tumors tend to occur in younger patients. Known risk factors for malignancy include older age, history of systemic lymphoma, and immunosuppression. [30]

Clinical Presentation

Conjunctival lymphoid tumors appear as salmon colored, smooth, elevated lesions of the bulbar or forniceal conjunctiva (Figures 13 & 14). There is a predisposition for the inferior fornix. [31] Nasal lesions have poor outcomes due to potentially deeper extension into surrounding tissue. Bilateral involvement is present in up to 20% of all patients, although the lesions tend to be asymmetric. Importantly, systemic lymphoma develops in 17% of patients with unilateral lesions and in 47% of patients with bilateral disease. [31] It is difficult to differentiate benign reactive lymphoid hyperplasia from malignant lymphoma on slit lamp exam. Thus, excisional biopsy is required for diagnosis.

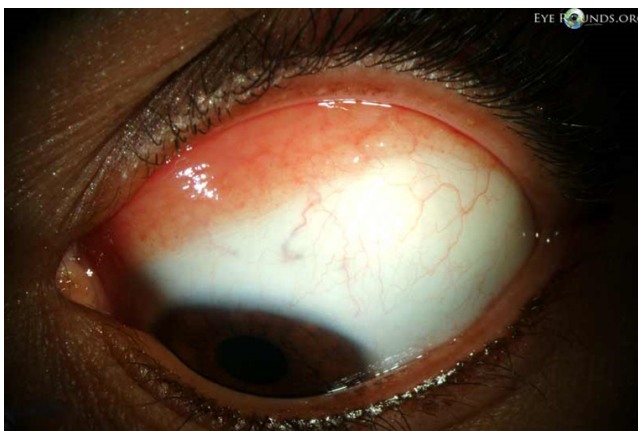

Figure 13: Conjunctival benign lymphoid hyperplasia. Slit lamp photo displaying superior conjunctival lesion with characteristic salmon patch appearance.

Pathology

It is important to obtain immunofluorescence testing and fresh samples for appropriate pathological diagnosis. Benign reactive lymphoid hyperplasia is characterized by polymorphic, well-differentiated lymphocytes and possibly plasma cells. These cells tend to have well-developed germinal centers. Lymphomas are monomorphic, without germinal centers. Flow cytometry is helpful in determining whether cells are monoclonal or polyclonal, whether cells are B or T cells, and if DNA abnormalities are present. The majority of conjunctival lymphomas are B cell lymphomas (68-81%). [32,33]

Treatment

Treatment of lymphoid tumors depends upon the underlying diagnosis. In a patient with a suspected lymphoid tumor, a complete medical workup for systemic lymphoma is warranted. Included in the initial investigation is a history and physical, complete blood count with differential, and magnetic resonance imaging (MRI) of brain and orbits, as well as PET scan to identify a systemic lymphoma. In addition to a comprehensive evaluation, excisional biopsy should be completed to identify the underlying pathology. In the case of benign reactive lymphoid hyperplasia, treatment can be observation or topical steroids for a few weeks. In the case of low-grade lymphoid neoplasm, low-

dose external beam radiation therapy is recommended. In the case of high-grade lymphoma, higher dose external beam radiation is recommended (usually 40-45Gy). [34] Generally, lymphomas respond well to radiation. If systemic lymphoma is discovered on workup, then treatment consists of chemotherapy with or without radiation. [30]

Follow up and Prognosis

Patients with benign reactive lymphoid hyperplasia have a very good prognosis, and lesions generally resolve with

excision, steroids, or observation. Most localized lymphomas respond well to excision and radiation. In patients with systemic lymphoma, chemotherapy is often indicated for treatment, with rituximab as the treatment of choice. A recent study reported that the 10-year progression free survival in bilateral disease is 48% compared to 72% survival rate in those with unilateral disease. [35] Due to risk of recurrence, patients with lymphoma should be followed indefinitely, with follow up every 3 months for the first year, and every 6-12 months thereafter. [36]

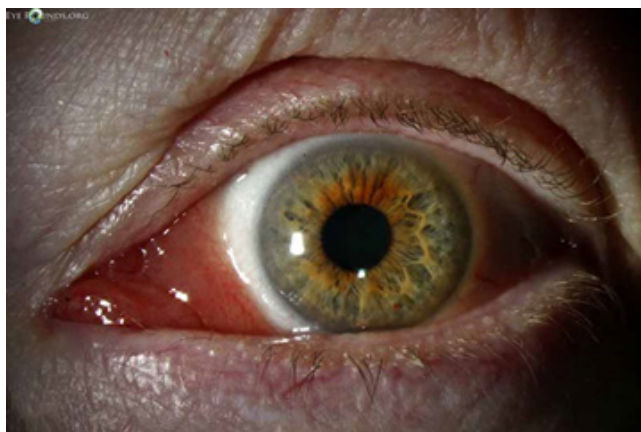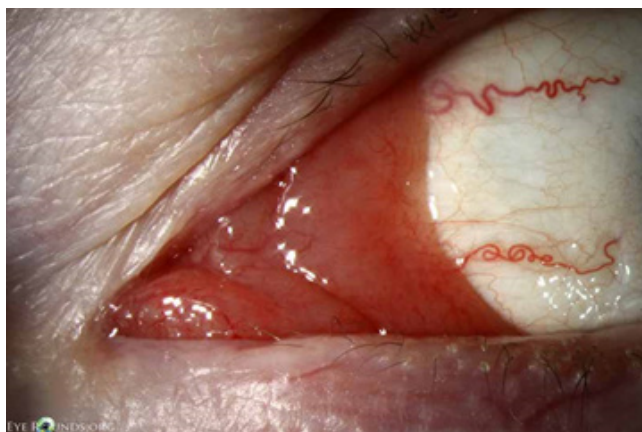


Figure 14: Conjunctival lymphoma.
Slit lamp photo displaying salmon patch lesion extending into the semilunaris and caruncle.

References

- Seregard S. Conjunctival melanoma. *Surv Ophthalmol* 1998;42(4):321-350. PubMed.gov/9493274
- Isager P, Osterlind A, Engholm G, Heegaard S, Lindegaard J, Overgaard J, Storm HH. Uveal and conjunctival malignant melanoma in Denmark, 1943-97: incidence and validation study. *Ophthalmic Epidemiol* 2005;12(4):223-232. PubMed.gov/16033743 DOI: 10.1080/09286580591000836
- McLaughlin CC, Wu XC, Jemal A, Martin HJ, Roche LM, Chen VW. Incidence of noncutaneous melanomas in the U.S. *Cancer* 2005;103(5):1000-1007. PubMed.gov/15651058 . DOI: 10.1002/cncr.20866
- Shields CL, Shields JA, Gunduz K, Cater J, Mercado GV, Gross N, Lally B. Conjunctival melanoma: risk factors for recurrence, exenteration, metastasis, and death in 150 consecutive patients. *Arch Ophthalmol* 2000;118(11):1497-1507. PubMed.gov/11074806
- Gandini S, Sera F, Cattaruzza MS, Pasquini P, Zanetti R, Masini C, Boyle P, Melchi CF. Meta-analysis of risk factors for cutaneous melanoma: III. Family history, actinic damage and phenotypic factors. *Eur J Cancer* 2005;41(14):2040-2059. PubMed.gov/16125929 . DOI: 10.1016/j.ejca.2005.03.034
- Wong JR, Nanji AA, Galor A, Karp CL. Management of conjunctival malignant melanoma: a review and update. *Expert Rev Ophthalmol* 2014;9(3):185-204. PubMed.gov/25580155 . DOI: 10.1586/17469899.2014.921119
- Hurst EA, Harbour JW, Cornelius LA. Ocular melanoma: a review and the relationship to cutaneous melanoma. *Arch Dermatol* 2003;139(8):1067-1073. PubMed.gov/12925397 . DOI: 10.1001/archderm.139.8.1067
- Yu GP, Hu DN, McCormick S, Finger PT. Conjunctival melanoma: is it increasing in the United States? *Am J Ophthalmol* 2003;135(6):800-806. PubMed.gov/12788119
- Shields JA, Shields CL, Mashayekhi A, Marr BP, Benavides R, Thangappan A, Phan L, Eagle RC, Jr. Primary acquired melanosis of the conjunctiva: experience with 311 eyes. *Trans Am Ophthalmol Soc* 2007;105:61-71; discussion 71-62. PubMed.gov/18427595
- Shields CL, Markowitz JS, Belinsky I, Schwartzstein H, George NS, Lally SE, Mashayekhi A, Shields JA. Conjunctival melanoma: outcomes based on tumor origin in 382 consecutive cases. *Ophthalmology* 2011;118(2):389-395 e381-382. PubMed.gov/20723990 . DOI: 10.1016/j.ophtha.2010.06.021
- Gloor P, Alexandrakis G. Clinical characterization of primary acquired melanosis. *Invest Ophthalmol Vis*

- Sci 1995;36(8):1721-1729.
 iovs.arvojournals.org/article.aspx?articleid=2161849
12. Gerner N, Norregaard JC, Jensen OA, Prause JU. Conjunctival naevi in Denmark 1960-1980. A 21-year follow-up study. *Acta Ophthalmol Scand* 1996;74(4):334-337. PubMed.gov/8883545
 13. Folberg R, Jakobiec FA, Bernardino VB, Iwamoto T. Benign conjunctival melanocytic lesions. Clinicopathologic features. *Ophthalmology* 1989;96(4):436-461. PubMed.gov/2657539
 14. Jakobiec FA, Folberg R, Iwamoto T. Clinicopathologic characteristics of premalignant and malignant melanocytic lesions of the conjunctiva. *Ophthalmology* 1989;96(2):147-166. PubMed.gov/2649838
 15. Shields JA, Shields CL, De Potter P. Surgical management of circumscribed conjunctival melanomas. *Ophthalm Plast Reconstr Surg* 1998;14(3):208-215. PubMed.gov/9612814
 16. Rodriguez-Reyes AA, Rios y Valles-Valles D, Corredor-Casas S, Gomez-Leal A. Advanced conjunctival melanoma. *Can J Ophthalmol* 2004;39(4):453-460. PubMed.gov/15327112
 17. Esmaeli B. Regional lymph node assessment for conjunctival melanoma: sentinel lymph node biopsy and positron emission tomography. *Br J Ophthalmol* 2008;92(4):443-445. PubMed.gov/18369054 . DOI: 10.1136/bjo.2007.131615
 18. Lee GA, Hirst LW. Ocular surface squamous neoplasia. *Surv Ophthalmol* 1995;39(6):429-450. PubMed.gov/7660300
 19. Kiire CA, Dhillon B. The aetiology and associations of conjunctival intraepithelial neoplasia. *Br J Ophthalmol* 2006;90(1):109-113. PubMed.gov/16361679 . DOI: 10.1136/bjo.2005.077305
 20. Karcioglu ZA, Wagoner MD. Demographics, etiology, and behavior of conjunctival squamous cell carcinoma in the 21st century. *Ophthalmology* 2009;116(11):2045-2046. PubMed.gov/19883851 . DOI: 10.1016/j.ophtha.2009.09.031
 21. Sjo N, Heegaard S, Prause JU. Conjunctival papilloma. A histopathologically based retrospective study. *Acta Ophthalmol Scand* 2000;78(6):663-666. PubMed.gov/11167228
 22. Shields CL, Shields JA. Tumors of the conjunctiva and cornea. *Surv Ophthalmol* 2004;49(1):3-24. PubMed.gov/14711437
 23. Tunc M, Char DH, Crawford B, Miller T. Intraepithelial and invasive squamous cell carcinoma of the conjunctiva: analysis of 60 cases. *Br J Ophthalmol* 1999;83(1):98-103. PubMed.gov/10209445
 24. Mittal R, Rath S, Vemuganti GK. Ocular surface squamous neoplasia - Review of etio-pathogenesis and an update on clinico-pathological diagnosis. *Saudi J Ophthalmol* 2013;27(3):177-186. PubMed.gov/24227983 . DOI: 10.1016/j.sjopt.2013.07.002
 25. Sayed-Ahmed IO, Palioura S, Galor A, Karp CL. Diagnosis and Medical Management of Ocular Surface Squamous Neoplasia. *Expert Rev Ophthalmol* 2017;12(1):11-19. PubMed.gov/28184236 . DOI: 10.1080/17469899.2017.1263567
 26. Shields CL, Chien JL, Surakiatchanukul T, Sioufi K, Lally SE, Shields JA. Conjunctival Tumors: Review of Clinical Features, Risks, Biomarkers, and Outcomes--The 2017 J. Donald M. Gass Lecture. *Asia Pac J Ophthalmol (Phila)* 2017;6(2):109-120. PubMed.gov/28399347 . DOI: 10.22608/APO.201710
 27. Honavar SG, Manjandavida FP. Tumors of the ocular surface: A review. *Indian J Ophthalmol* 2015;63(3):187-203. PubMed.gov/25971163 . DOI: 10.4103/0301-4738.156912
 28. Tabin G, Levin S, Snibson G, Loughnan M, Taylor H. Late recurrences and the necessity for long-term follow-up in corneal and conjunctival intraepithelial neoplasia. *Ophthalmology* 1997;104(3):485-492. PubMed.gov/9082277
 29. Shields CL, Demirci H, Karatza E, Shields JA. Clinical survey of 1643 melanocytic and nonmelanocytic conjunctival tumors. *Ophthalmology* 2004;111(9):1747-1754. PubMed.gov/15350332 . DOI: 10.1016/j.ophtha.2004.02.013
 30. Tsai PS, Colby KA. Treatment of conjunctival lymphomas. *Semin Ophthalmol* 2005;20(4):239-246. PubMed.gov/16352495 . DOI: 10.1080/08820530500350845
 31. Shields CL, Shields JA, Carvalho C, Rundle P, Smith AF. Conjunctival lymphoid tumors: clinical analysis of 117 cases and relationship to systemic lymphoma. *Ophthalmology* 2001;108(5):979-984. PubMed.gov/11320031
 32. Coupland SE, Krause L, Delecluse HJ, Anagnostopoulos I, Foss HD, Hummel M, Bornfeld N, Lee WR, Stein H. Lymphoproliferative lesions of the ocular adnexa. Analysis of 112 cases. *Ophthalmology* 1998;105(8):1430-1441. PubMed.gov/9709754 . DOI: 10.1016/S0161-6420(98)98024-1

33. Knowles DM, Jakobiec FA, McNally L, Burke JS. Lymphoid hyperplasia and malignant lymphoma occurring in the ocular adnexa (orbit, conjunctiva, and eyelids): a prospective multiparametric analysis of 108 cases during 1977 to 1987. *Hum Pathol* 1990;21(9):959-973. PubMed.gov/2394438
34. Uno T, Isobe K, Shikama N, Nishikawa A, Oguchi M, Ueno N, Itami J, Ohnishi H, Mikata A, Ito H. Radiotherapy for extranodal, marginal zone, B-cell lymphoma of mucosa-associated lymphoid tissue originating in the ocular adnexa: a multiinstitutional, retrospective review of 50 patients. *Cancer* 2003;98(4):865-871. PubMed.gov/12910532 . DOI: 10.1002/cncr.11539
35. Kirkegaard MM, Rasmussen PK, Coupland SE, Esmaeli B, Finger PT, Graue GF, Grossniklaus HE, Honavar SG, Khong JJ, McKelvie PA, Mulay K, Prause JU, Ralfkiaer E, Sjo LD, Toft PB, Vemuganti GK, Thuro BA, Curtin J, Heegaard S. Conjunctival Lymphoma--An International Multicenter Retrospective Study. *JAMA Ophthalmol* 2016;134(4):406-414. PubMed.gov/26891973 . DOI: 10.1001/jamaophthalmol.2015.6122
36. Tanimoto K, Kaneko A, Suzuki S, Sekiguchi N, Maruyama D, Kim SW, Watanabe T, Kobayashi Y, Kagami Y, Maeshima A, Matsuno Y, Tobinai K. Long-term follow-up results of no initial therapy for ocular adnexal MALT lymphoma. *Ann Oncol* 2006;17(1):135-140. PubMed.gov/16236754 . DOI: 10.1093/annonc/mdj025
37. Rath S, Connors JM, Dolman PJ, Rootman J, Rootman DB, White VA. Comparison of American Joint Committee on Cancer TNM-based staging system (7th edition) and Ann Arbor classification for predicting outcome in ocular adnexal lymphoma. *Orbit* 2014;33(1):23-28. PubMed.gov/24180616. DOI: 10.3109/01676830.2013.842257

Citing this article

Benage M, Fox AR, Boyce MR, Greiner MA, with Syed NA. Ocular Surface Tumors. EyeRounds.org. posted December 20, 2017; Available from: EyeRounds.org/tutorials/Ocular-Surface-Tumors/

Tutorials

Cataract

Patient Communication during Cataract Surgery

An EyeRounds Tutorial

Jason P. Brinton, MD and Thomas A. Oetting, MD

July 28, 2011

Introduction

Cataract extraction is the most common surgical procedure in the United States today with over 3 million cases performed annually. Patient expectations for cataract surgery have increased over the past several decades as surgeons have transitioned from standard extra-capsular techniques to a clear-cornea phaco-emulsification procedure. The surgery is quick and often under topical anesthesia. However, just because the surgery is faster now, doesn't mean that patients are not as anxious as ever about the procedure and what is going to happen to them. The purpose of this tutorial is to offer some suggestions to assist the surgeon with the intraoperative portion of patient communication.

Background

Various studies have looked at a number of factors relating to the quality of the patient's intraoperative experience, among them confidence, pain, understanding, satisfaction, memory, and reassurance.[Mokashi 2004] Three to 16.2% of patients who had cataract surgery with topical or retrobulbar anesthesia reported they were frightened by the visual experience of the procedure.[Tan 2005] Fear may lead a patient to become restless or uncooperative. The language and conduct of the operative team has been demonstrated to have a meaningful effect on these parameters. In one study, handholding by a nurse was shown to produce a significant decrease in patient epinephrine levels and in the number of patients reporting intraoperative anxiety.[Moon 2001] A second study showed that a hand massage five minutes before cataract surgery led to a decrease in patient levels of epinephrine, norepinephrine, cortisol, blood pressure, pulse, and reported anxiety.[Kim 2001] In a third study patients were allowed to use an electronic patient-controlled alert device that allowed them to level of anxiety related to their cataract extraction procedure.[Mokashi 2004] In addition to discussions that take place in the exam lane, some surgeons have sought to familiarize the patient with cataract surgery in advance of their procedure by allowing them to watch a surgery live. Some ambulatory surgery centers have an operating room setup that allows patients contemplating cataract surgery to watch live surgery through a window to the operating room or by video feed. Other surgeons may refer patients to websites such as www.eyerounds.org to familiarize them with process of undergoing cataract surgery.

What follows are some suggestions on how to communicate with patients while performing cataract surgery. For a video of informed consent for cataract surgery see the following link: cataractsurgeryforgreenhorns.blogspot.com/2009/01/consent-for-cataract-surgery.html

"Do I Have Cancer?"

Your patients are listening. They listen to the words we use and tone of our speech. They hear how you treat your staff and expect professionalism.

A patient experience from several years ago illustrates how a single word uttered in the operating room, taken out of context, can result in a significant misunderstanding. In this case Dr. Oetting was operating with one of the senior Iowa residents. Toward the end of the case the anterior chamber temporarily shallowed and for a moment the two surgeons discussed several conditions that could lead to this finding. Among those mentioned was "malignant glaucoma," also known as aqueous misdirection. The temporary shallowing ended up being inconsequential and the case was completed without incident.

When the patient returned for his postoperative month one visit he asked if he could speak with Dr. Oetting in private. The patient then queried, "when are you going to tell me about my cancer?" The patient had heard the adjective "malignant" in the operating room and spent the next four weeks believing that he had a cancer about which his surgeons had not informed him.

The words and tone of voice we choose in the operating room contribute to the patient's overall experience. When balanced with appropriate silence, they provide comfort to the patient, allow for a greater measure of involvement in their medical care, and promote safety.

Steps of Cataract Surgery with Suggestions on Patient Communication

Preoperative, day of surgery

What they may be thinking

- I will never keep this straight
- Why so many drops?
- What are these drops for?

What to say

- ◇ "We will give you a printed instruction sheet and the nurses will go all of the drops after the surgery."
- ◇ Topical anesthetic drops: this drop will numb the eye for your comfort but may sting for a few seconds.
- ◇ Antibiotic drops: this drop is to prevent infection.
- ◇ Steroid drops: this drop is for your comfort.
- ◇ Dilating drops: this drop is to open the pupil and expose the cataract and may blur your vision.

Retrobulbar anesthetic injection:

What they may be thinking

- I thought this was not going to hurt?
- Is that a needle?
- Why are we doing this?

What to say

- ◇ "Look straight up at the ceiling and try to keep both eyes open. This is the hardest part of the procedure but will make everything else pretty easy. You will feel a poke in your eyelid followed by pressure around your eye as the numbing medicine starts to work."

Surgical prep

What they may be thinking

- I can feel this on my skin I thought I was numb
- What is she doing now?

What to say

- ◇ "This cold solution helps clean the eye to prevent infection. You may feel this on your skin but don't worry your eye is numb."

Draping

What they may be thinking

- Will I be able to breath?
- What is she doing now?

What to say

- ◇ "These sheets are to keep the eye clean during surgery; it is really just a fancy paper towel so you can breath right through it. Plus you will have a lot of oxygen flowing from this nasal cannula. So really you will have more air than usual."

Microscope Light

What they may be thinking

- It is so bright!
- How long will this last?

What to say

- ◇ "At first the microscope light will be very bright and then you will get used to it. We will also give you some medicine to help make the light less bright."

Lid speculum placement

What they may be thinking

- Am I supposed to keep my eye open?
- What is she doing now?

What to say

- ◇ "This is a soft device that keeps your eye open so you don't have to worry about blinking" (consider avoiding the term speculum, especially in female patients who may have encountered this word in its ob-gyn context).

Incisions

What they may be thinking

- When will they really get started?
- Will it hurt?
- What is she doing now?

What to say

- ◇ "We are getting started now and everything is going great."

Intracameral lidocaine

What they may be thinking

- That hurts I thought I was numb!
- What is she doing now?

What to say

- ◇ "Here is the rest of the medicine to get you the rest of the way numb you may feel a sting while I put it in and then you will be all the way numb."

Viscoelastic

What they may be thinking

- The microscope light is bright!
- Then the light goes dim. Am I going blind?
- What is she doing now?

What to say

- ◇ "This medicine makes the light less bright."

Malyugin ring insertion

What they may be thinking

- I can feel some pressure, is this going to really hurt?
- What is she doing now?

What to say

- ◇ "You may feel some pressure inside your eye on this step don't worry it will just last a second."

Capsulorhexis

What they may be thinking

- How is the surgery going?
- What is she doing now?

What to say

- ◇ "The surgery is going great and this is a very delicate part and i would like you to hold very still for a minute or so."

Hydrodissection

What they may be thinking

- I can't follow the light any more, what do I do now?
- What is she doing now?

What to say

- ◇ "it may be hard to follow the light now so just try to look up at the ceiling."

Phacoemulsification

What they may be thinking

- What are those funny noises
- Are we making any progress yet?
- I feel fluid by my ear is that blood!?
- What is she doing now?

What to say

- ◇ "Now we are using the machine that removes the cataract you will hear some funny noises and voices. During this part we use a lot of water so don't worry if you feel some fluid."

Cortical removal

What they may be thinking:

- How much longer
- Something seems different, is everything OK?
- What is she doing now?

What to say

- ◇ "The main part of the cataract is out and we're 2/3 of the way done and are just removing some of the soft parts of the cataract."

Placement of intraocular lens implant

What they may be thinking:

- I can see some funny shapes
- I am feeling some pressure
- Am I going to see yellow forever now?
- What is she doing now?

What to say

- ◇ "This is the most interesting part as we are going to place the artificial lens. You may feel some pressure as we place the lens which will look like an amber crystal. Can you see it? It will give you very clear vision."

Removal of viscoelastic

What they may be thinking

- What is she doing now?

What to say

- ◇ "We are removing a protective jelly from around the lens implant and are almost done."

Wound Closure

What they may be thinking

- Wow that was fast!
- Why do I need a suture (if they did)?
- What is she doing now?

What to say

- ◇ "We're nearly done. I'm checking to see if your wound can seal itself. It looks like we need to place a suture to keep the eye secure. You may feel a little poking sensation as we place the suture to close the wound. Everything is going great."

End of the Case

What they may be thinking

- What do I do now?
- When do I see her again?
- Why is everything so blurry?

What to say

- ◇ "We are all done and your surgery went great. Your vision will be blurry for a few days as the drops wear off and the swelling goes away. We will see you in four to 5 hours and make sure your pressure is okay. Thank you for holding so still."

Some additional suggestions:

- Use "anticipatory reassurance." Consider what the patient may be wondering about as you talk to them.
- It is important to gauge how much information the patient wants to hear as you go along.
- Talk to patients you trust and ask them what the experience is like.
- If you have a problem let the patient know the case is going to take a little longer and briefly why.

References

Kim MS, Cho KS, Woo H, Kim JH. Effects of hand massage on anxiety in cataract surgery using local anesthesia. *J Cataract Refract Surg.* 2001;27(6):884-90.

Mokashi A, Leatherbarrow B, Kinsey J, Slater R, Hillier V, Mayer S. Patient communication during cataract surgery. *Eye (Lond).* 2004;18(2):147-51.

Moon JS, Cho KS. The effects of handholding on anxiety in cataract surgery patients under local anaesthesia. *J Adv Nurs.* 2001;35(3):407-15.

Tan CS, Au Eong KG, Kumar CM. Visual experiences during cataract surgery: what anaesthesia providers should know. *Eur J Anaesthesiol.* 2005;22(6):413-9.

Citing this article

Brinton JP, Oetting TA. Patient Communication during Cataract Surgery: An EyeRounds Tutorial. *Eyeroounds.org.* July 28, 2011; Available from: www.Eyeroounds.org/tutorials/Communication-Cataract-Surgery.htm

last updated: 07/28/2011

Ten Tips to Prevent and Treat Iris Prolapse

Steven M. Christiansen, MD and Thomas A. Oetting, MS, MD

May 3, 2017

See video at <https://vimeo.com/215781899>

From antiquity to today, managing iris prolapse has long been a challenge for cataract surgeons, with its occurrence leading to increased risk of endophthalmitis, epithelial ingrowth, symptomatic glare, and several other postoperative complications. This tutorial will propose ten tips to prevent and treat iris prolapse. An accompanying article will discuss the history of iris prolapse as well as several mechanical and fluid dynamics-based theories believed to contribute to iris prolapse.

1. **Create a "longer" wound**

Recall that one of the primary factors driving iris prolapse is the distance from the iris to the internal opening of the wound. If you are concerned about the potential for iris prolapse, consider making a slightly longer clear corneal wound.

2. **Avoid overfilling the anterior chamber with viscoelastic**

Beginning cataract surgeons often overfill with viscoelastic as it is easier to make the main wound in a firm eye, however this creates a larger pressure differential between the anterior and posterior chambers, and increases the risk of iris prolapse. In our experience, this seems to be an issue primarily with dispersive viscoelastic. A good rule of thumb is that if you are noticing considerable viscoelastic spilling out of the paracentesis, you may have overfilled the AC and should be weary of possible prolapse.

3. **Remove viscoelastic before hydrodissection**

Hydrodissection poses the greatest risk of prolapse, and taking measures to prophylactically lower the anterior chamber pressure by removing viscoelastic is critical in preventing prolapse.

4. **Create a fluid tract before hydrodissection**

Before hydrodissection, use Balanced Salt Solution (BSS) to create a fluid tract for fluid to exit the eye. This tract prevents the situation where the BSS cannot leave the eye without taking viscoelastic with it, which could result in a rapid decrease in anterior chamber pressure - a main risk factor for prolapse.

5. **Support the iris mechanically with iris hooks or ring**

Consider placing a single iris hook posterior to the main wound, or place several hooks in a diamond configuration with one of the hooks posterior to the main wound in a similar fashion. Alternatively, a Malyugin ring stabilizer can be used. Mechanically supporting the iris is particularly helpful if there is potential for intraoperative floppy iris syndrome.(1-3)

6. **STOP! Resist the urge to reposit prolapsed iris**

As soon as iris prolapse occurs, the knee-jerk reaction is to want to immediately push the iris back into the eye. It can be tough to overcome this urge, but realize that it is usually in repositing the prolapsed iris that pigment is permanently lost from the posterior iris. Also, manual reposition is rarely effective. Instead, the surgeon should immediately release trapped fluid or viscoelastic from the paracentesis to decompress the anterior chamber.

7. **Decompress the anterior chamber and then reposit iris**

In order to resolve the prolapse, you must first decrease the force driving the iris to prolapse through the wound. This is typically due to an elevated anterior chamber pressure, often due to fluid from hydrodissection being trapped posteriorly behind the lens or unable to exit the eye due to impedance from viscoelastic. If fluid is trapped behind the lens, place a second instrument into the anterior chamber via the paracentesis and gently rock the lens to release the trapped fluid. If fluid is trapped by viscoelastic, burping or manually removing viscoelastic with a cannula will usually lower the pressure sufficiently to allow the iris to be easily reposit.

8. **Stroke the main wound**

Use a hydrodissection cannula to gently stroke the cornea overlying the main wound. This technique is adopted from partial thickness endothelial keratoplasty, wherein stroking the cornea externally can cause internal movement of the endothelial graft, and also works well for releasing the prolapsed iris.

9. **Lower the intraocular pressure/bottle height and decrease the aspiration flow rate/vacuum**

Once you have successfully reposit the iris, you should take measures to keep the iris from prolapsing again during the remainder of the case by stabilizing the fluidics. This can be done by lowering the intraocular pressure or bottle height and decreasing the aspiration flow rate/vacuum, which helps minimize large fluctuations in anterior chamber pressure and decreases the risk of repeat prolapse.

10. **Don't make a bad situation worse**

After prolapse, the iris architecture has been disrupted, and even a seemingly simple step like inserting the intraocular lens could catch the peripheral iris and cause an iridodialysis. Prior to IOL insertion, consider placing viscoelastic immediately posterior to the main wound to create more space for IOL insertion.

To learn more about the history of iris prolapse and theories explaining its causes, view the related tutorial: [Iris Prolapse: The History of this Ancient \(and Present\) Surgical Challenge](#) at EyeRounds.org/tutorials/iris-prolapse-history.htm

More surgical videos describing these (and more) tips on iris prolapse

www.facebook.com/pg/cataract.surgery/videos

www.facebook.com/cataract.surgery/videos/173461071140/

www.facebook.com/cataract.surgery/videos/159211146140/

References

1. Chang DF, Campbell JR. Intraoperative floppy iris syndrome associated with tamsulosin. *J Cataract Refract Surg* 2005;31(4):664-673. [PMID 15899440]
2. Oetting TA, Omphroy LC. Modified technique using flexible iris retractors in clear corneal cataract surgery. *J Cataract Refract Surg* 2002;28(4):596-598. [PMID 11955897]
3. Tint NL, Yeung AM, Alexander P. Management of intraoperative floppy-iris syndrome-associated iris prolapse using a single iris retractor. *J Cataract Refract Surg* 2009;35(11):1849-1852. [PMID 19878813]

Suggested Citation Format

Christiansen SM, Oetting TA. Ten Tips to Prevent and Treat Iris Prolapse. May 3, 2017; Available from: EyeRounds.org/tutorials/ten-tips-iris-prolapse.htm

last updated: 05/03/2017

Tutorials

Glaucoma

Medical Management of Glaucoma

A Primer

William E. Flanary, MD, Lorraine A. Myers (Provencher), MD, Wallace L.M. Alward, MD

September 1, 2015

Introduction

There are numerous risk factors for glaucoma, but the only one we can effectively treat is intraocular pressure (IOP). All medications used in glaucoma act to either decrease production of aqueous humor or increase its outflow, thereby reducing IOP. The goal of this article is to introduce the different classes of medications, their mechanisms of action, efficacy, and potential side effects. Medical management of glaucoma is an art form. The decision to start, stop, or adjust a medication is often a gray area and may be approached differently by different eye care providers.

Prostaglandin Analogues

Four prostaglandin analogues are currently available for clinical use: latanoprost, bimatoprost, travoprost, and tafluprost (Table 1). In general, these medications are well tolerated, popular, and highly effective for most patients. Although the exact mechanism of action of this class of medications is not fully known, an increase in uveoscleral outflow is generally accepted as the primary mechanism. Some studies suggest prostaglandin analogues also increase trabecular outflow facility by regulating matrix metalloproteinases and remodeling the extracellular matrix within the trabecular meshwork, however the data supporting this theory is not as consistent as that describing uveoscleral outflow [1].

Prostaglandin analogues are dosed once every evening with peak effect 10-14 hours after administration, and more frequent dosing may actually lead to a paradoxical increase in pressure [1]. Studies show an IOP lowering ability of 25-32% for latanoprost, travoprost, and tafluprost and 27-33% for bimatoprost [2]. Latanoprost and travoprost are prodrugs that are activated after being hydrolyzed by corneal esterases. Prostaglandins are indicated for all types of open angle glaucoma, including primary open angle glaucoma, pseudoexfoliation glaucoma, pigmentary glaucoma, and normal-tension glaucoma. These medications are not as effective in primary congenital glaucoma and

angle closure glaucoma [3]. Prostaglandin analogues are relatively contraindicated in patients with cystoid macular edema and in patients with inflammatory glaucoma due to the theoretical risk of worsening inflammation.

Side effects of prostaglandin analogues are mainly ocular. Hyperemia is common, but is minimized by the evening dosing. Increased iris pigmentation, observed in 33% of patients after five years, occurs more frequently in persons with hazel (yellow-brown) irides. Other side effects include periocular hyperpigmentation, hypertrichosis, hyperemia, and periorbitopathy (Figure 1). These effects appear to be reversible with drug discontinuation.

Issues to consider when starting prostaglandin analogues

- Is there active inflammation in the eye or a history of ocular inflammation?
- Is there a history of cystoid macular edema?
- If dosing in one eye, will the patient tolerate potential asymmetric changes in the appearance of the eye?

Disclaimer: The medications discussed in this article are limited to those available in the United States. There is variability in availability from country to country. The medication cost included in each table is derived from the average cost of each medication found in local pharmacies in the Iowa City/Coralville, Iowa area as reported by GoodRx.com. Prices and availability may vary by geographic area.


Abbreviations

BID = twice a day
QD = each day / every day
QHS = each bedtime
QID = four times a day
TID = three times a day

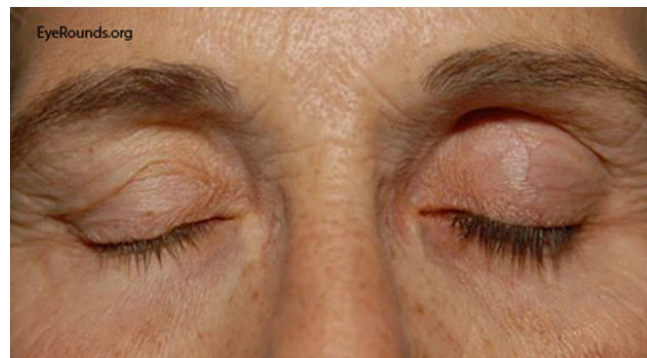

Figure 1: Note the elongated lashes (hypertrichosis) and periorbital atrophy on the left due to prostaglandin use

Table 1: Commonly used Prostaglandin analogues

Generic	Brand	Concentration	Dosing	Cost Generic	Cost Brand	Example Cap Color
Latanoprost	Xalatan®	0.005%	QHS	\$16/2.5ml	\$140/2.5ml	
Travaprost	Travatan®	0.004%		N/A	\$80/2.5ml	
Bimatoprost	Lumigan®	0.01%, 0.03%		N/A	\$150/2.5ml (0.1%)	
Tafluprost	Zioptan®	0.0015%		N/A	\$160/month	

Beta-Adrenergic Antagonists (β-Blockers)

β-blockers are popular, effective, generally well-tolerated, and indicated in all forms of glaucoma. Four β-blockers are currently available for clinical use: timolol, levobunolol, carteolol, and betaxolol, and can be divided into two subclasses of topical β-blockers: Non-selective and selective (Table 2). The non-selective β-blockers, timolol, levobunolol, and carteolol, target both β-1 and β-2 receptors, while the selective β-blocker, betaxolol, selectively targets only β-1 receptors [1]. The mechanism of action involves the blockade of sympathetic nerve endings in the ciliary epithelium, decreasing cyclic adenosine monophosphate (cAMP) production, and subsequently decreasing aqueous humor secretion by 20-30% during the day [3]. β-blockers have little IOP-lowering effect at night and are thus generally dosed once in the morning, or sometimes twice daily, especially when used in combination agents.

Patients taking a systemic β-blocker may have a diminished response to topical therapy. Prolonged use of β-blockers can result in tachyphylaxis. A reduced IOP response may also occur within weeks of starting treatment, as receptor saturation responds with up-regulation of the β-adrenergic receptor.

Treatment of one eye with β-blockers will sometimes lead to a decrease in the IOP of the contralateral, untreated eye, indicating there is a degree of systemic uptake with topical β-blockers. Recall that the β1-receptor has largely cardiac effects, and the β-2 receptor has largely pulmonary effects. Betaxolol, a β1 selective receptor antagonist,



therefore, has fewer systemic respiratory side effects when compared to non-selective β-blockers, which target both β1 and β2 receptors. Though the efficacy of IOP-lowering is reduced in betaxolol for this same reason, betaxolol is considered to be safer for patients with respiratory or central nervous system (CNS) disease [3]. β-blockers have also been shown to decrease high-density lipoprotein (HDL) and increase cholesterol levels, though it is unclear the impact this may have on cardiovascular risk. Carteolol may have fewer effects on serum lipids [1]. Caution should be used when treating children with beta blockers, as they can reach high serum concentrations.

Systemic side effects may include bronchospasm, bradycardia, increased heart block, masking of hypoglycemic symptoms, decreased blood pressure, reduced exercise tolerance, depression, syncope, CNS depression, mood swings, and decreased libido. Abrupt withdrawal may worsen hyperthyroidism. Ocular side effects may include allergy, punctate keratitis, corneal anesthesia, and aggravation of myasthenia gravis.

Issues to consider when starting a β-blocker

- Does the patient have respiratory or heart disease?
- Is the patient at high risk for hypoglycemia?
- Does the patient have thyroid disease or myasthenia gravis?
- Does the patient have problems with anxiety, depression, fatigue, or impotence?

Table 2: Commonly used Beta-Adrenergic Antagonists (β-blockers)

Generic	Brand	Concentration	Dosing	Cost generic	Cost brand	Example Cap Color
Non-selective						
Timolol	Timoptic®	0.25%, 0.5%	QD-BID	\$4/5ml (0.5%)	\$160/5ml (0.5%)	 0.5% β-blockers
Levobunolol	Betagan®	0.25%, 0.5%		\$4/5ml (0.5%)	\$58/5ml (0.5%)	
Carteolol	Ocupress®	1.0%		\$12/5ml	N/A	
β1-selective						
Betaxolol	Betoptic®	0.25%, 0.5%	QD-BID	\$50/5ml (0.5%)	\$286/5ml (0.5%)	 0.25% β-blockers

α2-Adrenergic Agonists

Two α2-adrenergic agonists are currently available for use: apraclonidine and brimonidine. These have replaced non-selective adrenergic agents which caused ocular vasoconstriction, pupillary dilation, and eyelid retraction via α1-adrenergic agonism. The α2-agonists decrease aqueous production and increase aqueous outflow, although their exact mechanism remains unclear. The α2-agonists are indicated for all forms of glaucoma, and some evidence suggests they may have neuroprotective effects, which could provide additional benefit in normal-tension glaucoma [4].

Apraclonidine is often used in the pre- and post-operative setting, particularly after laser or cataract surgery, as it is an effective short-term IOP lowering agent. Patients often develop topical sensitivity or tachyphylaxis, which limits its long term use. Further, the incidence of allergic reaction to apraclonidine is up to 40% and may include follicular conjunctivitis and contact blepharodermatitis. Fortunately, the cross-reactivity to brimonidine in patients with allergy to apraclonidine is minimal. Despite low incidence of true allergy to brimonidine, long-term intolerance is high (>20%) due to local adverse effects, i.e. hyperemia and blepharoconjunctivitis and even ectropion and granulomatous anterior uveitis. If a patient is on several drops and presents with the aforementioned signs or symptoms, regardless of the duration of therapy, it is reasonable to first suspect the α2-agonist as potentially contributing. Preservative free options exist and will be reviewed later in this article.

Both α2-agonists, apraclonidine and brimonidine, can lower IOP by 20-30% and are dosed BID or TID. Brimonidine is found in combination with timolol (Combigan®), dosed BID, or brinzolamine (Simbrinza®), dosed BID or TID. An absolute contraindication to brimonidine is use in children under 3-4 years of age as it may cross the blood brain barrier and result in fatal respiratory arrest, along with somnolence, hypotension, seizures, and derangement of CNS neurotransmitters. Apraclonidine is a safer alternative, as it does not cross the blood brain barrier. The α2-agonists are relatively contraindicated in patients taking monoamine oxidase inhibitors or tricyclic antidepressants.

Remember, α2-agonists are notorious for ocular side effects. Apraclonidine may cause irritation, pruritis, allergy, follicular conjunctivitis, dermatitis, eyelid retraction, ischemia, conjunctival blanching, ocular ache, photopsia, and miosis. Brimonidine may cause foreign-body sensation, eyelid edema, dryness, and ocular sensitivity/allergy, though less allergy compared to apraclonidine (Figure 2). Systemic side effects may include hypotension, syncope, vasovagal attack, dry mouth and nose, headache, anxiety, depression, and fatigue.



Issues to consider when starting α2-Adrenergic Agonists

- Is this a child under 3-4 years of age? (do not use)

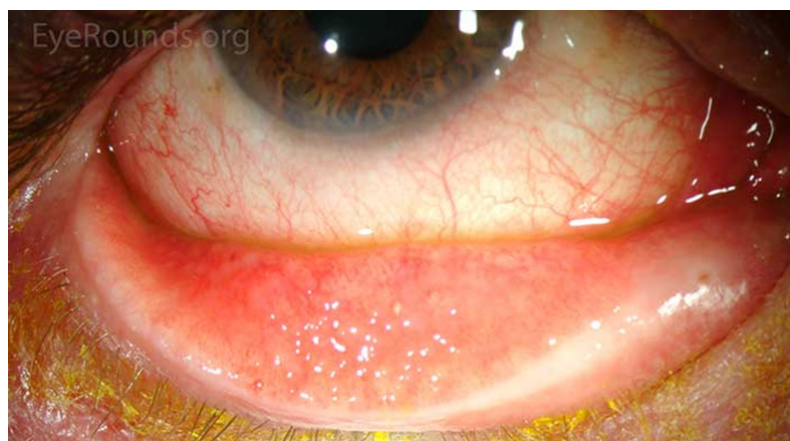

Figure 2: Follicular conjunctivitis from brimonidine use

Table 3: Commonly used α2-Adrenergic Agonists

Generic	Brand	Concentration	Dosing	Cost generic	Cost brand	Example Cap Color
Selective						
Apraclonidine	Iopidine®	0.5%, 1.0%	BID-TID	\$50/5ml (1%)	\$152/5ml (1%)	 Apraclonidine
Brimonidine	Alphagan®	0.1%, 0.2%	BID-TID	\$9/5ml	\$124/5ml (0.1%)	 Brimonidine

Carbonic Anhydrase Inhibitors

Carbonic anhydrase inhibitors (CAIs) function as direct antagonists to ciliary epithelial carbonic anhydrase, an enzyme necessary for production of aqueous humor. More than 90% of this enzyme must be inhibited in order to decrease intraocular pressure [1]. Systemic CAIs, of which acetazolamide and methazolamide are the most common, have been available for decades, but their use in glaucoma has been limited due to the potential for serious side effects and the availability of alternative topical agents with fewer side effects. Topical CAIs (dorzolamide, brinzolamide) are generally better tolerated with fewer side effects and are commonly used as both an individual medication for glaucoma as well as part of several combination drops. Systemic agents have greater efficacy, with 30-50% IOP reduction compared to 15-20% IOP reduction with topical agents [5]. Of the systemic agents, acetazolamide is considered more effective than methazolamide, though it also has more side effects. Acetazolamide is eliminated in the kidneys, while methazolamide is metabolized in the liver.

Common adverse effects of topical CAIs include bitter taste and punctate keratopathy. Eyes with compromised endothelial dysfunction (e.g. Fuchs dystrophy) are at higher risk for corneal decompensation and should not be treated


with topical CAIs. Some patients complain of burning with dorzolamide; this is less problematic with brinzolamide. Adverse effects of systemic CAIs are usually dose-dependent and include paresthesias of the fingers and toes, fatigue, loss of energy, and loss of appetite. Abdominal discomfort and bitter taste, particularly with carbonated beverages, are also commonly encountered. Rarely, patients may develop blood dyscrasias, including aplastic anemia, thrombocytopenia, and agranulocytosis. Hypokalemia may also develop, particularly in patients who are taking other diuretic medications (e.g. thiazides) (1).

Although CAIs are sulfonamide derivatives, they are generally tolerated in those with sulfa allergies [6]. In a large retrospective study by Lee et al. in 2004, high dose acetazolamide was used in patients with idiopathic intracranial hypertension as well as a self-reported sulfa allergy without serious adverse effects [7].

Issues to consider when starting a carbonic anhydrase inhibitor

- Does this patient have normal corneal endothelial function (for topical use)?
- Does this patient have baseline hepatic or renal impairment (for systemic use)?

Table 4: Commonly Used Carbonic Anhydrase Inhibitors

Generic	Brand	Concentration	Dosing	Cost generic	Cost brand	Cap Color
Topical						
Dorzolamide	Trusopt®	2.0%	BID-TID	\$25/10ml	\$87/10ml	
Brinzolamide	Azopt®	1.0%		N/A	\$260/10ml	
Systemic						
Acetazolamide	Diamox®	250, 500mg	BID-QID	\$56/120tabs (250mg)	N/A	Tabs are white or orange
Methazolamide	Neptazane®	25, 50, 100mg	BID-TID	\$140/60 tabs (50mg)	N/A	

Cholinergic Stimulators

Pilocarpine is the most commonly used cholinergic in medical practice. Pilocarpine decreases IOP by stimulating ciliary muscle contraction. This produces traction on the scleral spur by virtue of its attachment to the ciliary musculature. The displacement of the scleral spur leads to an increase in conventional (trabecular) aqueous outflow. The miosis induced by pilocarpine also improves outflow in eyes with angle closure glaucoma by pulling peripheral iris from the anterior chamber angle. Conversely, pilocarpine decreases uveoscleral outflow, which may cause a paradoxical rise in IOP. Pilocarpine is typically administered four times a day. The maximum IOP lowering effect occurs within two hours, with a reduction in IOP of approximately 20% [1].

The ocular side effects of ciliary muscle spasm and miosis result in poor tolerance of pilocarpine, particularly in


young patients with high accommodative ability. Pilocarpine should be avoided in highly myopic patients due to the increased risk of retinal detachment. Other potential ocular side effects include cataract formation and corneal endothelial toxicity. Systemic toxicity is rare and includes activation of the parasympathetic nervous system including diaphoresis, lacrimation, salivation, gastrointestinal distress, and bronchospasm.

Echothiophate is an indirect-acting cholinergic medication rarely used today due to the side effect profile (redness, brown ache, pigmented iris cysts) and the existence of numerous, more effective, and better tolerated topical medications. Echothiophate is still available in pharmacies, and has the advantage of being more potent and dosed twice daily, though it is more expensive than pilocarpine. Unfortunately, pilocarpine is intermittently unavailable.

Issues to consider when starting a cholinergic stimulator

- Is this patient myopic?
- Does this patient have high accommodative ability?




Table 5: Commonly used cholinergic agonists

Generic	Brand	Concentration	Dosing	Cost generic	Cost brand	Example Cap Color
Direct						
Pilocarpine HCl	IsoptoCarpine	1%, 2%, 4%	QID	\$4/15ml (1%)	\$94/15ml (1%)	
Indirect						
Echothiophate iodide	Phospholine iodide	1.25%	QD-BID	N/A	\$100/5ml	

Combination medications

Combination drops are an effective way to decrease the drop burden for patients who require multiple topical medications. Available combinations in the US include Dorzolamide/Timolol, Brimonidine/Timolol, and Brinzolamide/Brimonidine. Additional well-tolerated combination drops are available outside the US but are not FDA approved. The biggest drawback for patients prescribed combination medications is the high cost.

Table 6: Commonly used combination medications

Generic	Brand	Concentration	Dosing	Cost generic	Cost brand	Example Cap Color
Dorzolamide/ Timolol	Cosopt®	2.0%/0.5%	BID	\$25/10ml	\$150/10ml	
Brimonidine/ Timolol	Combigan®	0.2%/0.5%		N/A	\$135/5ml	
Brinzolamide/ Brimonidine	Simbrinza®	1.0%/0.2%		N/A	\$135/8ml	

BAK Preservative-Free Options

Numerous studies have documented the potential for ocular surface toxicity with long-term use of preserved glaucoma medications [8-10]. A prospective survey by Pisella et al. in 2002 found a higher incidence of ocular surface symptoms (e.g. redness, follicles, punctate keratopathy) in patients taking preserved eye drops versus non-preserved drops, and many of the minor adverse reactions reported by patients may be caused by the presence of preservatives [11]. Benzalkonium chloride (BAK) is a widely-used preservative found in many commonly used glaucoma medications and several BAK-free and preservative free alternatives exist across multiple classes of glaucoma med-

ications. Unfortunately, the high cost of these medications is prohibitive for many patients. Insurance coverage is often a challenge, with most insurance companies requiring documented failure of preserved medications prior to use of any non-preserved option.

Issues to consider when starting a preservative free drop

- Has the patient tried and failed the available preserved option?
- Are they willing to pay out of pocket if insurance denies coverage?

Table 7: Commonly Used BAK-Free Options

Medication	Brand	Concentration	Preservative	Cost brand
Alpha agonists				
Brimonidine	Alphagan-P®	0.1%, 0.15%, 0.2%	Purite©	\$30/5ml (0.2%)
Prostaglandins				
Travaprost	Travatan-Z®	0.004%	sofZia©	\$160/2.5ml
Tafluprost	Zioptan®	0.0015%	None	\$130/mo
Beta blockers				
Timolol maleate gel	Timoptic-XE®	0.25%, 0.5%	Benzododecinium	\$200/5ml (0.5%)
Timolol in Ocudose	Timoptic®	0.25%, 0.5%	None	\$450/mo (0.5%)
Cholinergics				
Echothiophate	Phospholine Iodide	1.25%	Chlorbutanol	\$100/5ml
Combination				
Timolol/Dorzolamide	Cosopt PF®	0.2%/0.5%	None	\$110/mo

References

1. Glaucoma. Basic and Clinical Science Course. 2014-2015. American Academy of Ophthalmology.
2. Camras CB, Alm A, Watson P, Stjernschantz J. Latanoprost, a prostaglandin analog, for glaucoma therapy: efficacy and safety after 1 year of treatment in 198 patients. Latanoprost Study Group. *Ophthalmology*. 1996;103(11):1916-1924.
3. Alward WLM. *Glaucoma: The Requisites*. Mosby. 1999.
4. Sena DF, Lindsley K. Neuroprotection for treatment of glaucoma in adults. *Cochrane Database Syst Rev*. 2013; 2: CD006539.
5. Strahlman E, Tipping R, Vogel R. A double-masked, randomized 1-year study comparing dorzolamide (Trusopt), timolol, and betaxolol. International Dorzolamide Study Group. *Arch Ophthalmol*. 1995;113(8):1009-1016.
6. Drugs for some common eye disorders. *Treat Guide Med Letter*. 2012 Nov; 10(123):79-86.
7. Lee AG, Anderson R, Kardon RH, Wall M. Use of Acetazolamide in Sulfonamide-Allergic Patients With Neurologic Channelopathies. *Am J Ophthalmol* 2004; 138: 114-118.
8. De Saint Jean M, Debbasch C, Brignole F, et al. Toxicity of preserved and unpreserved antiglaucoma topical drugs in an in vitro model of conjunctival cells. *Curr Eye Res* 2000;20:85-94.
9. Burstein NL. Corneal cytotoxicity of topically applied drugs, vehicles and preservatives. *Surv Ophthalmol* 1980;25:15-30.
10. Burstein NL. The effects of topical drugs and preservatives on the tears and corneal epithelium in dry eye. *Trans Ophthalmol Soc UK* 1985;104:402-409.
11. Pisella PJ, Pouliquen P, Baudouin C. Prevalence of ocular symptoms and signs with preserved and preservative free glaucoma medication. *Br J Ophthalmol* 2002;86:418-423.

Suggested Citation Format

Flanary WE, Myers (Provencher) LA, Alward WLM. Medical management of glaucoma: A primer. EyeRounds.org. posted September 1, 2015; Available from: EyeRounds.org/tutorials/glaucoma-medical-treatment

last updated: 09/01/2015

MIGS: Minimally Invasive Glaucoma Surgery

Austin R. Fox, MD, Tyler B. Risma, MD, Jason P. Kam, MD, Daniel I. Bettis, MD

September 27, 2017

Introduction

Glaucoma is the leading cause of irreversible blindness in the world with an estimated global burden of over 64 million people that is projected to increase to 111.8 million by 2040.[1] Currently, the only modifiable risk factor for glaucoma is intraocular pressure (IOP), and lowering IOP is the mainstay of treatment to date. Traditionally, topical medications, laser, and incisional surgery (trabeculectomy or tube shunts) have been the primary means to lower IOP and treat glaucoma. Topical medications require patient adherence, and cost may present a barrier to access. Selective laser trabeculoplasty (SLT) is typically effective initially, but its effectiveness can decrease over time.[2] Trabeculectomy and tube shunt surgeries are highly effective but carry a higher risk of complications. In the Tube Versus Trabeculectomy (TVT) Study, IOP decreased by a mean of 41.4% with tube surgery and 49.5% with trabeculectomy with decreased requirement for medication in both groups at 5 years follow up.[3] However, early complications (≤ 1 month) were seen in 21% of tube group and 37% of the trabeculectomy group, and late complications (> 1 month) were seen in 34% of the tube group and 36% of the trabeculectomy group. The rate of reoperation for complications was 22% in the tube group and 18% in the trabeculectomy group.[4] As an alternative to traditional glaucoma treatments, minimally invasive glaucoma surgery (MIGS) has shown promise for the future management of glaucoma.

The cardinal features of MIGS, as proposed by Saheb and Ahmed in 2012 [5], are:

- ◆ Ab interno, micro-incisional approach (*note: InnFocus MicroShunt uses an ab-externo approach.)
- ◆ Minimal trauma/disruption to normal anatomy and physiology
- ◆ Demonstrable/reliable IOP lowering
- ◆ Extremely high safety profile
- ◆ Rapid post-op recovery, with minimal need for follow-up

MIGS typically require shorter operation time and allow for more rapid recovery. MIGS can be combined with cataract extraction (CE) for patients with mild to moderate glaucoma and cataracts. While MIGS have been approved for and studied in open angle glaucoma (OAG), they have also been used for other forms of glaucoma, including pseudoexfoliation, post-traumatic, pediatric, and ocular hypertension. With a lower risk profile, MIGS may be well-suited as a first line surgical intervention for monocular or high-risk patients. Though early studies show MIGS may be less effective in lowering IOP than traditional glaucoma surgeries, MIGS do fill a gap in the treatment of patients who would benefit from lower IOP but do not warrant the risk of traditional surgery. The growing array of MIGS work

by increasing trabecular outflow, increasing uveoscleral outflow, increasing subconjunctival outflow, or decreasing aqueous production.

See Table 1: Overview of MIGS procedures and descriptions.

iStent (Glaukos Corporation)

The iStent Trabecular Micro-Bypass Stent was the first FDA-approved (2012) trabecular microbypass. It works by incising then stenting Schlemm's canal to increase trabecular outflow. The iStent is a 1.0 mm x 0.3 mm, heparin-coated, non-ferromagnetic titanium (allowing magnetic resonance imaging up to 3 T). Its tapered design allows it to slide into Schlemm's canal, where it is then anchored by its 3 retention arches (Figure 1). The iStent is indicated for mild to moderate OAG previously treated with glaucoma drops, and performed in conjunction with CE.

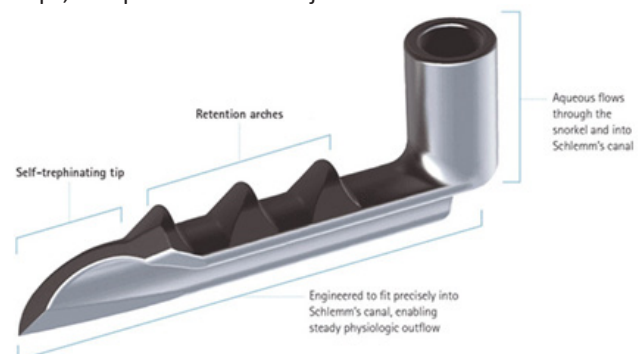


Figure 1. iStent Trabecular Micro-Bypass Stent. Source: Glaukos Corporation, www.glaukos.com/healthcare-professionals/istent/ Image used with permission.

Multiple randomized controlled trials (RCTs) have been conducted regarding the iStent. The iStent Study Group conducted the largest RCT including 240 subjects with mild to moderate glaucoma.

At 1 year, there was a significant difference in the iStent with CE group versus the control CE alone group in achieving the primary endpoint of an IOP ≤ 21 mmHg without glaucoma medications (72% vs 50%, $p < 0.001$). A secondary endpoint, decrease in IOP of $\geq 20\%$ without glaucoma medications, was also significantly different between the 2 groups (66% vs 48%, $p = 0.003$). In addition, there was a significant difference in the reduction of medication burden among the groups at 1 year: 0.2 ± 0.6 medications were required in the iStent with CE group versus 0.4 ± 0.7 medications required in the CE alone group ($p = 0.016$).[6]

Table 1: Overview of MIGS procedures and descriptions.

MIGS:	Specifics / Procedure:
Increase Trabecular Outflow	
iStent Micro-Bypass	Heparin-coated, non-ferromagnetic titanium stent; 1.0 mm x 0.3 mm. <i>Ab interno</i> insertion into Schlemm's canal
Gonioscopy-assisted transluminal trabeculotomy (GATT)	<i>Ab interno</i> trabeculotomy using illuminated microcatheter (iTrack; Ellex) or prolene/nylon suture passed through a 1-2 mm goniotomy into Schlemm's canal 360° and lysed through the trabecular tissue
Trabectome	<i>Ab interno</i> trabeculectomy using combination of electrocautery, irrigation and aspiration
TRAB 360 Trabeculotomy	<i>Ab interno</i> trabeculotomy using disposable, non-powered device from which a flexible nylon-like trabeculotome is advanced into Schlemm's canal for 180° and then lysed (x2 to perform up to 360° trabeculotomy)
Kahook Dual Blade	<i>Ab interno</i> trabeculotomy using a single use, tapered, stainless steel blade
Ab interno canaloplasty	Illuminated microcatheter (iTrack; Ellex) and viscosurgical device used to cannulate and viscodilate Schlemm's canal
Hydrus Microstent	Crescent-shaped scaffold (8-mm long) composed of nickel-titanium alloy, <i>Ab interno</i> insertion into Schlemm's canal
Increase Uveoscleral / Suprachoroidal/ Supraciliary Outflow	
CyPass Micro-Stent	Fenestrated micro-stent, composed of biocompatible, polyimide material (6.35 mm x 510 mm, 300 mm lumen) <i>Ab interno</i> insertion between anterior chamber/sclera and suprachoroidal space
iStent Supra	Heparin-coated stent (4mm long, 0.16-0.17mm lumen) composed of polyethersulfone (PES) with a titanium sleeve. <i>Ab interno</i> insertion between anterior chamber/sclera and suprachoroidal space
Increase Subconjunctival Outflow	
XEN Glaucoma Treatment System	Tissue-conforming tube implant (6-mm long) composed of gelatin and glutaraldehyde material <i>Ab interno</i> insertion from the anterior chamber, through sclera into the subconjunctival space, bleb forming
InnFocus MicroShunt	Flexible microshunt (8.5 mm x 0.350 mm, 70 µm lumen) composed of SIBS (poly(styrene-block-isobutylene-block-styrene)) <i>Ab-externo</i> , subconjunctival (via peritomy) insertion through scleral needle tract into anterior chamber, connecting it to sub-Tenon's space, bleb forming
Decrease Aqueous Production	
Endocyclophotocoagulation	<i>Ab interno</i> cyclodestruction of ciliary body epithelium using continuous energy (810nm wavelength)

At 2 years, the proportion of subjects achieving primary outcome remained significantly higher in the iStent with CE group (61% vs 50%, $p = 0.036$), however the difference in IOP decrease $\geq 20\%$ without glaucoma medications was not significantly different between the 2 groups (53% vs 44%, $p = 0.09$), and there was also no significant difference in number of glaucoma medications used ($p = 0.09$). After 2 years, IOP in the iStent with CE group was 8.4 mm Hg lower than baseline IOP, and IOP in the CE alone group was

7.5 mm Hg lower than baseline IOP, which was not a statistically significant difference.[7] The iStent Study Group showed that the iStent's efficacy was modest but allowed a prolonged reduction in IOP and medication burden. Importantly, there were no serious complications associated with the iStent. The most common complications were stent obstruction (4.3%) or malposition (2.6%), neither of which caused any adverse events.

Multiple iStents

To evaluate the efficacy of multiple iStents (2 or 3) in conjunction with CE, a prospective study of 53 eyes with OAG was conducted.[8] After 1 year, the overall mean IOP was significantly lower (14.3 ± 2.9 mmHg) than baseline (18.0 ± 4.0 mmHg) ($p < 0.001$) in each group (2 or 3) ($p < 0.001$). There was also a significant decrease in mean glaucoma medication at 1 year by 74% (2.7 ± 1.0 to 0.7 ± 1.1 , $p < 0.001$). Additionally, 31 study eyes (59%) were off of all medications at 1 year. This study showed that multiple iStents can be safely implanted and result in effective IOP reduction on fewer glaucoma medications.

iStent Inject - The 2nd Generation iStent

The iStent Inject is a 2nd generation iStent, which was developed with the premise that multiple iStents may be more effective than a single iStent. It is smaller in size (0.36 mm x 0.23 mm) and designed for perpendicular insertion into Schlemm's canal, no longer requiring parallel sliding of the iStent for positioning (*Figure 2*). Each device comes pre-loaded with 2 stents, so that both can be inserted in one procedure. A RCT of 192 subjects showed that implantation of 2 iStent Injects is comparable to medical treatment with two agents (latanoprost and timolol) in reducing IOP after 1 year.[9] Both the iStent Inject group and medication group had similar reductions in IOP (8.1 ± 2.6 mmHg and 7.3 ± 2.2 mmHg) and achieved similar rates of IOP reduction $\geq 20\%$ compared to baseline at 1 year (94.7% and 91.8%). As with the original iStent, there was a highly favorable safety profile with the iStent Inject.[9]

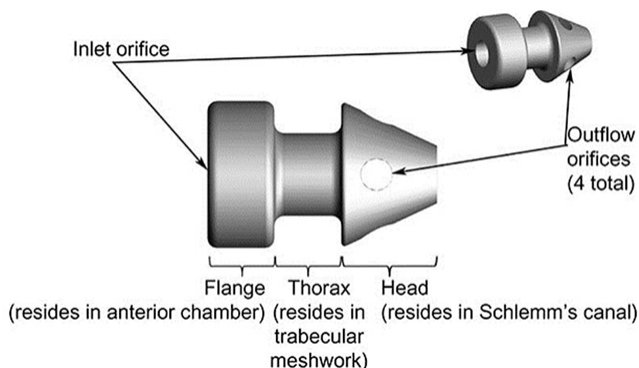


Figure 2. iStent Inject Source: Belovay et al. J Cataract Refract Surg. 2012;38(11):1911-7.[8]

Gonioscopy-assisted transluminal trabeculotomy (GATT)

GATT was first described as a minimally-invasive form of *ab interno* trabeculotomy by Grover *et al.* in 2014.[10] An illuminated microcatheter (iTrack; Ellex) or suture (typically 5-0 or 6-0 nylon or prolene) is passed through a 1-2 clock hour goniotomy into Schlemm's canal then advanced for 360 degrees. It is then pulled centrally, applying force to lyse through the trabecular meshwork (TM) and creating a

360-degree trabeculotomy (fig. 3. [10]). The iTrack microcatheter has a 200-micron diameter shaft with a lubricated coating, along with a lighted tip, which can be constantly or intermittently illuminated to monitor catheter location. Like other MIGS, GATT is indicated for medically-uncontrolled OAG and can be performed with or without CE.

Grover *et al.* conducted a retrospective review of 85 consecutive patients for whom GATT was performed with or without CE.[10] At 12 months follow-up of 57 primary OAG patients, IOP decreased by 11.1 ± 6.1 mmHg (40%) on an average of 1.1 ± 1.8 fewer glaucoma medications. For 28 patients with secondary OAG, IOP decreased by 19.9 ± 10.2 mmHg (57%) on an average of 1.9 ± 2.1 fewer medications. There was no statistically significant difference in IOP change related to lens status or whether concurrent CE was performed in eyes undergoing GATT.[10] The primary complication was transient hyphema in 30% of patients, which resolved in most patients by 1 month post-operatively. However, hyphema was still present in 3 patients at 1 month post-operatively, 1 patient at 3 months, and 1 patient at 6 months. Additional glaucoma surgery was needed in 9% (8/85) of the patients. Due to the nature of the procedure, there are several absolute contraindications: required anticoagulation, bleeding diatheses, angle closure, obscured angle structures, severe endothelial compromise, or intraocular lens instability. Relative contraindications include previous corneal transplant and an inability to elevate patient's head 30° during the first postoperative week.

In a retrospective review of the pediatric population, Grover *et al.* showed GATT to be a viable treatment option equivalent to *ab externo* trabeculotomy for the treatment of primary congenital glaucoma and juvenile OAG.[11]

SEE VIDEO AT: <https://youtu.be/y463tW3lh0Q>

Trabectome (NeoMedix Inc.)

Trabectome is an FDA-approved (2004) device used to perform *ab interno* trabeculectomy (AIT). Trabectome combines electrocautery with irrigation and aspiration and consists of a 19.5 gauge handpiece with a bipolar 550 kHz electrode. The handpiece is disposable and requires a separate irrigation and aspiration console with a high frequency generator (*Figure 4*). As the electrocautery ablates trabecular meshwork up to 180 degrees, the natural drainage pathway is exposed. Simultaneously aspiration and irrigation are used to remove the ablated tissue to allow aqueous outflow. Initially, trabectome was indicated for primary OAG patients with uncontrolled IOP on maximal medical therapy, however many cases have reported the use of trabectome in a wide array of glaucoma subtypes, including narrow angle glaucoma.[12] In addition, AIT has been shown to be a good option in patients with pseudoexfoliation glaucoma and with a history of a failed trabeculectomy.[13,14]

No RCTs have been conducted examining trabectome. However, a meta-analysis compiled the data of 14 studies including 5,091 subjects and found an overall (66%) aver-

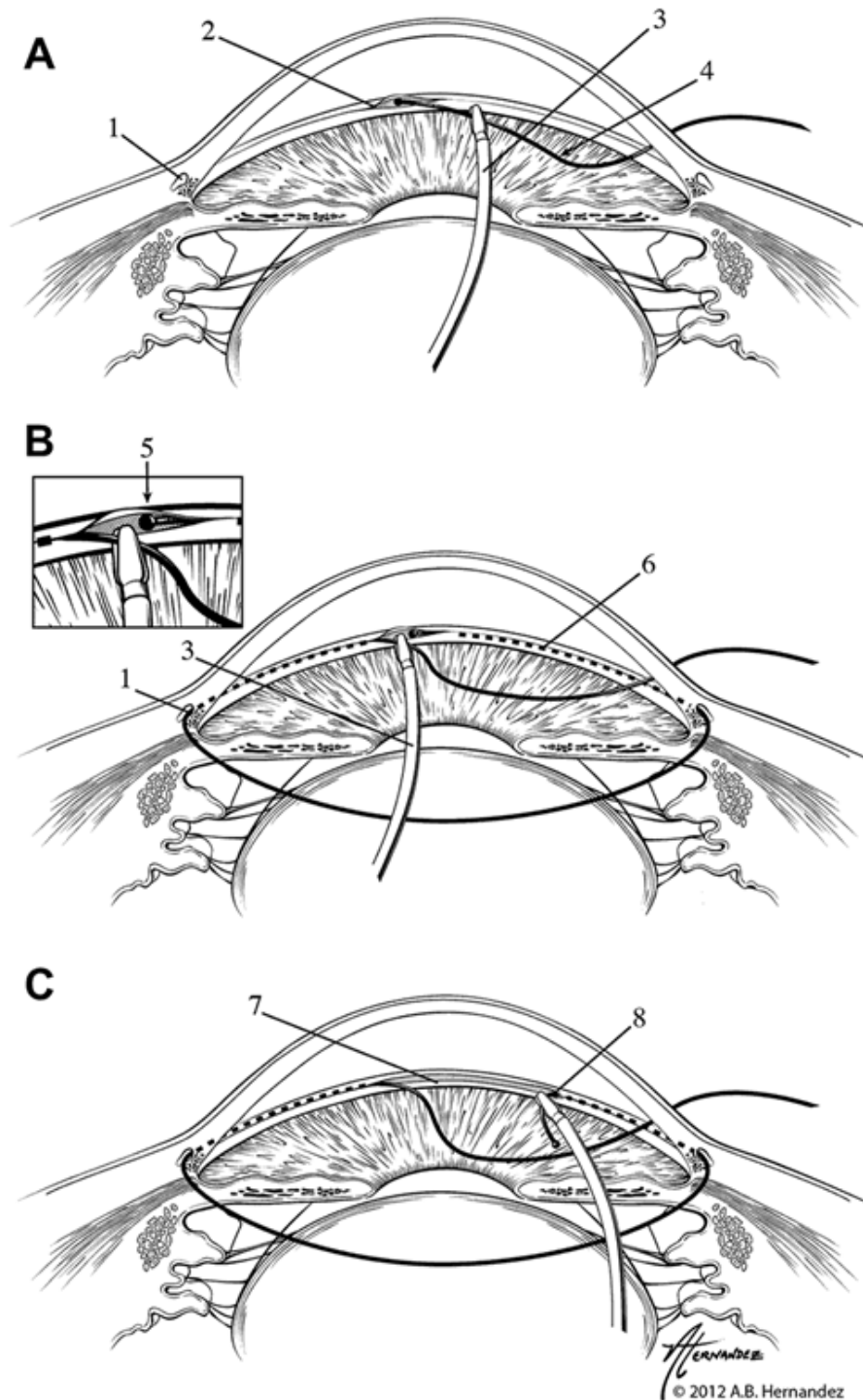


Figure 3. Illustrations documenting the key steps of the gonioscopy-assisted transluminal trabeculotomy procedure. **A,** Initial cannulation of Schlemm's canal within the anterior chamber. **B,** The catheter (or suture) has been passed 360° around the canal. **C,** The distal tip of the catheter (or suture) has been retrieved and is being externalized, thus creating the circumferential trabeculotomy.

1 = Schlemm's canal; 2 = initial goniotomy site; 3 = microsurgical forceps; 4 = either the suture or microcatheter; 5 = distal end of the suture or microcatheter after it has been passed 360° around Schlemm's canal; 6 = path of the suture or microcatheter within Schlemm's canal; 7 = trabecular shelf that is created after this procedure; 8 = trabeculotomy that is created when the distal end of the suture or catheter is retrieved and externalized. Image used with permission.[10]

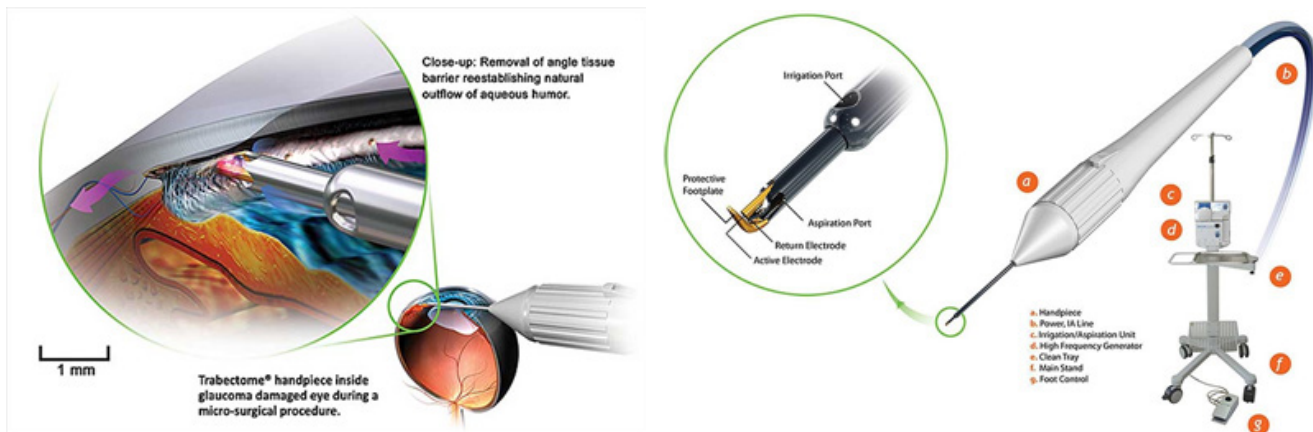


Figure 4. Trabectome Procedure, Handpiece, and Console. Source: NeoMedix Corporation, www.neomedix.net/Learning/Library/Images Images used with permission.



5a: TRAB 360 device

5b: procedure

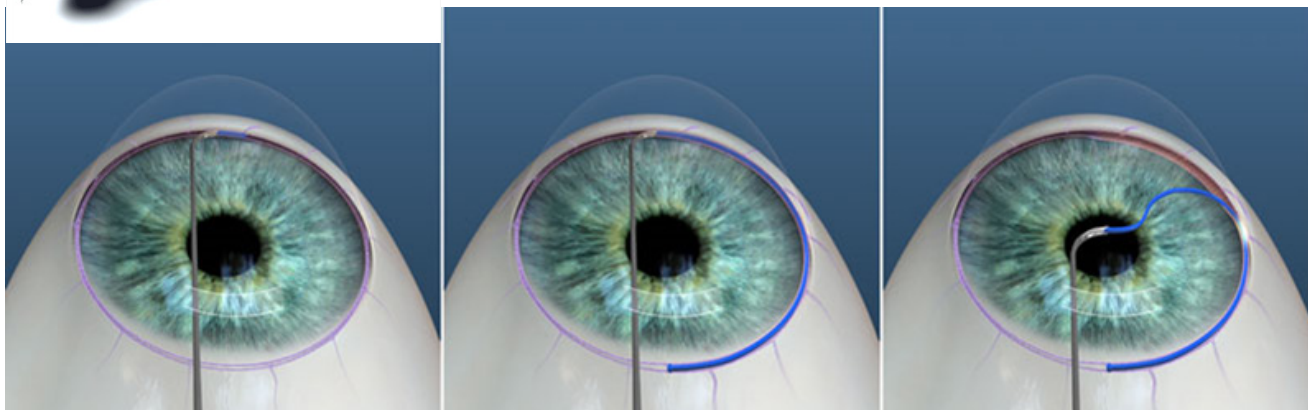


Figure 5. TRAB 360 device and procedure. Source: Sight Sciences, <http://www.sightsciences.com>

age rate of success, defined as IOP \leq 21 mmHg with 20% decrease while avoiding reoperation, after 2 years.

Trabectome alone resulted in a 10.5 ± 1.9 mmHg (39%) decrease in IOP with 0.99 ± 0.54 fewer glaucoma medications with an average success rate of 46% after 2 years.

Trabectome performed with CE resulted in a 6.24 ± 1.98 mmHg (27%) decrease in IOP with 0.76 ± 0.35 fewer glaucoma medications with an average success rate of 85% after 2 years.

The most common complications reported after trabectome were transient hyphema, peripheral anterior synechiae, corneal injury, and transient IOP spike. The rate of serious vision-threatening complications was minimal (< 1%), and these included hypotony (IOP < 5mmHg) 1 month after surgery, cyclodialysis cleft, choroidal hemorrhage, and endophthalmitis.[15]

TRAB 360 Trabeculotomy (Sight-Sciences)

TRAB 360 is a disposable, non-powered device used to perform an ab interno 360° trabeculotomy. The TRAB 360 device consists of a cannula, from which a flexible nylon-like trabeculotome is advanced into Schlemm's canal for 180 degrees (Figure 5). After the trabeculotomy is created, the trabeculotome can be retracted once and then advanced into the remainder of Schlemm's canal in the opposite direction for up to a total of 360 degrees. Like other trabeculotomy procedures, TRAB 360 is indicated for open angle glaucoma when IOP is not optimized on medical management.

Initial results from a study of the TRAB 360 device were reported by Sarkisian et al. at the 2015 American Society of Cataract and Refractive Surgery (ASCRS) Annual Meeting.[16] Surgical success, defined as IOP between

6-21 mmHg, was achieved in 25 of 30 eyes (83%) with or without glaucoma medications at the final follow-up visit. Mean IOP decreased from 19.8 ± 6.4 mmHg to 13.5 ± 4.6 at final follow up. Glaucoma medication burden was also decreased from a mean of 1.1 ± 1.2 pre-operative glaucoma medications to a mean of 0.2 ± 0.5 medications at the final visit. Mean time of follow-up was 131.5 ± 101.6 days. Transient hyphema was the most frequent postoperative complication and resolved by 1 week postoperatively in all cases.

Kahook Dual Blade (New World Medical)

The Kahook Dual Blade is a single-use, tapered, stainless steel blade used to incise and remove a nasal strip of trabecular meshwork tissue (Figure 6). After the tissue is engaged by the tapered tip, it travels up the angled ramp, where it meets two parallel blades. As the blades are advanced, this results in a ribbon of TM tissue that is separated from Schlemm's canal. Afterwards, the strip of TM is removed from the anterior chamber. Through one incision, the TM may be removed for a total of up to 180 degrees. Unlike Trabectome, there is no need for additional machinery for electrocautery, and theoretically, there is no collateral thermal damage. Currently, there are no published clinical trials on the Kahook Dual Blade. In a preclinical study of human donor corneoscleral rims, the Kahook Dual Blade showed more complete excision of TM tissue on histologic analysis with minimal damage to adjacent tissue as compared to a microvitreoretinal blade and the Trabectome (NeoMedix Inc.). In subsequent human eye perfusion studies, all devices showed significant reduction in IOP.[17] Figure 6

See video at www.kdbcert.com



Figure 6. Kahook Dual Blade and device. Source: New World Medical, Inc. Images used with permission.

Ab interno Canaloplasty

Ab interno canaloplasty (ABiC) increases aqueous outflow through cannulation of Schlemm's canal with an illuminated microcatheter (iTrack, Ellex), which is then withdrawn as an ophthalmic viscosurgical device is injected to viscodilate Schlemm's canal and the proximal collector channels. It has been theorized that viscodilation may also create microperforations within the TM to aid in aqueous outflow. As the viscoelastic is injected, blanching of episcleral vessels, which is indicative of a patent collecting system, serves as an indirect indicator of success. Indications for ABiC include mild to moderate OAG when maximal medical management and laser trabeculoplasty have failed. ABiC can be a better option for high risk monocular patients or for patients who are unable to stop anticoagulation, as ABiC minimally disrupts the TM with lower rates of hyphema. Contraindications to *ab interno* canaloplasty are similar to those of GATT (mentioned above), as proposed by Grover *et al.*[10] ABiC can be performed as a standalone procedure or in conjunction with CE.

In a retrospective review, Gallardo and Khaimi reported favorable results on 228 eyes treated with ABiC with and without CE.[18] Overall, mean preoperative IOP was 19.0 ± 6.5 mm Hg, and the mean preoperative number of glaucoma medications was 2.0 ± 1.0 . At 12 months post-operatively, mean IOP decreased 30% to 13.3 ± 2.0 mm Hg, and the mean postoperative number of glaucoma medications decreased by 50% to 1.0 ± 1.0 . The specific complications were not reported in Gallardo's and Khaimi's series, however in a case series of 20 eyes achieving similar success, there was only 1 reported complication of Descemet's detachment during injection of viscoelastic.[18] There were no reported cases of significant hyphema in either of these series.

See video at goo.gl/aAf8EX

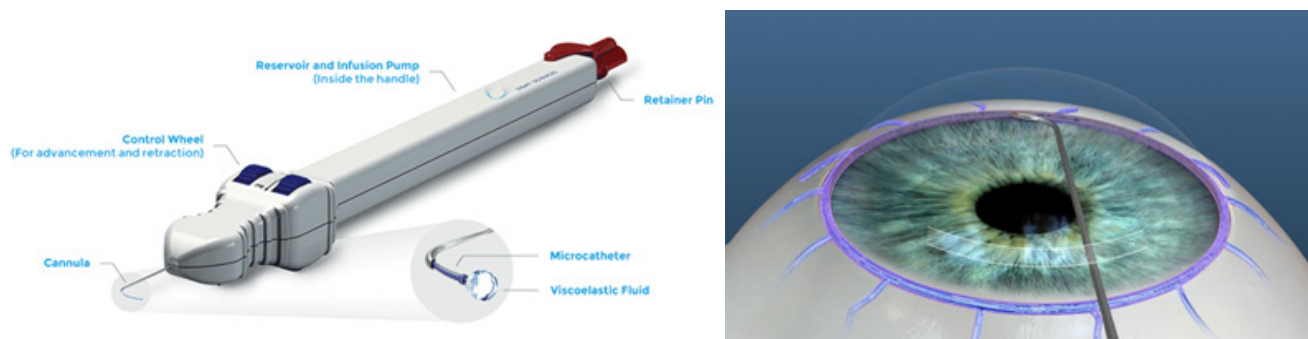


Figure 7. VISCO360 Viscosurgical System. Source: Sight Sciences, <http://www.sightosciences.com> Images used with permission.

VISCO360 Viscosurgical System (*Sight Sciences*)

VISCO360 Viscosurgical System is a device, similar to TRAB360, through which ABiC can be performed (*Figure 7*). There are no published data on the VISCO360. However, there is an ongoing multicenter, RCT evaluating the safety and effectiveness of the VISCO 360 Canaloplasty in primary OAG as compared to SLT.[19]

Hydrus Microstent (*Ivantis, Inc*)

The Hydrus Microstent improves aqueous outflow into multiple collector channel ostia by serving as an "intracanalicular scaffold" for Schlemm's canal and a bypass of the TM. The Hydrus Microstent is an 8-mm ("3 clock hours") long, crescent-shaped scaffold composed of a nickel-titanium alloy (nitinol) with windows and spines (*Figure 8*) and comes preloaded in a hand-held injector. Hydrus implantation is currently being investigated in conjunction with CE and is indicated for mild to moderate OAG.

In a prospective, multicenter RCT (HYDRUS II), 100 OAG patients were randomized to a Hydrus Microstent with CE arm and a CE alone arm. At 2 years, there was a statistically significant difference in the primary endpoint of a 20% reduction in diurnal, washed-out IOP compared to baseline. The primary endpoint was met in 80% (40/50) of patients in the Hydrus Microstent with CE arm compared to 46% (23/50) in the CE alone arm ($p = 0.001$). At 2 years, the mean reduction in IOP in the Hydrus Microstent with CE arm (9.4 mmHg) was significantly lower than in the CE alone arm (7.4 mmHg) ($p = 0.01$). There was also a statistically significant difference in mean glaucoma medications per patient after 2 years, decreasing from 2.0 ± 1.0 to 0.5 ± 1.0 medications in the Hydrus Microstent with CE arm and from 2.0 ± 1.1 to 1.0 ± 1.0 in the CE alone arm ($p = 0.02$). The proportion of patients who did not require medications after 2 years was 73% in the Hydrus Microstent with CE arm and 38% in the CE alone arm ($p = 0.001$). In this study, there was a significantly higher rate of focal peripheral anterior synechiae (PAS) in the Hydrus Microstent with CE arm at 2-years of follow-up (6/50, $p = 0.01$). However, PAS had no effect on outcomes, as IOP and medication use were similar to that in the overall Hydrus Microstent with

CE arm.[20] Other prospective, multicenter RTCs are being conducted including the HYDRUS III study, which compares the Hydrus Microstent with the iStent, and the HYDRUS IV study, which is the largest MIGS RCT, including 556 subjects with mild to moderate glaucoma.[21]

Cypass Micro-stent (*Alcon*)

The CyPass Micro-stent is a FDA-approved (2016) suprachoroidal shunt used to increase uveoscleral outflow. The CyPass device itself is a flexible, fenestrated micro-stent sized 6.35 mm x 510 μ m with a 300 μ m lumen and composed of biocompatible, polyimide material (*Figure 9*). It comes preloaded with the micro-stent on a guide-wire conformed to the shape of the sclera to facilitate dissection and insertion between the anterior chamber/sclera and suprachoroidal space. The CyPass Micro-stent is indicated for mild to moderate primary OAG.

The COMPASS Trial was a multicenter RCT including 505 subjects with mild to moderate primary OAG. Subjects were intraoperatively randomized into a CyPass Micro-stent with CE arm (374 subjects) and a CE alone arm (131 subjects).[22] At 2 years, there was a statistically significant difference in the primary endpoint, a 20% reduction in diurnal, washed-out IOP compared to baseline. This endpoint was met in 77% of the Cypass Micro-stent with CE arm compared to 60% in the CE arm ($p = 0.001$). After 2 years, the mean reduction in IOP in the Cypass Micro-stent with CE arm (7.4 mmHg) was significantly lower than in the CE arm (5.4 mmHg) ($p < 0.001$). There was also a statistically significant difference in mean glaucoma medications per patient and the proportion of patients who did not require medications after 2 years. At 2 years, patients in the Cypass Micro-stent group decreased the number of medications from a baseline of 1.4 ± 0.9 to 0.2 ± 0.6 . In the CE alone arm, medication use decreased from a baseline of 1.3 ± 1.0 to 0.6 ± 0.8 . After 2 years, 85% in the Cypass Micro-stent with CE arm and 59% in the CE alone arm did not require medications ($p < 0.001$). There were no significant differences in the rate of adverse events between the two arms. However, reported adverse events included transient BCVA loss ≥ 2 lines (8.8%), visual field loss progression (6.7%), transient iritis (8.6%), transient corneal edema (3.5%), and transient hypotony (2.9%).[22]




Figure 8. Hydrus Microstent Device. Source: Ivantis, Inc. Images used with permission.

iStent SUPRA (Glaukos Corporation)

The iStent SUPRA is a suprachoroidal stent, which is also designed to increase uveoscleral outflow. The device is a heparin-coated, 4 mm tube with a 0.16 - 0.17 mm lumen, made of polyethersulfone (PES) with a titanium sleeve. As with the original iStent, the device has retention ridges to hold the device in place (*Figure 10*). The iStent SUPRA is preloaded into an injector device, which is used to direct the device between the anterior chamber/sclera and suprachoroidal space. Placement of the iStent SUPRA can be combined with CE and is indicated for mild to moderate OAG.

Katz *et al.* conducted a prospective study of 80 subjects with moderate to advanced OAG on 2 glaucoma medications. Eighty subjects received the iStent SUPRA and travoprost postoperatively and agreed to be followed for 5 years.[23,24] After follow-up through 1 year (n=42), 98% of eyes met the primary endpoint of 20% reduction in IOP with reduction in 1 medication. The mean medicated diurnal IOP decreased from 20.4 mmHg to 12.7 mmHg at 1 year and to 11.9 mmHg at 2 years. The preoperative mean washed-out IOP was 24.8 mmHg, and after a 1 month medication wash-out at both 1 and 2 year time points, mean washed-out IOP was 16.7 mmHg and 17.0 mmHg respectively. Additionally, an IOP \leq 15 mmHg was achieved in 90% of eyes on travoprost at 2 years. Transient hypotony (IOP < 5mmHg) was observed at week one in 2 eyes, both of which resolved by 1 month. One case was associated with choroidal detachment, which resolved by 3 months. BCVA was stable or improved in all but 1 subject due to cataract progression. To gain FDA approval, Glaukos recently completed enrollment (February 2017) for a prospective RCT including 505 subjects with moderate to mild primary OAG and cataract.[25]

XEN gel stent (Allergan)

The XEN gel stent is an FDA-approved (2016) subconjunctival stent, which allows aqueous outflow from the anterior chamber into the subconjunctival space to lower IOP. It is a 6 mm tube composed of gelatin and glutaraldehyde. The implant is preloaded within a 27-gauge needle on a disposable injector. The device is inserted into the anterior chamber, passed *ab interno*, and then tunneled through sclera to deploy the device within the subconjunctival space (*Figure 10*). After implantation, the device creates a filtering bleb. It may be performed with or without adjuvant antimetabolites (mitomycin C), which in this case would be injected beneath the conjunctiva.

There are three sizes of the XEN gel stent based on lumen diameter. The XEN45 (45 μ m lumen) is the only currently FDA-approved size and is for use in patients with refractory glaucoma failing surgical treatment, primary OAG, pseudo-exfoliative, or pigmentary glaucoma with open angles that have failed maximum medical therapy.

In a multicenter, single-arm clinical trial including 65 patients, the implantation of the XEN45 gel stent resulted in a 20% reduction in mean diurnal IOP from baseline on the

same or fewer number of glaucoma medications in 76.3% of subjects at 12 months.[27] There was a decrease in IOP from a mean baseline of 25.1 ± 3.7 mmHg to 15.9 ± 5.2 mmHg. At 12 months, the mean number of glaucoma medications decreased from baseline of 3.5 ± 1.0 to 1.7 ± 1.5 . Most common adverse events included hypotony (IOP < 6 mmHg), BCVA loss \geq 2 lines (n = 4 at 12 months), and an IOP increase > 10 mmHg from baseline. The reported cases of hypotony were transient and resolved in all cases without sequelae. Six of the 17 subjects with an IOP increase > 10 mmHg from baseline had a secondary glaucoma procedure performed prior to the 12-month visit. Needling procedures were needed in 21 subjects due to a flat bleb with the absence of microcysts, fibrotic or blocked bleb filtration area, or a high risk of bleb failure as determined by investigators.

Two other sizes of the XEN gel stents (63 μ m and 140 μ m) have been studied in pilot trials, showing significant IOP reduction and achieving complete success in 29/34 (85%) patients and qualified success in 40/45 (89%) patients. However, there were high rates of eyes requiring needling with or without antifibrotics in both studies: 12/37 (32%) and 21/49 (47%) respectively. Though there were few complications, anterior chamber fill with a viscoelastic was required in 2/34 (6%) and 4/45 (9%) of subjects.[28 ,29] Antifibrotics were not used intraoperatively, but it is thought that the rate of needling would be lower if used during placement of the XEN gel stent, which is currently under study.

InnFocus Microshunt (InnFocus Inc/Santen)

The InnFocus Microshunt also allows aqueous drainage into the subconjunctival space, however it is placed using an *ab externo* approach. The device is 8.5 mm x 0.350 mm with a 70 μ m lumen and composed of SIBS [poly(-styrene-block-isobutylene-block-styrene)] material which regulates aqueous flow (*Figure 12*). After making a small conjunctival peritomy, a needle is used to create a small scleral pocket, within which a smaller needle enters the anterior chamber. The device is then implanted and allows aqueous humor to drain from the anterior chamber into sub-Tenon's space to form a bleb. As in trabeculectomy, mitomycin C is routinely placed in the area of the intended bleb. InnFocus Microshunt implantation may be performed with or without CE. The InnFocus Microshunt is not yet FDA-approved, but is indicated for the treatment of mild, moderate, or severe OAG.

Few published studies have evaluated the InnFocus Microshunt, but clinical trials are being conducted to obtain FDA approval.[30] In a prospective, observational study of 23 eyes having failed maximal medical therapy, 14 eyes received the InnFocus Microshunt and 9 eyes received InnFocus Microshunt in conjunction with CE.[31] After 3 years of follow-up (n = 22), the qualified rate of success, defined as IOP \leq 14 mm Hg and IOP reduction \geq 20%, was 95%. IOP decreased from 23.8 ± 5.3 mmHg to 10.7 ± 3.5 mmHg, and the mean number of glaucoma medications de-

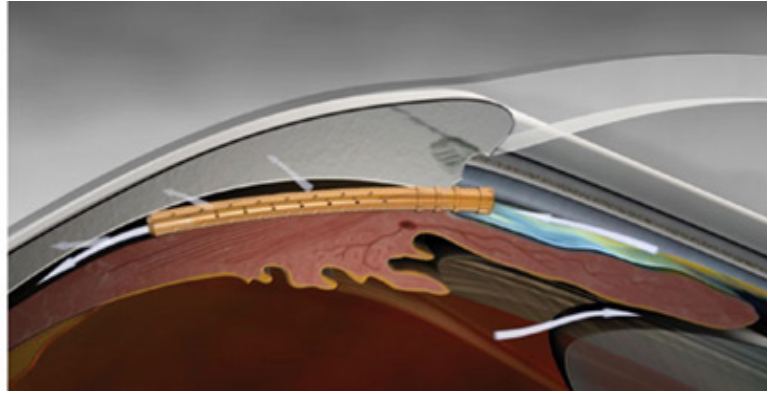


Figure 9. A) CyPass Micro-stent device. B) CyPass Micro-stent device inserted into suprachoroidal space. Source: Alcon. Images used with permission

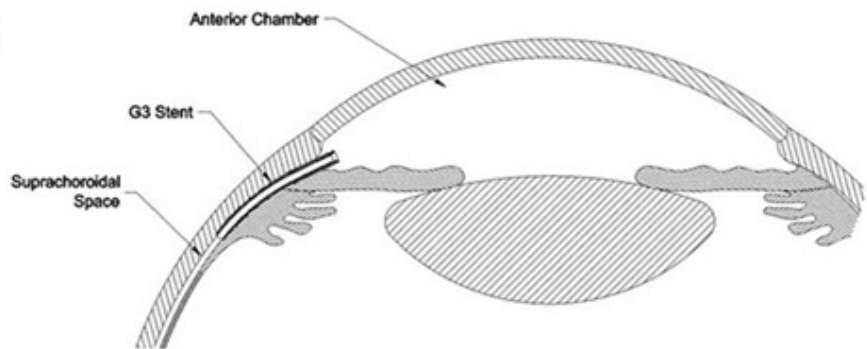


Figure 10. A) iStent SUPRA device. B) iStent SUPRA inserted into suprachoroidal space. Source: Surgical Innovations in Glaucoma. Springer[26] Images used with permission from Springer-Verlag, New York

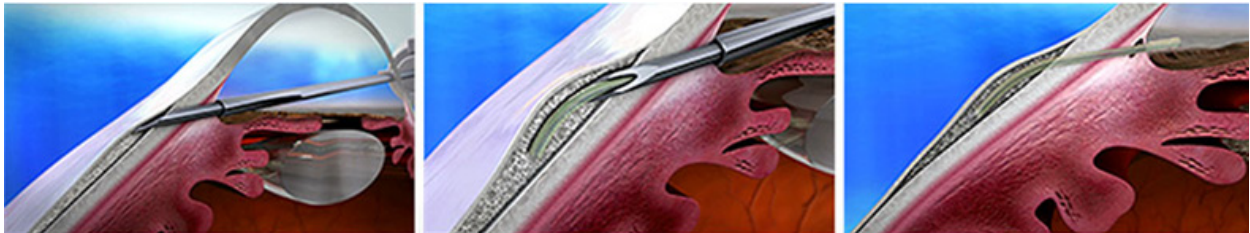


Figure 11. Insertion of the XEN Gel Shunt into Subconjunctival Space. Source: www.aquesys.com/xen Images used with permission.

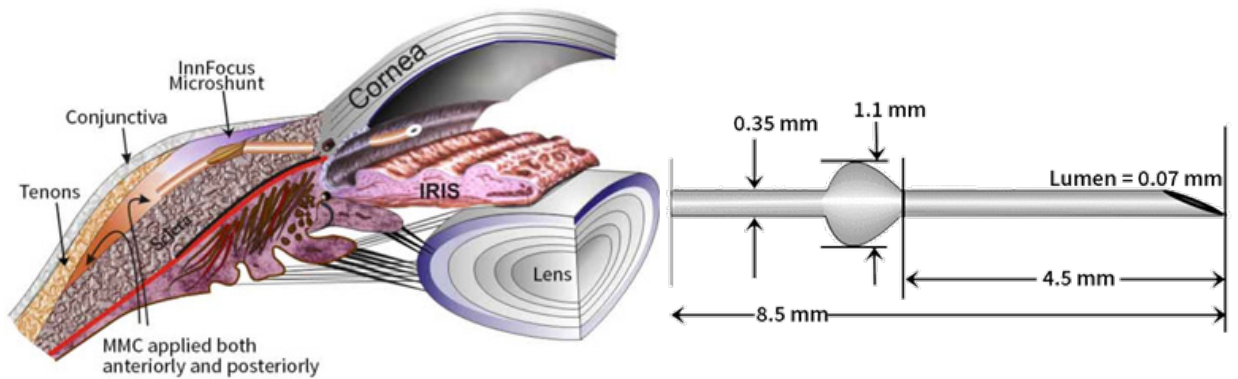


Figure 12. InnFocus Microshunt implanted between subconjunctival space and anterior chamber. Image used with permission from InnFocus, Inc.[30]

creased from 2.4 ± 0.9 to 0.7 ± 1.1 . Reported complications included transient hypotony in 3 patients and transient choroidal effusion in 2 patients, all of which spontaneously resolved by week 3 and week 12, respectively. Additionally, 3 patient

Endocyclophotocoagulation ECP (Endo Optiks Inc)

Endocyclophotocoagulation (ECP) consists of cyclodestruction of the ciliary body epithelium to reduce aqueous production and therefore IOP. The ECP probe is reusable device, which includes a laser source, camera, and light source. After it is introduced into the anterior chamber, the probe can then be directed towards the anterior ciliary processes to deliver precise continuous energy (810 nm wavelength) for successful photocoagulation, visualized as localized shrinkage and whitening of the processes (*Figure 13*). Through a single corneal incision, approximately 240 to 300 degrees of the ciliary processes can be treated, but incisions are needed for a 360-degree treatment. As expected, the greater the amount of processes treated, the greater the reduction in IOP and need for glaucoma medications.[32]

Excessive energy or overtreatment results in eruption of ciliary processes and may be accompanied by a "popping" sound. ECP induces an inflammatory response, and steroids (intravenous or oral) are often helpful to suppress inflammation and reduced IOP spikes. ECP may be utilized in many types of glaucoma (open or closed angle), includ-

ing pediatric glaucoma.[33] ECP may be used as an initial management option for mild to moderate glaucoma or for patients with advanced glaucoma that have failed previous management.[34] ECP can be performed with or without CE but is better suited for pseudophakic or aphakic eyes, as ECP can lead to cataract and zonular damage.

In a recent, non-randomized prospective study, Francis et al. showed ECP with CE to be effective in decreasing IOP and medication burden, compared to CE alone in a group of 160 consecutive patients with medically-controlled OAG. [35] The rate of success, defined as IOP 5 - 21 mmHg and reduction in glaucoma medications without a rise in IOP, was significantly higher in the ECP with CE group compared to the CE alone group after 3 years ($p < 0.01$). Similarly, IOP and required glaucoma medications were significantly lower in the ECP with CE group as compared to the CE alone group. After 2 years, the mean IOP in the ECP with CE group ($n = 80$) decreased from baseline of 18.1 ± 3.0 mmHg to 16.0 ± 3.3 mmHg on fewer glaucoma medications (1.5 ± 0.8 to 0.4 ± 0.7), and the mean IOP decreased from 18.1 ± 3.0 mmHg to 17.3 ± 3.2 mmHg on fewer glaucoma medications (2.4 ± 1.0 to 2.0 ± 1.0) in the control group ($n = 80$). Reported adverse events included hyphema, inflammation, and IOP spike. Smaller, prospective studies have also shown ECP to be comparable to traditional incisional glaucoma surgeries with fewer complications.[36 ,37]

Also see Endocyclophotocoagulation video, at www.endooptiks.com/video/BasicECP.mp4

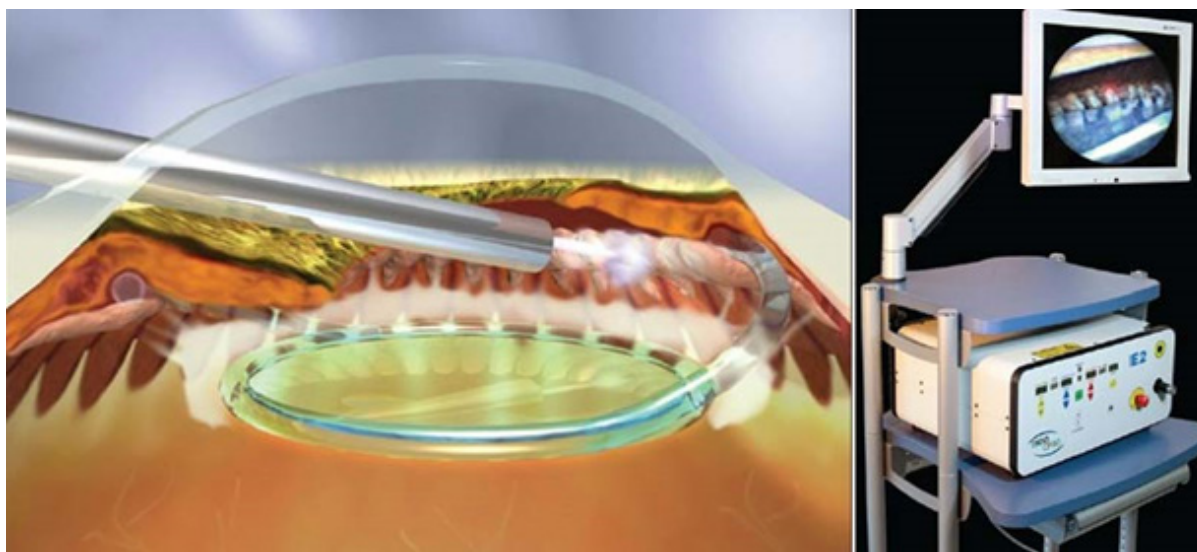


Figure 13. Endocyclophotocoagulation. ECP probe in ciliary sulcus space delivering energy to ciliary processes. Video screen of cryophotocoagulated ciliary processes after ECP procedure. Images used with permission. Source: Beaver Visitec, Int'l, Inc.

Cost of MIGS

One study conducted by Iordanous *et al.* compared the cost of Trabectome, iStent, and ECP to glaucoma medications in the Ontario Health Insurance Plan.[38] Though physician fees and start up costs were not included for each MIGS device, the cumulative cost savings of successful Trabectome, iStent, and ECP procedures as compared to mono-drug, bi-drug, and tri-drug therapy were shown

to be modest over a 6 year period (*Figure 14*). Trabectome had the greatest cost savings, followed by ECP, and then iStent. While glaucoma management can be a financial burden, many other factors, such as effectiveness, safety, quality of life, or compliance, must be further considered as well. As MIGS are further developed and more widely used, more evidence and long-term follow-up will allow further study of cost-effectiveness.

Table 2: Relative effectiveness of MIGS Procedures based on decrease in IOP and decrease in medications for selected studies. Note *Combined procedure MIGS with cataract extraction **Mean follow up.

MIGS Procedure	Decrease in IOP	Decrease in Medications	Study Type
iStent Micro-Bypass* [7]	8.4 mmHg @ 2 years	0.8 @ 2 years	Randomized controlled trial
iStent Inject [9]	8.1 mmHg @ 1 year	Not available	Prospective, randomized trial
Gonioscopy-assisted transluminal trabeculotomy (GATT)* [10]	8.4 mmHg @ 1 year	1.9 @ 1 year	Retrospective review
Trabectome* [15]	6.2 mmHg @ 2 years	0.76 @ 2 years	Meta-analysis
TRAB 360 Trabeculotomy [16]	6.3 mmHg @ 131.5 days**	0.9 @ 131.5 days**	Retrospective review
Ab interno canaloplasty* [18]	4.0 mmHg @ 1 year	1.0 @ 1 year	Case-series review
Hydrus Microstent* [20]	9.4 mmHg @ 2 years	1.5 @ 2 years	Randomized controlled trial
CyPass Micro-Stent* [22]	7.4 mmHg @ 2 years	1.2 @ 2 years	Randomized controlled trial
iStent Supra [23 ,24]	7.8 mmHg @ 2 years	Not available	Prospective, single arm clinical trial
XEN Glaucoma Treatment System [27]	9.2 mmHg @ 1 year	1.8 @ 1 year	Prospective, single arm clinical trial
InnFocus MicroShunt* [31]	16.2 mmHg @ 3 years	1.6 @ 3 years	Prospective, single arm clinical trial
Endocyclophotocoagulation* [35]	2.1 mmHg @ 2 years	1.1 @ 2 years	Prospective case-control study

Table 3: Cumulative 6-Year Cost Comparison of Trabectome, iStent, and ECP versus Mono-drug, Bi-drug, and Tri-drug Therapy. Adapted from Journal of Glaucoma. 23(2):e112-e118, 2014.[38]

Cumulative Cost Per Patient (Canadian Dollar \$, 2014)						
	1 year	2 year	3 year	4 year	5 year	6 year
Trabectome	744.00	744.00	744.00	744.00	744.00	744.00
iStent	1044.00	1044.00	1044.00	1044.00	1044.00	1044.00
Endoscopic Photocoagulation	244.00	244.00	244.00	244.00	244.00	244.00
Medical Therapy						
Mono-drug	170.54	341.08	511.61	682.15	852.69	1023.23
Bi-drug	386.09	772.18	1158.28	1544.37	1930.46	2316.55
Tri-drug	528.12	1056.24	1584.36	2112.48	2640.60	3168.71

Conclusion

MIGS is a relatively new category of procedures with a limited number of studies showing largely acceptable safety profiles and modest efficacy. While MIGS surgeries currently appear unlikely to supplant traditional incisional glaucoma surgeries, they fill an important gap between medical therapy and incisional surgery for mild to moderate glaucoma and can often mitigate medication burden. As the area of MIGS continues to evolve, more rigorous studies with longer follow-up will increase our understanding of the full efficacy and safety of MIGS procedures.

DISCLAIMER: EyeRounds editorial board members, the authors, and the University of Iowa do not recommend or endorse any specific tests, drugs, devices, products, services, physicians, or medical institutions that may be mentioned or referenced on this web site. Manufacturers of products and procedures mentioned have no influence on the editorial content or presentation and such content does not imply or express endorsements of any product, service, or company.

References

1. Tham YC, Li X, Wong TY, Quigley HA, Aung T, Cheng CY. Global prevalence of glaucoma and projections of glaucoma burden through 2040: a systematic review and meta-analysis. *Ophthalmology* 2014;121(11):2081-2090. [PubMed.gov/24974815](http://pubmed.gov/24974815)
2. Leahy KE, White AJ. Selective laser trabeculoplasty: current perspectives. *Clin Ophthalmol* 2015;9:833-841. [PubMed.gov/26005327](http://pubmed.gov/26005327)
3. Gedde SJ, Schiffman JC, Feuer WJ, Herndon LW, Brandt JD, Budenz DL, Tube versus Trabeculectomy Study G. Treatment outcomes in the Tube Versus Trabeculectomy (TVT) study after five years of follow-up. *Am J Ophthalmol* 2012;153(5):789-803 e782. [PubMed.gov/22245458](http://pubmed.gov/22245458)
4. Gedde SJ, Herndon LW, Brandt JD, Budenz DL, Feuer WJ, Schiffman JC, Tube Versus Trabeculectomy Study G. Postoperative complications in the Tube Versus Trabeculectomy (TVT) study during five years of follow-up. *Am J Ophthalmol* 2012;153(5):804-814 e801. [PubMed.gov/22244522](http://pubmed.gov/22244522)
5. Saheb H, Ahmed, II. Micro-invasive glaucoma surgery: current perspectives and future directions. *Curr Opin Ophthalmol* 2012;23(2):96-104. [PubMed.gov/22249233](http://pubmed.gov/22249233)
6. Samuelson TW, Katz LJ, Wells JM, Duh YJ, Giamporcaro JE, Group USIS. Randomized evaluation of the trabecular micro-bypass stent with phacoemulsification in patients with glaucoma and cataract. *Ophthalmology* 2011;118(3):459-467. [PubMed.gov/20828829](http://pubmed.gov/20828829)
7. Craven ER, Katz LJ, Wells JM, Giamporcaro JE, iStent Study G. Cataract surgery with trabecular micro-bypass stent implantation in patients with mild-to-moderate open-angle glaucoma and cataract: two-year follow-up. *J Cataract Refract Surg* 2012;38(8):1339-1345. [PubMed.gov/22814041](http://pubmed.gov/22814041)
8. Belovay GW, Naqi A, Chan BJ, Rateb M, Ahmed, II. Using multiple trabecular micro-bypass stents in cataract patients to treat open-angle glaucoma. *J Cataract Refract Surg* 2012;38(11):1911-1917. [PubMed.gov/22980724](http://pubmed.gov/22980724)
9. Fea AM, Belda JL, Rekas M, Junemann A, Chang L, Pablo L, Voskanyan L, Katz LJ. Prospective unmasked randomized evaluation of the iStent inject ((R)) versus two ocular hypotensive agents in patients with primary open-angle glaucoma. *Clin Ophthalmol* 2014;8:875-882. [PubMed.gov/24855336](http://pubmed.gov/24855336)
10. Grover DS, Godfrey DG, Smith O, Feuer WJ, Montes de Oca I, Fellman RL. Gonioscopy-assisted transluminal trabeculotomy, ab interno trabeculotomy: technique report and preliminary results. *Ophthalmology* 2014;121(4):855-861. [PubMed.gov/24412282](http://pubmed.gov/24412282)
11. Grover DS, Smith O, Fellman RL, Godfrey DG, Butler MR, Montes de Oca I, Feuer WJ. Gonioscopy assisted transluminal trabeculotomy: an ab interno circumferential trabeculotomy for the treatment of primary congenital glaucoma and juvenile open angle glaucoma. *Br J Ophthalmol* 2015;99(8):1092-1096. [PubMed.gov/25677669](http://pubmed.gov/25677669)
12. Bussell II, Kaplowitz K, Schuman JS, Loewen NA, Trabectome Study Group. Outcomes of ab interno trabeculectomy with the trabectome by degree of angle opening. *Br J Ophthalmol* 2015;99(7):914-919. [PubMed.gov/25336577](http://pubmed.gov/25336577)
13. Ting JL, Damji KF, Stiles MC, Trabectome Study G. Ab interno trabeculectomy: outcomes in exfoliation versus primary open-angle glaucoma. *J Cataract Refract Surg* 2012;38(2):315-323. [PubMed.gov/22322166](http://pubmed.gov/22322166)
14. Bussell, II, Kaplowitz K, Schuman JS, Loewen NA, Trabectome Study G. Outcomes of ab interno trabeculectomy with the trabectome after failed trabeculectomy. *Br J Ophthalmol* 2015;99(2):258-262. [PubMed.gov/25170064](http://pubmed.gov/25170064)
15. Kaplowitz K, Bussell, II, Honkanen R, Schuman JS, Loewen NA. Review and meta-analysis of ab-interno trabeculectomy outcomes. *Br J Ophthalmol* 2016;100(5):594-600. [PubMed.gov/26733487](http://pubmed.gov/26733487)
16. Sarkisian SR, Allan EJ, Ding K, Dvorak J, Badawi DY. New Way for Ab Interno Trabeculotomy: Initial Results [poster]. ASCRS ASOA Symposium and Congress; 17-21 April 2015; San Diego, CA. ascrs.confex.com/ascrs/15am/webprogram/Paper15533.html
17. Seibold LK, Soohoo JR, Ammar DA, Kahook MY. Preclinical investigation of ab interno trabeculectomy using a novel dual-blade device. *Am*

- J Ophthalmol* 2013;155(3):524-529 e522. [PubMed.gov/23218696](#)
18. Ellex iScience. Ab-Interno Canaloplasty: A Comprehensive Minimally Invasive Glaucoma Surgery That Keeps Its Promise: 12 month case series review, 2016. [Last rev.; accessed on 13 Sept. 2017] www.ellex.com/wp-content/uploads/sites/9/ABiC-Whitepaper-12-Months-1.pdf
 19. U.S. National Institutes of Health. Randomized Study of the Safety and Effectiveness of the Sight Sciences VISCO™360 Viscosurgical System Versus SLT in Primary Open Angle Glaucoma (VISCO360 Study). Bethesda, MD: ClinicalTrials.gov, 2016. [Last rev. on 25 July 2017; accessed on 18 Sept. 2017] www.clinicaltrials.gov/ct2/show/NCT02928289
 20. Pfeiffer N, Garcia-Feijoo J, Martinez-de-la-Casa JM, Larrosa JM, Fea A, Lemij H, Gandolfi S, Schwenn O, Lorenz K, Samuelson TW. A Randomized Trial of a Schlemm's Canal Microstent with Phacoemulsification for Reducing Intraocular Pressure in Open-Angle Glaucoma. *Ophthalmology* 2015;122(7):1283-1293. [PubMed.gov/25972254](#)
 21. U.S. National Institutes of Health. Safety & Effectiveness Study of the Hydrus Device for Lowering IOP in Glaucoma Patients Undergoing Cataract Surgery. Bethesda, MD: ClinicalTrials.gov, 2016. [Last rev. on 5 Sept. 2017; accessed on 18 Sept. 2017] www.clinicaltrials.gov/ct2/show/NCT02928289
 22. Vold S, Ahmed, II, Craven ER, Mattox C, Stamper R, Packer M, Brown RH, Ianchulev T, CyPass Study G. Two-Year COMPASS Trial Results: Supraciliary Microstenting with Phacoemulsification in Patients with Open-Angle Glaucoma and Cataracts. *Ophthalmology* 2016;123(10):2103-2112. [PubMed.gov/27506486](#)
 23. Myers JS, Katz LJ. Results of suprachoroidal stent and topical travoprost for reduction of IOP and medication in open-angle glaucoma [Abstract]. Annual Meeting Program and Abstract Book. The 24th Annual AGS Meeting; February 27, 2014; Washington, DC., p. 70; 2014
 24. Emerick GT. Highlights of the AGS Annual Meeting: The latest research findings from the 24th annual meeting of the American Glaucoma Society, held February 26th to March 2nd. *Glaucoma Today* 2014, glaucomatoday.com/pdfs/gt0314_rsrch.pdf. (March/April):10-11
 25. Glaukos Corp. Glaukos Completes Patient Enrollment in Pivotal Phase of U.S. IDE Clinical Trial for iStent SUPRA®. [Press Release Feb. 16, 2017]. San Clemente, CA: Business Wire, 2017. www.businesswire.com/news/home/20170216005253/en/
 26. Hill RA, Haffner D, Voskanyan L. The iStent® MIGS Family: iStent®, iStent Inject®, and iStent Supra® In: Samples JR, Ahmed IIK, editors. *Surgical Innovations in Glaucoma*. New York: Springer-Verlag; 2014; p. 147-156.
 27. Allergan Inc. Directions for use for the XEN Glaucoma Treatment System: Allergan, Inc., 2017. [Last rev. on Feb. 2017; accessed on March 6 2017] allergan-web-cdn-prod.azureedge.net/actavis/actavis/media/allergan-pdf-documents/labeling/xen/dfu_xen_glaucoma_treatment_system_us_feb2017.pdf
 28. Sheybani A, Dick HB, Ahmed, II. Early Clinical Results of a Novel Ab Interno Gel Stent for the Surgical Treatment of Open-angle Glaucoma. *J Glaucoma* 2016;25(7):e691-696. [PubMed.gov/26561420](#)
 29. Sheybani A, Lenzhofer M, Hohensinn M, Reitsamer H, Ahmed, II. Phacoemulsification combined with a new ab interno gel stent to treat open-angle glaucoma: Pilot study. *J Cataract Refract Surg* 2015;41(9):1905-1909. [PubMed.gov/26482822](#)
 30. InnFocus Inc. FDA Approves InnFocus Glaucoma Study Expansion: Final Clinical Testing Phase to BEgin. [Press Release Nov. 10, 2015]: CISION, 2015. www.prnewswire.com/news-releases/fda-approves-innfocus-glaucoma-study-expansion-300175743.html
 31. Batlle JF, Fantes F, Riss I, Pinchuk L, Alburquerque R, Kato YP, Arrieta E, Peralta AC, Palmberg P, Parrish RK, 2nd, Weber BA, Parel JM. Three-Year Follow-up of a Novel Aqueous Humor MicroShunt. *J Glaucoma* 2016;25(2):e58-65. [PubMed.gov/26766400](#)
 32. Kahook MY, Lathrop KL, Noecker RJ. One-site versus two-site endoscopic cyclophotocoagulation. *J Glaucoma* 2007;16(6):527-530. [PubMed.gov/17873713](#)
 33. Carter BC, Plager DA, Neely DE, Sprunger DT, Sondhi N, Roberts GJ. Endoscopic diode laser cyclophotocoagulation in the management of aphakic and pseudophakic glaucoma in children. *J AAPOS* 2007;11(1):34-40. [PubMed.gov/17307681](#)
 34. Chen J, Cohn RA, Lin SC, Cortes AE, Alvarado JA. Endoscopic photocoagulation of the ciliary body for treatment of refractory glaucomas. *Am J Ophthalmol* 1997;124(6):787-796. [PubMed.gov/9402825](#)
 35. Francis BA, Berke SJ, Dustin L, Noecker R. Endoscopic cyclophotocoagulation combined with phacoemulsification versus phacoemulsification alone in medically controlled glaucoma. *J Cataract Refract Surg* 2014;40(8):1313-1321. [PubMed.gov/25088629](#)
 36. Lima FE, Magacho L, Carvalho DM, Susanna R, Jr., Avila MP. A prospective, comparative study between endoscopic cyclophotocoagulation and the Ahmed drainage implant in refractory glaucoma. *J Glaucoma* 2004;13(3):233-237. [PubMed.gov/15118469](#)
 37. Gayton JL, Van Der Karr M, Sanders V. Combined cataract and glaucoma surgery: trabeculectomy versus endoscopic laser cycloablation. *J Cataract Refract Surg* 1999;25(9):1214-1219. [PubMed.gov/10476504](#)
 38. Iordanous Y, Kent JS, Hutnik CM, Malvankar-Mehta MS. Projected cost comparison of Trabectome, iStent, and endoscopic cyclophotocoagulation versus glaucoma medication in the Ontario Health Insurance Plan. *J Glaucoma* 2014;23(2):e112-118. [PubMed.gov/23807348](#)

Suggested Citation Format

Fox AR, Risma TB, Kam JP, Bettis DI. MIGS: Minimally Invasive Glaucoma Surgery. EyeRounds.org. posted September 27, 2017; Available from: EyeRounds.org/tutorials/MIGS/

last updated: 09/27/2017

Tutorials

Neuro-Ophthalmology

Visual Field Testing: A basic tutorial

Joy N. Carroll and Chris A. Johnson, Ph.D.

August 22, 2013

Introduction: Components of Vision

Vision is a combination of distinct measurable functions: visual acuity, color vision, vernier (alignment) acuity, the perception of movement and change in luminous intensity (flicker) or differences in luminous intensity (contrast). Visual acuity is the ability to determine fine detail and distinguish one object from another. Acuity is tested with vision charts of letters or images.

Changes in luminous intensity are perceived as flicker, and the difference in luminous intensity from one object to another is perceived as contrast [1]. The visual field encompasses the entire region of space seen while gaze is directed at any central object. This tutorial explains visual field testing.

The Visual Field

Under normal daylight (photopic) conditions, the smallest or least intense visible objects are only seen in the central region of the visual field. In the periphery, objects must be larger or more intense to be identified. A normal visual field extends approximately 100° temporally (laterally), 60° nasally, 60° superiorly, and 70° inferiorly [2]. A physiologic scotoma (a blind spot) exists at 15° temporally where the optic nerve leaves the eye. Definitive location varies slightly on an individual basis. The average blind spot is 7.5° in diameter, vertically centered 1.5° below the horizontal meridian [3]. See figure 1. For dim night lighting (scotopic) conditions, the mid periphery is the most sensitive region of the visual field.

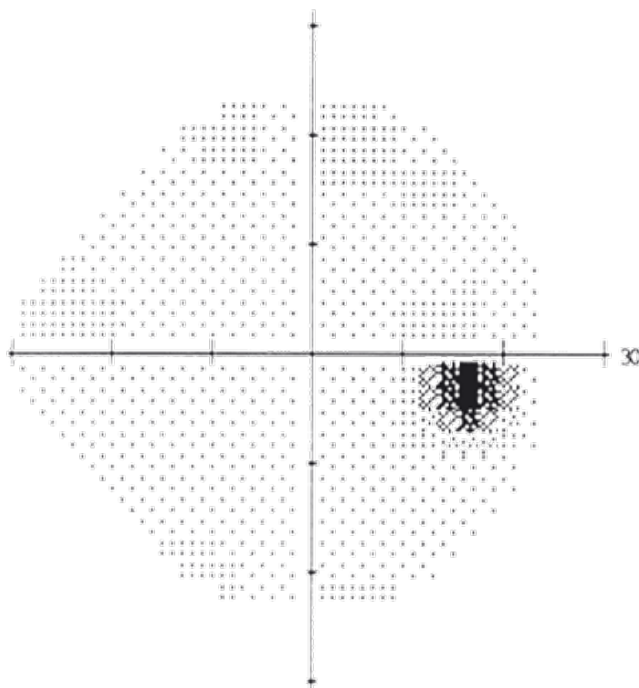


Figure 1: Physiologic scotoma. The scotoma is the area of increased pixilation, indicating decreased visual acuity.

Anatomy & Physiology

The visual field corresponds to the topographic arrangement of photoreceptors in the eye. When photons of light are absorbed by the photoreceptor cells of the retina, a cis-trans isomerization of 11-cis chromophore begins the phototransduction cascade, resulting in hyperpolarization of bipolar and horizontal cells, and ultimately activation of ganglion cells, which form the nerve fiber layer [4]. The nerve fibers travel to the optic nerve head, where the optic nerve originates. At the optic nerve head (also known as the optic disc), there are no photoreceptors, only nerve fibers. This region corresponds to the physiologic scotoma.

The highest density of cone (photopic) photoreceptors is located in the macula. The ganglion cell axons which ultimately join to form the optic nerve travel horizontally as the papillomacular bundle from the macula to the temporal aspect of the optic disc. The nerve fibers respect the median raphe along the horizontal meridian. The ganglion cells originating temporal to the macula must also travel to the optic disc without crossing the median raphe. To do so they must arc around the papillomacular bundle, forming the appropriately named arcuate fibers. Ganglion cells originating in the areas of the retina nasal to the disc do not have to arc around the macula. They are therefore oriented radially, making a fairly straight path to the optic nerve. Visual field defects resulting from ganglion cell loss, such as those from glaucoma, correspond to these anatomical patterns.

It is important to note that visual field coordinates are the opposite of retinal coordinates. Light entering the eye from the temporal visual field is detected by photoreceptors on

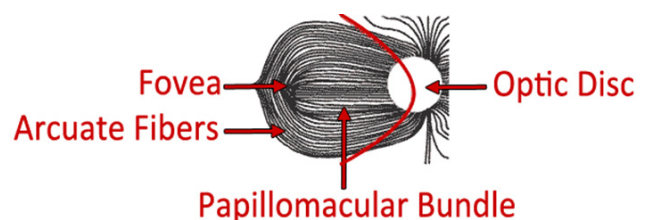


Figure 2: Ganglion Cell Pathways

the nasal side of the retina and light entering from the nasal visual field is detected by the temporal photoreceptors. Similarly, light from the superior visual field is absorbed in the inferior retina and vice versa. Therefore, a patient with injury to the ganglion cells in the temporal retina would be predicted to have a nasal visual field defect.

Rays of Light on the Retina

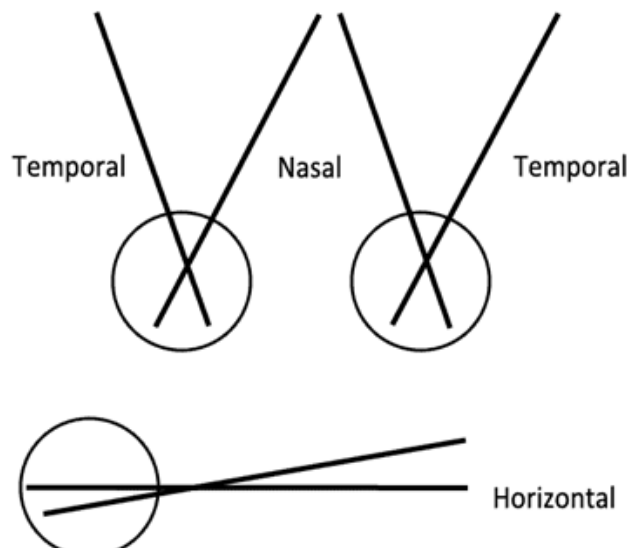


Figure 3: Light Paths to the Retina. Light originating superior to the eye is detected by the inferior retina. Light originating temporal to the eye is detected by the nasal aspect of the retina.

History

Recognition of the visual field extends back more than 2,000 years to the time of Hippocrates, who recognized a hemianopsia [5]. Visual fields are frequently evaluated by simply covering one eye and asking the patient to look straight ahead while using peripheral vision to identify an object, or the number of fingers shown by the examiner. The field is often tested at only four locations, which is sensitive only for large field defects. This method of testing is referred to as **confrontation visual field evaluation**.

Quantification of visual fields was developed during the nineteenth century. Jannik Bjerrum began mapping visual fields by asking patients to identify whether a white object on the end of a black stick, in front of a black screen, was seen. Several targets of varying sizes on the wand were tested, effectively mapping the variation in size required for vision in different areas of the field. This method of testing, known as the tangent screen, only measures the central 30° of the visual field [5].

The Amsler grid is another tool for measuring the central visual field occupied by the macula (approximately 8 degrees in diameter). The test consists of a card with horizontal and vertical black lines intersecting on a white background, held at a distance of 25 cm or 40 cm. While fixing gaze on a point in the center of the grid, areas that are

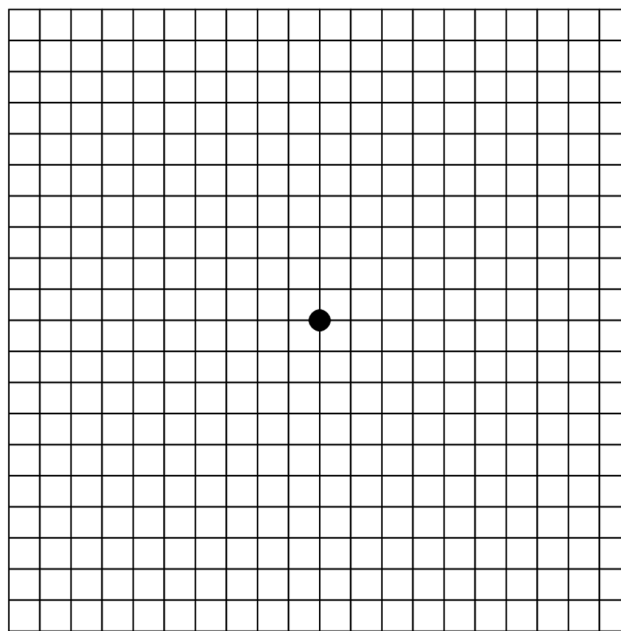


Figure 4: Amsler grid

blurry, absent, or distorted are identified by the patient. Central vision corresponds with the macula, hence the use of Amsler grids to follow macular pathology clinically [5].

Kinetic and Static Perimetry

A method of testing the complete visual field was developed by Hans Goldmann. His bowl-shaped perimeter uses bright light as targets superimposed on a white background. Targets may vary in size, luminance, and color. Goldmann perimetry requires trained perimetrists to measure and draw the visual field. Challenges include cost and inter-perimetrist variability [5]. In practice, Goldmann perimetry is a form of kinetic perimetry: a stimulus is *moved* from beyond the edge of the visual field into the field. The location at which the stimulus is first seen marks the outer perimeter of the visual field for the size of the stimulus tested.

Automated perimetry was developed in the 1970s. As the name suggests, automated perimetry maps a visual field with the aid of a computer. The Octopus perimeter, the Humphrey Field Analyzer, and Humphrey Matrix are a few of the available automated perimeters. Although the Octopus can perform a modified kinetic perimetry, most automated perimetry is static: *stationary* stimuli, varying in size and intensity, are presented in specific locations within the visual field [6].

Humphrey Visual Field Test

Several basic conditions must be met for a successful map of the visual field to be produced by any method. The individual must be able to maintain a constant gaze toward a fixed location for several minutes. Each eye is tested separately while the opposite eye is covered with

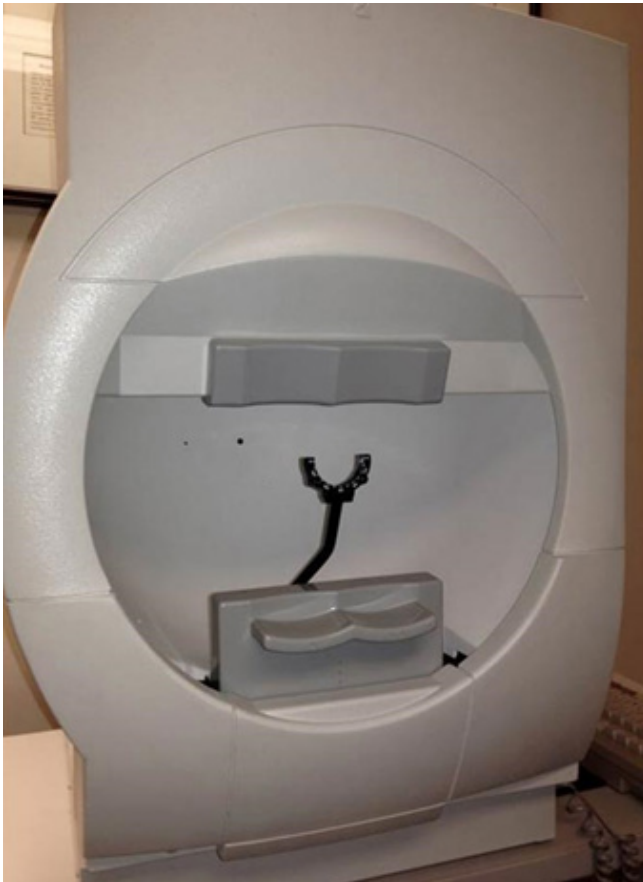

Figure 5: Humphrey Visual Field Analyzer

a patch. Refractive correction must be made with a test lens. Spectacles must not be worn because they can cause false defects in the visual field due to their shape [6]. In addition, correction must be made for presbyopia, to reduce accommodative strain. Standard adjustments for presbyopia are available based on age alone. To correct an astigmatism >0.75 diopters, a cylindrical lens must be used. If the eyelid or lashes obstruct the visual axis, the lid may be taped to the forehead to lift it out of the way.

During Humphrey Visual Field (HVF) testing, the patient places his head in the chinrest and fixes his gaze toward a central fixation point in a large, white bowl. As stated above, this test is an example of static perimetry. It assesses the ability to see a non-mobile stimulus which remains for a brief moment (200 ms) in the visual field. When the patient sees a presented stimulus, he presses the button on a handheld remote control. Different locations within a given region of the visual field are tested until the threshold, or the stimulus intensity seen 50% of the time, is seen at each test location.

Stimuli vary in size and luminous intensity. Goldmann size III (about $\frac{1}{2}$ degree in diameter) is generally used, but Goldmann size V (approximately 2 degrees in diameter) is available for patients with decreased visual acuity ($<20/200$) or other visual impairment. Goldmann sizes I, II, and III are rarely used clinically. The luminous intensity of the stimuli can be varied over a range of 0.08 to 10,000 apostilbs (asb). It is reported in decibels (dB) of attenu-

ation, or dimming, extending from 0 dB (the brightest, unattenuated stimulus) to 51 dB (the dimmest, maximally attenuated stimulus). If the patient is unable to see even the brightest, unattenuated stimulus, it is reported as <0 dB.

The Swedish Interactive Thresholding Algorithm (SITA) is frequently used. SITA is a forecasting procedure that uses Bayesian statistical properties that is similar to the methods used for providing weather information and predictions. SITA allows for more rapid analysis than would be possible without forecasting. By taking into account a user's results in nearby locations, stimuli that are unlikely to be seen, or extremely likely to be seen are not tested exhaustively. Instead the stimuli that are likely near threshold are tested.

Reading the Humphrey Visual Field Printout

All of the information provided on the visual field printout is important. Patient identity information and the specific test and stimulus size are located near the top of the analysis. It is important to verify that the patient's birthdate was properly entered as an error will result in comparisons with normal individuals in the wrong age group.

Beneath the patient's name is a statement giving information about the testing parameters, such as "Central 24-2 Threshold Test." The first statement, "Central 24" indicates that the central 24 degrees of visual field were analyzed. The next number indicates how the grid of points is aligned to the visual axis. The number "1" indicates that the middle points are overlying the horizontal and vertical meridians. The number "2" indicates that the grid of points straddles these meridians. This is the setting most commonly used, as it is easier to assess whether visual field defects respect the horizontal or vertical midline.

Next on the report are the reliability indices, including fixation losses, false positives, and false negatives. Fixation losses occur when the patient reports seeing a stimulus that is presented in the predicted area of the physiologic blind spot. False positives occur when a patient presses the button when no stimulus is presented. Eager-to-please participants sometimes struggle with high false positive rates (i.e., they are "trigger happy"). False positives can often be corrected by providing a simple statement that many stimuli will not be seen even with normal vision. False negatives occur when a patient fails to see a significantly brighter stimulus at a location than was previously seen. False negatives are usually the result of attention lapses or fatigue and are difficult to correct.

The visual threshold is the intensity of stimulus seen 50% of the time at each location. The threshold values of each tested point are listed in decibels in the sensitivity plot. Higher numbers mean the patient was able to see a more attenuated light, and thus has more sensitive vision at that location. To the right of the numerical sensitivity plot is the grayscale map. This map presents sensitivity across the patient's visual field with lighter regions indicating higher sensitivity and darker regions reflecting lower sensitivi-

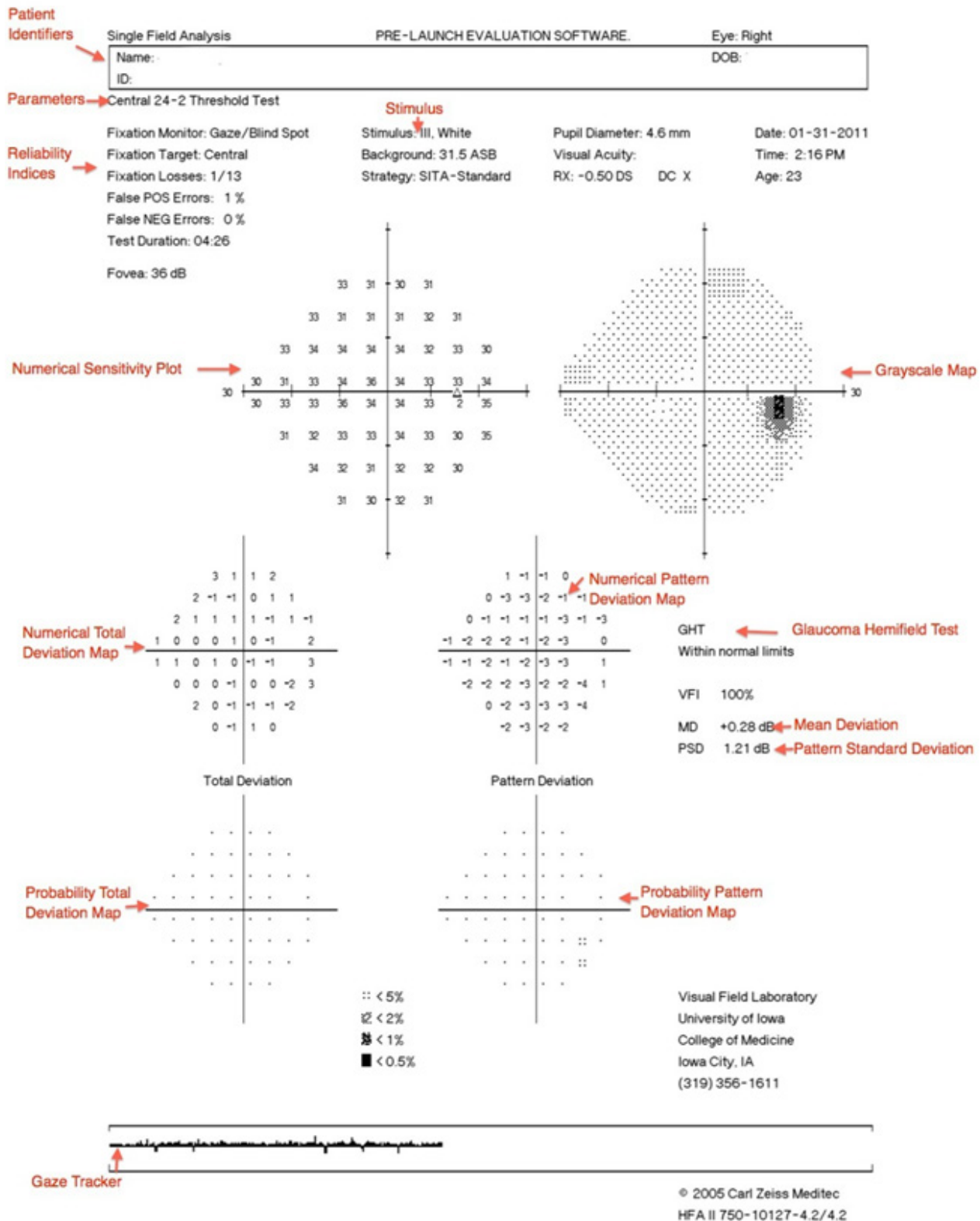


Figure 6: HVF 24-2. Courtesy Michael Wall, M.D.

ty. The sensitivities are not compared to any normative database. Therefore the map may draw attention to an irregularity within a field, but may minimize field loss if loss is more homogenous across the field. Caution should be used as it can be misleading based on where the machine chooses to make the cutoff between the different shades of gray. The raw threshold data should always be assessed in conjunction with the grayscale representation.

The numerical total deviation map compares the patient's visual sensitivity to an average normal individual of the same age. It is useful to compare with age-matched normal thresholds as sensitivity normally decreases gradually with age. Positive values represent areas of the field where the patient can see dimmer stimuli than the average individual of that age. Negative values represent decreased sensitivity from normal.

The numerical pattern deviation map shows discrepancies within a patient's visual field by correcting for generalized decreases in visual sensitivity. It is useful to show localized areas of sensitivity loss hidden within a field that is diffusely depressed. For example, a person with dense cataracts may have decreased threshold across the entire visual field and this may obscure more focal losses due to coexisting disorders like glaucoma. Rather than comparing the patient's threshold values with a normative database, the pattern deviation analysis finds the patient's 7th most sensitive (85th percentile) non-edge point and gives it a value of zero [6]. Each other test location is then compared with this value to correct for any generalized depression. It has been demonstrated that this method is the best for separating widespread or diffuse loss from localized loss.

The bottom-most probability plots are grayscale versions of the total deviation and pattern deviation maps. These maps may be useful to visually represent the statistical significance of the total and pattern deviation calculations. The grayscale maps should only be interpreted in conjunction with the numerical maps to avoid extrapolations.

On the right side of the printout are several useful numbers. The glaucoma hemifield test (GHT) compares groups of corresponding points above and below the horizontal meridian to assess for significant difference which may be consistent with glaucoma. Mean deviation (MD) is the mean deviation in the patient's results compared to those expected from the age-matched normative database. This calculation weighs center points more highly than peripheral points. Pattern standard deviation (PSD) is a depiction of focal defects. It is determined by comparing the differences between adjacent points. Higher values represent more focal losses, while lower values can represent either no loss or diffuse loss. Short-term fluctuations (SF) are a calculation portraying the variability between repeated measurements of the same test location. High SF decreases the reliability of the test. Corrected pattern standard deviation (CPSD) corrects the PSD for the SF. If there is high variability when testing the same point (high SF), PSD is given less weight due to decreased predictive value, and CPSD will therefore appear lower than PSD.

Along the bottom of the HVF printout is a gaze tracker. The patient's pupil is monitored during testing, and each time the pupil moves (representing a loss of fixation or head alignment), an upstroke is recorded. Losses of fixation decrease the accuracy of visual field testing because abnormalities will not correspond with the expected anatomic region of the retina and some may be missed entirely. When the gaze tracker loses view of the pupil (representing a blink or droopy upper eyelid), a downstroke is recorded. Pupillary obstruction can also decrease the accuracy of results.

Goldmann Visual Field Testing

Goldmann visual field (GVF) perimetry is not as widely available as HVF because it requires skilled perimetrists who manually map the visual field without the aid of a computer algorithm. Light is projected into a white bowl with a standardized background light intensity. The projected light forms a fairly circular stimulus. Six stimulus sizes are available, ranging from 0.0625 mm² (about 6 minutes of arc diameter) to 64 mm² (about 2 degrees in diameter) when viewed at 30 cm, which is the standard distance between the patient's eye and the stimulus on the background. The overall field mapping technique used is a form of kinetic perimetry, where a stimulus is moved into the field of vision. When the patient sees the stimulus, he indicates so with a low-tech method. At the University of Iowa a washer is given to the patient, with instructions to tap the table with the washer whenever the stimulus is seen. The perimetrist then makes a mark at the point where the stimulus was seen. To account for reaction time, a good perimetrist consistently adjusts the location of the mark. At the conclusion of the tests, the marks are connected by lines to form smooth boundaries of the visual field, or isopters. Areas of decreased sensitivity (scotomata) are mapped by an opposite process, beginning at the center of the area of loss and moving the target outward in at least 8



Figure 7: Goldmann Perimeter

directions (different clock hours). The different colors used represent stimuli of different sizes and luminous intensities.

Goldmann Visual Field Interpretation

The final result of a GVF is a diagram similar to a topographic map. An analogy commonly used to conceptualize these diagrams is the "island of vision." In this analogy, the visual field is an island with a central peak and the altitude correlates with the visual sensitivity in a given location. In this analogy, physiologic blind spot is represented by a pit or a well in the island. The isopters are named with three characters: a Roman numeral, an Arabic number, and a letter. The Roman numeral indicates the Goldmann size of the stimulus. The Arabic number and letter indicate the attenuation of the light. The combination "4e" is used when there is no attenuation. For each Arabic number less than "4," the light is attenuated by 5 dB. For each letter earlier in the alphabet than "e," the light is attenuated by 1 dB. Within the confines of an isopter, the patient is able to see a light of this size and intensity. Scotomata are represented by areas shaded with a solid color. The color represents the depth of the scotoma, or the dimmest, smallest stimulus the patient is unable to see in that area. For example, in figure 8, the physiologic blind spot is shaded orange

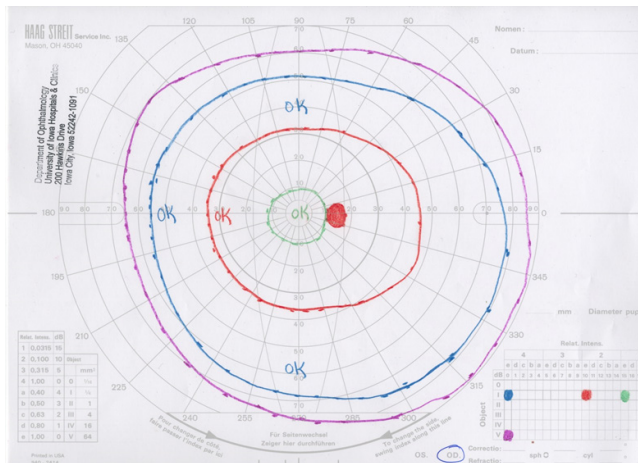


Figure 8: Goldmann Visual Field. Courtesy Chris A. Johnson, Ph.D.

like the I2e isopter. This suggests the patient is unable to see the I2e stimulus in the area but was able to see the dimmer I4e stimulus.

Glaucomatous Visual Field Defects

Loss of optic nerve axons in glaucoma eventually results in visual field defects, but the defects may not be evident until a considerable percentage of axons are lost. After that point in disease progression, further progression can be followed with serial visual field measurements. The visual field defects associated with glaucoma are not specific for the disease. For example, a generalized depression of the entire field is a change associated not only with glaucoma, but could also be the result of a cataract. Additional examples of glaucomatous changes include but are not limited to focal depression, focal or generalized contraction of the visual field, and blind spot baring (reduced sensitivity directly around the optic nerve head) [7].

Scotomata are islands of reduced sensitivity within the visual field surrounded by areas of better vision. Islands shaped like commas are named Seidel scotomata. Islands that arc in the shape of the arcuate fibers are Bjerrum or arcuate scotomata. Those that affect the center of vision are central scotomata and those that are located around the central ten degrees of the visual field are paracentral scotomas. If a defect is located in the nasal field and extends ten degrees along the horizontal meridian in a single isopter, or 5 degrees in multiple isopters, it is known as a nasal step.

End stage glaucoma can result in a superior or inferior hemifield defect, or even loss of all vision other than a central or temporal island of vision. Visual acuity (which is a measure of central vision) may remain 20/20, but the peripheral field of vision may be severely reduced.

Patterns of Visual Field Loss [7,8,9]

Damage to visual mechanisms along various portions of the visual pathways from the optics and photoreceptors up to the visual centers of the brain will produce different shapes and patterns of visual field loss. To assist you in being able to properly interpret visual fields, a table indicating the classic patterns of visual field loss associated with damage to different visual structures is presented (see table, next page).

Online Resources

- ◆ EyeWiki by The American Academy of Ophthalmology (eyewiki.aaopt.org/Standard_Automated_Perimetry)
- ◆ Imaging and Perimetry Society (perimetry.org)

Patterns Visual Field Loss**Classic Location of Defect**

Generalized decrease in sensitivity	Media opacity (cornea, lens, or vitreous), decreased attention
Constriction of the visual field	Retina, optic nerve, small pupils
Ring scotoma	Retina degeneration
Central scotoma	Macula or optic nerve
Cecocentral scotoma	Papillomacular nerve bundle or nearby retina in region between the macula and optic nerve head
Arcuate scotoma	Arcuate retina ganglion cell nerve fiber bundles or retinal vasculature
Temporal wedge	Nasal retina radial fibers entering the optic nerve
Blind spot enlargement	Optic nerve
Multiple scattered defects	Retina
Hemifields respecting the horizontal meridian	Retina ganglion cell nerve fiber bundles or less commonly retinal vasculature
Hemifields respecting the vertical meridian	Optic chiasm or posterior visual pathways
Bitemporal	Optic chiasm
Homonymous	Optic chiasm or optic radiations
Horizontal tongue	Lateral geniculate body
Congruous bilateral defects	Nearer to the optic chiasm
Incongruous bilateral defects	Nearer to the posterior visual cortex
"Pie in the sky"	Temporal lobe
"Pie on the floor"	Parietal lobe
"Punched out" defects	Occipital lobe

References

1. Anderson DR. Standard Perimetry. *Ophthalmol Clin N Am* 2003;16: 205-212. [PMID: 12809158]
2. Ramulu P. Standard Automated Perimetry. 2012. [Cited 2013 May 29]; Available from eyewiki.aao.org/Standard_Automated_Perimetry
3. Armaly MF. The size and location of the normal blind spot. *Arch Ophthalmol*. 1969; 81(2):192-201. [PMID: 5764683]
4. Palczewsk K. Chemistry and Biology of Vision. *The Journal of Biological Chemistry* 2012; 287(3): 1612-1619. [PMID: 22074921]
5. Johnson CA, Wall M, Thompson HS. A history of perimetry and visual field testing. *Optom Vis Sci*. 2011 Jan;88(1):E8-15. [PMID: 21131878]
6. Sample PA, Dannheim F, Artes P, Dietzsch J, Henson D, Johnson CA, Ng M, Schiefer U, Wall M. Imaging and Perimetry Society Standards and Guidelines. *Optom Vis Sci* 2011;88:4-7. [PMID: 21099442]
7. Alward, WL. (1999) Perimetry. In: WL Alward, Glaucoma: The Requisites, 1e (pp. 56-102). Mosby.
8. Johnson CA. Detecting functional changes in the patient's vision – Visual Field Analysis. Schacknow and Samples, *The Glaucoma Book*, Wilmington, PA: Springer, 2010, Chapter 23, p. 229-264.
9. Johnson CA, Wall M. The Visual Field. Chapter 35 in *Adler's Physiology of the Eye*, 11th ed (Levin, Nilsson, Ver Hoeve, Wu, Kaufman and Alm, eds), 2011, pp 655-676.

Citing this article

Carroll JN, Johnson CA. Visual Field Testing: A basic tutorial. *EyeRounds.org*. August 21, 2013; available from EyeRounds.org/tutorials/VF-testing/

last updated: 8/21/2013

Idiopathic Intracranial Hypertension (Pseudotumor Cerebri)

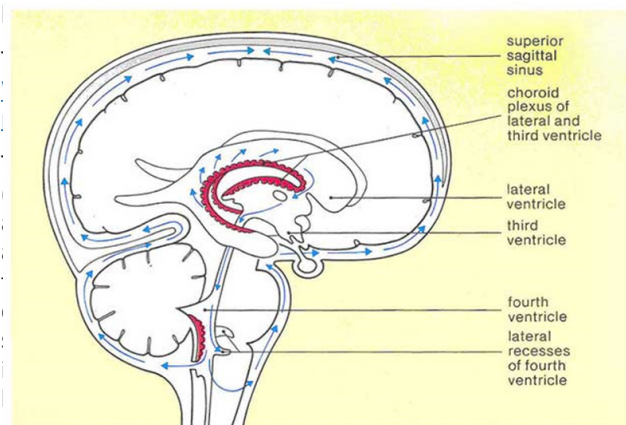
Michael Wall, M.D.

The University of Iowa
 Department of Neurology and
 Department of Ophthalmology and Visual Sciences

The initial sections of this tutorial are written with the goal of informing patients, the final sections regarding the medical treatment of IIH are written with the physician in mind.

Introduction

Idiopathic Intracranial Hypertension is a condition of high pressure in the fluid around the brain. It is also known as pseudotumor cerebri because there are some of the signs and symptoms of a brain tumor without a brain tumor



Perkin D, Rose FC, Blackwood W, Shawdon HH. Atlas of Clinical Neurology. Philadelphia: JB Lippincott, 1986. Fig 1.1.

Figure 1. The cerebrospinal fluid circulation. (used with permission)

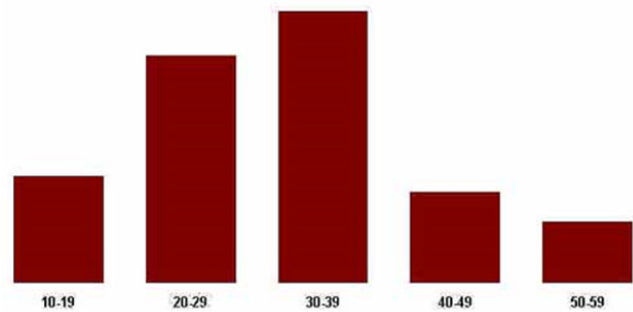
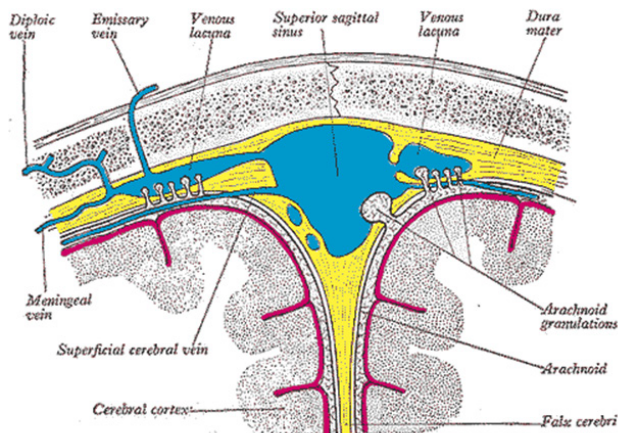


Fig 3. Age at diagnosis of IIH

What causes idiopathic intracranial hypertension?

Although we do not know what causes IIH, we have many clues. The condition occurs mostly in women in the childbearing years. The symptoms often start or worsen during a period of weight gain. The disease is rare in thin men. This has led some researchers to look for hormonal changes within the body. To date no consistent changes in hormones have been found.

Although no associated conditions besides recent weight gain are usually found, many conditions have been linked to high intracranial pressure. Any disorder that blocks the flow of spinal fluid between the brain and its route to the blood, the jugular vein, can cause raised pressure. For example, scarring cells next to the brain that absorb the spinal fluid (the arachnoid granulations) can cause raised pressure. Similarly, blood clots in the veins draining the brain can cause increased intracranial pressure (a disorder called venous sinus thrombosis). Withdrawal of corticosteroids, high doses of vitamin A or excessive intake of foods containing considerable vitamin A (such as liver), use of body building-type steroids and possibly certain drugs such as tetracycline and lithium can cause raised intracranial pressure. These conditions can mimic IIH.



Warwick R, Williams PL. Gray's Anatomy, 35th British ed. Philadelphia: W.B. Saunders, 1973. fig. 7.166, p. 991.

Figure 2. Meninges and Superficial Cerebral Veins. (used with permission)

What are the typical symptoms of IIH?

The symptoms most commonly reported by IIH patients followed by their frequency are:

- ◆ headache (94%)
- ◆ transient visual obscurations or blurring (68%)
- ◆ pulse synchronous tinnitus or "wooshing noise" in the ear (58%)
- ◆ pain behind the eye (44%)
- ◆ double vision (38%)
- ◆ visual loss (30%)
- ◆ pain with eye movement (22%)

Headache

Headache is present in nearly all patients with IIH and is the usual symptom for which patients seek medical attention. The headaches of the IIH patient are usually severe and daily; they are often throbbing. They are different from previous headaches, may awaken the patient and usually last hours. Nausea is common and vomiting less so. The headache is often the worst head pain ever experienced. Although uncommon, the presence of pain behind the eyeball that is worsened movements of the eyes can occur.

Transient visual obscurations

Visual obscurations are episodes of transient blurred vision that usually last less than 30 seconds and are followed by full recovery of vision. Visual obscurations occur in about 3/4 of IIH patients. The attacks may involve one or both eyes. They are not correlated with the degree of intracranial hypertension or with the extent of optic nerve swelling. Visual obscurations do not appear to be associated with poor visual outcome.

Pulsatile intracranial noises

Pulsatile intracranial noises or pulse-synchronous tinnitus is common in IIH. The sound is often unilateral. In patients with intracranial hypertension, compression of the jugular vein on the side of sound abolishes it. It is likely due to turbulence and narrowing of the transverse venous sinus (See Figure below), known to occur with increased intracranial pressure.

Visual loss

The most serious problem patients have is vision loss. (Figure 5, 6) About 5% of patients go blind in at least one eye. These are usually patients who do not return for follow-up evaluation or seek attention very late in their course.

A further scientific discussion can be found with this article: Wall M, George D. Idiopathic intracranial hypertension. A prospective study of 50 patients. Brain. 1991 Feb;114 (Pt 1A):155-80. PubMed PMID: 1998880).

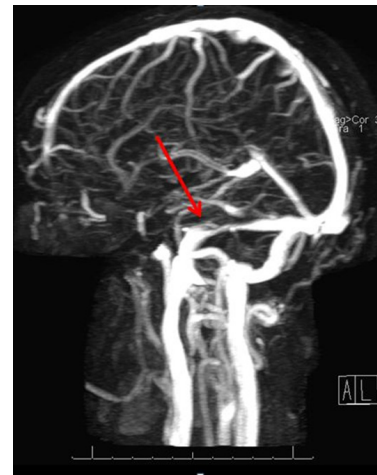


Fig. 4. This figure shows is a magnetic resonance venogram showing veins draining the brain. The arrow points to a narrow transverse venous sinus likely responsible for pulsatile tinnitus.

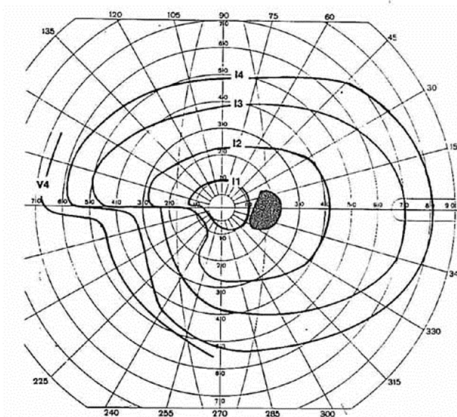


Figure 5. At typical visual field defect present using Goldmann perimetry in an IIH patient. Notice the large blind spot (black filled area) and the lower left indentation (an inferior nasal nerve fiber bundle defect).

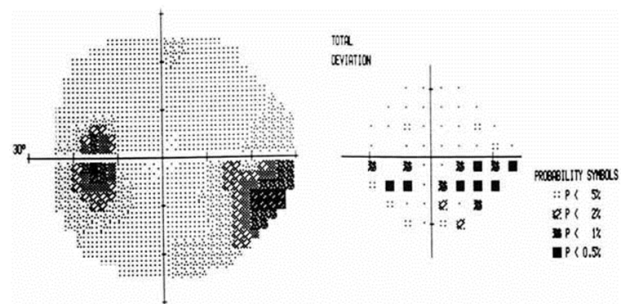


Figure 6. A similar inferior nasal nerve fiber bundle defect in an IIH patient found with automated perimeter (Humphrey perimeter). These defects may resolve fully with treatment.

How is the diagnosis of IIH made?

The diagnosis of IIH is made by identifying the typical symptoms of the disease along with documentation of a high spinal fluid pressure (measured during a spinal tap). The neurologic examination is normal except for the presence of swollen optic nerves called papilledema (seen by examining the back of the eye). (Figs 7-12) Sometimes double vision occurs, caused by limitation of lateral eye movement. Lastly, neuroimaging procedures such as CT scans or MRI scanning are normal except for signs known to occur with increased pressure.

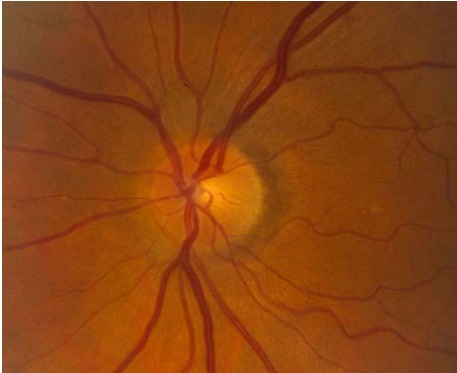

Figure 7. Normal optic nerve (central pinkish disk)

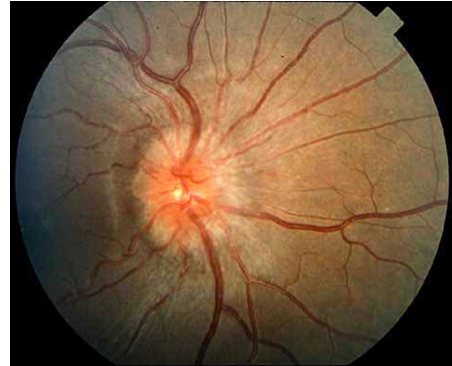

Figure 10. Grade II papilledema. The halo of edema now surrounds the optic disc.

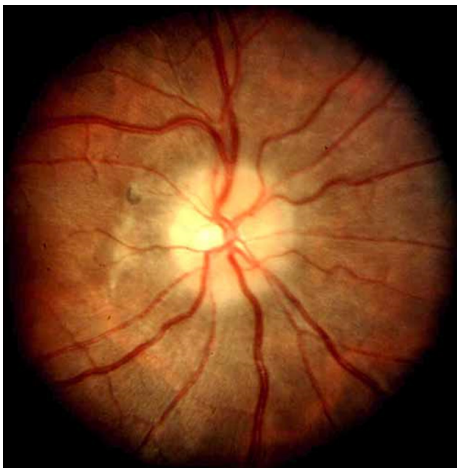


Figure 8. An optic nerve with mild swelling (papilledema). Note the pathologic "C"-shaped halo of edema surrounding the optic disk (Grade I papilledema).

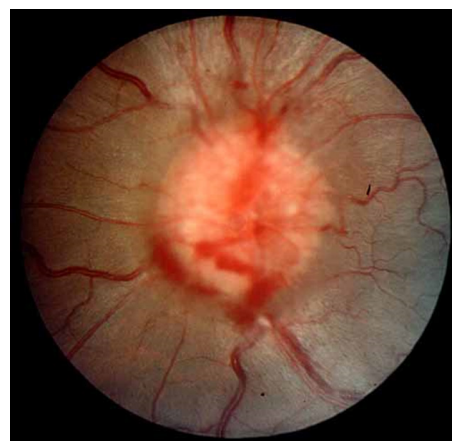

Figure 11. Grade IV papilledema. With more severe swelling in addition to a circumferential halo, the edema covers major blood vessels as they leave the optic disk (grade III) and vessels on the disk (grade IV). A subretinal hemorrhage is present at 7 o'clock.

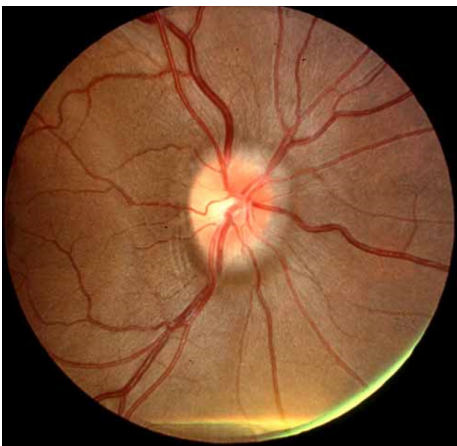


Figure 9. Grade I papilledema, Another example of an optic nerve with mild papilledema.

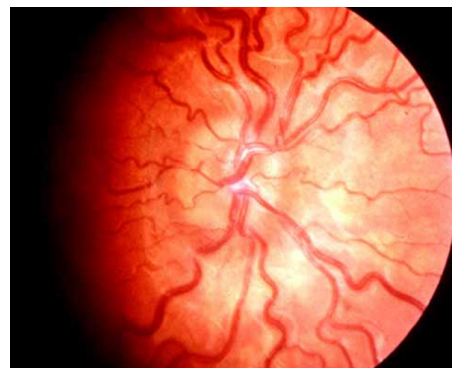


Figure 12. Pseudopapilledema. A patient with an elevated optic nerve present since birth. There is no halo, no major vessel covering a small nerve with abnormal vessel branching and tortuosity.

What is the relationship between optic nerve swelling and visual loss?

Why do the optic nerves swell with increased intracranial pressure?

Idiopathic intracranial hypertension is a disorder of increased in the fluid filled spaces around the brain pressure of unknown cause. The increased pressure takes place in the subarachnoid space, a space between the brain / spinal cord complex and its coverings called the meninges (Figure 1, 2). When a spinal tap is done, the needle is placed in the subarachnoid space to measure the pressure. Well, the eye is an outgrowth of the brain and with this outgrowth, the subarachnoid space continues right up to the optic nerve head (optic disc, papilla) in the back of the eyeball. When the pressure increases in this space, fibers in the optic nerve are compressed. This makes it harder for the neurons to transport their proteins and organelles so there is a decrease or slow down in flow in optic nerve fibers. This buildup is seen as swelling or edema of the optic nerve head or papilla, hence the term papilledema. A more extensive discussion can be found in Wall, M. *Curr Neurol Neurosci Rep* 2008; 8:87-93. <https://doi.org/10.1007/s11910-008-0015-0>

What is the danger of papilledema to vision?

When the optic nerve fibers are under pressure, their microcirculation or blood supply is also under pressure. This results in decreased blood flow to the optic nerve, damage to the nerve and resultant visual loss. Since all the optic nerve fibers are under pressure, a visual field examination is necessary to determine whether visual loss is taking place so that the appropriate treatment can be started.

Can vision loss be reversed?

Fortunately, visual loss can be reversed. However, much depends on how long the visual loss has been present. In some cases, full recovery takes place and in others partial recovery. Most patients with visual loss have **some recovery with treatment** (Wall M, George D. Idiopathic intracranial hypertension: a prospective study of 50 patients. *Brain*, 1991; 114A(1): 155–180. doi.org/10.1093/oxford-journals.brain.a101855).

What are the earliest signs of permanent vision loss?

The most common early sign of visual loss is inferior nasal loss found with visual field testing. However, other types of visual loss can occur. What is important is that it is rare for early visual loss to involve the central area of vision. And, early peripheral visual loss is seldom recognized by the patient. This is yet another reason why perimetry is very necessary in the evaluation and management of patients with idiopathic intracranial hypertension.

How is IIH treated?

Treatment for patient with IIH can be divided into medical treatment and surgical treatment. The cornerstone of medical treatment is weight loss. It does not appear to be the total number of pounds lost. Some patients are effectively treated by losing one pound every week or two for several months and then maintaining the weight loss. It has been shown that loss of 5-10% of body weight is often sufficient for optic disc edema to regress, symptoms resolve and vision improve.

Loss of fluid can also be obtained using diuretics (fluid pills). Diamox (acetazolamide) is the most commonly used medication. It is relatively safe but nearly all patients have tingling of the fingers and toes. This tingling is a benign symptom and suggests the medication is working. Patients also experience that carbonated soft drinks taste metallic. Less commonly, kidney stones can occur and rarely other blood disorders. Another diuretic commonly used that appears to be effective in some patients is Lasix (furosemide).

Please see supplemental information at the end of Part I regarding side effects of acetazolamide.

While there is no evidence based treatment to guide medical therapy there is currently an ongoing National Eye Institute sponsored trial, the Idiopathic Intracranial Hypertension Treatment Trial (IIHTT) (www.clinicaltrials.gov/ct2/show/NCT01003639). The trial has two aims. One is to determine if acetazolamide (Diamox) with a low sodium weight reduction diet is superior to placebo with the diet. The second aim is to investigate the cause of idiopathic intracranial hypertension. Further information can be found at the NORDIC website (www.nordicclinicaltrials.com).

The surgical treatments currently used are optic nerve sheath fenestration (making slits in the optic nerve sheath or covering) (Figure 13) and CSF shunting procedures (running a tube from the spinal fluid space into the abdominal

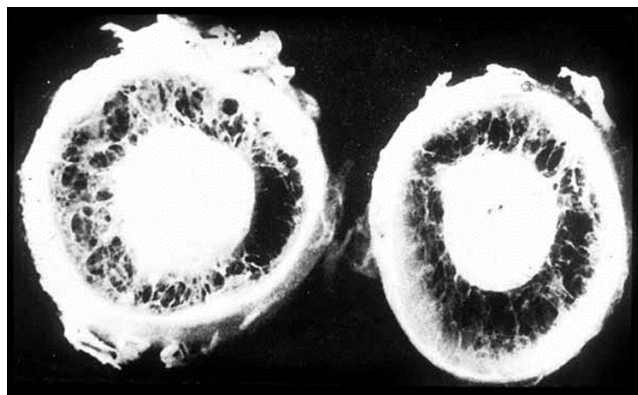


Figure 13. Cut sections of optic nerves (post-mortem) from a patient with papilledema. Note the large space, filled with the web-like strands of arachnoid between the nerve and the nerve sheath. With optic nerve sheath surgery, a hole is cut in the sheath of the nerve that allows fluid to leak and pressure to decrease. from Sergott RC, Savino PJ, Bosley TM. Modified optic nerve sheath decompression provides long-term visual improvement for pseudotumor cerebri. *Arch Ophthalmol* 1988; 106:1391-1397.

cavity or a vein). These procedures are used when patients do not respond adequately to medical therapy. Optic nerve sheath fenestration is done first by an incision into the orbit. The eyeball is moved to the side and the optic nerve sheath is exposed. Slits or a large hole are then placed in the optic nerve sheath and fluid drains out, thereby taking pressure off the optic nerve.

The second surgical procedure, called CSF shunting, is done as follows. Tubing is placed in the spinal fluid space, (either the space entered during a lumbar puncture or space in or around the brain and tubing is then run to the abdomen or a vein). This lowers the pressure around the brain and optic nerve, thereby eliminating the symptoms of raised intracranial pressure. Unfortunately, these procedures are complicated by various problems, the most severe one being some patients have periodic occlusion of the tubing with recurrence of symptoms and sometimes vision loss. A repeat operation is then needed. An overview of treatment is summarized in figure 14.

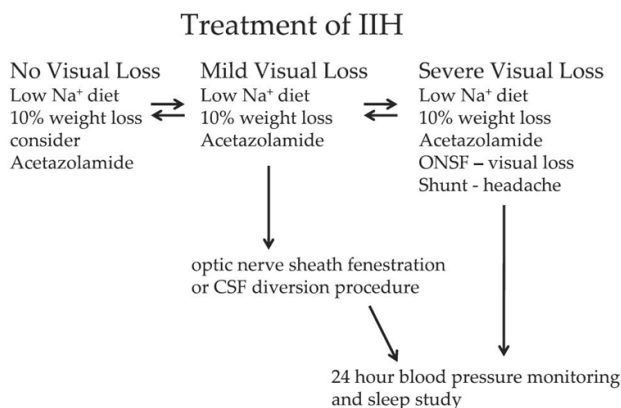


Figure 14. Treatment strategies for IIH. Treatment algorithm for IIH. Visual loss does not include enlargement of the blind spot unless it is compromising vision. Optic Nerve Sheath fenestration is preferred to steroids. Downward arrows show the next step when vision worsens

Management of the pregnant IIH patient

Pregnancy occurs in IIH as often as in the general population and in any trimester. Patients with IIH during pregnancy do not have an increased spontaneous abortion rate. Therapeutic abortion to limit progressive disease is not indicated. The pregnant patient with IIH should be treated as any other patient with IIH. Also, the pregnancy should be managed like any other. The major exception is caloric restriction because of its adverse effect of ketosis on the fetus. Weight gain can be limited to 20 pounds or the amount recommended by an obstetrician.

Use of corticosteroids has not been associated with birth defects in humans. Acetazolamide may be used after 20 weeks gestation; use before 20 weeks has been associated with one case of sacrococcygeal teratoma. Glycerol and thiazide diuretics probably should not be used in the second half of pregnancy because of the risk of decrease in

placental blood flow. There is no obstetric contraindication to surgery for those that require it.

How is visual loss prevented?

The best way to prevent visual loss is to test vision regularly with a visual field examination called perimetry. Patients should be followed frequently with tests of vision until the doctor is confident that there is no vision loss occurring. Vision testing should then be done once or twice a year or whenever new symptoms occur. Unfortunately, IIH is a life-long disease and tends to occur during periods of weight gain. The symptoms though are very treatable and, if treatment is started early enough, the vision loss is reversible.

For an update, please see the appendix of this article “Idiopathic Intracranial Hypertension Treatment Trial (IIHTT). What Have We Learned?”

Diamox (acetazolamide) side effects

Tingling or pins and needles feelings around the mouth and in the hands and feet is a common side effect of acetazolamide and suggests the medicine is working. Nearly everyone who takes acetazolamide notices that carbonated beverages taste metallic. Renal stones, although painful, are very treatable. These occur in a few percent of patients.

A rare but serious side effect is aplastic anemia. This is when the bone marrow fails to produce an adequate number of red and white blood cells. It occurs in one in 15,000 patient years on acetazolamide. That means for every 15,000 patients on acetazolamide for one year, one will develop this potentially fatal side effect. Statistically speaking, if you drive a car you are more likely to die from an automobile accident.

- ◆ Aplastic anemia usually occurs in the first six months of therapy
- ◆ Aplastic anemia from acetazolamide has been reported most often in the elderly

Should you have repeated blood work to check for aplastic anemia?

- ◆ In 1987 dollars it has been estimated that it would cost about \$650,000 to detect one case, adjusted for inflation, that’s about \$1.4 million in 2018.
- ◆ Finding the case and stopping the medication does not necessarily cure the patient; this is unlike mammograms, chest x-rays and proctoscopy which are shown to improve detection of a potentially fatal treatable disease,
- ◆ In a perfect world, we could test everybody for everything that is potentially fatal and provide all people with all available medical care; unfortunately this is not realistic to do.

Side effects as rare as aplastic anemia from acetazolamide are often not tested for. Our dilemma is: do you burden thousands of patients with the cost and inconvenience of monthly and bimonthly testing to find something very rare that you may not be able to treat? This philosophical issue ultimately must be faced and decided by the patient. It is the patient’s money and life and is, therefore, the patient’s decision whether to spend their money on monitoring the blood (a complete blood count) for aplastic anemia while taking acetazolamide.

End Part I

Part II: Medical Treatment of IIH

(written for physicians)

Treatment of raised intracranial pressure is both medical and surgical. It is aimed mainly at lowering of intracranial pressure and secondarily at treating symptoms directly, for example headache. Unfortunately, all reports to date are anecdotal as there have not been any controlled clinical treatment trials for idiopathic intracranial hypertension. While there is no evidence based treatment to guide medical therapy there is currently an ongoing National Eye Institute sponsored trial, the [Idiopathic Intracranial Hypertension Treatment Trial \(clinicaltrials.gov/ct2/show/NCT01003639\)](https://clinicaltrials.gov/ct2/show/NCT01003639). The trial has two aims. One is to determine if acetazolamide (Diamox) with a low sodium weight reduction diet is superior to placebo with the diet. The second aim is to investigate the cause of idiopathic intracranial hypertension. Further information can be found at the [NORDIC website \(www.nordicclinicaltrials.com/\)](http://www.nordicclinicaltrials.com/).

Weight Loss

Weight loss has been used to treat IIH for many years. Newborg in 1974 reported remission of papilledema in all nine patients placed on a strict diet. She used a low calorie adaptation of Kempner's rice diet. The patient's intake was 400-1000 calories per day by fruits, rice, vegetables and occasionally 1-2 oz of meat. Fluids were limited to 750-1250 ml/day and sodium to less than 100 mg/day. All patients had reversal of their papilledema. Unfortunately, there was no mention of the patients' visual testing.[1]

The beneficial effects of weight loss have also been reported more recently. Kupersmith and colleagues retrospectively reviewed the charts of 250 IIH medically treated IIH patients from two centers and tabulated results on 56 patients that had at least 6 months of follow-up and otherwise met entry criteria.[2] The mean time to improve one papilledema grade was about 4 months in patients with weight loss compared with about 1 year in patients without weight loss. Papilledema resolved in 28/38 patients with weight loss compared with 8/20 without weight loss.

Johnson and coworkers retrospectively studied 15 IIH patients treated with acetazolamide and weight loss for 24 weeks.[3] They reported 3.3% weight loss in patients having one grade of improvement in their papilledema grade. Nine of 10 patients that improved took acetazolamide as did the four patients that did not lose weight and had no improvement in papilledema grade. Our experience from a pilot study with 29 patients has also been that improvement often occurs with only modest degrees of weight loss. Greer however, reported a group of six obese patients that became asymptomatic without weight loss.[4] Sinclair and coworkers, have shown diet over a three month period lowers intracranial pressure.

Resolution of IIH in a patient following surgically induced weight loss (gastric exclusion procedure) was first reported by Amaral.[5] Sugarman and coworkers performed gastric weight reduction surgery in 24 morbidly obese women with IIH.[6] Five patients were lost to follow-up. Symptoms resolved in all but one patient within 4 months of the procedure. Two patients regained weight associated with return of their symptoms. There were significant but treatable surgically-related complications.

Since marked recent weight gain is a predictor of visual deterioration[7] and we have observed papilledema resolve with weight loss as the only treatment, we strongly encourage our patients to pursue a supervised weight loss program. As Friedman and colleagues have shown, there is a subset of IIH patients with orthostatic edema.[8] Low salt diets and fluid restriction may also be beneficial for IIH patients. This may be especially true in patients that lose only a few percent of their total body mass yet have resolution of their optic disc edema. It is not yet clear whether improvement occurs because of weight loss per se or other changes in diet such as fluid or sodium restriction.

Lumbar Puncture

Repeated lumbar puncture, although still used by some neurologists, leaves much to be desired as a treatment. Lumbar puncture has only a short-lived effect on CSF pressure; Johnston and Paterson[9] found a return of pressure to pre-tap level after only 82 minutes. Interestingly, Weisberg[10] reported 6 of 28 patients treated with serial lumbar punctures symptomatically improved.

Repeated lumbar punctures also raise the risk of developing intraspinal epidermoid tumors presumably caused by implantation of epidermal cells. Lastly, repeated lumbar punctures to measure CSF pressure do so at only one point in time. Since CSF pressure fluctuates widely throughout the day, this information has only limited clinical use for modifying treatment plans. Following the patient's papilledema (which reflects the mean intracranial pressure) is a superior index of the mean intracranial pressure.

Corticosteroids

Paterson[13] first reported the efficacy of corticosteroids for treating IIH in five of six consecutive patients. Weisberg[10] has documented prompt beneficial initial responses to steroids. Corticosteroids are still used to treat this disease but their mechanism of action remains unclear. The side effects of weight gain, striae, and acne are particularly unfortunate for these obese patients. Although patients treated with steroids often respond well, there may be recurrence of papilledema with rapid tapering of the dose. This may be accompanied by severe worsening of visual function. A prolonged tapering may prevent return of symptoms and signs in some patients.

Use of corticosteroids to treat IIH patients has largely been abandoned by most neuro-ophthalmologists.

Thiazide Diuretics

Jefferson and Clark[15] treated 30 patients with various types of oral dehydrating agents (chlorthalidone, hydroflumethiazide, glycerol and urea). All patients were also placed on a weight reduction diet. They used blind spot size as their main outcome measure. This measure can be problematic for many reasons including changes in refractive error[16] and changes in stimulus speed and reaction times between exams. Fourteen of these patients had reduced visual acuity, and in all, vision improved with therapy. Friedman treated 30 women with IIH with chlorthalidone and spironolactone.[8] In 15, dextroamphetamine or phenteramine was added and 18 patients also were treated with acetazolamide. This treatment did not consistently reduce headaches and only four of the 30 patients had improvement in their papilledema. Thiazides are not first line drugs to treat idiopathic intracranial hypertension.

Acetazolamide

In 1974, McCarthy and Reed[17] showed inhibition of CSF flow but not until over 99.5% of choroid plexus carbonic anhydrase was inhibited. Lubow and Kuhr, in 1976, reported a series of IIH patients, many of whom were treated successfully with acetazolamide (Diamox®) and weight reduction.[18] An important study was published in 1978 by Gücer and Viernstein.[19] They used intracranial pressure monitoring before and after treatment in four IIH patients. They monitored acetazolamide treatment in two of the patients and showed gradual CSF pressure reduction in both. They only reported the dose in one of the patients (four grams of acetazolamide per day). Ten years later, Tomsak et al.,[20] documented resolution of papilledema with photographs of the optic disc in four patients treated with one gram of acetazolamide a day. Acetazolamide appeared to be an effective medication in their patients with results occurring over several months.

The mechanism of action of acetazolamide is likely multifactorial. It has been found to reduce CSF production in humans by 6-50%.[21] It has been thought to work by inhibition of carbonic anhydrase that causes a reduction in transport of sodium ions across choroid plexus epithelium. Also, it changes the taste of foods and causes carbonated beverages to taste metallic. This may aid the patient in weight loss. Additionally, some patients experience nausea, further helping them to lose weight.

Topiramate (Topamax) is a structurally related medication used for headache. It has weight loss as a side effect! To date, it appears about as effective as acetazolamide but is considerably more expensive.

The most effective dose is not yet determined. In addition to the gustatory side effects, patients commonly experience tingling in the fingers, toes, and perioral region, and less commonly, malaise, nausea and anorexia are reported. Rarely patients will develop renal stones. Metabolic acidosis, evidenced by lowered serum bicarbonate, is a

good measure of compliance. Younger patients tolerate acetazolamide better than older ones and the Diamox 500mg sequels appeared to be better tolerated. Aplastic anemia is so rare, some advocate not monitoring complete blood counts. Zimran and Beutler estimate the cost of finding one case would be \$1.5 million.[22] While it has been suggested that patients that are sulfa allergic should not use acetazolamide because of potential cross reaction, there is no conclusive evidence for withholding the drug in sulfa allergic patients. If patients develop renal stones, one can discontinue the medication or continue usage with periodic ultrasound examinations to see if the renal stones are recurring.

Furosemide

It has been documented that furosemide (Lasix®) can lower intracranial pressure.[7,23-25] Furosemide has also been used to treat IIH.[26] It appears to work by both diuresis and reducing sodium transport into the brain.[28]

Based on an assumption by McCarthy and Reed[17] that the effects of acetazolamide and furosemide might be additive, Schoeman treated pediatric IIH patients with this combination therapy.[29] In a controlled trial of children with tuberculous meningitis, 57 with communicating hydrocephalus were randomly assigned to three treatment groups: antituberculous drugs only; or additional intrathecal hyaluronidase or oral acetazolamide and furosemide in addition to antituberculous treatment. Acetazolamide and furosemide in combination was significantly more effective in achieving normal ICP than antituberculous drugs alone.[30]

Schoeman then treated eight pediatric IIH patients with oral acetazolamide (37-100 mg/kg) and furosemide (1 mg/kg) until the papilledema cleared. He used continuous 1-hour lumbar cerebrospinal fluid pressure monitoring these children with IIH on admission and at weekly intervals until the baseline pressure became normal. Six children had an increased baseline cerebrospinal fluid pressure, whereas raised intracranial pressure was diagnosed in three children based on an abnormal pulse wave and/or pressure waves. The mean baseline pressure normalized in all patients within 6 weeks of start of therapy. As with all treatments of IIH, all reports to date are anecdotal and recommended treatments vary widely.

Glycerol

Oral glycerol is a form of cerebral dehydration first recommended in 1963 to reduce intracranial pressure. A single dose of one gram/kg of glycerol will raise serum osmolality from 295 to 320 mOsm/L in 90 minutes, and reduce CSF pressure for 3 to 5 hours. Doses every four hours can cause a reversed osmotic gradient and a rebound increase in intracranial pressure[31,32] while a six hour interval is too long and allows the pressure to recur. Together, the added calories the large volume of glycerol needed, the awkwardness for a working person to use this medication, the nauseating side effects, and other side effects make this a

cumbersome medication for IHH. It is rarely used today for increased intracranial pressure.

Treatment of Headache

Sometimes, in spite of full medical therapy to reduce CSF pressure, headaches persist. We have success in some patients with standard prophylactic vascular headache remedies. However, caution should be used in patients with visual loss as the hypotension that accompanies many of these medications can accelerate the visual loss.

Patients with idiopathic intracranial hypertension also have other headache syndromes. Especially in patients with a migraine history, analgesic rebound or caffeine rebound headaches may coexist. It may require IV dihydroergotamine to break this troublesome headache syndrome.

Recommendations

Weight loss is the cornerstone of therapy for idiopathic intracranial hypertension. We recommend a low salt, weight reduction diet with loss of about 5 - 10% of body weight followed by stable weight. This goal, of modest weight loss, is more likely to succeed than the usual aggressive weight loss program.

In our experience, acetazolamide appears to be an effective treatment for idiopathic intracranial hypertension. We start the patient with a dose of 250 mg orally twice daily and increase the dose every four days by 250 mg until a dose of 1 gram a day is reached or the patient becomes intolerant to the side effects. If tolerated we give the medication twice daily with meals. If after one to two months there is no substantial improvement in visual function or symptoms, we gradually increase the dose to two grams per day. Doses of up to four grams a day may be needed but we usually obtain a beneficial effect in the one to two gram a day range. If acetazolamide is not well tolerated we use furosemide or topiramate. Modification of therapy is based on a combination of the patient's symptoms, visual field examinations and changes in papilledema.

Reference List

1. Newborg B. Pseudotumor cerebri treated by rice reduction diet. *Arch Intern Med* 1974; 133:802-807.
2. Kupersmith MJ, Gamell L, Turbin R, Peck V, Spiegel P, Wall M. Effects of weight loss on the course of idiopathic intracranial hypertension in women. *Neurology* 1998; 50(4):1094-1098.
3. Johnson LN, Krohel GB, Madsen RW, March GA, Jr. The role of weight loss and acetazolamide in the treatment of idiopathic intracranial hypertension (pseudotumor cerebri). *Ophthalmology* 1998; 105(12):2313-2317.
4. Greer M. Benign intracranial hypertension. VI. Obesity. *Neurology* 1965; 15:382-388.
5. Amaral JF, Tsiaris W, Morgan T, Thompson WR. Reversal of benign intracranial hypertension by surgically induced weight loss. *Arch Surg* 1987; 122:946-949.
6. Sugeran HJ, Felton WL, III, Sismanis A, Kellum JM, DeMaria EJ, Sugeran EL. Gastric surgery for pseudotumor cerebri associated with severe obesity. *Ann Surg* 1999; 229(5):634-640.
7. Wall M, George D. Idiopathic intracranial hypertension. A prospective study of 50 patients. *Brain* 1991; 114:155-180.
bit.ly/2EJlkmH
8. Friedman DI, Streeten DH. Idiopathic intracranial hypertension and orthostatic edema may share a common pathogenesis. *Neurology* 1998; 50(4):1099-1104.
9. Johnston I, Paterson A. Benign intracranial hypertension. II. CSF pressure and circulation. *Brain* 1974; 97:301-312.
10. Weisberg LA. Benign intracranial hypertension. *Medicine* 1975; 54:197-207.
11. Batnitzky S, Keucher TR, Mealey T, Jr., Campbell RL. Iatrogenic intraspinal epidermoid tumors. *JAMA* 1977; 237:148-150.
12. Manno NJ, Uihlein A, Kernohan JW. Intraspinal epidermoids. *J Neurosurg* 1962; 19:754-756.
13. Paterson R, DePasquale N, Mann S. Pseudotumor Cerebri. *Medicine* 1961; 40:85-99.
14. Weisberg LA, Chutorian AM. Pseudotumor cerebri of childhood. *Am J Dis Child* 1977; 131:1243-1248.
15. Jefferson A, Clark J. Treatment of benign intracranial hypertension by dehydrating agents with particular reference to the measurement of the blind spot area as a means of recording improvement. *J Neurol Neurosurg Psychiatr* 1976; 39:627-639.
16. Corbett JJ, Jacobson DM, Mauer RC, Thompson HS. Enlargement of the blind spot caused by papilledema. *Am J Ophthalmol* 1988; 105:261-265.
17. McCarthy KD, Reed DJ. The effect of acetazolamide and furosemide on CSF production and choroid plexus carbonic anhydrase activity. *J Pharmacol Exp Ther* 1974; 189:194-201.
18. Lubow M, Kuhr L. Pseudotumor cerebri: comments on practical management. In: Glaser JS, Smith JL, editors. *Neuro-ophthalmology*, Vol. IX. St. Louis: C.V. Mosby, 1976: 199-206.
19. Gucer G, Vierenstein L. Long-term intracranial pressure recording in management of pseudotumor cerebri. *J Neurosurg* 1978; 49:256-263.
20. Tomsak RL, Niffenegger AS, Remler BF. Treatment of pseudotumor cerebri with Diamox (acetazolamide). *J Clin Neuro-ophthalmol* 1988; 8:93-98.
21. Rubin RC, Henderson ES, Ommaya AK, Walker MD, Rall DP. The production of cerebrospinal fluid in man and

- its modification by acetazolamide. *J Neurosurg* 1966; 25(4):430-436.
22. Zimran A, Beutler E. Can the risk of acetazolamide-induced aplastic anemia be decreased by periodic monitoring of blood cell counts? *Am J Ophthalmol* 1987; 104(6):654-658.
 23. Pollay M, Fullenwider C, Roberts PA, Stevens FA. Effect of mannitol and furosemide on blood-brain osmotic gradient and intracranial pressure. *J Neurosurg* 1983; 59(6):945-950.
 24. Roberts PA, Pollay M, Engles C, Pendleton B, Reynolds E, Stevens FA. Effect on intracranial pressure of furosemide combined with varying doses and administration rates of mannitol. *J Neurosurg* 1987; 66:440-446.
 25. Vogh BP, Langham MR, Jr. The effect of furosemide and bumetanide on cerebrospinal fluid formation. *Brain Research* 1981; 221(1):171-183.
 26. Corbett JJ. The 1982 Silversides lecture. Problems in the diagnosis and treatment of pseudotumor cerebri. *Can J Neurol Sci* 1983; 10:221-229.
 27. Cottrell JE, Robustelli A, Post K, Turndorf H. Furosemide- and mannitol-induced changes in intracranial pressure and serum osmolality and electrolytes. *Anesthesiology* 1977; 47(1):28-30.
 28. Buhrley LE, Reed DJ. The effect of furosemide on sodium-22 uptake into cerebrospinal fluid and brain. *Experimental Brain Research* 1972; 14(5):503-510.
 29. Schoeman JF. Childhood pseudotumor cerebri: clinical and intracranial pressure response to acetazolamide and furosemide treatment in a case series. *Journal of Child Neurology* 1994; 9(2):130-134.
 30. Schoeman J, Donald P, van Zyl L, Keet M, Wait J. Tuberculous hydrocephalus: comparison of different treatments with regard to ICP, ventricular size and clinical outcome. *Developmental Medicine & Child Neurology* 1991; 33(5):396-405.
 31. Guisado R, Tourtellotte WW, Arieff AI, Tomiyasu U, Mishra SK, Schotz MC. Rebound phenomenon complicating cerebral dehydration with glycerol. *J Neurosurg* 1975; 42:226-228.
 32. Rottenberg DA, Hurwitz BJ, Posner JB. The effect of oral glycerol on intraventricular pressure in man. *Neurology* 1977; 27:600-608.
 33. Corbett JJ, Nerad JA, Tse DT, Anderson RL. Results of optic nerve sheath fenestration for pseudotumor cerebri. The lateral orbitotomy approach. *Arch Ophthalmol* 1988;106:1391-1397.
 34. Corbett JJ, Thompson HS. The rational management of idiopathic intracranial hypertension. *Arch Neurol* 1989;46:1049-1051.
 35. Durcan FJ, Corbett JJ, Wall M. The incidence of pseudotumor cerebri. Population studies in Iowa and Louisiana. *Arch Neurol* 1988;45:875-877.
 36. Giuseffi V, Wall M, Siegel PZ, Rojas PB. Symptoms and disease associations in idiopathic intracranial hypertension (pseudotumor cerebri): a case-control study. *Neurology* 1991;41:239-244.
 37. Ireland B, Corbett JJ, Wallace RB. The search for causes of idiopathic intracranial hypertension. A preliminary case-control study. *Arch Neurol* 1990;47:315-320.
 38. Lessell S. Pediatric pseudotumor cerebri (idiopathic intracranial hypertension). *Surv Ophthalmol* 1992;37:155-166.
 39. Meador KJ, Swift TR. Tinnitus from intracranial hypertension. *Neurology* 1984;34:1258-1261.
 40. Sergott RC, Savino PJ, Bosley TM. Modified optic nerve sheath decompression provides long-term visual improvement for pseudotumor cerebri. *Arch Ophthalmol* 1988; 106:1391-1397.
 41. Wall M, George D. Visual loss in pseudotumor cerebri. Incidence and defects related to visual field strategy. *Arch Neurol* 1987;44:170-175.
 42. Wall M. The headache profile of idiopathic intracranial hypertension. *Cephalalgia* 1990;10:331-335.
 43. Wall, M. Idiopathic intracranial hypertension. *Neurol Clin* 9:73-95, 1991.

Appendix.

Idiopathic Intracranial Hypertension Treatment Trial (IIHTT). What Have We Learned?

[Michael Wall, MD](#)

February 4, 2015

Results of the IIHTT were published in the April 23, 2014 edition of the *Journal of the American Medical Association* (JAMA). Full text available at [Effect of Acetazolamide on Visual Function in Patients with Idiopathic Intracranial Hypertension and Mild Visual Loss: The Idiopathic Intracranial Hypertension Treatment Trial. JAMA 2014;311\(16\):1641-1651. dx.doi.org/10.1001/jama.2014.3312.](#)

What is the Idiopathic Intracranial Hypertension Treatment Trial?

The Idiopathic Intracranial Hypertension Treatment Trial is a multicenter, double-blind, randomized, placebo-controlled study of acetazolamide in 165 IIH participants with mild visual loss. All participants received a lifestyle modification program that included weight reduction with a program emphasizing lifestyle management and a low sodium diet. The main purpose of the trial was to determine the effect of acetazolamide in reducing or reversing visual loss after 6 months of treatment when added to the weight reduction program. Secondary purposes were to determine if acetazolamide lowered CSF pressure, improved quality of life and decreased optic nerve swelling. The structure of the trial is outlined in Figure 1.

Who was included in the trial?

Idiopathic intracranial hypertension (IIH) is a disorder primarily of overweight women of childbearing age characterized by increased intracranial pressure with its associated signs and symptoms including debilitating headaches and vision loss in an alert and oriented patient. Neuroimaging and CSF analysis are normal except for raised intracranial pressure. Also, no secondary cause of intracranial hypertension is apparent. The above features comprise the modified Dandy criteria for IIH and were necessary for entry into the trial.

The other important entry criterion was having mild visual loss. This was defined for study purposes as having a mean deviation (measure of average loss across the visual field on an automated visual field test) of from -2 to -7 dB. Additional inclusion and exclusion criteria can be found in the pdf of the primary outcome paper by clicking on the link at the top of the page.

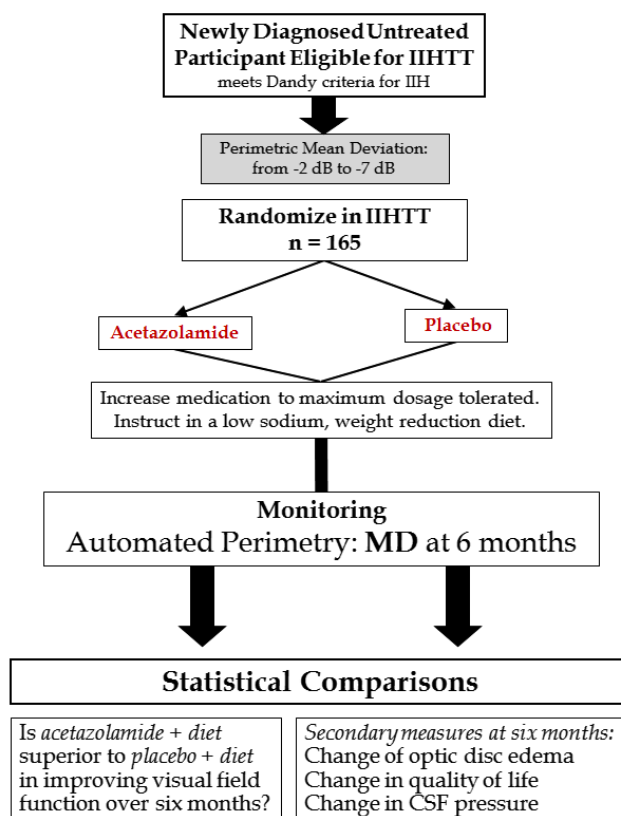


Figure 1. Study design of the IIHTT.

What did the trial conclude?

In IIH patients with mild visual loss, it was found that subjects taking acetazolamide, a type of diuretic, along with a low sodium diet program had significantly better visual outcomes than those taking placebo along with the diet. In addition, the patients taking acetazolamide also had significantly improved papilledema (optic nerve head swelling), quality of life measures and lower cerebrospinal fluid pressure.

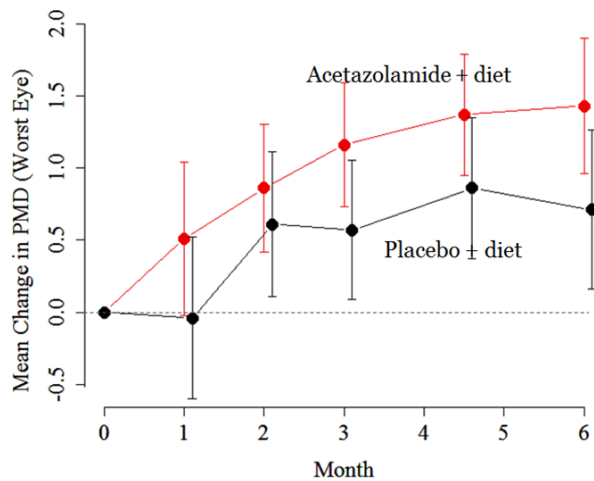


Figure 2. The acetazolamide-plus-diet group in red had a statistically significant improvement in visual field mean deviation with most of the change occurring in the first month.

What was new or unusual about the findings?

1. This is the first time there has been proof that acetazolamide use in IIH improves visual outcome.
2. The beneficial effects of acetazolamide and diet are independent. So, although the acetazolamide-plus-diet patients lost twice as much weight as placebo-plus-diet patients, the acetazolamide effect on PMD was independent of the weight loss. The average weight loss in the trial was 6%.
3. The patients with moderate to severe optic nerve swelling recovered substantially more vision than those with mild swelling.
4. Acetazolamide has its greatest effect on visual field function and papilledema in the first month of escalating dosage to the maximum dosage tolerated that did not interfere with activities of daily living.
5. Marked worsening of visual field function was much less common in the acetazolamide-plus-diet group compared to the placebo-plus-diet group (6 patients vs. 1) and risk factors for marked worsening were presence of high grade papilledema and lower visual acuity measures at baseline.
6. Many IIHTT subjects tolerated maximal dosages of acetazolamide up to four grams per day. While there were many expected side effects, quality of life measures were significantly better in the acetazolamide-plus-diet group. There was no permanent morbidity (bodily damage) from acetazolamide use.
7. IIH patients on acetazolamide as the only diuretic did not need potassium supplementation.

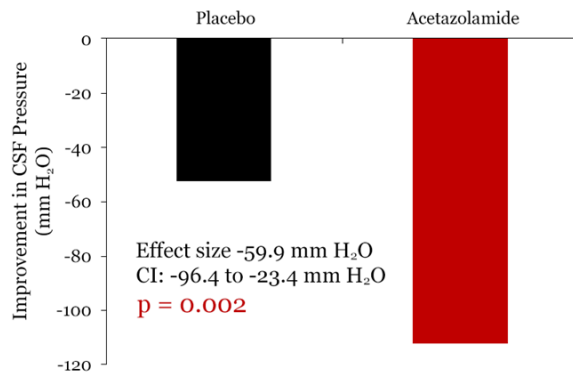
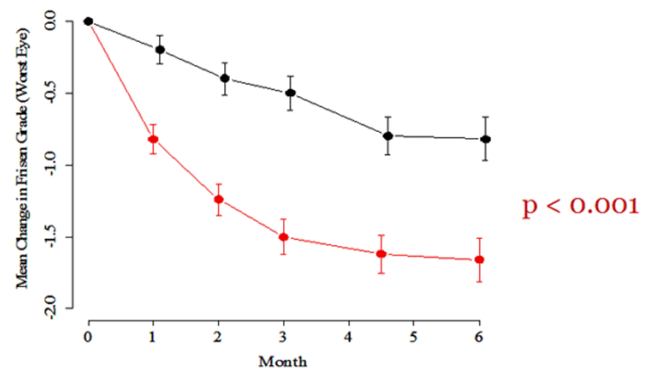


Figure 3. Change in CSF pressure. Both the placebo-plus-diet in black and acetazolamide-plus-diet groups in red improved from baseline but the acetazolamide-plus-diet group improved about twice as much.



Grades of Papilledema

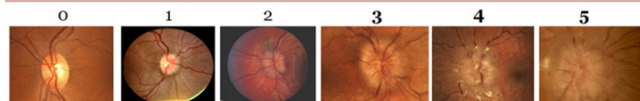


Figure 4. Change in papilledema grade. Both groups improved from baseline but the acetazolamide-plus-diet group in red improved much more.

What are the broader implications of the findings in terms of clinical relevance?

The broad implication is that for the first time, there is evidence from a randomized clinical trial that acetazolamide combined with a low sodium weight reduction program improves vision, reduces optic nerve head swelling, reduces intracranial pressure and shows improvement in quality of life measures. The main implication is there is now scientific evidence that acetazolamide improves vision in idiopathic intracranial hypertension while improving quality of life.

What does it mean that the main outcome article concluded the clinical importance of the improvement in visual field function is modest and yet to be determined?

While acetazolamide caused a *statistically* significant effect on visual field function in this group of patients with mild visual loss, the effect size of 0.71 dB may not be a *clinically*-significant amount of visual improvement. However, visual quality of life measures were statistically and clinically significantly better in the acetazolamide group compared with the placebo group. This suggests the effect is clinically significant.

Taking into account the IIHTT study design and methods, results, and limitations, how should clinicians apply the findings to patient management?

In patients with mild visual loss acetazolamide in the maximally tolerated dosage coupled with a low sodium weight loss program (with a goal of 6% total weight loss) should be used. This is especially true in patients with moderate to marked papilledema. There was three times the visual field improvement in subjects with high degrees of papilledema than with low grade papilledema. Since acetazolamide in the maximally tolerated dosage plus diet significantly lowers CSF pressure, improves general and visual quality of life scores and reduces papilledema, this combination is suggested for all patients with mild visual loss.

Patients without visual loss that have grades one or two papilledema may be managed with diet alone. They should be followed closely and if they worsen, acetazolamide can be added. Patients with worse than -7 dB mean deviation can be treated with this medical regimen or surgery but there are no clinical trials to guide therapy. A reasonable compromise in these patients would be to start treatment with acetazolamide-plus-diet and go to surgery if there is any worsening.

Treatment of Nystagmus and Saccadic Oscillations

Matthew J. Thurtell, MBBS FRACP and John J. Brinkley, MD

June 23, 2013

Introduction

Nystagmus is often encountered in ophthalmology practice, having a prevalence of about 24 per 10,000 in the general population.[1] Unlike physiologic nystagmus, where the slow phases of nystagmus minimize retinal image slip, the slow phases of pathologic nystagmus cause retinal image slip. Retinal image slip of greater than 5 degrees per second produces a decline in visual acuity, partly because the image of the object of interest no longer lies on the fovea, and illusory motion of the visual environment known as oscillopsia.[2,3] Saccadic intrusions and oscillations can also cause visual symptoms, such as difficulty reading, since they take the eye off target so that the image of the object of interest no longer lies on the fovea.[2]

Goals of Treatment

The goal of treatment is to reduce visual symptoms (e.g., blurred vision, oscillopsia) by reducing the speed of nystagmus slow phases or by suppressing saccadic oscillations. Treatments that stop the eyes from moving altogether (e.g., botulinum toxin injections into the extraocular muscles) are not ideal, because they cause oscillopsia during head movements (due to loss of the vestibulo-ocular reflex) and diplopia (due to loss of vergence eye movements).[2] Thus, treatments that suppress the abnormal eye movements without affecting normal eye movements are preferred. Note that some types of nystagmus (e.g., gaze-evoked) and saccadic intrusions (e.g., square-wave jerks) do not usually give visual symptoms and, thus, do not require specific treatment.

General Approaches to Treatment

Treatments for nystagmus that have been proposed include medical, optical, surgical, and other miscellaneous treatments (Table 1); few of these have been evaluated in prospective masked clinical trials.[2,4] Likewise, a variety of treatments for saccadic oscillations have been proposed; few have been evaluated in prospective masked clinical trials.[2] Most treatments aim to suppress the abnormal eye movements without affecting normal eye movements, whereas others aim to negate the visual consequences of the abnormal eye movements. Choice of treatment depends on the type of nystagmus or saccadic oscillation and its characteristics. While some patients will derive benefit from one treatment approach, others require a combination of treatments.[2,4]

Treatment of Acquired Forms of Nystagmus

Medical treatments are usually the most effective for treating acquired forms of nystagmus. Optical, surgical, and other treatments can also be helpful. The dosing and common side-effects of medical treatments for acquired forms of nystagmus are summarized in Table 2.[5]

Peripheral Vestibular Nystagmus

Nystagmus can result from peripheral vestibular diseases, such as vestibular neuritis, Ménière's disease, and benign paroxysmal positional vertigo. In most cases, the nystagmus is short-lived or intermittent. The associated vertigo, nausea, and vomiting are often more distressing to the patient than are the visual symptoms from the nystagmus. Consequently, the patient is best managed with treatments directed towards the underlying disorder.[6]

Video <https://collections.lib.utah.edu/details?id=180306>

Downbeat Nystagmus

Downbeat nystagmus is common and often causes disabling visual symptoms (e.g., vertical oscillopsia). Many affected patients seek treatment. Clonazepam, a GABA_A-agonist, has been shown to improve downbeat nystagmus in two uncontrolled trials.[7,8] Baclofen, a GABA_B-agonist, was thought to suppress downbeat nystagmus,[9,10] but did not produce a consistent benefit in a double-masked trial.[11] Gabapentin, now thought to act as an $\alpha 2\delta$ -1 calcium channel antagonist[12] and N-methyl-D-aspartate (NMDA) receptor antagonist,[13] did not consistently improve downbeat nystagmus in the same trial.[11] Anticholinergics have been suggested as a potential treatment.[14] However, a prospective double-masked trial showed

Table 1: Proposed Treatments for Nystagmus[4]

Treatment Approach	Examples
Medical	Gabapentin Memantine 4-aminopyridine 3,4-diaminopyridine Baclofen Clonazepam Valproate Trihexyphenidyl Benztropine Scopolamine Isoniazid Carbamazepine Barbiturates Alcohol Acetazolamide Brinzolamide (topical) Cannabis
Optical	Contact lenses Contact lens and spectacle combinations Prisms Electro-optical devices
Surgical	Anderson-Kestenbaum procedure Cüppers' divergence procedure Recession of rectus muscles Tenotomy and reattachment procedure
Other (Miscellaneous)	Botulinum toxin Acupuncture Biofeedback Cutaneous stimulation

that trihexyphenidyl produced only a modest improvement with significant side-effects.[15]

Recent trials have demonstrated that the aminopyridine potassium channel blockers are effective for downbeat nystagmus. 3,4-diaminopyridine and 4-aminopyridine have been shown to suppress downbeat nystagmus, although they are more effective in patients with cerebellar degenerations and less effective in those with focal cerebellar lesions.[16,17] 4-aminopyridine appears to be more effective than 3,4-diaminopyridine.[18] Both drugs are well tolerated, although they can cause seizures (usually in patients with a predisposition to epilepsy who are given high dosages) and cardiac arrhythmias in patients with QT inter-

val prolongation. The mechanism by which they suppress downbeat nystagmus is unclear, although they might work by altering the firing of cerebellar Purkinje cells.[19] 3,4-diaminopyridine has been shown to modulate the gravity-dependence of downbeat nystagmus and, thus, might suppress the nystagmus by modulating otolithic pathways.[20] An extended-release formulation of 4-aminopyridine is available in the US and is approved for the treatment of gait difficulties in multiple sclerosis (MS) patients.[21] At present, the aminopyridines are first-line treatment for downbeat nystagmus (see Table 2 for recommended dosing). In those who do not respond, a trial of clonazepam could be considered (Table 2). Surgery (e.g., tenotomy and reattachment) can be considered for treating severe in-

Table 2: Drug Treatments for Acquired Nystagmus[5]

Nystagmus Type	Treatment (dose, frequency)	Common Side-Effects
Peripheral Vestibular Nystagmus	Treatment of underlying disorder	Not applicable
Downbeat Nystagmus	4-aminopyridine (5-10mg, tid)	Dizziness, paresthesias, incoordination
	3,4-diaminopyridine (10-20mg, tid)	Dizziness, paresthesias, incoordination
	Clonazepam (0.5-1mg, bid)	Drowsiness, dizziness, incoordination
Upbeat Nystagmus	Memantine (10mg, qid)	Lethargy, dizziness, headache
	4-aminopyridine (5-10mg, tid)	Dizziness, paresthesias, incoordination
	Baclofen (5-10mg, tid)	Drowsiness, dizziness, lethargy
Torsional Nystagmus	Gabapentin (300mg, qid)	Dizziness, incoordination, drowsiness
Seesaw Nystagmus	Alcohol	Drowsiness, incoordination, vomiting
	Clonazepam (0.5-1mg, bid)	Drowsiness, dizziness, incoordination
	Memantine (10mg, qid)	Lethargy, dizziness, headache
Periodic Alternating Nystagmus	Baclofen (5-10mg, tid)	Drowsiness, dizziness, lethargy
	Memantine (5-10mg, qid)	Lethargy, dizziness, headache
Acquired Pendular Nystagmus in MS	Gabapentin (300mg, qid)	Dizziness, incoordination, drowsiness
	Memantine (10mg, qid)	Lethargy, dizziness, headache
Acquired Pendular Nystagmus in OPT	Gabapentin (300mg, qid)	Dizziness, incoordination, drowsiness
	Memantine (10mg, qid)	Lethargy, dizziness, headache
	Trihexyphenidyl (5-20mg, tid)	Dry mouth, blurred vision, dizziness

Abbreviations: bid, twice daily; MS, multiple sclerosis; OPT, oculopalatal tremor; qid, four times daily; tid, three times daily

tractable oscillopsia in patients with downbeat nystagmus, either alone or in combination with medical therapy,[22] but clinical trials are yet to be performed.

Video <https://collections.lib.utah.edu/details?id=180371>

Upbeat Nystagmus

Upbeat nystagmus can produce vertical oscillopsia, but the nystagmus resolves spontaneously; long-term treatment is only required if it is persistent. There have been very few clinical trials evaluating proposed treatments. One uncontrolled trial reported a benefit with baclofen. [9] A prospective double-masked cross-over trial reported reduction of upbeat nystagmus or upbeat components of nystagmus with memantine, a non-competitive NMDA receptor antagonist, but not with gabapentin.[23] In another study, 4-aminopyridine suppressed upbeat nystagmus in one patient.[24] A trial of memantine, 4-aminopyridine,

or baclofen could be considered in patients with visual symptoms from persistent upbeat nystagmus (see Table 2 for recommended dosing).

Video: <https://collections.lib.utah.edu/details?id=180329>

Torsional Nystagmus

Torsional nystagmus can cause disabling oscillopsia. However, there have been very few clinical trials evaluating proposed treatments. A double-masked cross-over trial reported a modest reduction with gabapentin, but little response to memantine, in a single patient.[23] While further studies are required to identify medications that suppress torsional nystagmus, a trial of gabapentin could be considered in patients with visual symptoms from persistent torsional nystagmus (see Table 2 for recommended dosing).

Video: <https://collections.lib.utah.edu/details?id=180297>

Seesaw Nystagmus

Acquired seesaw nystagmus is rarely encountered, but can give rise to disabling oscillopsia. Several small studies have suggested that pendular seesaw nystagmus can be suppressed by alcohol or clonazepam in individual patients.[25-27] A double-masked cross-over trial reported that the jerk form (hemi-seesaw nystagmus) can be suppressed with gabapentin or memantine.[23] Treatment with clonazepam, gabapentin, or memantine could be considered in patients with visual symptoms from persistent seesaw nystagmus (see Table 2 for recommended dosing).

Video: <https://collections.lib.utah.edu/details?id=188591>

Periodic Alternating Nystagmus

Patients with acquired periodic alternating nystagmus often complain of oscillopsia. Several non-randomized and non-controlled studies have reported complete suppression of the nystagmus with baclofen.[28-30] The efficacy of baclofen in treating periodic alternating nystagmus has been confirmed in primates.[31] A benefit from memantine has been reported in a patient whose nystagmus was refractory to baclofen.[32] At present, baclofen is considered first-line treatment for acquired periodic alternating nystagmus, while memantine could be tried in those patients who do not respond to baclofen (see Table 2 for recommended dosing).

Video <https://collections.lib.utah.edu/details?id=180294>

Acquired Pendular Nystagmus in Multiple Sclerosis

Acquired pendular nystagmus (APN) can occur in patients with multiple sclerosis (MS) and causes disabling visual symptoms. The hypothesis that it arises due to instability of the ocular motor neural integrator led to testing of drugs thought to have effects on GABA- and glutamate-mediated mechanisms. GABAergic drugs (e.g., clonazepam, valproate, and isoniazid) were found to help some patients in early studies.[33,34] The effects of gabapentin, which was initially thought to have GABAergic effects, were compared with those of baclofen in a double-masked study including patients with APN.[11] Visual acuity improved with gabapentin, but not baclofen, and only gabapentin reduced median nystagmus slow phase speed. However, some patients had no response to gabapentin or reported severe side-effects (e.g., ataxia). Gabapentin was subsequently compared with vigabatrin, which is known to be purely GABAergic.[35] Gabapentin suppressed APN, but vigabatrin did not, suggesting that gabapentin might suppress APN by a non-GABAergic mechanism; gabapentin

is now thought to exert its effect via the $\alpha\delta$ -1 calcium channel subunit[12] and NMDA receptors.[13] Two recent prospective masked trials have confirmed that gabapentin is often effective in suppressing APN in MS, but not all patients respond.[23,36]

Several prospective masked trials have demonstrated that memantine can suppress APN in patients with MS when given in doses of 40-60mg per day.[23,36,37] It can reduce APN in those patients who do not respond to gabapentin.[23,37] However, patients with MS can develop a reversible exacerbation of MS symptoms when receiving 30mg or more of memantine per day[38] and, thus, gabapentin may be the preferred initial treatment for APN in MS (see Table 2 for recommended dosing). There is a potential role for combining drug therapies (e.g., gabapentin and memantine), but no clinical trials have been conducted to date. Surgery (e.g., tenotomy and reattachment) might also be effective in suppressing APN in patients with severe intractable oscillopsia,[22] but should not be routinely recommended as clinical trials are yet to be performed.

Video: <https://collections.lib.utah.edu/details?id=180282>

Acquired Pendular Nystagmus in Oculopalatal Tremor

The nystagmus of oculopalatal tremor (OPT) often causes severe intractable oscillopsia. Several studies have evaluated the effect of anticholinergic agents on the nystagmus of OPT. Although individual patients can respond to trihexyphenidyl,[39,40] it was only modestly effective in a prospective masked trial.[15] A prospective double-masked trial comparing intravenously-administered scopolamine, benztrapine, and glycopyrrolate found that scopolamine reduced the nystagmus of OPT, whereas benztrapine was less effective, and glycopyrrolate had no effect.[14] However, treatment with intravenous scopolamine resulted in significant side-effects and is not practical for day-to-day treatment. Transdermal scopolamine was also found to be unreliable, given that it can make the nystagmus worse in some patients or cause significant side-effects.[41] Two prospective double-masked cross-over trials have demonstrated that gabapentin and memantine can suppress the nystagmus of OPT.[11,23] Although the nystagmus of OPT is often more refractory to treatment with gabapentin and memantine than is APN due to MS, a trial of therapy is worthwhile (see Table 2 for recommended dosing). There is a potential role for combined drug therapies (e.g., gabapentin and memantine) or surgical therapy (e.g., tenotomy and reattachment), but these treatment approaches have not been evaluated in clinical trials.

Treatment of Congenital Forms of Nystagmus

Treatment for congenital forms of nystagmus depends on the severity of visual symptoms, severity of any associated afferent visual system anomalies, and the characteristics of the nystagmus itself.[2,4] Some patients do not have visual symptoms, especially if “foveation periods” are well developed, and most do not complain of oscillopsia.[42] Those with impaired vision might have so due to afferent visual system anomalies (e.g., optic nerve or foveal hypoplasia),[2] such that suppression of the nystagmus does not produce a significant improvement in vision. However, patients with visual symptoms with intact afferent visual systems can benefit from treatments that suppress the nystagmus.[2,4]

Infantile Nystagmus Syndrome

Infantile nystagmus can be treated using optical, surgical, and medical approaches.[2,4] Optical treatments are simple, safe, and may be all that is required to improve vision. Correction of refractive error alone might bring about an appreciable improvement in vision.[43,44] Use of contact lenses might be preferred over spectacle lenses, because contact lenses often suppress infantile nystagmus by an uncertain mechanism.[45] Spectacle lenses are preferred in patients whose nystagmus suppresses with convergence, because prism can be added to induce convergence, and thereby suppress the nystagmus and improve visual acuity, during viewing of far targets.[46] Sufficient convergence can be produced by a pair of 7 diopter base-out prisms with -1 diopter sphere added to compensate for the accompanying accommodation.

Several surgical procedures can be considered for treatment of infantile nystagmus. The Anderson-Kestenbaum procedure aims to move the attachments of the extraocular muscles, so that the null point of the nystagmus is shifted to the straight ahead position.[47,48] The Anderson-Kestenbaum procedure also leads to decreased nystagmus intensity outside of the null zone and may improve head posture.[49-51] However, selection of patients who will benefit requires measurement of visual acuity and nystagmus in different gaze positions. Cüppers’ divergence procedure can be effective in patients whose nystagmus suppresses with convergence; the procedure diverges the eyes, so that the patient is required to converge during far viewing.[52,53] In some patients, combining the Anderson-Kestenbaum and Cüppers’ divergence procedures can produce a better outcome than either procedure alone.[53] Another surgical approach involves large recessions of the horizontal rectus muscles,[54-58] sometimes in combination with other procedures,[59] to produce sup-

pression of the nystagmus. However, the nystagmus can increase following an initial improvement, due to adaptive changes. It has been observed that some suppression of the nystagmus and broadening of the null zone follows almost all surgical procedures for infantile nystagmus, which led to the suggestion that merely detaching the muscles, dissecting the perimuscular fascia, and re-attaching them at the same site (“tenotomy and reattachment”) might suppress the nystagmus.[60] Studies in a canine model support this hypothesis.[61] Clinical trials indicate that some patients treated with tenotomy and reattachment show improvement in some measures of visual and ocular motor function following horizontal rectus surgery,[62-64] but not all reports agree.[65] Since the operation may have its effects by disrupting extraocular proprioceptive feedback signals, variations on the original procedure have been proposed.[66] Carefully selected patients with infantile nystagmus can benefit from surgical treatments that are tailored to their individual visual and ocular motor findings: (1) if there is a narrow eccentric null zone, then the Anderson-Kestenbaum procedure could be considered; (2) if the nystagmus is reduced with convergence, then Cüppers’ divergence procedure could be considered; and (3) if neither of these conditions apply, then tenotomy and reattachment could be considered. Patients with infantile nystagmus and afferent visual system anomalies (e.g., oculo-cutaneous albinism) are less likely to benefit from surgical intervention.[67]

Medical treatments of infantile nystagmus are less favorable, since they would need to be given life-long and can cause side-effects. A randomized, controlled, double-masked trial comparing gabapentin and memantine found that the nystagmus intensity and visual acuity improved in both treatment groups.[68] However, patients with afferent visual system anomalies derived only a small benefit. Recent studies have reported that infantile nystagmus might be suppressed with carbonic anhydrase inhibitors, including oral acetazolamide and topical brinzolamide.[69,70] Infantile nystagmus can also be reduced after smoking cannabis.[71] Lastly, gene therapy holds the potential for treatment of nystagmus associated with congenital retinal disorders. For example, in an animal model of Leber’s congenital amaurosis, successful gene therapy restored vision and reduced the associated nystagmus.[72-75]

Other Congenital Forms of Nystagmus

The treatment options for other congenital forms of nystagmus are limited. Treatment for latent nystagmus (fusional maldevelopment nystagmus syndrome) consists of measures to improve vision, such as correction of refractive error and treatment of amblyopia.[2,4] Spasmus nutans syndrome typically resolves spontaneously and does not require specific intervention.[2,4]

Treatment of Intractable Nystagmus

There are several treatment options for patients who do not respond to the approaches listed above. Optical devices that negate the visual effects of the nystagmus can be tried. One such approach consists of using high-plus spectacle lenses in combination with high-minus contact lenses.[2,4,76] While the visual effects of the nystagmus can be effectively negated using this approach, it is only useful when the patient is stationary and viewing monocularly, since the visual effects of normal eye movements are also negated.[77] Another approach involves use of an electro-optical device, which measures the ocular oscillations and incorporates image-shifting optics to negate, in real-time, their visual effects.[78] Electro-optical devices are best suited for patients with pendular forms of nystagmus, since the abnormal eye movements can be more easily distinguished from normal eye movements, but these devices remain experimental and are not yet commercially available. Treatments to stop the eyes from moving altogether, such as botulinum toxin injections into the extraocular muscles, can also be considered in patients with intractable nystagmus. While the injections can lead to reduced oscillopsia and improved visual acuity, patients often develop diplopia and ptosis.[79-84] Furthermore, normal eye movements are impaired and the treatment is only effective for several weeks to months, making botulinum toxin injections limited in therapeutic value.[2,4]

Treatment of Saccadic Oscillations

The treatment of saccadic oscillations depends on whether the patient has visual symptoms from the oscillations. Some forms of saccadic oscillation, such as square-wave jerks, do not cause visual symptoms and, thus, do not require specific treatment.[2] For saccadic oscillations that cause visual symptoms, medical treatments are most effective.[2]

Macrosaccadic Oscillations

Macrosaccadic oscillations often result in difficulty with reading, but there are few clinical trials investigating proposed treatments. Memantine reduced the frequency of the oscillations and improved reading ability in one family with macrosaccadic oscillations due to cerebellar ataxia and, thus, could be considered in patients with symptomatic macrosaccadic oscillations.[85]

Ocular Flutter and Opsoclonus

Ocular flutter and opsoclonus can produce oscillopsia. When due to brainstem encephalitis, treatment with intravenous immunoglobulin (IVIg), corticosteroids, azathioprine, or monoclonal antibodies directed against B-lymphocytes can speed recovery.[86-88] In adults with paraneoplastic opsoclonus, treatment of the underlying tumor can produce an improvement in the oscillations.[87] Plasmapheresis, IVIg, and immunoabsorption therapy can also be effective.[89-91] Opsoclonus in children with neural crest tumors often responds to corticosteroids[92] and sometimes to IVIg.[93] New therapies with monoclonal antibodies directed against B-lymphocytes may be effective.[88] Occasional patients gain a benefit from medications, such as gabapentin,[94] but formal clinical trials have not been conducted.

[Ocular Flutter](#) Video:

<https://collections.lib.utah.edu/details?id=180316>

[Opsoclonus](#) Video:

<https://collections.lib.utah.edu/details?id=180305>

References

1. Sarvananthan, N., Surendran, M., Roberts, E.O., et al.: The prevalence of nystagmus: the Leicestershire nystagmus survey, *Invest Ophthalmol Vis Sci* 50:5201-5206, 2009.
2. Thurtell, M.J., Leigh, R.J.: Nystagmus and saccadic intrusions, *Handb Clin Neurol* 102:333-378, 2011.
3. Demer, J.L., Amjadi, F.: Dynamic visual acuity of normal subjects during vertical optotype and head motion, *Invest Ophthalmol Vis Sci* 34:1894-1906, 1993.
4. Thurtell, M.J., Leigh, R.J.: Therapy for nystagmus, *J Neuroophthalmol* 30:361-371, 2010.
5. Thurtell, M.J., Rucker, J.C., Tomsak, R.L., et al.: Medical treatment of acquired nystagmus, *Expert Rev Ophthalmol* 6:307-314, 2011.
6. Strupp, M., Thurtell, M.J., Shaikh, A.G., et al.: Pharmacotherapy of vestibular and ocular motor disorders, including nystagmus, *J Neurol* 258:1207-1222, 2011.
7. Currie, J.N., Matsuo, V.: The use of clonazepam in the treatment of nystagmus-induced oscillopsia, *Ophthalmology* 93:924-932, 1986.
8. Young, Y.H., Huang, T.W.: Role of clonazepam in the treatment of idiopathic downbeat nystagmus, *Laryngoscope* 111:1490-1493, 2001.
9. Dieterich, M., Straube, A., Brandt, T., et al.: The effects of baclofen and cholinergic drugs on upbeat and downbeat nystagmus, *J Neurol Neurosurg Psychiatry* 54:627-632, 1991.
10. Kastrup, O., Maschke, M., Keidel, M., et al.: Presumed

- pharmacologically induced change from upbeat- to downbeat nystagmus in a patient with Wernicke's encephalopathy, *Clin Neurol Neurosurg* 107:70-72, 2004.
11. Averbuch-Heller, L., Tusa, R.J., Fuhry, L., et al.: A double-blind controlled study of gabapentin and baclofen as treatment for acquired nystagmus, *Ann Neurol* 41:818-825, 1997.
 12. Bauer, C.S., Nieto-Rostro, M., Rahman, W., et al.: The increased trafficking of the calcium channel subunit $\alpha_2\delta_1$ to presynaptic terminals in neuropathic pain is inhibited by the $\alpha_2\delta_1$ ligand pregabalin, *J Neurosci* 29:4076-4088, 2009.
 13. Kim, Y.S., Chang, H.K., Lee, J.W., et al.: Protective effect of gabapentin on N-methyl-D-aspartate-induced excitotoxicity in rat hippocampal CA1 neurons, *J Pharmacol Sci* 109:144-147, 2009.
 14. Barton, J.J., Huaman, A.G., Sharpe, J.A.: Muscarinic antagonists in the treatment of acquired pendular and downbeat nystagmus: a double-blind, randomized trial of three intravenous drugs, *Ann Neurol* 35:319-325, 1994.
 15. Leigh, R.J., Burnstine, T.H., Ruff, R.L., et al.: The effect of anticholinergic agents upon acquired nystagmus: a double-blind study of trihexyphenidyl and tridihexethyl chloride, *Neurology* 41:1737-1741, 1991.
 16. Strupp, M., Schuler, O., Krafczyk, S., et al.: Treatment of downbeat nystagmus with 3,4-diaminopyridine: a placebo-controlled study, *Neurology* 61:165-170, 2003.
 17. Kalla, R., Glasauer, S., Schautzer, F., et al.: 4-aminopyridine improves downbeat nystagmus, smooth pursuit, and VOR gain, *Neurology* 62:1228-1229, 2004.
 18. Kalla, R., Spiegel, R., Claassen, J., et al.: Comparison of 10-mg doses of 4-aminopyridine and 3,4-diaminopyridine for the treatment of downbeat nystagmus, *J Neuroophthalmol*, 2011.
 19. Glasauer, S., Rossert, C.: Modelling drug modulation of nystagmus, *Prog Brain Res* 171:527-534, 2008.
 20. Helmchen, C., Sprenger, A., Rambold, H., et al.: Effect of 3,4-diaminopyridine on the gravity dependence of ocular drift in downbeat nystagmus, *Neurology* 63:752-753, 2004.
 21. Hauser, S.L., Johnston, S.C.: 4-aminopyridine: new life for an old drug, *Ann Neurol* 68:A8-A9, 2010.
 22. Tomsak, R.L., Dell'Osso, L.F., Jacobs, J.B., et al.: Eye muscle surgery for acquired forms of nystagmus. In: Leigh, R.J., Devereaux, M.W. (Eds): *Advances in Understanding Mechanisms and Treatment of Infantile Forms of Nystagmus*. New York: Oxford University Press, 2008:112-116.
 23. Thurtell, M.J., Joshi, A.C., Leone, A.C., et al.: Crossover trial of gabapentin and memantine as treatment for acquired nystagmus, *Ann Neurol* 67:676-680, 2010.
 24. Glasauer, S., Kalla, R., Büttner, U., et al.: 4-aminopyridine restores visual ocular motor function in upbeat nystagmus, *J Neurol Neurosurg Psychiatry* 76:451-453, 2005.
 25. Frisé, L., Wikkelsø, C.: Posttraumatic seesaw nystagmus abolished by ethanol ingestion, *Neurology* 36:841-844, 1986.
 26. Lepore, F.E.: Ethanol-induced reduction of pathological nystagmus, *Neurology* 37:887, 1987.
 27. Cochlin, J.P., Hannequin, D., Domarcolino, C., et al.: Intermittent see-saw nystagmus abolished by clonazepam, *Rev Neurol (Paris)* 151:60-62, 1995.
 28. Halmagyi, G.M., Rudge, P., Gresty, M.A., et al.: Treatment of periodic alternating nystagmus, *Ann Neurol* 8:609-611, 1980.
 29. Furman, J.M., Wall, C., Pang, D.: Vestibular function in periodic alternating nystagmus, *Brain* 113:1425-1439, 1990.
 30. Garbutt, S., Thakore, N., Rucker, J.C., et al.: Effects of visual fixation and convergence in periodic alternating nystagmus due to MS, *Neuroophthalmology* 28:221-229, 2004.
 31. Cohen, B., Dai, M., Yakushin, S.B., et al.: Baclofen, motion sickness susceptibility and the neural basis for velocity storage, *Prog Brain Res* 171:543-553, 2008.
 32. Kumar, A., Thomas, S., McLean, R., et al.: Treatment of acquired periodic alternating nystagmus with memantine: a case report, *Clin Neuropharmacol* 32:109-110, 2009.
 33. Lefkowitz, D., Harpold, G.: Treatment of ocular myoclonus with valproic acid, *Ann Neurol* 17:103-104, 1985.
 34. Traccis, S., Rosati, G., Monaco, M.F., et al.: Successful treatment of acquired pendular elliptical nystagmus in multiple sclerosis with isoniazid and base-out prisms, *Neurology* 40:492-494, 1990.
 35. Bandini, F., Castello, E., Mazzella, L., et al.: Gabapentin but not vigabatrin is effective in the treatment of acquired nystagmus in multiple sclerosis: how valid is the GABAergic hypothesis? *J Neurol Neurosurg Psychiatry* 71:107-110, 2001.
 36. Starck, M., Albrecht, H., Pöhlmann, W., et al.: Acquired pendular nystagmus in multiple sclerosis: an examiner-blind cross-over treatment study of memantine and gabapentin, *J Neurol* 257:322-327, 2010.
 37. Starck, M., Albrecht, H., Straube, A., et al.: Drug therapy for acquired pendular nystagmus in multiple sclerosis, *J Neurol* 244:9-16, 1997.
 38. Villoslada, P., Arrondo, G., Sepulcre, J., et al.: Memantine induces reversible neurologic impairment in

- patients with MS, *Neurology* 72:1630-1633, 2009.
39. Herishanu, Y., Louzoun, Z.: Trihexyphenidyl treatment of vertical pendular nystagmus, *Neurology* 36:82-84, 1986.
 40. Jabbari, B., Rosenberg, M., Scherokman, B., et al.: Effectiveness of trihexyphenidyl against pendular nystagmus and palatal myoclonus: evidence of cholinergic dysfunction, *Mov Disord* 2:93-98, 1987.
 41. Kim, J.I., Averbuch-Heller, L., Leigh, R.J.: Evaluation of transdermal scopolamine as treatment for acquired nystagmus, *J Neuroophthalmol* 21:188-192, 2001.
 42. Abadi, R.V., Whittle, J.P., Worfolk, R.: Oscillopsia and tolerance to retinal image movement in congenital nystagmus, *Invest Ophthalmol Vis Sci* 40:339-345, 1999.
 43. Anderson, J., Lavoie, J., Merrill, K., et al.: Efficacy of spectacles in persons with albinism, *J AAPOS* 8:515-520, 2004.
 44. Hertle, R.W.: Examination and refractive management of patients with nystagmus, *Surv Ophthalmol* 45:215-222, 2000.
 45. Dell'Osso, L.F., Traccis, S., Erzurum, S.I.: Contact lenses and congenital nystagmus, *Clinical Vision Science* 3:229-232, 1988.
 46. Serra, A., Dell'Osso, L.F., Jacobs, J.B., et al.: Combined gaze-angle and vergence variation in infantile nystagmus: two therapies that improve the high-visual-acuity field and methods to measure it, *Invest Ophthalmol Vis Sci* 47:2451-2460, 2006.
 47. Anderson, J.R.: Causes and treatment of congenital eccentric nystagmus, *Br J Ophthalmol* 37:267-281, 1953.
 48. Kestenbaum, A.: Nouvelle operation de nystagmus, *Bull Soc Ophtalmol Fr* 6:599-602, 1953.
 49. Lee, I.S., Lee, J.B., Kim, H.S., et al.: Modified Kestenbaum surgery for correction of abnormal head posture in infantile nystagmus: outcome in 63 patients with graded augmentation, *Binocul Vis Strabismus Q* 15:53-58, 2000.
 50. Chang, Y.H., Chang, J.H., Han, S.H., et al.: Outcome study of two standard and graduated augmented modified Kestenbaum surgery protocols for abnormal head postures in infantile nystagmus, *Binocul Vis Strabismus Q* 22:235-241, 2007.
 51. Gupta, R., Sharma, P., Menon, V.: A prospective clinical evaluation of augmented Anderson procedure for idiopathic infantile nystagmus, *J AAPOS* 10:312-317, 2006.
 52. Cüppers', C.: Probleme der operativen therapie des okularen nystagmus, *Klin Mbl Augenheilk* 159:145-157, 1971.
 53. Sendler, S., Shallo-Hoffmann, J., Mühlendyck, H.: Die artifizielle-divergenz-operation beim kongenitale nystagmus, *Fortschr Ophthalmol* 87:85-89, 1990.
 54. von Noorden, G.K., Sprunger, D.T.: Large rectus muscle recession for the treatment of congenital nystagmus, *Arch Ophthalmol* 109:221-224, 1991.
 55. Helveston, E.M., Ellis, F.D., Plager, D.A.: Large recession of the horizontal recti for treatment of nystagmus, *Ophthalmology* 98:1302-1305, 1991.
 56. Alio, J.L., Chipont, E., Mulet, E., et al.: Visual performance after congenital nystagmus surgery using extended hang back recession of the four horizontal rectus muscles, *Eur J Ophthalmol* 13:415-423, 2003.
 57. Atila, H., Erkam, N., Isikcelik, Y.: Surgical treatment in nystagmus, *Eye* 13:11-15, 1999.
 58. Erbagci, I., Gungor, K., Bekir, N.A.: Effectiveness of ret-roequatorial recession surgery in congenital nystagmus, *Strabismus* 12:35-40, 2004.
 59. Arroyo-Yllanes, M.E., Fonte-Vazquez, A., Perez-Perez, J.F.: Modified Anderson procedure for correcting abnormal mixed head position in nystagmus, *Br J Ophthalmol* 86:267-269, 2002.
 60. Dell'Osso, L.F.: Development of new treatments for congenital nystagmus, *Ann N Y Acad Sci* 956:361-379, 2002.
 61. Dell'Osso, L.F., Hertle, R.W., Williams, R.W., et al.: A new surgery for congenital nystagmus: effects of tenotomy on an achiasmatic canine and the role of extraocular proprioception, *J AAPOS* 3:166-182, 1999.
 62. Hertle, R.W., Dell'Osso, L.F., FitzGibbon, E.J., et al.: Horizontal rectus tenotomy in patients with congenital nystagmus, *Ophthalmology* 110:2097-2105, 2003.
 63. Hertle, R.W., Dell'Osso, L.F., FitzGibbon, E.J., et al.: Horizontal rectus muscle tenotomy in children with infantile nystagmus syndrome: a pilot study, *J AAPOS* 8:539-548, 2004.
 64. Wang, Z.I., Dell'Osso, L.F.: Tenotomy procedure alleviates the "slow to see" phenomenon in infantile nystagmus syndrome: model prediction and patient data, *Vision Res* 48:1409-1419, 2008.
 65. Boyle, N.J., Dawson, E.L., Lee, J.P.: Benefits of ret-roequatorial four horizontal muscle recession surgery in congenital idiopathic nystagmus in adults, *J AAPOS* 10:404-408, 2006.
 66. Dell'Osso, L.F., Tomsak, R.L., Thurtell, M.J.: Two hypothetical nystagmus procedures: augmented tenotomy and reattachment and augmented tendon-suture (sans tenotomy), *J Pediatr Ophthalmol Strabismus* 46:337-344, 2009.
 67. Hertle, R.W., Anninger, W., Yang, D., et al.: Effects of extraocular muscle surgery on 15 patients with ocu-

- lo-cutaneous albinism (OCA) and infantile nystagmus syndrome (INS), *Am J Ophthalmol* 138:978-987, 2004.
68. McLean, R., Proudlock, F., Thomas, S., et al.: Congenital nystagmus: randomized, controlled, double-masked trial of memantine/gabapentin, *Ann Neurol* 61:130-138, 2007.
 69. Thurtell, M.J., Dell'Osso, L.F., Leigh, R.J., et al.: Effects of acetazolamide on infantile nystagmus syndrome waveforms: comparisons to contact lenses and convergence in a well-studied subject, *Open Ophthalmol J* 4:42-51, 2010.
 70. Dell'Osso, L.F., Hertle, R.W., Leigh, R.J., et al.: Effects of topical brinzolamide on infantile nystagmus syndrome waveforms: eyedrops for nystagmus, *J Neuroophthalmol* 31:228-233, 2011.
 71. Pradeep, A., Thomas, S., Roberts, E.O., et al.: Reduction of congenital nystagmus in a patient after smoking cannabis, *Strabismus* 16:29-32, 2008.
 72. Narfstrom, K., Katz, M.L., Bragadottir, R., et al.: Functional and structural recovery of the retina after gene therapy in the RPE65 null mutation dog, *Invest Ophthalmol Vis Sci* 44:1663-1672, 2003.
 73. Acland, G., Aguirre, G., Ray, J., et al.: Gene therapy restores vision in a canine model of childhood blindness, *Nature Genetics* 28:92-95, 2001.
 74. Jacobs, J.B., Dell'Osso, L.F., Hertle, R.W., et al.: Eye movement recordings as an effectiveness indicator of gene therapy in RPE65-deficient canines: implications for the ocular motor system, *Invest Ophthalmol Vis Sci* 47:2865-2875, 2006.
 75. Bennicelli, J., Wright, J.F., Komaromy, A., et al.: Reversal of blindness in animal models of leber congenital amaurosis using optimized AAV2-mediated gene transfer, *Mol Ther* 16:458-465, 2008.
 76. Rushton, D., Cox, N.: A new optical treatment for oscillopsia, *J Neurol Neurosurg Psychiatry* 50:411-415, 1987.
 77. Leigh, R.J., Rushton, D.N., Thurston, S.E., et al.: Effects of retinal image stabilization in acquired nystagmus due to neurologic disease, *Neurology* 38:122-127, 1988.
 78. Stahl, J.S., Lehmkuhle, M., Wu, K., et al.: Prospects for treating acquired pendular nystagmus with servo-controlled optics, *Invest Ophthalmol Vis Sci* 41:1084-1090, 2000.
 79. Helveston, E.M., Pogrebniak, A.E.: Treatment of acquired nystagmus with botulinum A toxin, *Am J Ophthalmol* 106:584-586, 1988.
 80. Leigh, R.J., Tomsak, R.L., Grant, M.P., et al.: Effectiveness of botulinum toxin administered to abolish acquired nystagmus, *Ann Neurol* 32:633-642, 1992.
 81. Tomsak, R.L., Remler, B.F., Averbuch-Heller, L., et al.: Unsatisfactory treatment of acquired nystagmus with retrobulbar botulinum toxin, *Am J Ophthalmol* 119:489-496, 1995.
 82. Ruben, S.T., Lee, J.P., Oneil, D., et al.: The use of botulinum toxin for treatment of acquired nystagmus and oscillopsia, *Ophthalmology* 101:783-787, 1994.
 83. Repka, M.X., Savino, P.J., Reinecke, R.D.: Treatment of acquired nystagmus with botulinum neurotoxin A, *Arch Ophthalmol* 112:1320-1324, 1994.
 84. Carruthers, J.: The treatment of congenital nystagmus with Botox, *J Pediatr Ophthalmol Strabismus* 32:306-308, 1995.
 85. Serra, A., Liao, K., Martinez-Conde, S., et al.: Suppression of saccadic intrusions in hereditary ataxia by memantine, *Neurology* 70:810-812, 2008.
 86. Pless, M., Ronthal, M.: Treatment of opsoclonus-myoclonus with high-dose intravenous immunoglobulin, *Neurology* 46:583-584, 1996.
 87. Bataller, L., Graus, F., Saiz, A., et al.: Clinical outcome in adult onset idiopathic or paraneoplastic opsoclonus-myoclonus, *Brain* 124:437-444, 2001.
 88. Pranzatelli, M.R., Tate, E.D., Travelstead, A.L., et al.: Immunologic and clinical responses to rituximab in a child with opsoclonus-myoclonus syndrome, *Pediatrics* 115:e115-e119, 2005.
 89. Engle, E.C., Hedley-White, T.: A 29-month-old girl with worsening ataxia, nystagmus, and subsequent opsoclonus and myoclonus, *New Engl J Med* 333:1995, 1995.
 90. Cher, L.M., Hochberg, F.H., Teruya, J., et al.: Therapy for paraneoplastic neurologic syndromes in six patients with protein A column immunoadsorption, *Cancer* 75:1678-1683, 1995.
 91. Nitschke, M., Hochberg, F., Dropcho, E.: Improvement of paraneoplastic opsoclonus-myoclonus after protein A column therapy, *New Engl J Med* 332:192, 1995.
 92. Koh, P.S., Raffensperger, J.G., Berry, S., et al.: Long-term outcome in children with opsoclonus-myoclonus and ataxia and coincident neuroblastoma, *J Pediatrics* 125:712-716, 1994.
 93. Fisher, P.G., Wechsler, D.S., Singer, H.S.: Anit-Hu antibody in a neuroblastoma-associated paraneoplastic syndrome, *Ped Neurol* 10:309-312, 1994.
 94. Moretti, R., Torre, P., Antonello, D., et al.: Opsoclonus-myoclonus syndrome: Gabapentin as a new therapeutic proposal, *Eur J Neurology* 7:455-456, 2000.

Suggested Citation Format

Thurtell MJ, Brinkley JJ. Treatment of Nystagmus and Saccadic Oscillations. June 23, 2013; Available from EyeRounds.org/tutorials/Nystagmus/ last updated: 6/24/2013

Tutorials

Oculoplastic Surgery

Benign Lesions of the External Periocular Tissues

A Tutorial

Lucas T. Lenci, MD; Christopher A. Kirkpatrick, MD; TJ Clark, MD; Amanda C. Maltry, MD; Nasreen A. Syed, MD; Richard C. Allen, MD, PhD; Erin M. Shriver, MD

June 14, 2017

Introduction

Part of the complete ophthalmic examination includes inspection of the eyelids and lashes. Anatomically, the eyelids are bordered superiorly by the eyebrow and inferiorly by the cheek. The majority of this area is covered superficially by a keratinizing stratified squamous epithelium. Because of this, the eyelid is prone to many of the same dermatologic lesions found elsewhere on the skin covered areas of the body.

The eyelids contain numerous specialized adnexal structures that differ depending on the location in the eyelids. The dermis lies deep to the epidermis and contains cilia, the sebaceous glands of Zeis, the apocrine sweat glands of Moll, eccrine sweat glands, and pilosebaceous units. Deep to the orbicularis near the eyelid margin lays a dense plaque of fibrous connective tissue known as the tarsal plate, which contains sebaceous meibomian glands. Finally the conjunctiva contains the accessory lacrimal glands of Wolfring and Krause as well as goblet cells. This tutorial details the common, benign lesions found on the eyelid. Malignant lesions of the eyelid (e.g., basal cell carcinoma, squamous cell carcinoma, sebaceous adenocarcinoma, malignant melanoma, etc.) are covered in a separate tutorial at <https://eyerounds.org/tutorials/malignant-lesions-of-ext-periocular-tissues>. This article is by no means an extensive discussion of every benign eyelid lesion; rather it serves as an overview/tutorial to guide diagnosis and treatment.

Chalazion

A chalazion is a chronic lipogranulomatous inflammatory process that occurs in the eyelid. It results from obstruction of the meibomian glands (deep chalazion) or Zeis glands (superficial chalazion) with subsequent leakage of the lipid contents into the surrounding tissues, inciting a granulomatous inflammatory process.

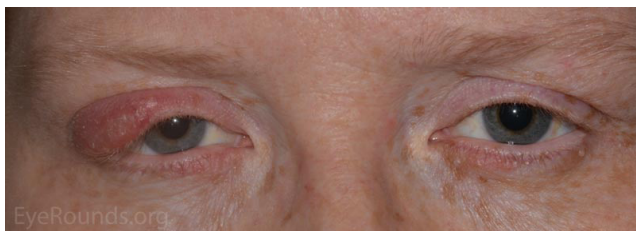

Figure 1: Chalazion

Presentation

Patients will present with a hard, painless nodule in the eyelid that slowly enlarges over the course of weeks to months. It may be the result of a hordeolum (see note below) or develop *de novo*. This process is commonly associated with rosacea and blepharitis.

Pathology

Pathology specimens classically show zonal lipogranulomatous inflammation centered on clear spaces previously filled with lipid ("lipid dropout" – an artifact of processing). There is a mixed inflammatory infiltrate that consists of neutrophils, plasma cells, lymphocytes, epithelioid histiocytes and multinucleate giant cells.

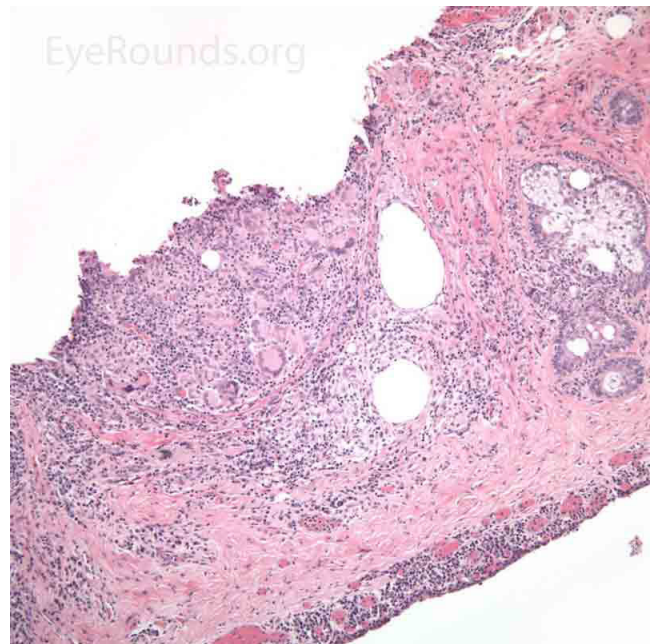


Figure 2: Chalazion pathology

Treatment options

- ◆ Hot compresses
- ◆ Lid hygiene
- ◆ Topical or oral antibiotics
- ◆ Surgical excision

Note

In contrast to a chalazion, a hordeolum (stye) is an acute, purulent inflammatory process of any gland (meibomian, Zeiss, Moll, or eccrine) in the eyelid that presents as a discrete, warm, erythematous, painful pustule over the course of a few days. The pathology is typified by a small, purulent abscess consisting of neutrophils and necrotic cellular debris centered on a hair follicle and its adjacent gland.

Xanthelasma

A Xanthelasma is a tumor consisting of intracellular accumulation of lipid. This lesion is typified by a collection of lipid-laden macrophages within the dermis.

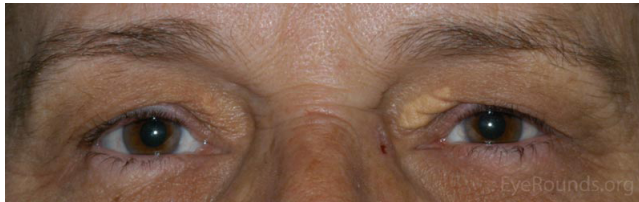

Figure 3: Xanthelasma

Presentation

The patient will present with multiple soft, yellowish plaques commonly found near the medial canthi of the upper and lower lids. These lesions are more common with increasing age and may be associated with disorders of lipid metabolism.

Pathology

The dermis will show a collection of histiocytes with foamy, lipid-laden cytoplasm that tend to cluster around blood vessels.

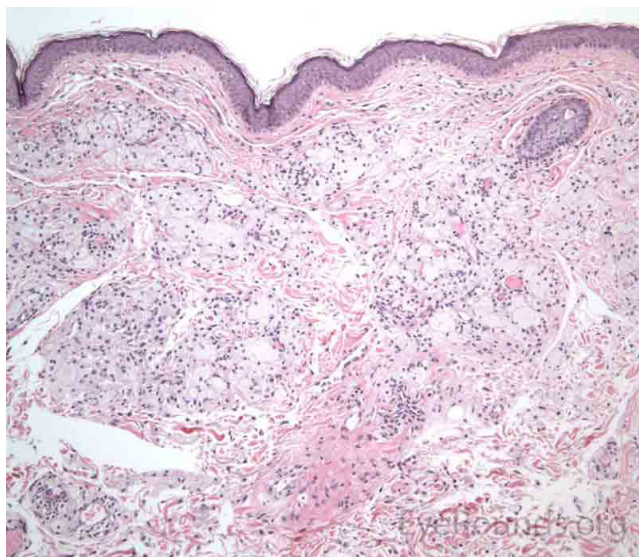


Figure 4: Xanthelasma pathology

Treatment options

- ◆ Surgical excision
- ◆ CO₂ laser
- ◆ Topical 100% trichloroacetic acid

Note

There is a high recurrence rate after treatment for xanthelasma.

Epidermal inclusion cyst (epidermoid cyst)

An epidermal inclusion cyst (EIC) is a dermal implantation cyst of epidermis. It can be congenital or acquired. The acquired form is usually in a site of prior trauma, which causes occlusion of the orifice of the hair follicle.

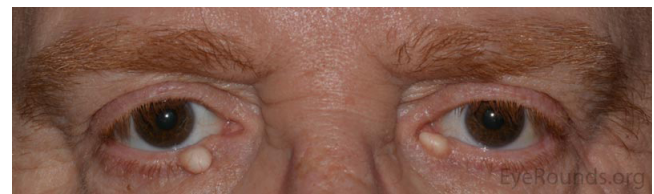

Figure 5: Epidermal inclusion cyst

Presentation

This often presents as a slow-growing, elevated, round, smooth, white lesion. These lesions do not trans-illuminate and can have a central pore that designates the remaining pilar duct. These lesions can become secondarily infected or rupture and incite an inflammatory reaction.

Pathology

A pathologic specimen of this process will show a cystic structure within the dermis that is lined by stratified squamous keratinizing epithelium with desquamated keratin in the cyst lumen. There are no dermal appendages in the cyst wall (this is the differentiating feature from a dermoid cyst).

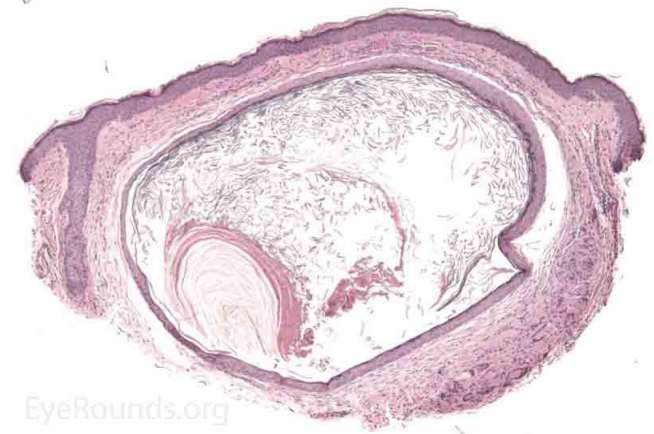


Figure 6: Epidermal inclusion cyst pathology

Treatment options

- ◆ Excision
- ◆ Marsupialization

Note

Milia are multiple, small epidermal inclusion cysts that are histologically identical to EIC and vary only in size. Cutaneous (not orbital) dermoid cysts are similar to EIC, but contain skin adnexal structures (hair, sweat/sebaceous glands) in the cyst wall. The cyst lumen also contains hair shafts and glandular secretions in addition to keratin.

Apocrine hidrocystoma

An apocrine hidrocystoma is a cyst that results from ductal occlusion of an apocrine sweat gland of Moll. It is considered a variant of an adenoma of the secretory cells of Moll rather than a retention cyst.

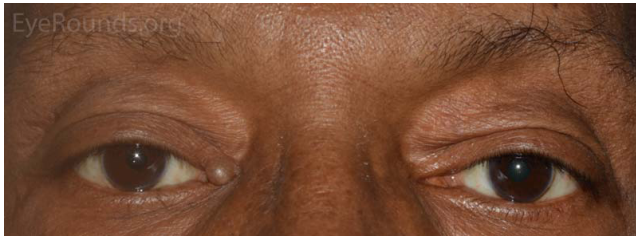

Figure 7: Apocrine hidrocystoma

Presentation

The patient will present with a solitary, round, smooth, cystic lesion located along the lid margin and commonly found near the canthi. These lesions are translucent and will trans-illuminate, but can occasionally take on a bluish tint.

Pathology

Pathology (figure 8) shows an irregular cystic structure within the dermis. The cyst is lined by a double layer of cuboidal epithelium with the inner-most (luminal) layer demonstrating apocrine differentiation (apical decapitation secretion).

Treatment options

- ◆ Marsupialization
- ◆ Excision

Note

Eccrine hidrocystoma is a ductal retention cyst resulting from occlusion of a duct of an eccrine sweat gland. These lesions are clinically and sometimes histologically indistinguishable from an apocrine hidrocystoma. These lesions are different in that they enlarge in conditions that stimulate perspiration (heat or humidity) and vary histologically as the cyst lumen is lined with a double layer of cuboidal epithelium without apocrine differentiation.

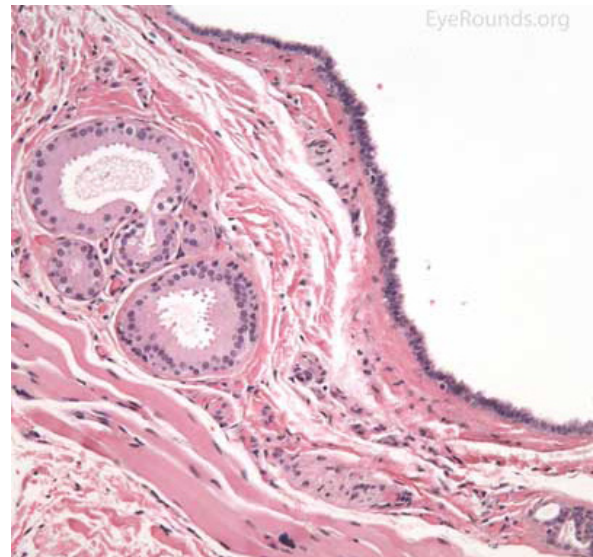
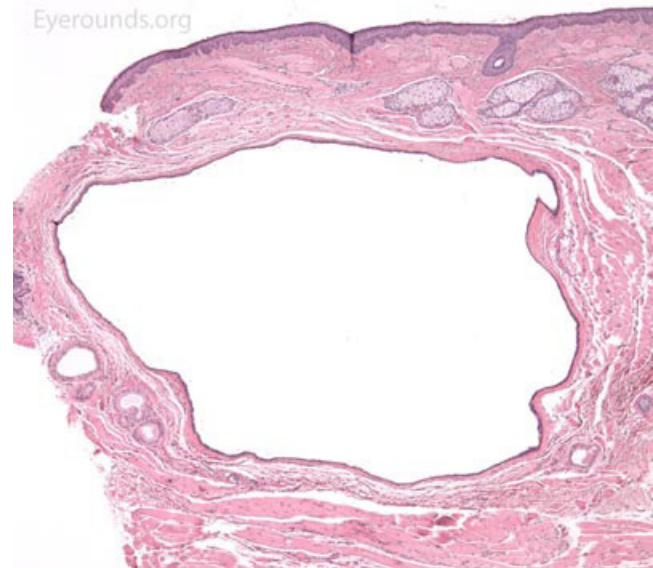

Figure 8: Apocrine hidrocystoma pathology.

Syringoma

A syringoma is a benign, adenomatous tumor of the eccrine sweat gland that likely arises from malformed eccrine ducts.

Presentation

The most common presentation is multiple, soft, small (1-2 mm), mildly hypopigmented papules arising on or near the lid margin or in the dermis. Syringoma are more common on the lower lid and occur more often in young female patients.

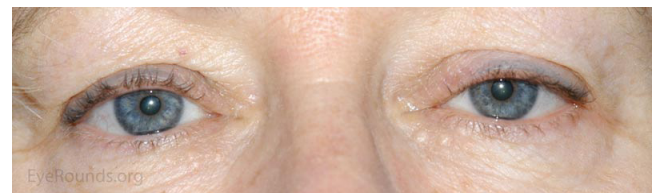

Figure 9: Syringoma

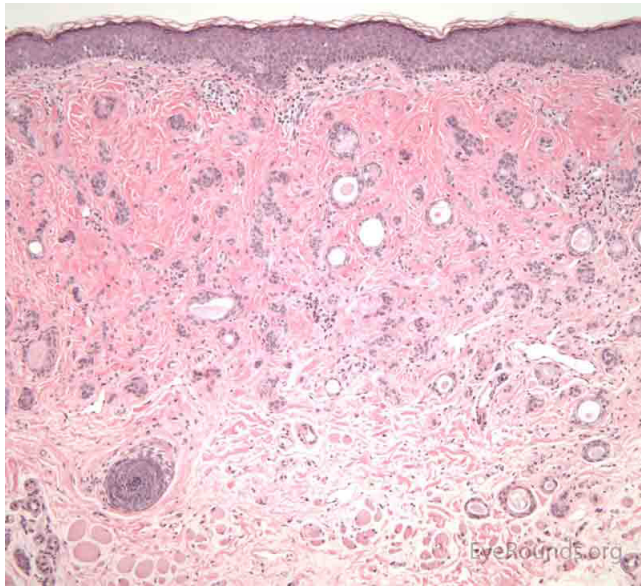


Figure 10: Syringoma pathology

Pathology

A pathologic sample of this process will show epithelial strands of small basophilic cells extending into the dermis that represents proliferation of eccrine sweat gland structures. These are classically described as "comma-shaped" or "tadpole" in appearance. Additionally, there will be multiple small, round, cystic ductules of proliferating eccrine glands that are lined by a double layer of flattened epithelial cells with a colloidal secretory material in the central lumen.

Treatment options

- ◆ Laser ablation
- ◆ Surgical excision

Nevus

A nevus is a congenital, hamartomatous (benign neoplasm in the tissue of origin) tumor of incompletely differentiated melanocytes (nevus cells).

Presentation

The presentation of a nevus is highly variable. Though not clinically apparent, nevi are present at birth and typically evolve and manifest variably throughout a person's life. Initial clinical presentation occurs during childhood as a flat, pigmented macule. At this time the nevus is typically a

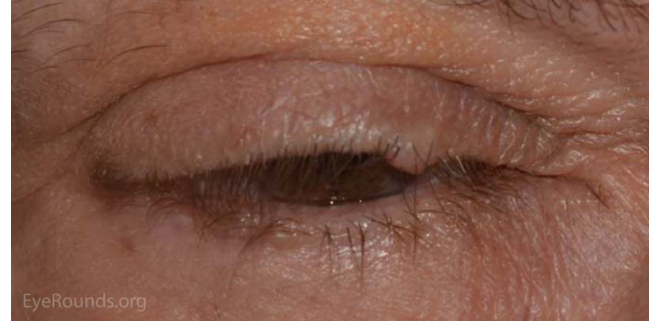

Figure 11: Intradermal nevus

junctional nevus – the nevus cells are located in the basal epithelial layer at the epidermal, dermal junction. Pigmentation often increases during puberty and then beyond the second decade, it becomes an elevated, pigmented papule. Over time the nevus transforms into a compound nevus – the nevus cells have extended from the junctional zone down into the dermis that gives it elevation. As the patient ages, the nevus loses its epidermal pigmentation and remains as an elevated, minimally pigmented or amelanotic lesion. At this point, the nevus is known as an intradermal nevus – there is involution of the epidermal component and all of the nevus cells are within the dermis.

Nevi are frequently found on the periocular skin, eyelids and eyelid margins. Nevi found on the lid margin can mold to the underlying ocular surface if they contact the globe and can have lashes protruding from them.

Pathology

Just as clinical presentation varies, pathologic features vary depending on the evolutionary stage of the nevus. Typical nevus cells are bland, benign appearing, but atypical melanocytes are round, basaloid and tend to cluster together in nests or chords. These cells contain "pseudo-inclusion cysts" which are abnormal infoldings of the cell nucleus that appear as a clearing within the cell nucleus. Nevus

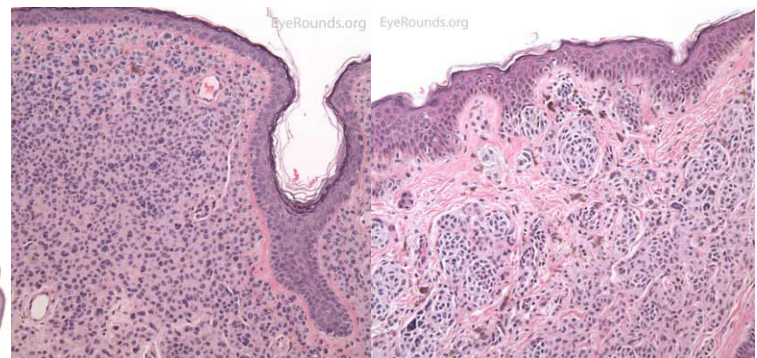
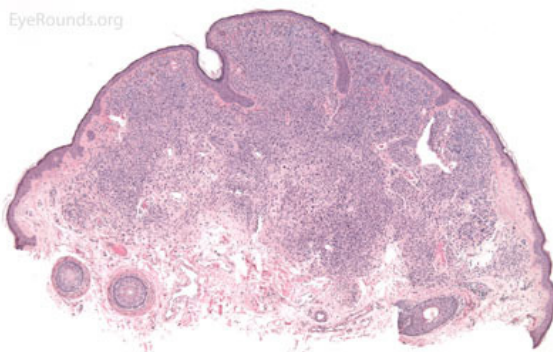


Figure 12: Nevus Pathology. a and b: Intradermal nevus pathology. c: Compound nevus pathology

cells tend to show polarity within a lesion, that is the nuclei tend to become more "mature" (smaller, thinner, and darker) as they progress deeper into the dermis. In the superficial aspect of the nevus, type A nevus cells have an epithelioid appearance. The nevus cells become smaller and darker as they move deeper (type B cells). In the deepest aspect of the nevus, type C nevus cells have a flatter, thinner nucleus and take on a spindle or Schwann cell-like appearance. Nevi contain highly variable amounts of pigmentation. As previously described, the location of the nevus cells within the lesion is what classifies the type of nevus

- ◆ Junctional nevus - nevus cells are all located at the epidermal, dermal junction in the basal epithelium
- ◆ Compound nevus – nevus cells are located at the epidermal, dermal junction in the basal epithelium AND in the dermis
- ◆ Intradermal nevus – nevus cells are all located within the dermis

Treatment options

- ◆ Shave biopsy
- ◆ Excisional biopsy
- ◆ Wedge resection on the eyelid

Seborrheic keratosis

A seborrheic keratosis is an acquired, benign papilloma that results from intraepidermal proliferation of benign basal cells.

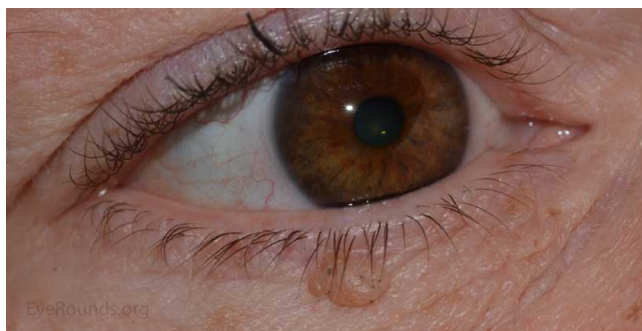

Figure 13: Seborrheic keratosis

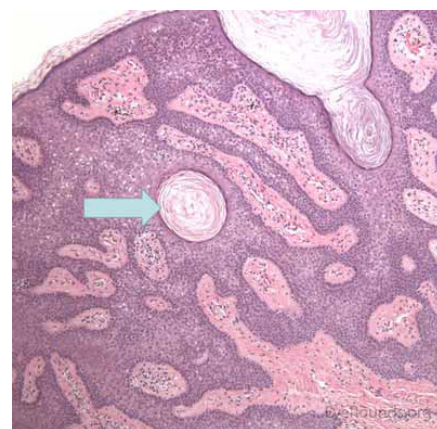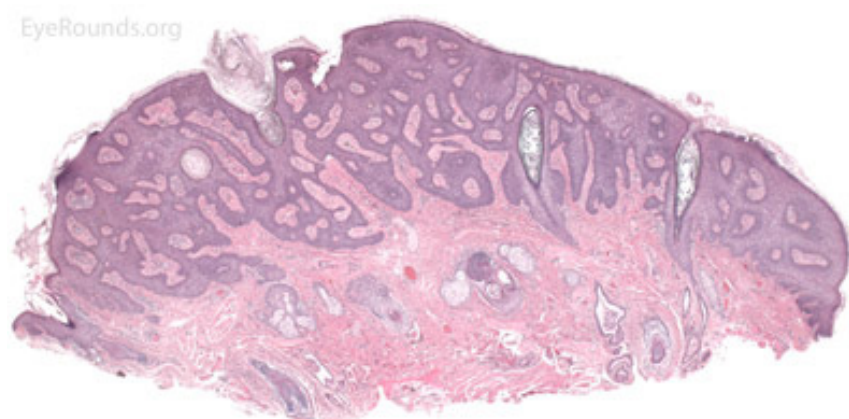


Figure 14: Seborrheic keratosis pathology

Presentation

The presentation is variable, but lesions are typically sharply defined, brownish and have a rough, warty surface. They are classically described as "greasy" and "stuck-on". The lesions have a variable degree of pigmentation and hyperkeratosis. The morphology may be sessile, pedunculated, lobulated, papillary or verrucoid. It is common for these lesions to increase in size and number with age.

Pathology

Pathologic specimens will show acanthosis, hyperkeratosis, and papillomatosis. Low magnification will accentuate the "stuck on" appearance of this papillomatous growth with upward acanthosis (Figure 14A). Higher magnification shows a proliferation of cells within the epidermis that closely resemble normal basal cells. The epidermis may proliferate down in to the dermis in a reticulated pattern with narrow interconnecting cords or tracts. There may be pseudohorn cysts, which are crevices or infoldings of epidermis cut in cross-section that appear to be cystic accumulations of keratinous material (Figure 14B). Pigmentation of these lesions is variable.

Treatment options

- ◆ Shave excision at the epidermal-dermal junction

Note

A sudden onset of multiple seborrheic keratoses is known as Leser-Trélat sign and is associated with systemic malignancy, classically gastrointestinal adenocarcinoma. There is a lesion very similar to seborrheic keratosis known as irritated seborrheic keratosis or inverted follicular keratosis. These lesions typically present as pink to flesh colored small papules that appear with rapid growth. Pathologically they are very similar as well, except that the normal basaloid cells of the lesion surround whorls of non-keratinizing squamous epithelium known as "squamous eddies" within the epidermis.

Verruca vulgaris

Verruca vulgaris, more commonly known as a wart, is a papillomatous growth that is caused by an epidermal infection with human papilloma virus (usually HPV 6 or 11).

Presentation

These lesions typically occur near the eyelid margin, but can occur anywhere on the periocular skin. They typically appear as a small, non-pigmented papule with a digitated surface or as an elongated, filiform lesion with papillomatous growth.

Pathology

Verruca lesions are typified by massive papillomatosis with acanthosis. There is usually a large degree of hyperkeratosis and these lesions will demonstrate parakeratosis. The parakeratosis in verruca lesions is classically apical (Figure 16A). On higher magnification, infected cells will demonstrate koilocytosis – cytoplasmic clearing with nuclear contraction (Figure 16B). These vacuolated keratocytes will have condensation and clumping of dark-staining keratohyaline granules in the periphery of the cell and occasionally show intranuclear eosinophilic viral inclusion bodies. Verruca lesions will typically have a mixed inflammatory infiltrate in the underlying superficial dermis.

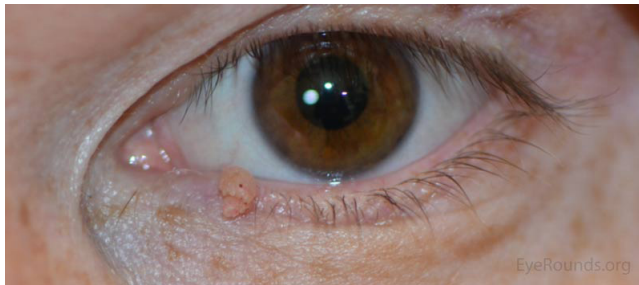


Figure 15: Verruca vulgaris

Treatment options

- ◆ Excision
- ◆ Cryotherapy

Note

Verruca lesions are known for recurrences.

Molluscum contagiosum

Molluscum contagiosum is an epidermal viral infection caused by the DNA poxvirus Molluscum Contagiosum Virus (MCV).

Presentation

This process will typically present with multiple, small (1-3 mm), discrete, dome-shaped or nodular, waxy papules with characteristic umbilicated centers. It is more common in pediatric populations or those that are immune compro-

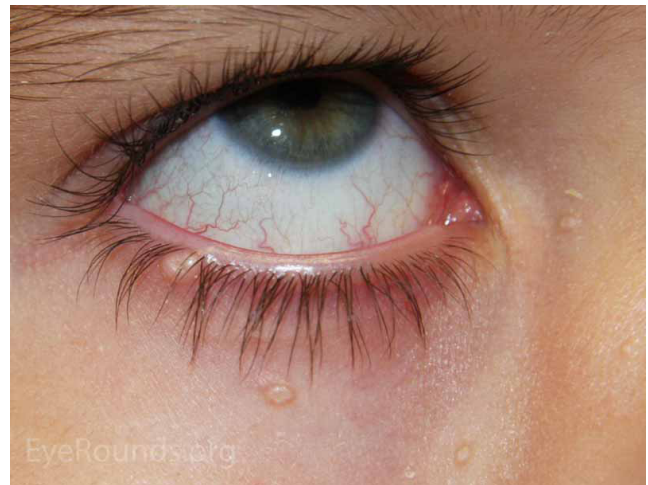

Figure 17: Molluscum contagiosum

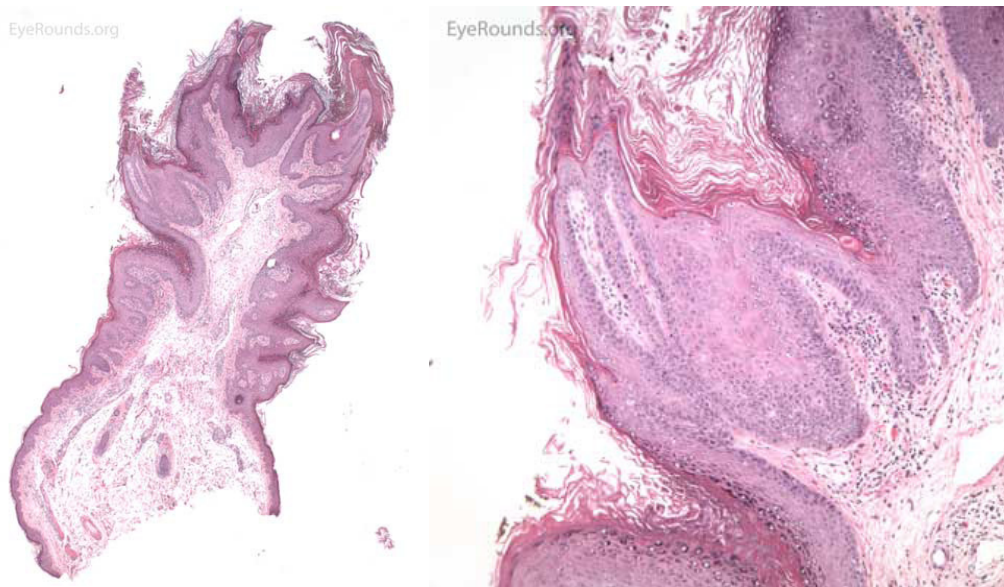


Figure 16: Verruca vulgaris pathology

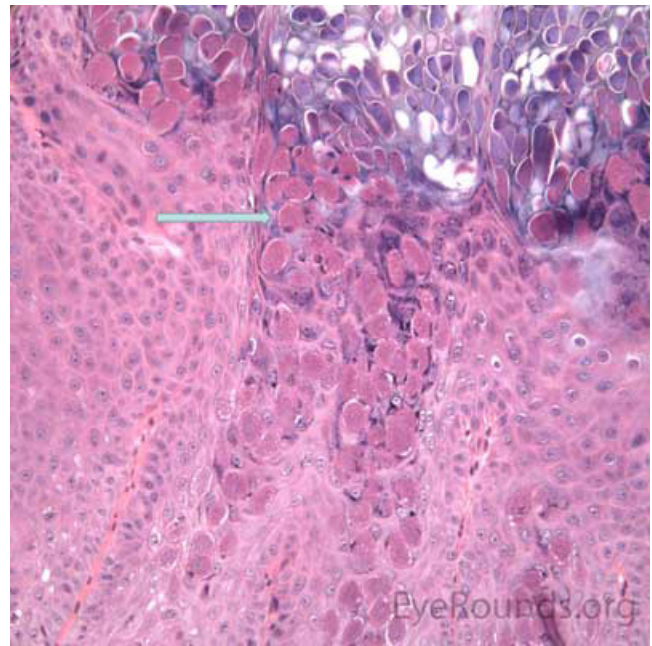
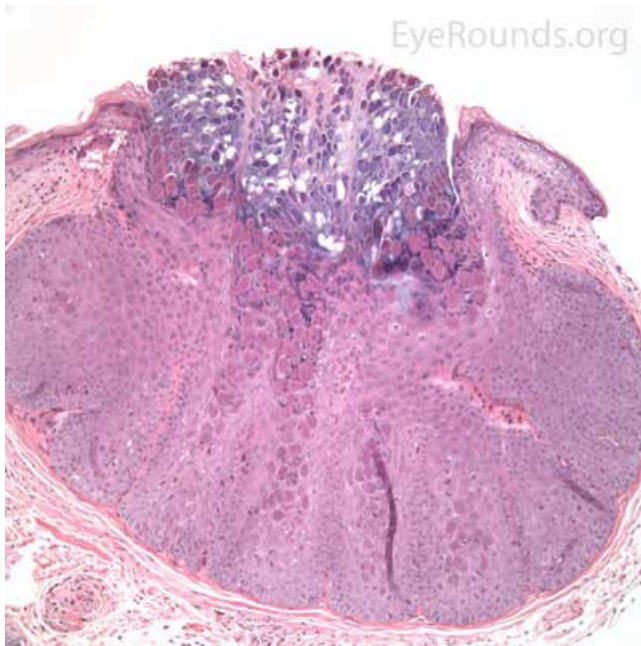

Figure 18: Molluscum contagiosum pathology

mised (i.e., HIV, AIDS, Wiskott-Aldrich syndrome). Patients may also present with a chronic follicular conjunctivitis that is caused by molluscum bodies being shed into the tear film from the eyelid lesions.

Pathology

This process has a very distinct pathologic appearance of a nodular proliferation of epithelium producing a central focus of necrotic cells extruding to the surface. Infected cells contain large, homogeneous, intracytoplasmic inclusion bodies called molluscum bodies that represent replicating pox virus in the cytoplasm and tend to displace the cell nucleus peripherally (Figure 18B). Infected cells tend to be smaller and more eosinophilic in the deeper layers of the lesion and become larger and more basophilic as they extend toward the surface.

Treatment options

- ◆ Excision
- ◆ Cryotherapy
- ◆ Curettage

Note

Treatment of the skin lesions will resolve any associated irritative follicular conjunctivitis.

Acrochordon

An acrochordon is a benign, acquired papilloma. It is known by many other names including skin tag, fibroepithelial polyp or squamous papilloma.

Presentation

These lesions can present as single or multiple and can range in size typically from 1 mm to 1 cm. They are classically polypoid, soft and attached by a stalk. The lesions can be non- or slightly pigmented, but if twisted about its stalk, the lesion may infarct and change color from tan to black. They are more common in the middle-aged and elderly patient and have a higher occurrence in areas of skin friction.

Pathology

Pathologic specimens (figure 20) show a polypoid lesion with a fibrovascular stalk that contains loose, collagenous stroma surrounded by a mostly unremarkable epithelium. There are varying degrees of acanthosis and hyperkeratosis.

Treatment options

- ◆ Excisional
- ◆ Shave biopsy

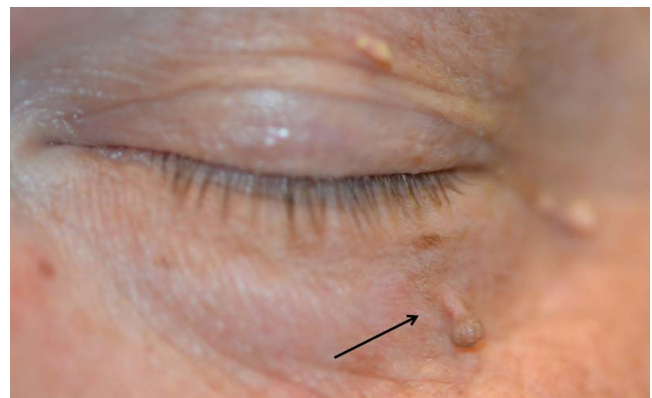

Figure 19: Acrochordon

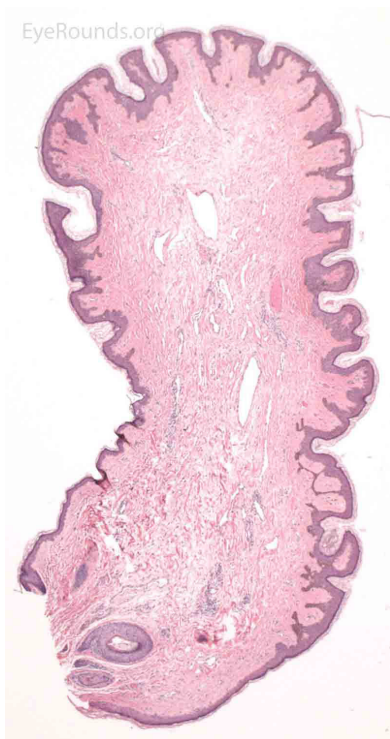

Figure 20: Acrochordon pathology

References

1. Barnhill, RL, Crowson, AN. Textbook of Dermatopathology, 2nd edition. Part 4: Proliferations – Hamartomas, Hyperplasias, Neoplasias. New York, NY: The McGraw-Hill Company; 2004; Chapters 26-36, p. 559-984.
2. Holds, JB, Chang, WJ, Durairaj, VD, et al. Orbits, Eyelids, and Lacrimal System. Section 7. Basic and Clinical Science Course. San Francisco: American Academy of Ophthalmology; 2013; Chapter 10: Classification and Management of Eyelid Disorders, p. 145-187.
3. Rosa, RH, Buggage, R, Harocopos, GJ, et al. Ophthalmic Pathology and Intraocular Tumors. Section 4. Basic and Clinical Science Course. San Francisco: American Academy of Ophthalmology; 2013; Chapter 13: Eyelids, p. 205-227.
4. Yanoff, M, Sassani JW. Ocular Pathology, 6th edition. Chapter 6: Skin and Lacrimal Drainage System. St. Louis, MO: Mosby Inc; 2009. p. 165-222.

Suggested Citation Format

Lenci LT, Kirkpatrick CA, Clark TJ, Maltry AC, Syed NA, Allen RC, Shriver EM. Benign Lesions of the External Periocular Tissues: A Tutorial. EyeRounds.org. posted May 10, 2017; Available from: <http://EyeRounds.org/tutorials/benign-lid-lesions/>

last updated: 06/14/2017

Malignant Lesions of the External Periocular Tissues

A Tutorial

Lucas T. Lenci, MD; Sebastian J. Sciegenka; Christopher A. Kirkpatrick, MD, T.J. Clark, MD; Nasreen A. Syed, MD; Erin M. Shriver, MD

June 14, 2017

Introduction

A thorough ophthalmic examination should always include careful inspection of the external periocular tissues. These tissues include specialized structures that are prone to unique pathology. For example, the eyelid has cilia, sebaceous glands of Zeis, apocrine sweat glands of Moll, eccrine sweat glands, and vellus hairs. Deep to the eyelid dermis lays the orbicularis muscle followed by the tarsal plate containing the sebaceous Meibomian glands and ducts. These structures can give rise to both benign and malignant proliferations. Here we discuss those that are malignant. Please refer to eyerounds.org/tutorials/benign-lid-lesions/ to see benign eyelid lesions. The following discussion includes the presentation and pathology of common eyelid malignancies. This is meant to be an overview and tutorial. Additionally, treatment options are briefly discussed but are not exhaustive. Treatment of these malignant tumors depends on the extent of invasion as well as lymph node and systemic involvement.

Keratoacanthoma

Keratoacanthoma is a rare tumor usually occurring in fair-skinned individuals over areas of chronic sun exposure or sites of prior trauma. Most commonly occurs during the 6th decade of life. They are regarded as part of the spectrum of squamous cell carcinomas. These are more common in immunocompromised individuals. Some classify keratoacanthoma as a low grade malignancy and refer to them as "squamous cell carcinoma with keratoacanthoma-like features".[1]

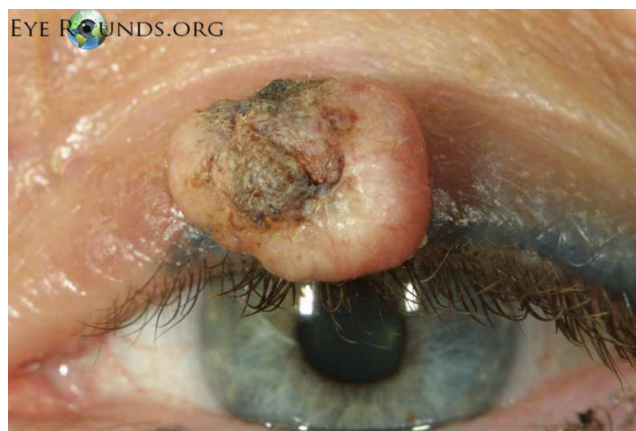

Figure 1: Keratoacanthoma

Keratoacanthoma which arose over a period of weeks. Note the classic dome-shaped nodule with elevated, rolled margins and a central keratin-filled crater. (The darkened coloration of the upper lid is a permanent eyeliner tattoo.) (Contributor – Jesse Vislisel, MD)

Presentation

Classically presents as a flesh colored to erythematous elevated nodule with a central keratin plug on the lower eyelid. These lesions grow quickly, up to 2.5 cm over 2-4 weeks, followed by a slower involutinal phase taking several months. During involution, a keratin-filled crater may form and if left alone, a permanent, depressed scar remains.

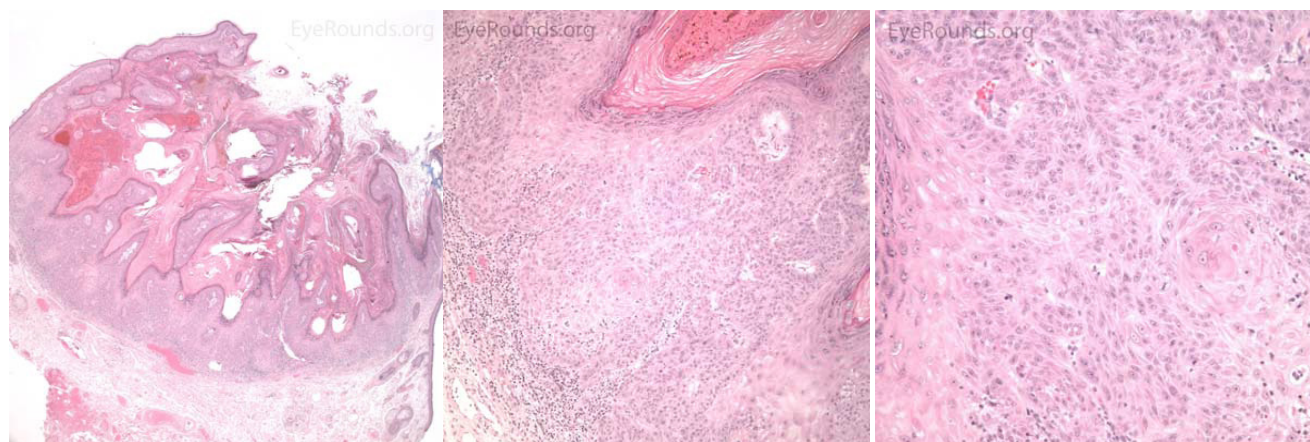


Figure 2: Keratoacanthoma Histology (same specimen at different magnifications): *Classic cup-shaped invagination of well-differentiated squamous cells forming irregularly configured nests and strands at the base of the lesion.*

Pathology

Typical pathologic specimens show a lymphocytic infiltrate at the base of the lesion and eosinophilic epithelium. The epidermis is acanthotic and often shows some nuclear atypia, dyskeratosis, squamous eddies and an increased mitotic rate. The proliferating epithelial cells will frequently undermine the adjacent normal epidermis, leading to a sharp transition between normal and thickened epithelium known as shoulder formation.

Treatment options

- ◆ Complete surgical excision
- ◆ Cryotherapy
- ◆ Topical or intralesional 5-fluorouracil

Notes

Cutaneous horns erupting from keratocarcinomas indicate a higher likelihood of underlying squamous cell carcinoma.

Basal Cell Carcinoma (BCC)

Basal cell carcinoma is the most common human malignancy and by far the most common eyelid malignancy, accounting for about 90% of malignant lesions on the eyelid. It most frequently affects fair-skinned, elderly patients with peak incidence at age 70. Risk factors include ultraviolet light exposure, age, chronic inflammation, immunosuppression, and exposure to arsenic and coal tar derivatives. [2]

Presentation

Basal cell carcinoma usually presents as a flesh colored to pearly, raised nodule with rolled edges. Some ulcerate or have telangiectatic vessels on the surface. From most to least common location, BCCs arise on the lower eyelid, medial canthus, upper eyelid, and lateral canthus. Many variants of BCC exist including nodular (>50% of cases), pigmented, superficial, cystic, and morpheaform. While they can invade locally and extensively, BCC grows slowly and has a very low rate of metastasis.

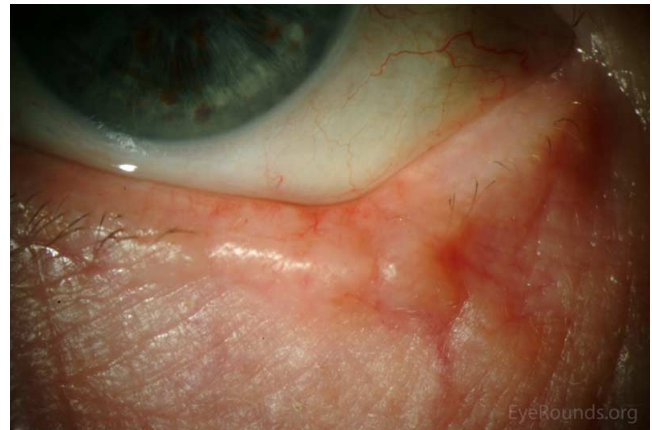
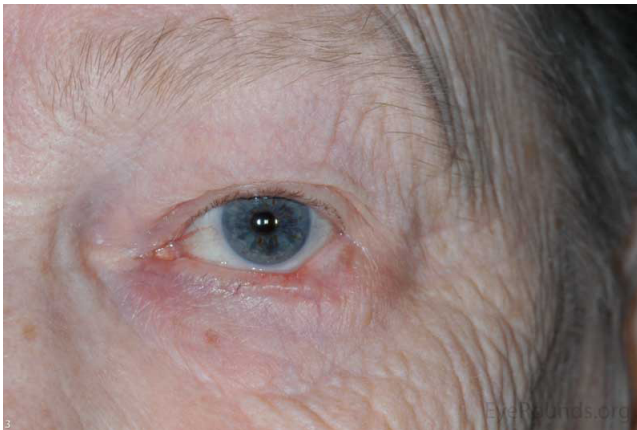

Figure 3: Basal Cell Carcinoma. BCC demonstrated on the left lower eyelid of a 76 year-old female. Note the nodular, pearly colored papule with rolled edges and telangiectatic vessels.

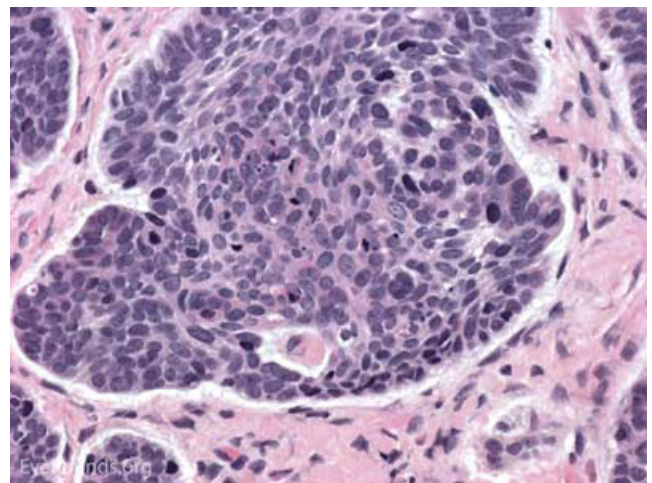
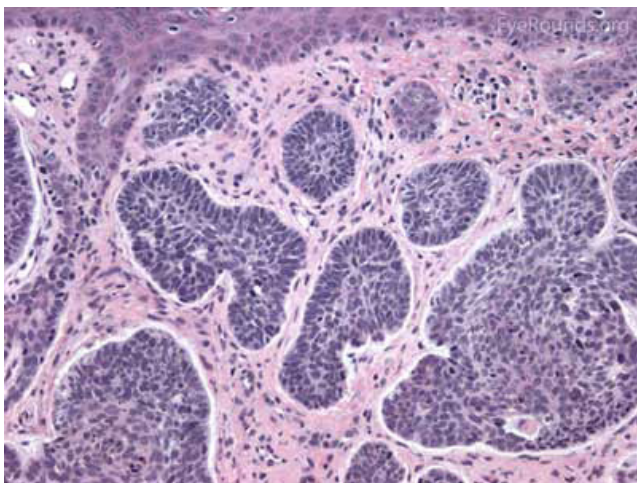


Figure 4: Basal Cell Carcinoma Histology. 4A: BCC tumor cells with relatively bland, monomorphic nuclei with high nuclear/cytoplasmic ratio in several cohesive nests lying within the dermis. 4B: Palisading of the cells around the outer edge of the tumor and retraction artifact

Pathology

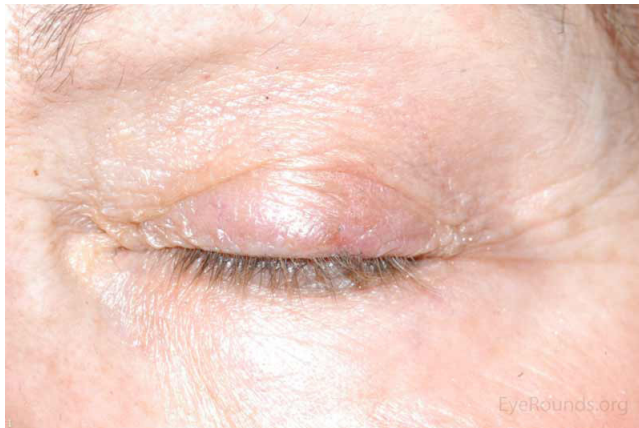BCC arises from the epidermis and invades into the dermis forming basophilic islands of tumor that typically have a palisading "picket fence" border that mimics the hair matrix. Tumor cells are characterized by relatively bland, monomorphous nuclei with high nuclear to cytoplasmic ratio. Single cell necrosis is common within the islands. The islands are often separated from the surrounding dermis by an artifactitious clear space (retraction artifact).

Treatment options

- ◆ MOHS micrographic excision
- ◆ Surgical excision with frozen section margin controls
- ◆ Topical imiquimod or 5-fluorouracil
- ◆ Adjunct systemic chemotherapy/targeted therapy (vismodegib or sonidegib)

Notes

BCCs of greatest concern are those arising near the medial canthus where they can more easily invade the orbit and sinuses. These are the most difficult to manage and carry a high risk of recurrence.



Actinic Keratosis (AK)

Actinic keratosis is a precancerous dysplastic squamous lesion that results from proliferation of atypical epidermal keratinocytes which have the ability to transform into squamous cell carcinoma. Major risk factors for AK include UV light exposure and fair skin. Although easily managed, the occurrence of AKs should increase clinical suspicion for other skin malignancies. [3]

Presentation

AKs typically present as erythematous, scaly macules or papules. Lesions usually are < 1cm in diameter and rough to the touch. The most frequently affected areas include the face, exposed scalp, and dorsum of forearms and hands. Several clinical variants exist including classic/common, hypertrophic, atrophic, AK with cutaneous horn, and pigmented.

Pathology

The pathology depends on the clinical variant, but classically demonstrates focal surface parakeratosis and loss of the stratum granulosum in the epidermis. There may be acanthosis with club-like extensions of the rete ridges into

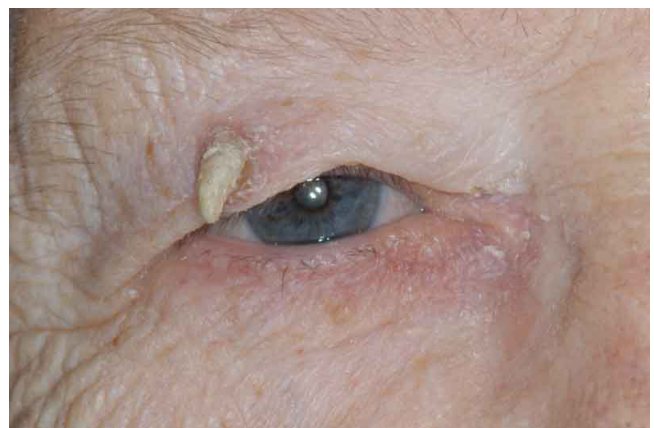

Figure 5: Actinic Keratosis. 5A: Classic AK overlying the middle portion of the left eyelid. 5B: AK with cutaneous horn presenting on the right upper eyelid.

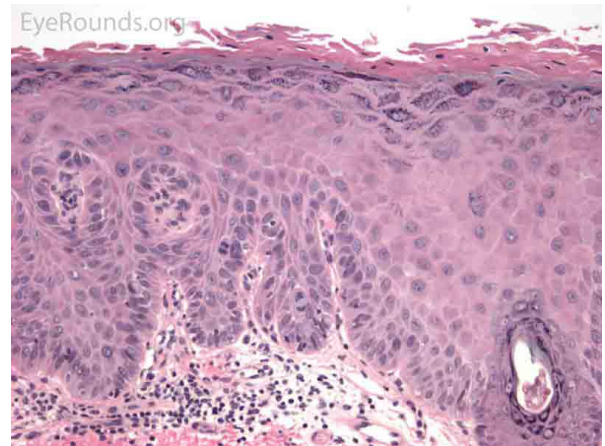
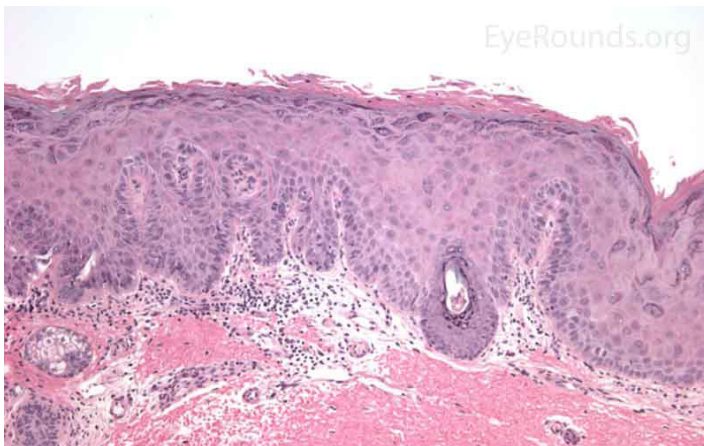
Figure 6: Actinic Keratosis Histology. Classic AK having features of epidermal acanthosis, disorganization of the epidermis (dysplasia), parakeratosis, and inflammation of the underlying dermis.

the dermis. Some degree of epidermal nuclear atypia is present, usually in the deeper layers of the epidermis. The superficial dermis may have a lymphocytic infiltrate at the base of the lesion. The underlying dermis usually has solar elastosis.

Treatment options

- ◆ Cryotherapy
- ◆ Topical imiquimod or 5-fluorouracil
- ◆ Surgical excision

Notes

The risk of developing frank malignancy from actinic keratosis is grossly estimated from multiple studies. Generally accepted statistics: individuals with AKs have a 10-25% chance of developing SCC; 25% of AKs resolve spontaneously; total risk of transformation for an individual lesion is estimated at 1%. Although the risk of death from AKs is low, they should be promptly treated; prevention of future SCC is more effective than treating after one develops.

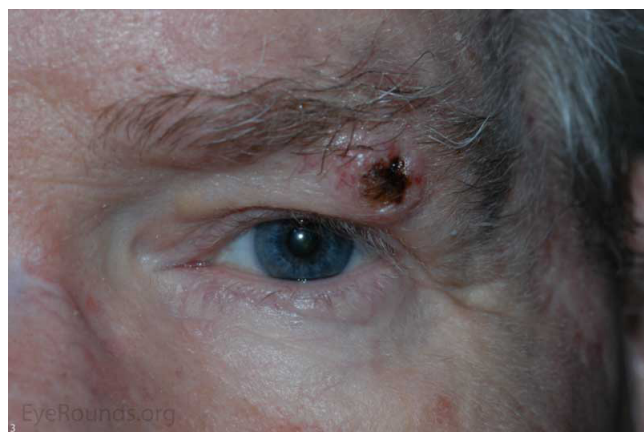

Figure 7a: Squamous Cell Carcinoma.

SCC demonstrated on left upper eyebrow of a 63 year-old Caucasian male. Note the ulcerated center with a relatively smooth outer rim of hyperkeratotic tissue. This lesion has a similar appearance to basal cell carcinoma.

Squamous Cell Carcinoma (SCC)

SCC is the second most common cutaneous malignancy, second only to BCC worldwide. However in dark skinned individuals, SCC is the most common skin cancer. They account for 5-10% of eyelid malignancies and may spread perineurally to invade the orbit or paranasal sinuses. The overall risk of metastasis is less than 5%, but the risk increases to 20-30% when present on lips, ears, or eyelids. Risks include UV exposure, fair skin, childhood sunburns, age, family or personal history, immunosuppression, smoking, arsenic exposure, and genetic predisposition. [4]

Presentation

There is a wide variety of SCC clinical presentations ranging from papules, plaques, or nodules with smooth, hyperkeratotic, or ulcerative secondary characteristics. Most are erythematous to pink nodules with overlying scale or crust with or without ulceration. SCC is most commonly found on the head and neck (55%), but can develop on any cutaneous surface. Squamous cell carcinomas have a predilection for the lower eyelid and lid margin.

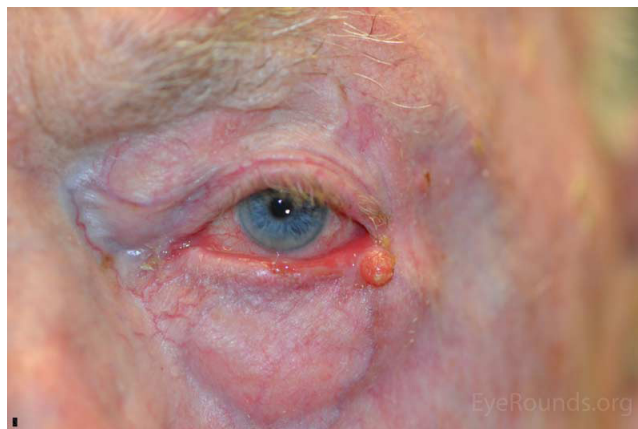

Figure 7b: Pedunculated squamous cell carcinoma

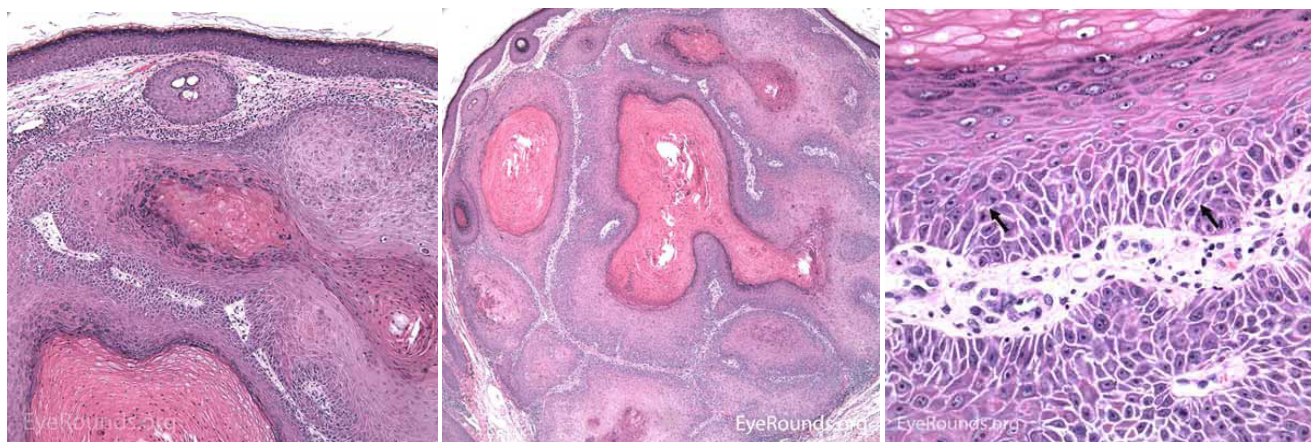

Figure 8: Squamous Cell Carcinoma Histology. Tumor cells can be seen invading the dermis, producing a fibrotic tissue reaction and keratin pearls. On highest magnification, intracellular bridges (arrows) are seen, strongly suggesting SCC.

Pathology

SCCs can vary from well differentiated to poorly differentiated on the eyelid. Atypical squamous cells form islands and strands extending deep to the epidermal basement membrane, infiltrating the dermis, and inciting a fibrotic dermal reaction. Prominent intercellular bridges (desmosomes) can be seen between cells. Dyskeratosis is often present in the form of horn cysts or keratin pearls. In contrast to BCC, cells are typically eosinophilic and may form whorls known as squamous eddies. SCC *in situ* is commonly referred to as Bowen disease.

Treatment options

- ◆ Mohs micrographic surgery
- ◆ Surgical excision with frozen section margin controls
 - Possible lymph node biopsy
- ◆ Topical imiquimod, 5-fluorouracil, EGFR inhibitors.

Notes

Unfortunately, SCC is at times downplayed as melanoma's less dangerous counterpart. However, among African Americans, SCC is the leading cause of mortality by skin malignancy. All suspected SCCs should be investigated further by biopsy.

Melanoma

The incidence of cutaneous melanoma is rising faster than any other cancer in the United States. Although rarely occurring on the eyelids, melanoma can be associated with a high mortality rate. Pigmentation remains a hallmark of this lesion, but half of eyelid melanomas are non-pigmented and may lead to misdiagnosis. Lentigo maligna is a subtype of melanoma *in situ* that usually occurs on the face or neck of older individuals. It is the most common melanoma subtype that affects the eyelids and has the ability to spread onto the conjunctiva. When atypical melanocytes

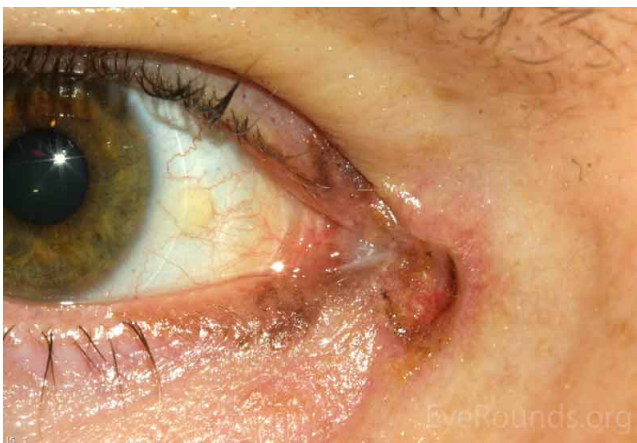

Figure 9: Melanoma. Melanoma demonstrated on 44 year-old male with a 15 year history of pigmented lesion on eyelid. Note the loss of eyelashes medially on the lower eyelid.

of lentigo maligna invade the dermis, the lesion is referred to as lentigo maligna melanoma (invasive melanoma). Risk factors include UV exposure, fair skin, childhood sunburns, presence of many dysplastic nevi, and a family or personal history of melanoma. [5]

Presentation

Histologic appearance of cutaneous melanoma depends on the subtype. Lentigo maligna typically presents as an irregularly pigmented, patchy, slowly expanding macule. Nodular thickening of the lesion is suggestive of an invasive component. Superficial spreading melanomas are variably pigmented macules or plaques with irregular borders and multiple color hues ranging from black to blue to brown. Nodular melanomas are usually darkly pigmented pedunculated or polypoid nodules; they can be amelanotic. In contrast to the long horizontal growth phase of lentigo maligna and superficial spreading melanoma, nodular melanomas are more worrisome because of their propensity for rapid vertical growth into dermis.

Pathology

Melanoma can have several different cell types histologically (epithelioid, spindle, and balloon cells) and may be subtle, especially if lacking pigment. They exhibit two forms of atypia: Architectural atypia is described as nests of atypical, pleomorphic melanocytes proliferating in the epidermis and dermis without pattern or symmetry (lentiginous pattern). Cytologic atypia is described as high nuclear to cytoplasmic ratio, prominent nucleoli, and increased mitotic rate. The single most important prognostic factor for cutaneous melanoma is depth of invasion measured in hundredths of a millimeter (Breslow depth).

Treatment options

- ◆ Mohs micrographic surgery, controversial
- ◆ Surgical excision with permanent margin controls, more common
 - (Lymph node biopsy/ dissection may be necessary based off of biopsy result)

Notes

The physical diagnostic guidelines of melanoma apply to the periocular tissues as they do to other skin surfaces. They follow the ABCDEs of melanoma – asymmetry, border irregularities, color heterogeneity with black and blue hues, diameter >6mm, and evolution or changing of lesion over time. Both patients and ophthalmologists should follow this mantra when screening for cutaneous melanomas to ensure prompt diagnosis and treatment.

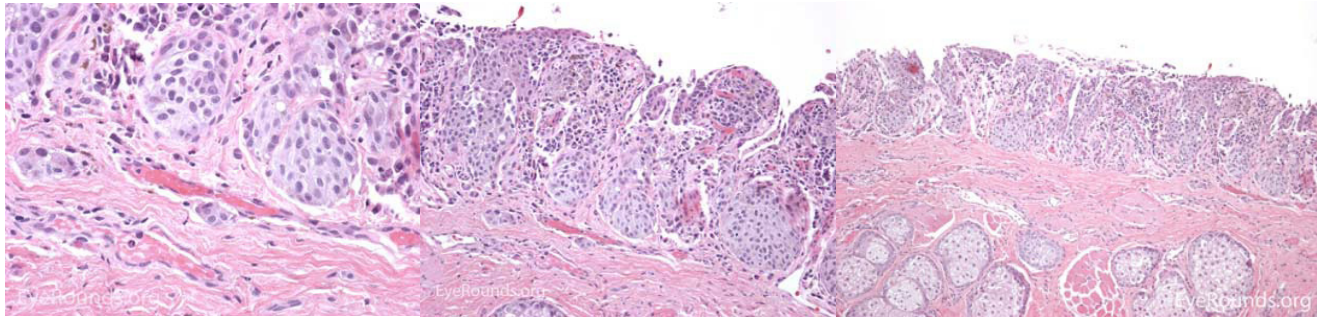


Figure 10: Melanoma Histology. Atypical, pleomorphic melanocytes are scattered throughout the epidermis and dermis without discernible pattern or symmetry. High N/C ratios and mitotic figures are appreciated here.

Sebaceous adenocarcinoma

Sebaceous adenocarcinoma is an uncommon, slow-growing but potentially aggressive malignancy often affecting the elderly with a predilection for female patients. It can arise from the meibomian glands, glands of Zeis, or caruncular sebaceous glands. Approximately 80% present on the head or neck with 40% involving the eyelid. Unlike BCC and SCC, sebaceous (adeno) carcinomas occur more commonly on the upper eyelid which has more numerous meibomian glands compared with the lower eyelid. [6,7]

Presentation

Sebaceous adenocarcinomas are notorious for masquerading as other conditions, such as chalazion or ulcerative blepharconjunctivitis. It may present as a small, rubbery, firm nodule on the upper eyelid. It may be papillomatous or present as diffuse tarsal thickening with eyelid misdirection. Madarosis (loss of eyelashes) is not uncommon. Caruncular lesions may be multi-lobulated, grey-yellow subconjunctival masses. When arising from the glands of Zeis, the lesions form small yellow nodules in front of the grey line which can cause eyelid malposition. The yellowish appearance associated with the tumor is due to sebum and one must be suspicious of this.

Pathology

Sebaceous adenocarcinoma consists of pleomorphic, atypical epithelial cells ranging from moderately differentiated to poorly differentiated. They may demonstrate foamy cytoplasm or a vesicular nucleus due to the presence of lipid. Other tumors may demonstrate cells with hyperchromatic nuclei. In order to stain for intracellular lipid, tissue that has not been processed into paraffin is necessary. Frozen sections can then be prepared with Oil red O or Sudan black stains to identify lipid. Also typical of sebaceous adenocarcinoma is pagetoid spread (clusters of tumor cells within the epidermis that have no apparent connection to the main portion of the tumor). Tumors may also spread in an in situ fashion, replacing normal epidermis and without dermal invasion.

Treatment options

- ◆ Wide surgical excision with permanent margin controls, map biopsies
- ◆ Adjunctive topical mitomycin C for non-invasive conjunctival involvement
- ◆ Radiation for larger tumors as an adjunct to surgery

Notes

Muir Torre syndrome (a subset of Lynch syndrome) is a rare autosomal dominant condition that predisposes to keratoacanthoma, basal cell carcinoma, sebaceous gland carcinoma and internal malignancies such as colon and genitourinary malignancies [8]

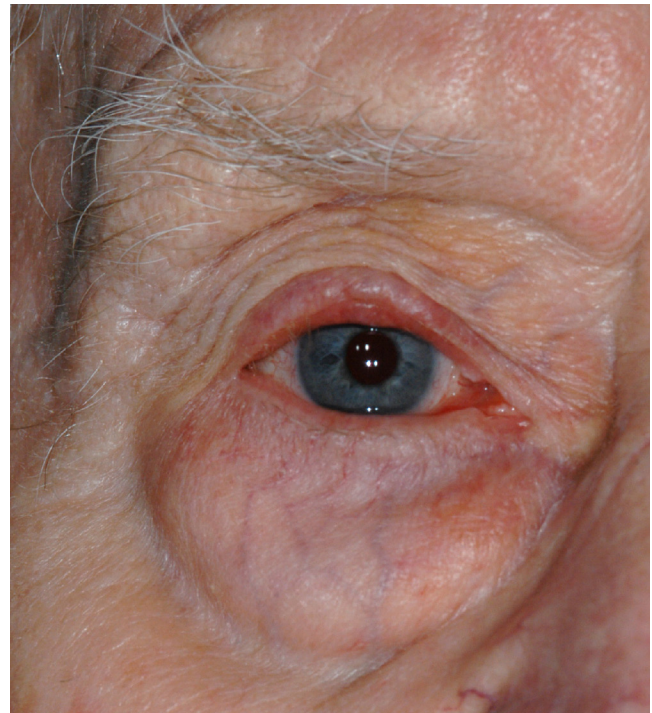


Figure 11: Sebaceous Carcinoma. Sebaceous carcinoma demonstrated on right upper eyelid of a 67 year-old male with history of chronic blepharitis. Note the ulceration and thickening of lid margin with loss of lashes.

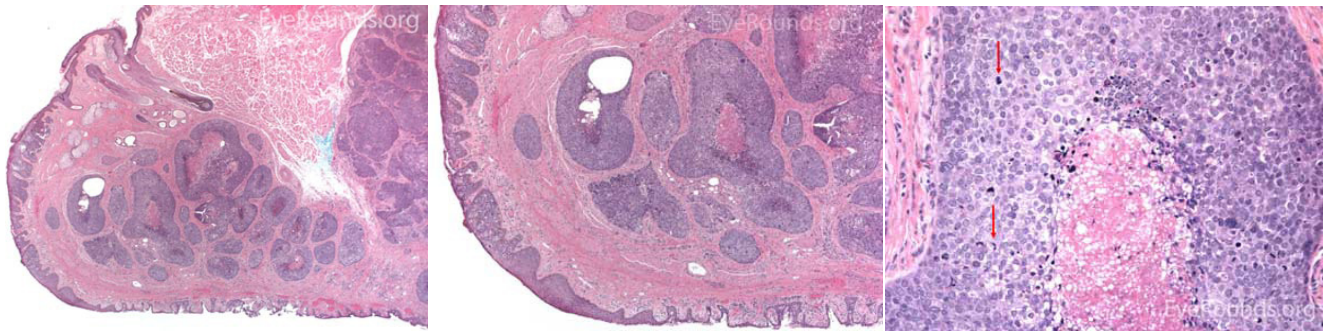


Figure 12: Sebaceous Gland Carcinoma Histology. Tumor cells with foamy cytoplasm and mitotic figures (red arrow) are shown.

Merkel Cell Carcinoma (MCC)

MCC is a rare but aggressive malignancy that typically affects older individuals with significant UV light exposure. Early histological studies suggest that MCC arises from Merkel cells, mechanoreceptor cells responsible for tactile sensation, located in the basal epidermis. Alternatively, it is also hypothesized that these tumors originate from immature totipotent stem cells of the skin. Risk factors for MCC include UV exposure, fair skin, age, immunosuppression, and infection with Merkel cell polyomavirus. [9]

Presentation

The typical presentation of MCC is a pink to blue-red, rapidly growing, painless, firm, shiny nodule with intact overlying skin. It is most frequently located on the upper eyelid, head, or neck and is often misdiagnosed as a cyst, lipoma, or other benign lesion. Because of their subtle yet aggressive nature, up to 30% of patients have regional lymph node involvement at presentation. [10,11]

Pathology

This neuroendocrine carcinoma is composed of deeply basophilic uniform cells with a high nucleus to cytoplasmic ratio, finely dispersed nuclear chromatin, and an inconspicuous nucleolus. Cells are crowded and often mold together. Single-cell necrosis, numerous mitotic figures, and lymphovascular, perineural, or epidermal invasion may also be seen. Merkel cells have features of both epithelial and neuroendocrine cells and express many markers that can be analyzed with immunohistochemistry such as synaptophysin, chromogranin and neurofilament.

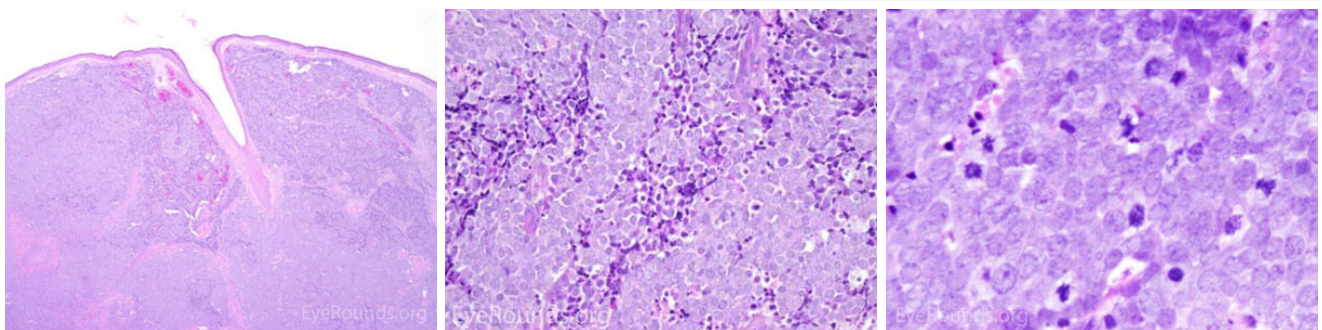


Figure 14: Merkel Cell Carcinoma Histology. Densely blue cells forming sheets, ribbons, and nests located in the dermis. Note the mitotic figures in the highest magnified image.

Treatment options

- ◆ Wide surgical excision/Mohs micrographic surgery +/- lymph node biopsy
- ◆ Systemic chemotherapy may be necessary with lymph node involvement

Notes

The risk of MCC is higher in patients with other malignancies and those who are immunosuppressed. The diagnosis of MCC alone should raise suspicion for the presence of underlying multiple myeloma, chronic lymphocytic leukemia, or malignant melanoma. Local recurrence and lymph node metastases are common; the 5 year survival is poor at 38%. [12]

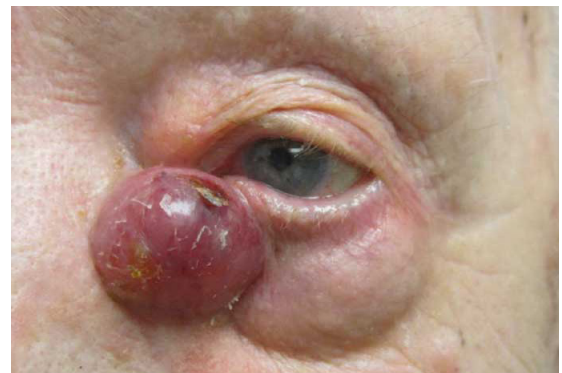

Figure 13: Merkel Cell Carcinoma. Merkel cell carcinoma demonstrated in 86 year-old female. This lesion was mostly painless but grew quickly after being incised by another physician. Note the dome shape and intense red color. Photo credit: Richard C. Allen, MD, PhD

References

1. Kwiek B, Schwartz RA. Keratoacanthoma (KA): An update and review. *J Am Acad Dermatol* 2016;74(6):1220-1233. www.ncbi.nlm.nih.gov/pubmed/26853179
2. Wu PA. Pathogenesis, clinical features, and diagnosis of basal cell carcinoma [Topic 5335 Version 27.0]. In: Stern RS, Robinson JK, editors. UpToDate [online resource]: Wolters Kluwer; 2017.
3. Padilla RS. Epidemiology, natural history, and diagnosis of actinic keratosis [Topic 13712 Version 10.0]. In: Robinson JK, editor. UpToDate [online resource]: Wolters Kluwer; 2015.
4. Lin JL, Asgari M. Clinical features and diagnosis of cutaneous squamous cell carcinoma (SCC) [Topic 16225 Version 14.0]. In: Stern RS, Robinson JK, editors. UpToDate [online resource]: Wolters Kluwer; 2017.
5. Fitzpatrick TB. Color atlas and synopsis of clinical dermatology : common and serious diseases. New York: McGraw-Hill, 1994.
6. Shields JA, Saktanasate J, Lally SE, Carrasco JR, Shields CL. Sebaceous Carcinoma of the Ocular Region: The 2014 Professor Winifred Mao Lecture. *Asia Pac J Ophthalmol (Phila)* 2015;4(4):221-227. www.ncbi.nlm.nih.gov/pubmed/26147013
7. Prieto-Granada C, Rodriguez-Waitkus P. Sebaceous Carcinoma of the Eyelid. *Cancer Control* 2016;23(2):126-132. www.ncbi.nlm.nih.gov/pubmed/27218789
8. Dores GM, Curtis RE, Toro JR, Devesa SS, Fraumeni JF, Jr. Incidence of cutaneous sebaceous carcinoma and risk of associated neoplasms: insight into Muir-Torre syndrome. *Cancer* 2008;113(12):3372-3381. www.ncbi.nlm.nih.gov/pubmed/18932259
9. Albores-Saavedra J, Batich K, Chable-Montero F, Sagy N, Schwartz AM, Henson DE. Merkel cell carcinoma demographics, morphology, and survival based on 3870 cases: a population based study. *J Cutan Pathol* 2010;37(1):20-27. www.ncbi.nlm.nih.gov/pubmed/19638070
10. Heath M, Jaimes N, Lemos B, Mostaghimi A, Wang LC, Penas PF, Nghiem P. Clinical characteristics of Merkel cell carcinoma at diagnosis in 195 patients: the AEIOU features. *J Am Acad Dermatol* 2008;58(3):375-381. www.ncbi.nlm.nih.gov/pubmed/18280333
11. Tai P. Pathogenesis, clinical features, and diagnosis of Merkel cell (neuroendocrine) carcinoma [Topic 7623 Version 23.0]. In: Stern RS, Robinson JK, editors. UpToDate [online resource]: Wolters Kluwer; 2016.
12. Zhan FQ, Packianathan VS, Zeitouni NC. Merkel cell carcinoma: a review of current advances. *J Natl Compr Canc Netw* 2009;7(3):333-339. www.ncbi.nlm.nih.gov/pubmed/19401065

Additional Reading

Kanski JJ, Nischal KK, Bowling B. *Clinical ophthalmology: a systematic approach*. 7th ed. St. Louis: Elsevier/Saunders, 2011.

Citing this article

Lenci LT, Sciegienka S, Kirkpatrick CA, Clark TJ, Syed NA, Shriver EM. Malignant Lesions of the External Periocular Tissues Tutorial. *EyeRounds.org*. posted May 10, 2017; Available from: EyeRounds.org/tutorials/malignant-lesions-of-ext-periocular-tissues

last updated: 06/14/2017

Thyroid Eye Disease

An Introductory Tutorial and Overview of Disease

Chase A Liaboe, BA; Thomas J Clark, MD; Keith Carter, MD; Erin M Shriver, MD

November 18, 2016

Introduction

Thyroid eye disease (TED) is an autoimmune inflammatory disease of the eye and surrounding tissues. It is also recognized in the literature as Graves' ophthalmopathy, Graves' orbitopathy, thyroid-associated ophthalmopathy, and thyroid orbitopathy. TED was originally associated strictly with the Graves' triad of hyperthyroidism, pretibial myxedema, and eye disease. More recently, TED has also been noted in Hashimoto's thyroiditis as well as in the absence of a thyroid dysfunction. While symptoms are typically bilateral, they are often asymmetric. The most common presenting signs are orbital and periorbital edema, eyelid retraction, eyelid lag in downgaze, restrictive strabismus, compressive optic neuropathy, and exposure keratopathy with common symptoms of ocular irritation and dryness (Figs. 1 and 2) [1]. The disease course of TED does not always coincide with thyroid activity or the treatment of underlying thyroid dysfunction.

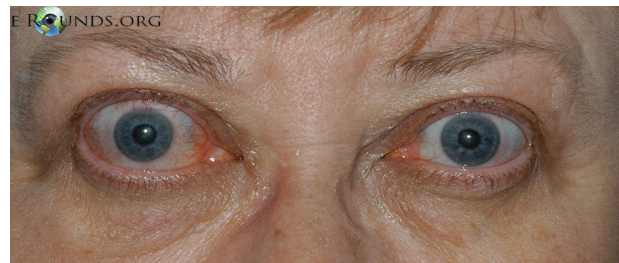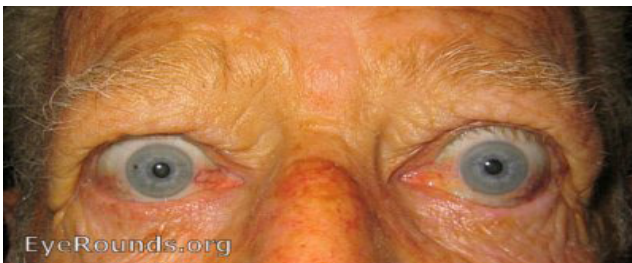Epidemiology

TED is the most common cause of orbital disease in North America and Europe and of both unilateral and bilateral exophthalmos. While TED is most commonly associated with Graves' disease, it can also occur in association with other thyroid states, pathologic or non-pathologic. TED has a higher prevalence in women than men (16 per 100,000 vs. 3 per 100,000, respectively). Both men and women demonstrate a bimodal pattern of age of diagnosis (40-44 and 60-64 years in women; 45-49 and 65-69 years in men). The median age of diagnosis is 43 years for all patients, with a range from 8-88 years. Patients diagnosed over the age of 50 years have a worse prognosis overall. Risk factors for TED include age, gender, ethnicity, and family history. A positive family history of TED is noted in 61% of TED patients[2].

TED exacerbation is thought to be associated with both genetic and environmental factors, such as cigarette smoking, low selenium levels, and stress [3]. Smoking has been shown to adversely affect the development, progression, and response to treatment of TED. Smokers are twice as likely to develop Graves' disease, and smokers who have Graves' disease are 7.7 times more likely to develop TED compared to nonsmokers with Graves' disease. (SEE BELOW "REGARDING SMOKING")

Pathophysiology

- ◆ Development of TED is centered on inflammation of orbital tissue via stimulation of orbital fibroblasts (Fig. 3).
 - Orbital fibroblasts are unlike other fibroblasts in the body, in that they express CD40 receptors (CD40-R), which are normally found on B-cells [4].
 - When T-cells interact with CD40-R on orbital fibroblasts, the orbital fibroblasts produce pro-inflammatory cytokines.
 - This leads to the synthesis of glycosaminoglycans (GAGs) and hyaluronic acid.
 - Up-regulation of GAG synthesis and deposition of GAGs results in congestion and edema of orbital tissue (Fig. 4).
 - Orbital fibroblasts originate from neural crest cells and can differentiate into adipocytes or myofibroblasts [4].
 - *Fibroblast-to-adipocyte* differentiation explains the fatty hypertrophy of orbital tissue found in TED characterized by extensive orbital adipose tissue proliferation and deposition, which more commonly leads to compressive optic neuropathy. [5]
 - *Fibroblast-to-myofibroblast* differentiation explains another variant of TED that manifests primarily with muscle enlargement and more commonly leads to restrictive myopathy [5].



Figures 1, 2: These patients have some of the classic signs and symptoms of TED. Note the periorbital edema, eyelid retraction, scleral show, and conjunctival injection.

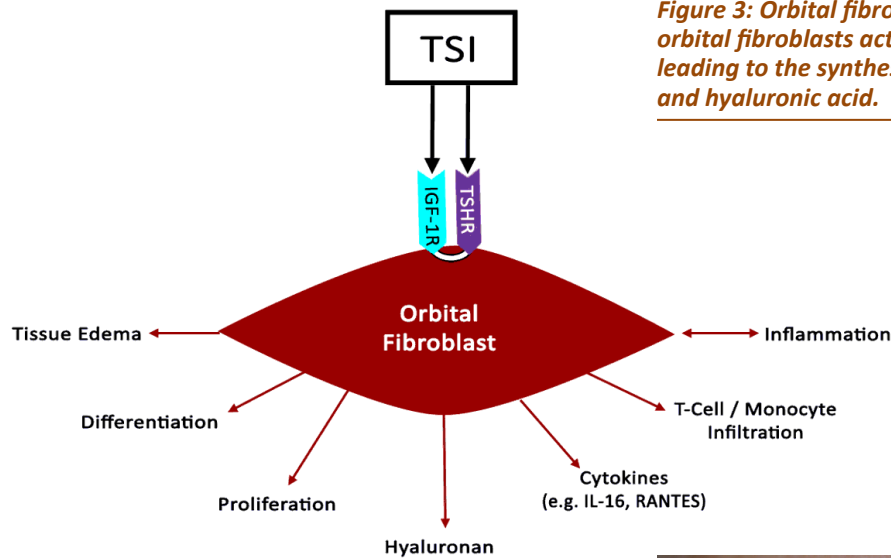


Figure 3: Orbital fibroblast activation. Stimulation of orbital fibroblasts activates pro-inflammatory genes, leading to the synthesis of glycosaminoglycans (GAGs) and hyaluronic acid.

- ◆ Two additional immunologic processes characterize the orbital fibroblast's role in TED
 - Antigen-dependent autoimmune response [1]
 - Expression of both insulin-like growth factor 1 receptor (IGF-1-R) and thyroid-stimulating hormone receptor (TSH-R) directly correlate with TED [6].
 - Both IGF-1-R and TSH-R are present on most types of human cells and are activated by their respective autoantibodies.
 - Activation of IGF-1-R stimulates synthesis of GAGs and secretions of chemoattractants by orbital fibroblasts, leading to orbital inflammation and congestion [6].
 - Activation of IGF-1-R and TSH-R cause orbital cytokine production, leading to GAG deposition in orbital tissues (Fig. 5).
 - TSH-R activation upregulates the synthesis of TSH-R mRNA [7].
 - TSH-R mRNA signals for additional fibroblast differentiation in the orbit.
 - Three types of TSH-R antibodies (TRA) are known, but only one type, thyroid-stimulating immunoglobulin (TSI), is associated with hyperthyroidism and TED [8].
 - A recent study found TSI levels correlate directly with the activity and severity of TED, and all TED patients with diplopia were positive for TSI.
 - TSI is the closest “functional biomarker” of TED that we have at this time.
 - While the amount of TSI produced is directly correlated with TED severity, TED can present without Graves’ disease or autoantibody formation [1].
 - Antigen-independent auto-inflammatory response[1]
 - Cytokines and chemokines directly activate a cell-mediated response, leading to an infiltration of inflammatory cells in orbital tissue.

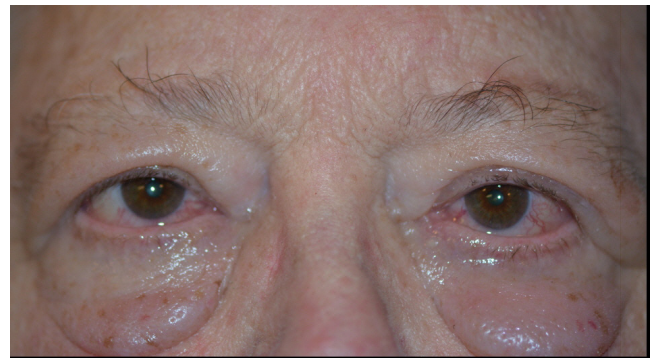

Figure 4: Orbital congestion. Up-regulation of GAG production and deposition results in congestion of orbital tissue.

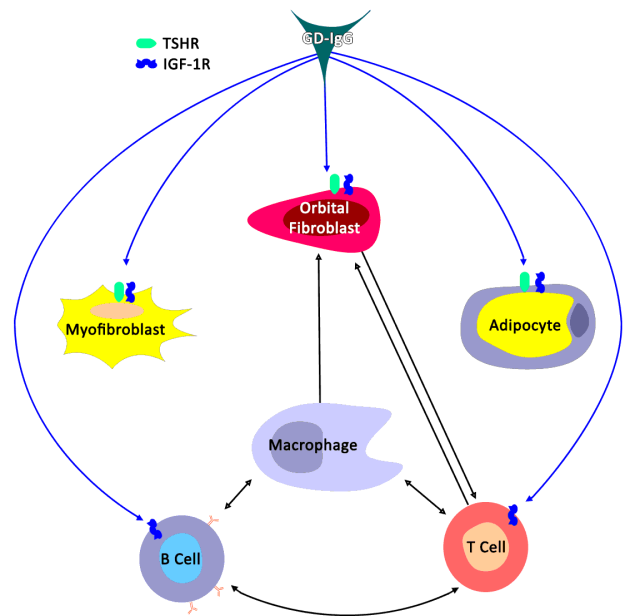


Figure 5: Antibody interaction. IGF-1-R and TSH-R are activated by TSI (GD-IgG). Activation of these receptors produces orbital cytokines, leading to GAG deposition and orbital inflammation and congestion.

- Monocytes, NK cells, and granulocytes are involved.
 - Many treatments of TED have targeted these immunologic processes. (SEE BELOW REGARDING TREATMENT)

Clinical Presentation

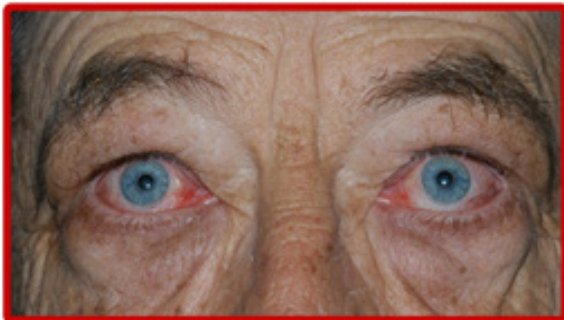The thyroid state of a patient presenting with TED is quite variable: 90% hyperthyroid, 6% euthyroid, 3% with Hashimoto's thyroiditis, and 1% hypothyroid [2]. Patients are simultaneously diagnosed with TED and thyroid dysfunction 20% of the time, and 60% present within 1 year of onset of thyroid disease [9]. However, TED can present long before (up to 10 years) or long after (up to 20 years) the initial presentation of thyroid disease [2].

TED is a self-limiting disease and may present in one of two stages: active or quiescent (Fig. 6). In the active stage, there is active inflammation, which can lead to orbital muscle enlargement, conjunctival injection and chemosis, ocular pain, and swelling of the periocular tissues and eyelids. This stage typically involves waxing and waning TED symptoms and can last months to years. On average, the active phase lasts for 1 year in non-smokers and 2-3 years in smokers. The quiescent phase follows spontaneous resolution of the active phase (Fig. 7). Active TED has a recurrence rate of 5-10% but is less likely to recur after 18 months of quiescence [10].

- ◆ Upper eyelid retraction – the most common presenting sign of TED (Fig. 8)
 - Up to 90% of patients affected (bilateral or unilateral) [2]
 - Multifactorial cause [2]
 - Increased sympathetic tone acting on Müller's muscle
 - Contraction of the levator palpebrae superioris
 - Ptosis
 - Scarring between the lacrimal gland and the levator palpebrae superioris

- Physical exam
 - Dalrymple's sign (Fig. 8): widening of the palpebral fissure with inferior and superior scleral show
 - Lagophthalmos (Fig. 9)
 - Inability to close the eyes completely
 - Manifests as dry eye, tearing, foreign body sensation, blurred vision, and eventually exposure keratopathy, especially with a poor Bell's reflex
 - Temporal flare (Fig. 10): elevation of the temporal upper eyelid compared to its normal anatomical location
- Treatment options (SEE BELOW REGARDING TREATMENT)
- ◆ Exophthalmos – the second most common sign associated with TED (Fig. 11)
 - 60% of patients are affected[2]
 - Physical exam
 - Exposure keratopathy: characteristic punctate epithelial erosions
 - Globe subluxation: anterior displacement of the globe[11]
 - Globe equator protrudes anteriorly in relation to the lids
 - Ophthalmologic emergency
 - Decreased perfusion of the optic nerve and the retina
 - Anoxic destruction of the optic nerve can cause irreversible visual loss
 - Treatment options (SEE BELOW REGARDING TREATMENT)
- ◆ Other common signs and symptoms associated with TED: eyelid lag, extraocular myopathy, pain with eye movement, optic neuropathy, chemosis, and conjunctival injection
 - Eyelid lag
 - 50% of patients affected
 - Static dysfunction in which the upper eyelid is elevated in relation to the globe while in down-gaze

Active Phase



Stable Phase

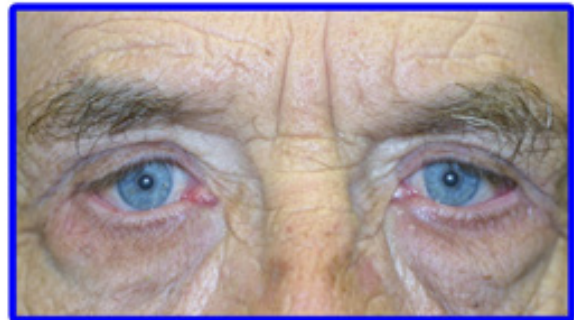

Figure 6: Active vs. Stable TED. Active TED is characterized by signs of inflammation (orbital muscle enlargement, conjunctival injection, swelling of periocular tissue, and chemosis). TED activity waxes and wanes, and usually transitions to stable TED within 1-3 years.

- Von Graefe’s sign
 - Dynamic form of eyelid lag associated with TED
 - Delayed descent of the upper eyelid during downgaze
- Restrictive extraocular myopathy (Figs. 12 and 13)
 - 40% of patients affected
 - Inferior and medial rectus muscles most commonly affected, leading to hypotropia and esotropia, respectively
 - Corneal light reflex –
 - Clinical examination in which position of light reflex relative to pupil and limbus is used to evaluate degree of duction in the four cardinal directions
 - Shown to be the best method of evaluating restrictive extraocular myopathy [12]
- Pain with eye movement[2]
 - 30% of patients affected
- Characterized as dull, deep orbital pain
- Optic nerve dysfunction from compressive optic neuropathy (Fig. 14) [2]
 - 6% of patients affected
 - Compression of the optic nerve due to enlargement of the rectus muscles and increased volume of periorbital tissue within the confines of the bony orbit
 - Presents with dyschromatopsia, decreased vision, and/or visual field defects
 - Ophthalmic emergency requiring immediate attention (SEE BELOW REGARDING TREATMENT)
- Chemosis and conjunctival injection (Figs. 15 and 16)
 - Sign of active inflammation cause by congestion of the orbital tissue
 - More pronounced at the site of the rectus muscle insertion

Disease Time Course and Intervention Strategy

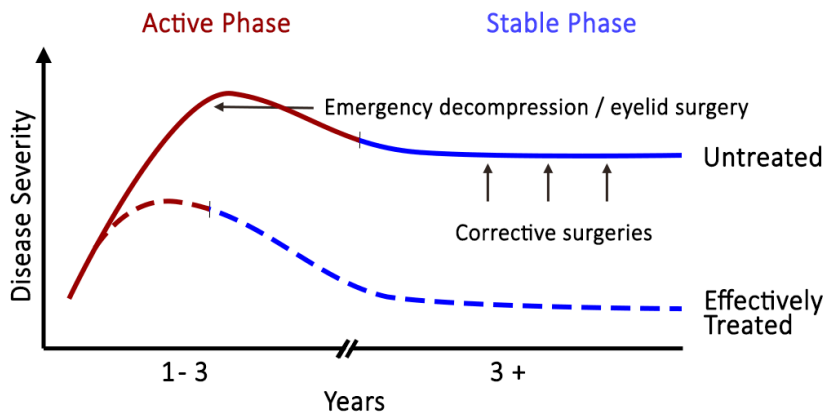


Figure 7: Rundle’s curve. As seen in the representation of TED activity over time in Rundle’s curve, early initiation of therapy is crucial in diminishing the final severity of disease manifestations.

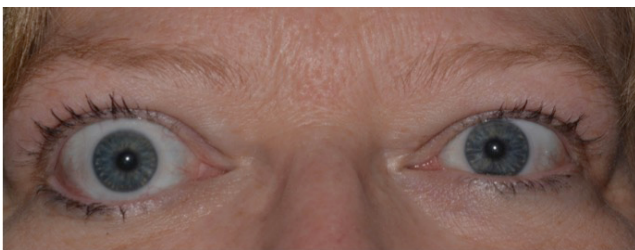

Figure 8: Eyelid retraction and Dalrymple’s sign. EYELID RETRACTION is the most common presenting sign of TED, and is the result of many factors associated with TED. DALRYMPLE’S SIGN is characterized by the widening of the palpebral fissure. Note the superior and inferior scleral show.

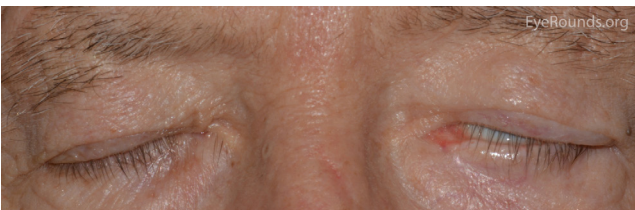

Figure 9: Lagophthalmos typically presents as dry eye, tearing, foreign body sensation, and blurred vision.

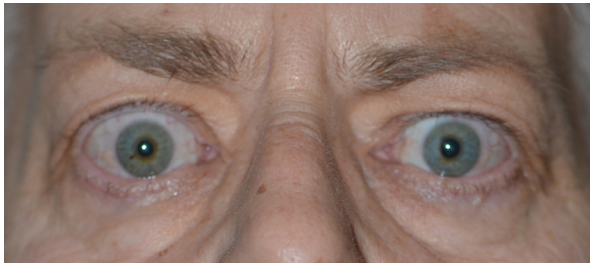

Figure 10: Temporal flare. Note the elevation of the temporal portion of the upper eyelid.

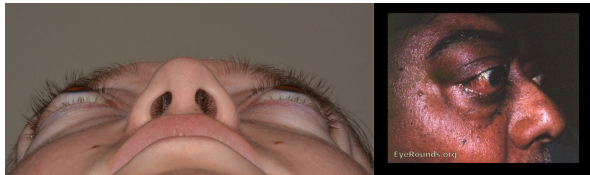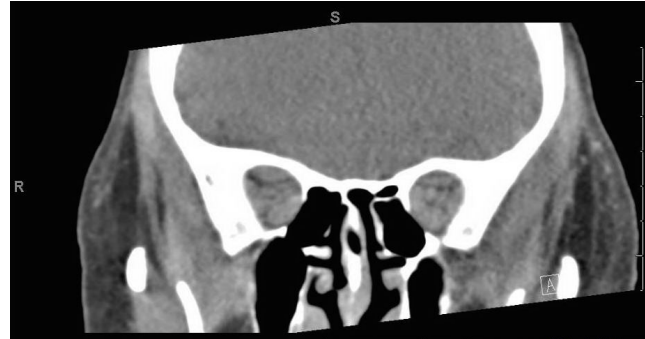


Figure 11: Exophthalmos. The globe is displaced anteriorly out of the orbit. This is an ophthalmologic emergency – the cornea is at risk for exposure, and the optic nerve is at risk of irreversible damage.

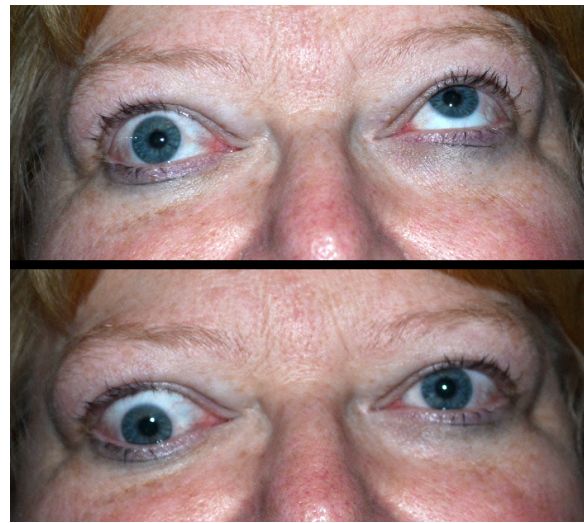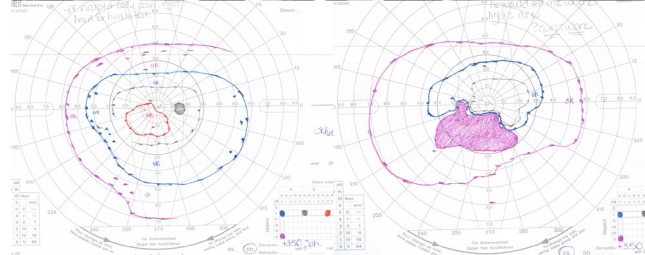
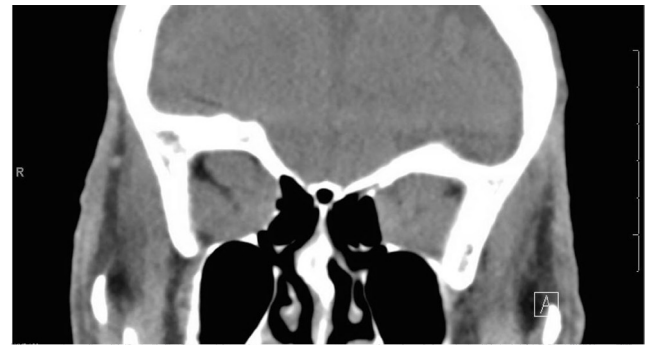
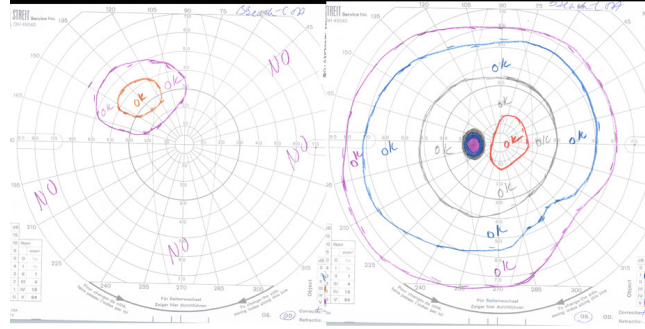


Figure 12: Hypotropia. Note the vertical misalignment of the eyes in primary gaze and the restrictive movement in upward gaze. This is due to an enlarged and restricted inferior rectus muscle.

Figure 14: Compressive optic neuropathy. This sequence shows a series of CT scans from patients with compressive optic neuropathy, with their associated visual fields.

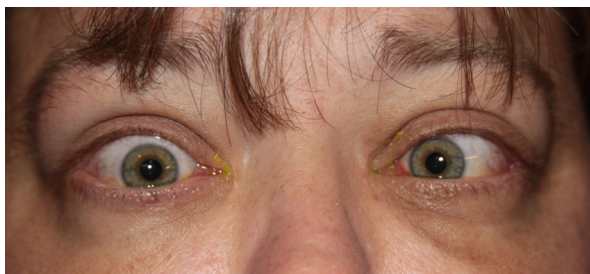

Figure 13: Esotropia. Note the horizontal misalignment of the eyes in primary gaze. This is due to an enlarged and restricted medial rectus muscle.

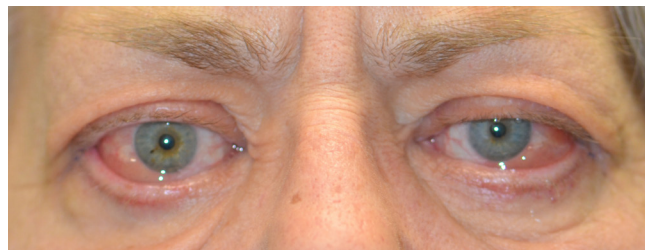

Figure 15: Chemosis. Note the swelling within the conjunctiva.

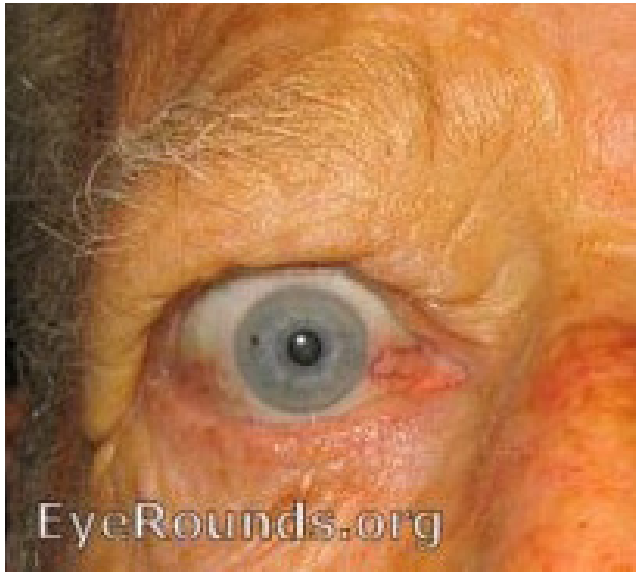

Figure 16: Note the dilation of the nasal and temporal conjunctival vessels.

- Exposure keratopathy (Fig. 17)
 - Secondary sign due to lagophthalmos from eyelid retraction and/or exophthalmos
 - Predisposes the cornea to bacterial infection (keratitis), which can lead to ulceration, endophthalmitis, and perforation
 - Multimodal management (SEE BELOW REGARDING TREATMENT)

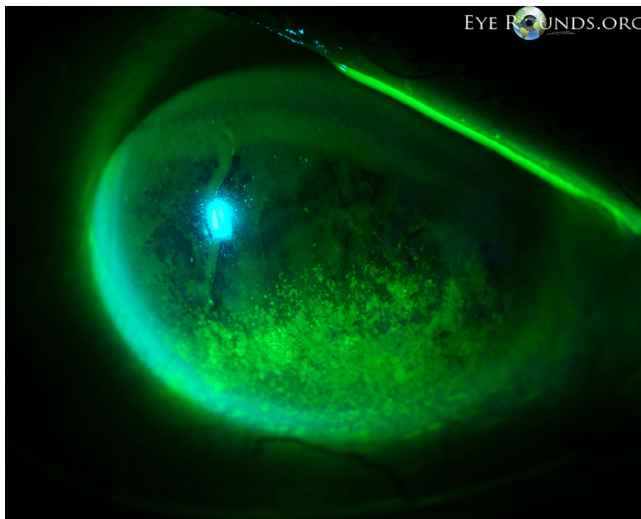


Figure 17: Exposure keratopathy. Punctate epithelial erosions (PEE) secondary to exposure keratopathy.

Workup and Diagnosis

Differential Diagnosis

When examining a patient with suspected TED, it is important to have a working differential. The following diagnoses share some similarities to the clinical presentation of TED

- ◆ **Allergic conjunctivitis** – While both can cause excess tearing and conjunctivitis, allergic conjunctivitis tends to be acute in onset from a new exposure, causes itching, can have papillary conjunctival reaction, and is not associated with eyelid retraction or exophthalmos (Fig. 18).
- ◆ **Myasthenia gravis (MG)** – Like TED, MG patients can present with diplopia. However, MG tends to worsen throughout the day and improves after rest while diplopia in TED is not typically variable. Also, MG patients may present with ptosis, which is not associated with TED. Diplopia associated with TED is restrictive in nature, which can be determined by forced duction testing.
- ◆ **Orbital myositis (OM)** – OM causes enlargement and inflammation of the muscle body and tendon insertion, rather than just the muscle body, as is the case in TED patients. Orbital myositis is not generally associated with eyelid retraction. OM is usually unilateral. A bilateral presentation would be unusual for OM, whereas TED can present either way.
- ◆ **Orbital tumors** – Orbital tumors are typically unilateral in presentation and can cause proptosis and a wide variety of motility disturbances depending on location. Orbital tumors are unlikely to cause eyelid retraction or lid lag. (SEE EYE ROUNDS CASE ON CAVERNOUS HEMANGIOMA bit.ly/2Gtaba8)
- ◆ **Carotid-cavernous fistula (CCF)** – Patients may hear pulse-synchronous tinnitus. Presentation may include proptosis, pulsatile exophthalmos, dilated conjunctival and episcleral vessels, elevated intraocular pressure, or enlarged EOM depending on the amount of flow through the fistula and the degree of congestion. A CCF would not cause eyelid retraction or temporal flare. (SEE EYE ROUNDS CASE ON CCF bit.ly/2BITg3U)
- ◆ **Chronic progressive external ophthalmoplegia (CPEO)** – CPEO slowly progresses over 5-15 years with most patients presenting with ptosis. All cardinal directions of gaze are affected, with downgaze most likely spared. TED, conversely, typically affects downward and nasal gaze.
- ◆ **Inflammatory orbitopathy**, such as granulomatosis with polyangiitis (GPA, formerly known as Wegener’s granulomatosis) – GPA typically presents with a mix of upper airway, lower airway, and renal pathologies. Patients may have conjunctivitis, episcleritis, scleritis, and/or uveitis. Other than conjunctivitis, these findings are uncommon in TED patients.
- ◆ **IgG4 disease** – Tumefactive lesions and fibrosis affecting one or more organs characterize this fibro-inflammatory disorder. It is most commonly present in the

biliary tree, retroperitoneum, salivary glands, orbit, and lymph nodes. It is thought to involve both humoral and cell-mediated immunity. Orbital IgG4 disease often involves painless swelling of the extraocular muscles, lacrimal glands, and infraorbital nerves in combination with paranasal sinus disease. IgG4 disease can also present as an inflammatory orbital mass lesion.

Clinical Requirements for Diagnosis

In diagnosing TED, two of the following three clinical requirements must be met [13,14]

- ◆ Laboratory evidence (current or recently-treated immune-related thyroid dysfunction)
 - Graves' disease
 - Hashimoto's thyroiditis
- ◆ Presence of thyroid antibodies without a dysthyroid state: TRA, thyroid-binding inhibitory antibodies, TSI, antimicrosomal antibody
- ◆ Exam findings (1 or more of the following)
 - Unilateral/bilateral eyelid retraction with temporal flare
 - Unilateral/bilateral proptosis
 - Restrictive strabismus
 - Compressive optic neuropathy
 - Fluctuating eyelid edema/erythema
 - Chemosis/caruncular edema
- ◆ Radiographic evidence: unilateral/bilateral fusiform enlargement of inferior rectus, medial rectus, superior rectus/levator complex, or lateral rectus

Disease Stratification

If TED is suspected, one must determine disease activity and severity in order to assess the urgency of treatment.

Disease Activity

In assessing the activity level of TED in a patient, the clinical activity score (CAS) can be used [15].

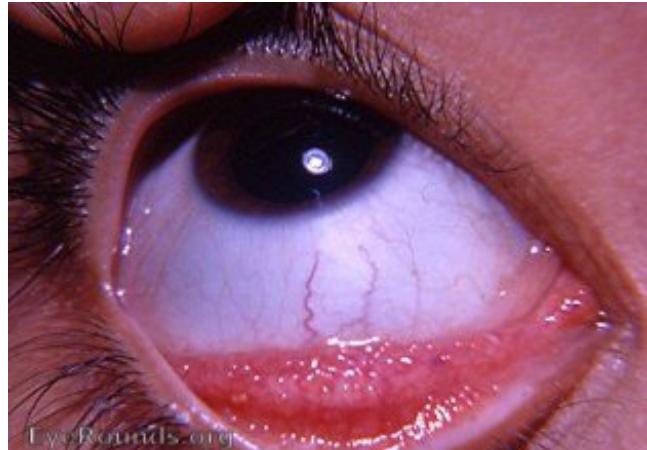

Figure 18: Allergic conjunctivitis. Note the presence of giant papillae.

- ◆ At the initial visit, patients are given a CAS score of 1-7, one point for each sign or symptom (Fig. 19):
 - Spontaneous orbital pain in the last 4 weeks
 - Gaze evoked orbital pain in the last 4 weeks
 - Eyelid swelling that is considered to be due to active TED
 - Eyelid erythema
 - Conjunctival injection considered to be due to active TED
 - Chemosis
 - Inflammation of caruncle or plica semilunaris
- ◆ At follow-up visits, add the 3 following criteria for a potential CAS score of 10 (one point for each sign or symptom)
 - Increase of ≥ 2 mm in proptosis
 - Decrease in uniocular motility in any one direction of ≥ 8 degrees
 - Decrease in visual acuity equivalent to 1 Snellen line
- ◆ TED is considered "active" if the CAS ≥ 3 at the initial visit or ≥ 4 at follow-up visits [16].

◆ Initial Visit (1 point each)

1. Spontaneous orbital pain in last 4 weeks
2. Gaze-evoked orbital pain in last 4 weeks
3. Eyelid swelling
4. Eyelid erythema
5. Conjunctival injection
6. Chemosis
7. Inflammation of caruncle or plica semilunaris

◆ CAS $\geq 3 \rightarrow$ "Active"

◆ Follow-Up Visit (1 point each)

Criteria 1-7

8. Increase ≥ 2 mm proptosis
9. Decrease in uniocular motility in any one direction of $\geq 8^\circ$
10. Decrease in visual acuity equivalent to 1 Snellen line

◆ CAS $\geq 4 \rightarrow$ "Active"

Figure 19: Clinical Activity Score (CAS).

Disease Severity

In classifying the severity of TED, 3 indices are typically used: NOSPECS, EUGOGO, and VISA.

- ◆ The Werner's NOSPECS measures clinical severity based on presenting features [17]
 - Class 0: No signs or symptoms
 - Class 1: Only signs (upper lid retraction and stare, +/- lid lag)
 - Class 2: Soft tissue involvement (edema of conjunctiva and lids, conjunctival injection)
 - Class 3: Proptosis
 - Class 4: Extraocular muscle involvement (usually with diplopia)
 - Class 5: Corneal involvement (primarily lagophthalmos)
 - Class 6: Sight loss (due to optic nerve involvement)
- ◆ The European Group Of Graves' Orbitopathy (EUGOGO) reports that TED severity can be classified by the following measurements [16]
 - Assess for an RAPD
 - Record lid retraction (Fig. 20)
 - MRD 1 (note superior scleral show)
 - MRD 2 (note inferior scleral show)
 - Note if temporal flare is present
 - Hertel exophthalmometer with intercanthal distance
 - Risk of cornea ulceration
 - Lagophthalmos
 - Bell's Phenomenon (if absent, eye will not rotate up and out with lid closure)
- ◆ EUGOGO has also proposed a classification scheme that grades TED as mild, moderate-to-severe, and sight-threatening based on the following criteria [16]
 - Mild
 - Mild impact on daily life
 - Insufficient to justify immunosuppressive/surgical treatment
 - One or more of the following
 - Minor lid retraction (< 2 mm)
 - Mild soft tissue involvement
 - Exophthalmos < 3 mm above normal for race and gender (~18 mm for Asians, 20 mm for Caucasians, and 22 mm for African Americans)
 - Transient or no diplopia
 - Corneal exposure responsive to lubricants
 - Moderate-to-severe
 - Non-sight-threatening but sufficient impact on life to justify immunosuppression or surgical intervention
 - One or more of the following
 - Lid retraction ≥ 2 mm
 - Moderate or severe soft tissue involvement
 - Exophthalmos ≥ 3 mm above normal for race and gender
 - Transient or constant diplopia

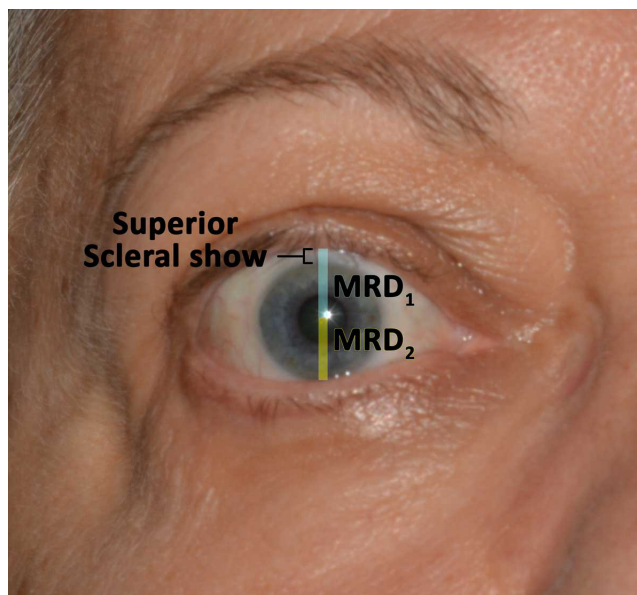


Figure 20: External eye measurements. This patient has lid retraction and superior scleral show. A demonstration of the MRD1 and MRD2 calculations is shown here.

- Sight-threatening
 - TED patients with resultant optic neuropathy and/or corneal breakdown
 - Warrants immediate intervention
- ◆ The VISA analysis (Vision, Inflammation, Strabismus, and Appearance) subjectively and objectively evaluates each category, which is based on the presence and severity of signs and symptoms (Fig. 21).

Treatment

Introduction to Treatment

Management goals include maintenance of general health and well-being, achieving a euthyroid state (without post-treatment hypothyroidism), and promotion of smoking cessation. Both smoking cessation and euthyroidism help prevent further exacerbation and decrease the duration of active disease. From an ophthalmologist's perspective, the primary goal is to preserve visual function, while also preventing exposure keratopathy, correcting diplopia, and improving blink dynamics and cosmesis.

- ◆ Smoking cessation is a key part of treatment.
 - Cigarette smoking
 - Increases severity of disease
 - Decreases the effectiveness of core treatment methods [3]
 - Cyanide, contained in cigarette smoke, is converted in the body to thiocyanate, an anti-thyroid agent
 - inhibits iodine uptake
 - increases iodine excretion
 - inhibits thyroid hormone synthesis

VISA FOLLOW-UP FORM

Date:

Visit #:

Patient Label:

ORBITOPATHY

Symptoms:

THYROID

Symptoms:

Date of birth:

Age:

Gender:

Progress:

Status:

GENERAL

Smoking:

Meds:

Therapy:

Therapy:

QOL: ☹️ ----- 😊

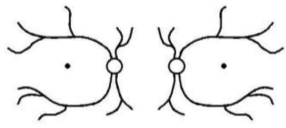
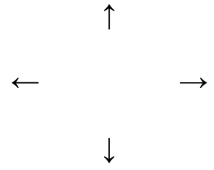

SUBJECTIVE	OBJECTIVE	OD	OS	
<p>VISION</p> <p>Vision: n / abn</p> <p>Color vis: n / abn</p> <p>Progress: s / b / w</p>	<p>Central vision: sc / cc / ph with manifest</p> <p>Color vision plates (HRR) / 14 Pupils (afferent defect)</p> <p>Optic nerve: Edema Pallor</p> <p>Macular/ lens pathology</p>	<p>20/___</p> <p>20/___</p> <p>y / n</p> <p>y / n y / n y / n</p>	<p>20/___</p> <p>20/___</p> <p>y / n</p> <p>y / n y / n y / n</p>	<p>Refractions</p> <p>Wearing _____ + _____ X _____</p> <p>_____ + _____ X _____</p> <p>Manifest _____ + _____ X _____</p> <p>_____ + _____ X _____</p> 
<p>INFLAMMⁿ/ CONGESTION</p> <p>Retrobulbar ache At rest (0-1) With gaze (0-1)</p> <p>Lid swelling: y / n</p> <p>Diurnal variation: (0-1)</p> <p>Progress: s / b / w</p>	<p>Caruncular edema (0-1)</p> <p>Chemosis (0-2)</p> <p>Conjunctival redness (0-1)</p> <p>Lid redness (0-1)</p> <p>Lid edema Upper (0-2) Lower (0-2)</p>			<p>Inflammatory Index (worst eye/eyelid)</p> <p>Caruncular edema (0-1):</p> <p>Chemosis (0-2):</p> <p>Conj redness (0-1):</p> <p>Lid redness (0-1):</p> <p>Lid edema (0-2):</p> <p>Retrobulbar ache (0-2):</p> <p>Diurnal Variation (0-1):</p> <p>Total: (10):</p>
<p>STRABISMUS/ MOTILITY</p> <p>Diplopia: None (0) With gaze (1) Intermittent (2) Constant (3)</p> <p>Head turn/ tilt: y / n</p> <p>Progress: s / b / w</p>	<p>Ductions (degrees):</p> <p>Restriction > 45° 30-45° 15-30° < 15°</p>	<p>+</p> <p>0 1 2 3</p>	<p>+</p> <p>0 1 2 3</p>	<p>Prism Measure:</p> 
<p>APPEARANCE/EXPOSURE</p> <p>Lid stare y / n</p> <p>Light sensitivity y / n</p> <p>Bulging eyes y / n</p> <p>Tearing y / n</p> <p>Ocular irritation y / n</p> <p>Progress: s / b / w</p>	<p>Upper lid position: MRD</p> <p>Scleral show (upper) (lower)</p> <p>Levator function</p> <p>Lagophthalmos</p> <p>Exophthalmometry (Base: mm)</p> <p>Corneal erosions</p> <p>Corneal ulcers</p> <p>IOP -straight -up</p>	<p>mm mm mm mm mm mm y / n y / n mmHg mmHg</p>	<p>mm mm mm mm mm mm y / n y / n mmHg mmHg</p>	<p>Fat prolapse and eyelid position:</p> 
<p>DISEASE GRADE</p> <p>V (optic neuropathy) y / n</p> <p>I (inflammation/congestion) 0-10</p> <p>S (diplopia) 0-3</p> <p>(restriction) 0-3</p> <p>A (appearance/exposure): normal - severe</p>		<p>Grade</p> <p>/ 1</p> <p>/ 10</p> <p>/ 3</p> <p>/ 3</p> <p>/ 3</p>	<p>Progress / Response</p> <p>s / b / w</p> <p>s / b / w</p> <p>s / b / w</p> <p>s / b / w</p> <p>s / b / w</p>	<p>DISEASE ACTIVITY</p> <p>Active</p> <p>Quiescent</p>
<p>MANAGEMENT</p>		<p>FOLLOW-UP INTERVAL:</p>		

Figure 21: VISA chart

- Smokers are twice as likely to develop Graves' disease when compared to nonsmokers.
- Patients with Graves' disease who smoke are 7.7 times more likely to develop TED when compared to nonsmokers.
- Smoking reduces the effectiveness of TED treatments such as corticosteroids and RAI.

TED is a self-limiting disease, with patients moving from the active to quiescent phase within 1-3 years with a 5-10% risk of recurrence [10]. Treatment for TED should start at the time of the diagnosis, as treatment becomes less effective as the disease progresses from the early, acute, active phase to the chronic quiescent phase.

◆ Rundle's Curve (Fig. 22)

- Early initiation of therapy is crucial in diminishing the final severity of disease manifestations.
- Treatment initiation
 - Treatment initiated during the early months of the active inflammatory phase has been shown to be most effective.
 - Initiation of therapy during the final months of active inflammatory phase has little effect on the final outcome of disease.
- Once the chronic fibrotic stage has set in, treatment options become more limited, i.e. primarily surgical.
- ◆ The majority of patients with TED (~75%) have mild to moderate disease and require primarily supportive care as a means of symptom management.
 - Ocular lubrication, by way of daytime eyedrops and nighttime ophthalmic ointment, is the mainstay of treatment for mild to moderate disease.
 - Topical cyclosporine has been shown to be beneficial in reducing symptoms of ocular surface irritation [10].
 - The following lifestyle modifications are also helpful adjuncts to ocular lubrication
 - Smoking cessation
 - Sodium restriction to reduce water retention and tissue edema
 - Sleeping with the head of the bed elevated to decrease orbital edema
 - Sunglasses to decrease photophobia and feelings of dryness
 - Oral NSAIDs can be used if periocular pain is a prominent complaint [10].
 - In the presence of diplopia, temporary press-on prism lenses (e.g. Fresnel) can be utilized.
 - Once stability in diplopia is achieved, the prism can be ground into glasses.
 - Alternatively, for stable diplopia, the patient may undergo strabismus surgery, assuming the patient has been in the stable phase of TED for several months.
 - Mineral supplementation with selenium, when taken regularly, has been shown to exert a significant

Disease Time Course and Intervention Strategy

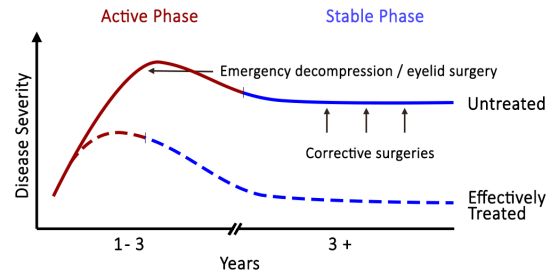


Figure 22: Rundle's curve. As seen in the representation of TED activity over time in the Rundle's curve, early initiation of therapy is crucial in diminishing the final severity of disease manifestations.

benefit in European patients with mild, non-inflammatory orbitopathy, but the benefit of this supplementation in other regions is debated [18].

- ◆ Approximately 20% of patients with TED undergo some type of surgical intervention [19].
 - In one study, 13% of patients with TED had eyelid surgery, 9% strabismus surgery, and 7% orbital decompression [19].
 - As a general guideline, surgery is not advised until a euthyroid state is maintained and the TED has been in the stable phase for at least 6-9 months.
 - Exceptions include visual loss from compressive optic neuropathy or corneal exposure, in which cases urgent surgical intervention is warranted.
 - In order to prevent repeat surgery following recovery from subsequent procedures, surgery for TED occurs in the following order, whenever possible
 - Orbital decompression
 - Strabismus surgery
 - Eyelid surgery

Aside from threatening vision and causing ocular and orbital pain, TED can be disfiguring and emotionally and psychologically taxing for many patients. Waxing and waning symptoms can be frustrating for both patient and provider. Education and reassurance are integral components of patient care. Peer support groups are invaluable for many patients.

Management of Systemic Hyperthyroidism

The following section starts with an overview of managing hyperthyroidism, followed by the different treatment options used in TED. It concludes with a discussion about therapeutic modalities specific to each sign or symptom associated with TED.

- ◆ While the course of TED does not parallel the status of systemic thyroid disease, achieving a euthyroid state is an important part of management.
 - Hyper- or hypothyroidism has been associated with a greater severity score than euthyroid patients.

- Restoration of a euthyroid state by antithyroid drugs has been associated with improvement of TED over several months [20].
- ◆ Oral beta-blockers can be used for symptom control (Fig. 23).
 - They decrease conversion of free T4 to T3.
 - They decrease heart rate, palpitations, anxiety, and heat intolerance.
- ◆ Propylthiouracil and methimazole, thiourea derivatives, are used for thyroid hormone suppression.
 - Remission rates are 30-50% at 12-24 months [21].
 - Relapse and/or hypothyroidism can occur.
 - Thyroidectomy can successfully treat the hyperthyroid state.
 - Nearly half of patients will become hypothyroid following surgery so close monitoring is needed [21].
 - Many studies have shown that post-thyroidectomy hypothyroidism results in worsening progression of TED [22].
 - Consider thyroidectomy in patients who are high risk for severe exacerbations of hyperthyroidism and are refractory to other treatment modalities [10].
- Smokers
- Severe, active TED
- Elevated T3 concentrations
- ◆ Radioactive Iodine (RAI)
 - 80% of patients achieve a hypothyroid state at 6-12 months [21].
 - RAI therapy is known to exacerbate TED in nearly 1/3 of patients undergoing treatment [23].
 - This may be caused by an increased release of TSH-R antigens from the thyroid cells, which enhances the immune response [8].
 - Smokers are more likely to demonstrate worsening following RAI [24].
 - Closely monitor thyroid labs following RAI therapy .
 - “Block and replace” therapy (RAI + methimazole + thyroxine) has been shown to limit post-RAI hypothyroidism [10].
 - RAI with moderate-dose oral prednisone is indicated when the risks of worsening TED outweigh the potential risks of systemic side effects from glucocorticoid therapy [22].

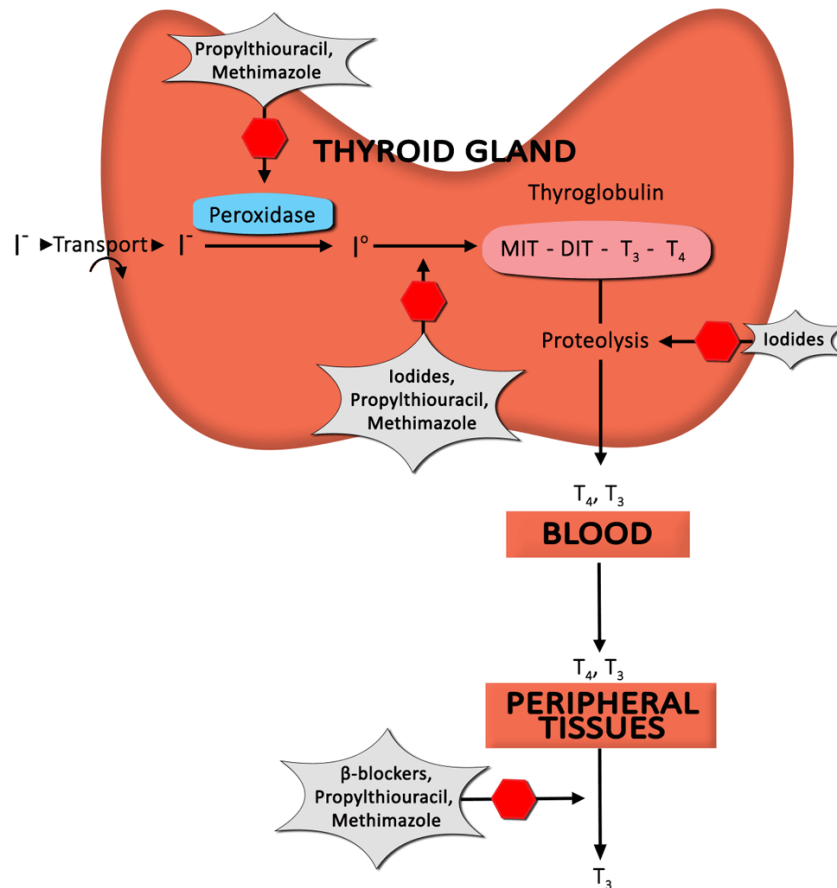


Figure 23: Anti-thyroid drug mechanisms. This diagram depicts the formation of thyroid hormone, as well as the mechanism of action of anti-thyroid drugs to decrease levels of circulating thyroid hormone.

- ◆ Thyroid Storm [22]
 - This hypermetabolic state is triggered by release of excessive thyroid hormone, which can lead to severe hypotension, heart failure, and shock.
 - It is inevitably fatal if untreated.
 - Triggers include stress (i.e. surgery, anesthesia), thyroid surgery, or RAI.
 - To prevent thyrotoxicosis, avoid operating on patients who are currently hyperthyroid.
- Multiple potential side effects, including but not limited to:
 - Cushing’s syndrome
 - Weight gain
 - Increased risk of infection
 - Exacerbation of diabetes mellitus, hypertension, and/or osteoporosis

Overview of Treatment Options

Corticosteroid Therapy

Corticosteroids are a mainstay of treatment in TED. The benefit derived from corticosteroid administration is due to anti-inflammatory and immunosuppressive effects. Unfortunately, a significant percentage of patients respond only partially (or not at all), and recurrences upon dose reduction or cessation are not infrequent [19].

- ◆ Oral prednisone[19]
 - This is typically started in high doses (60-100 mg daily).
 - Most effective in treating soft tissue changes and optic neuropathy
 - Usually tapered slowly over a course of several months
 - Multiple studies show a mean effectiveness rate of ~ 60%.
 - Drawbacks include:
 - High rate of ineffectiveness (~ 40%)
 - Need for high doses for an extended period of time
 - Frequent relapses upon dose reduction/therapy cessation

- ◆ Intravenous (IV) corticosteroids [15 ,25]
 - Compared to oral administration, IV is usually better tolerated and more effective (mean effectiveness ~ 70%).
 - Compared to months of treatment with oral prednisone, IV treatment usually lasts 12 weeks (6 weeks – 500 mg once weekly; 6 weeks – 250 mg once weekly), which allows for easy and early detection of “non-responders.”
 - IV decreases the need for additional medical therapy.
 - Additional considerations:
 - If prolonged high-dose treatment is anticipated, treat with calcium, vitamin D, and a proton pump inhibitor (for patients at high risk for gastric ulceration).
 - Incorporate frequent monitoring of serum electrolytes, blood glucose, liver function tests (LFTs), and blood pressure.
 - Patients receiving cumulative doses exceeding 8 g are at risk for hepatic toxicity, electrolyte disturbances, and cardiac arrhythmias [25].

Orbital Radiotherapy

Orbital radiotherapy (ORT) has been used in the management of TED for nearly a century and can be used alone or in conjunction with corticosteroids [26 ,27].

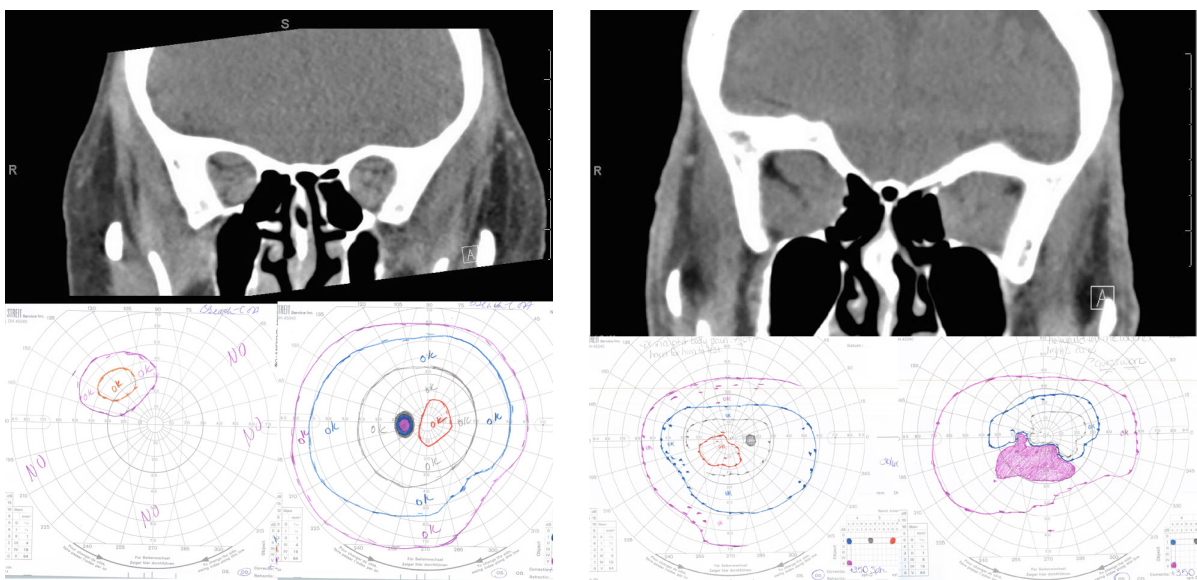


Figure 24: Compressive optic neuropathy. This sequence shows a series of CT scans from patients with compressive optic neuropathy, with their associated visual fields.

- ◆ Mechanisms of action [28]
 - Lymphocytes are temporarily sterilized.
 - Terminal differentiation in orbital fibroblasts is induced.
 - Adipocyte differentiation and fatty hypertrophy are limited.
 - This is more effective in patients < 40 years old who have more orbital fat hypertrophy.
 - Radiation induces death of tissue-bound monocytes.
 - Radiation blunts the immune response at the orbit, reducing inflammation of both the ocular surface and eyelids in ~ 60% of patients [10].
 - ORT has not been shown to have notable effects on proptosis or eyelid retraction.
- ◆ ORT can be used to treat the following sequelae of TED:
 - Compressive optic neuropathy
 - Ocular surface and periorbital tissue inflammation
 - Orbital congestion
 - Strabismus and ocular motility deficits
- ◆ Treatment regimen and effects
 - Use 2000 cGy, administered over 10 treatment sessions, during a 2-week time course [26].
 - A maximum effect occurs around 6 months post-treatment [29].
 - Treatment is associated with a transient exacerbation of periorbital edema, conjunctival injection, and chemosis [29].
- ◆ The role of ORT monotherapy has been controversial due to highly irregular results [26].
 - Effectiveness rates range from 20% - 90% in previously published studies.
 - The most convincing evidence for benefit is found in the treatment of restrictive vertical strabismus.
- ◆ A recent Cochrane review concluded that the combination of corticosteroids + ORT has a more sustained anti-inflammatory effect, leading to a decreased risk of compressive optic neuropathy in active TED patients, when compared to treatment with either corticosteroids or ORT monotherapy [27].
- ◆ Contraindications [29]
 - Patients with underlying microvascular retinopathy (e.g. diabetic or hypertensive retinopathy) have an increased incidence of radiation retinopathy (1-2%).
 - Patients may have increased risk of cataracts.
 - There is a theoretical concern for tumorigenesis, and thus, ORT is typically avoided in patients younger than 35 years.

Selenium [18]

- ◆ When taken regularly for one year, selenium has been shown to exert significant benefits in patients with mild, non-inflammatory orbitopathy.
- ◆ One study showed a benefit from selenium supplementation (100 µg twice daily) in Europe where the soil was selenium deficient.

- ◆ The benefit of selenium supplementation from non-selenium-deficient populations is not known.

Emerging Therapies

- ◆ Azathioprine [30]
 - This is a chemotherapeutic agent that inhibits DNA synthesis.
 - It is currently being studied in a Combined Immunosuppression and Radiotherapy in TED (CIRTED) trial [31].
 - Sporadic case reports have shown a benefit with use of the anti-TNF alpha biologics infliximab and etanercept.
- ◆ Rituximab [32]
 - This targets CD-20 on B-cells, which leads to B-cell depletion in the thyroid gland and decreased TSI production.
 - A recent study showed TED patients with CAS ≥ 4 that received rituximab (1000 mg, IV, twice over a two week interval) showed an average decrease in CAS that ranged from 2.3 to 4.7, with a median decrease ranging from 2.5 to 4.5.
 - The overall efficacy of rituximab therapy is complicated by the variable presentations and course of TED.
- ◆ Teprotumumab
 - Human monoclonal antibody (Graves' Disease IgG – GD-IgG) against the IGF-1-R recently investigated (phase II clinical trial) in patients with active, moderate to severe TED.
 - IGF-1-R has mitogenic and anti-apoptotic functions.
 - GD-IgG interacts directly with IGF-1-R.
 - IGF-1-R is upregulated in TED.
 - Anti-IGF-1-R therapy may interfere with this abnormal signaling pathway present in TED.

Treatment of Emergent Conditions

Optic Neuropathy

Overview (Fig. 24)

- ◆ Optic neuropathy occurs in about 6% of TED patients.
 - Mechanism
 - Inflammation and congestion at the orbital apex are severe enough that the optic nerve and its blood supply become compressed in the confines of the bony orbit.
 - Progressive expansion and congestion of the orbital tissues can lead to further stretching of the optic nerve.
 - Presentation
 - In most cases, vision loss is insidious, progressive, and typically bilateral (usually asymmetric).
 - Dyschromatopsia is an early sign of optic nerve dysfunction.
 - Common visual field deficits are loss of vision or central or diffuse visual field depression.

- The appearance of the optic disc is often unremarkable but can be edematous or atrophic.
- If disease is asymmetric, an RAPD may be present.

Treatment Modalities

◆ Corticosteroid therapy (Oral or IV)

- This is considered first-line therapy for compressive optic neuropathy [33]
 - This may be primary treatment, or a temporizing measure, until surgical decompression can be performed.
 - In non-emergent cases, steroid treatment (100 mg oral, tapering by 10 mg/week, for a total of 12 weeks) has been shown to be as effective as orbital decompression [15].
 - IV methylprednisolone can be used in management of both emergent and non-emergent cases of optic neuropathy.
 - High-dose IV methylprednisolone (830 mg weekly for 6 weeks, followed by 415 mg weekly for 6 weeks) in pulsatile administration is more efficacious than oral corticosteroids [25].
 - When cumulative doses exceed 8 g, measure liver enzymes and test liver function, as fatal hepatotoxicity has been reported [25].

◆ Orbital radiotherapy (ORT)

- This may be an alternative treatment to avoid extensive side effects associated with corticosteroid use [28].
- Numerous studies have demonstrated the effectiveness of ORT [27].
 - Over a 2 week time course, 2000 cGy are administered over 10 treatments.
 - This reduces extraocular muscle width near the orbital apex and may avoid need for urgent surgical decompression.
- There is concern for an initial inflammatory response with ORT, which can worsen compressive optic neuropathy [34].
- Fat may become more fibrotic after radiation, making decompression less effective post-radiation.

◆ Orbital Decompression

- See the following EyeRounds videos
 - Left lateral orbital decompression (04:35) bit.ly/2ESYDj7
 - Left medial orbital decompression (03:43) bit.ly/2okvSkZ
 - Right lateral orbital decompression (03:37) bit.ly/2oem0Km
 - Right medial orbital decompression (01:03) bit.ly/2okOn9d
 - Right orbital floor decompression (01:47) bit.ly/2ETeY2r
- If vision loss is rapid and progressive, surgical orbital decompression may be required to relieve pressure on the optic nerve and its blood supply –

typically after a failed trial of corticosteroids.

- This invasive procedure involves removal of bone and sometimes adipose tissue to provide access to space outside the orbit, which allows excess tissue to decompress from the confined orbit.
- Lateral wall decompression
 - ◆ Partial- or full-thickness inner aspects of the zygomatic bone and greater wing of the sphenoid bone are removed, which is typically performed through a canthotomy with inferior cantholysis.
 - ◆ Potential complications include cerebrospinal fluid leak secondary to dural tear, pulsatile exophthalmos, and oscillopsia [35].
 - Medial wall decompression
 - Segments of the ethmoid bone are removed allowing intraorbital contents to expand into the ethmoid air cells.
 - The lateral wall of the sphenoid bone may be removed as well.
 - The approach may be external or endoscopic.
 - When an external incision is made, it is typically transcaruncular and/or an extension of the orbital floor decompression incision, when applicable.
 - Potential complications
 - Diplopia secondary to alteration of globe position may occur.
 - Medial rectus prolapse into the ethmoid sinus can cause an abduction deficit.
 - Compression of the lesser wing of the sphenoid can cause internal carotid artery laceration or optic nerve damage.
 - Orbital floor decompression
 - This allows for expansion of orbital contents into the maxillary sinus.
 - Decompression may be performed just medial to the infraorbital nerve (largest area with the most benefit in decompressing the optic nerve) or may be both medial and lateral to the infraorbital nerve.
 - The optic strut is often left intact to minimize globe displacement.
 - Caution must be taken to avoid the infraorbital neurovascular bundle, which traverses the infraorbital canal.
 - Decompression is typically performed through a transconjunctival incision with a lateral canthotomy and inferior cantholysis, but a subciliary approach is used as well.
 - Potential complications include diplopia secondary to globe ptosis, supraduction deficit from inferior rectus prolapse, and CN V2 - distribution hypoesthesia.
 - Orbital fat decompression
 - The orbital fat may be removed alone or in conjunction with bony decomposition.
 - Orbital fat decompression has been shown to be especially beneficial in patients who tend to

have more orbital fat hypertrophy than EOM involvement, which is more common in patients < 40 years old.

- Pre-operative planning with computed tomography (CT) [36]
 - This may help confirm the diagnosis of TED.
 - CT allows for evaluation of the anatomy of the sinuses, cribriform plate, and lateral wall of the orbit.
 - CT also helps assess the potential benefit of fat and bone removal.
- Considerations with orbital decompression surgery
 - Decompression may be of any wall alone or in combination with other walls.
 - The medial wall and orbital floor decompressions are of the most benefit in compressive optic neuropathy but have a slightly higher rate of diplopia post-operatively.
 - The decompression is called “balanced” when the medial wall and lateral wall are included.
 - Studies have shown that the balanced decompression has lower rates of diplopia as compared to decompressions involving the floor.

Globe Subluxation

- ◆ Initial management with digital repositioning [37]
 - If digital repositioning fails, a Desmarres retractor (or if not available, a large-sized paperclip, bent to form a right angle (similar to a laryngoscope)) can be used to navigate between the upper lid margin and superior rectus to allow for proper repositioning.
 - Lateral tarsorrhaphy or orbital decompression surgery may be necessary, if initial managements fail.

Corneal Exposure

- ◆ Patients at high risk for corneal exposure include those with a combination of proptosis, eyelid retraction, lagophthalmos, neurotrophic cornea, and poor Bell’s reflex.
- ◆ Pathogenesis is centered on prolonged exposure of corneal surface, leading to corneal drying, which decreases vision and threatens barrier to infection.
- ◆ Treatment of non-emergent cases includes
 - Environmental modifications
 - Ocular surface lubrication
 - Increasing tear production via immunosuppression (cyclosporine, loteprednol, fluometholone)
 - Decreasing tear evaporation
 - Increasing oil content of tears
 - Omega-3 fatty acids
 - Warm compresses
 - Decreasing surface area for exposure and evaporation with eyelid surgery
 - Lid retraction repair
 - Orbital decompression
 - Lid tarsorrhaphy
 - Decreasing tear outflow (punctal plugs or cautery)

- ◆ Treat emergent cases when corneal integrity is threatened.
 - The cause of the exposure must be corrected, and more aggressive therapy is pursued to provide protection and moisture in the meantime.
 - A bandage contact lens (BCL) or scleral contact lens with concomitant topical antibiotic will protect the cornea from further drying, while also preventing infection.
 - A temporary tarsorrhaphy may be indicated while pursuing other treatment modalities to decrease factors that exacerbate exposure, including
 - Chemosis
 - Proptosis
 - Eyelid retraction
 - Ocular Surface Inflammation

Treatment of Non-Emergent Conditions

Proptosis (see Figure 11)

- ◆ Orbital decompression increases the volume of the bony orbit through removal of orbital bone and adipose tissue and allows a proptotic globe to recess back into its normal confines.
 - It is considered first-line therapy for cases of severe optic nerve compression.
 - Other indications include
 - Globe subluxation
 - Exposure keratopathy
 - Restoration of pre-morbid appearance in patients with residual proptosis following the active stage of TED
 - Because decompression surgery can alter globe positioning, decrease eyelid retraction, and affect extraocular motility, it should precede any extraocular muscle or eyelid surgery.
 - Orbital decompression can reduce proptosis and eyelid retraction [38].
 - See the “**EMERGENT TREATMENT**” section above for more information on orbital decompression.
- ◆ TED affects extraocular muscles in a predictable manner [39].
 - The inferior rectus and medial rectus are most commonly involved.
 - This presents as hypotropia and/or esotropia.
- ◆ Most TED patients with diplopia due to strabismus will not require surgical intervention, as most can be effectively managed with prism spectacles [39].
- ◆ Indications for strabismus surgery [39]
 - Patients may have intractable diplopia in primary gaze or with reading.
 - Abnormal head positioning may be present.
 - The position of the globe may be cosmetically unacceptable.

- ◆ Surgical approach [39]
 - Delay strabismus surgery until disease stability has been demonstrated.
 - Recession of the affected muscles is the most commonly used surgical method.
 - Adjustable sutures are helpful in especially difficult cases.
 - Although diplopia is frequently improved post-operatively, normal ocular motility is infrequently achieved for the following reasons
 - Restrictive nature of myopathy
 - Large muscle recessions
 - Ongoing chronic disease
 - With recession of the inferior rectus muscle, infraduction deficits may result, making the use of bifocals challenging.
- ◆ Extraocular muscle recession can worsen proptosis [40].
 - If orbital decompression is foreseeable, it should be performed prior to strabismus surgery, as orbital decompression can also alter strabismus.
- ◆ Extraocular muscle recession can effect eyelid position [40].
 - Large inferior rectus muscle recession can result in lower eyelid retraction, which is largely due to adherence between the inferior rectus muscle and the capsulopalpebral fascia of the lower eyelid.
 - With superior rectus recession, connection points between the superior rectus and upper eyelid elevators may worsen upper eyelid retraction.
 - Strabismus surgery should be undertaken prior to any corrective eyelid procedures.
- ◆ Botulinum toxin [41]
 - Poor surgical candidates that cannot be treated with prisms may benefit.
 - Restricted extraocular muscles are injected, which temporarily relieves restrictive strabismus and may have some lasting effects.
 - Consider alternative treatment if there is need for recurrent injections, difficulty in precisely delivering the agent within the orbit, or variability of effect on fibrotic extraocular muscles.

Eyelid Retraction (see Fig. 8)

- ◆ The etiology is multifactorial and may include
 - Increased sympathetic tone stimulating Müller’s muscle
 - Contraction and/or fibrosis of the levator palpebrae superioris in the upper lid and lower lid retractors in the lower lid
 - Proptosis
 - Scarring between the lacrimal gland and the levator palpebrae superioris

- ◆ Treatment
 - Non-surgical
 - Injection of hyaluronic acid gel fillers
 - Botulinum toxin to levator palpebrae superioris and/or Müller’s muscle [41]
 - A temporary measure injected into the levator palpebrae superioris to lower the upper eyelid position
 - Good for poor surgical candidates, patients in the active phase, or patients awaiting stability
 - Surgical
 - Implantation of an eyelid weight into the upper lid (e.g. gold or titanium)
 - Incision and/or recession of one or more of the eyelid retractors
 - Levator palpebrae superioris
 - Müller’s muscle
 - Capsulopalpebral fascia
 - Inferior tarsal muscle
 - Full-thickness blepharotomy
 - Insertion of “spacer” material to lengthen the eyelid
 - Ear cartilage
 - Hard palate
 - Sclera
 - Synthetic material
 - Porcine
 - Eyelid contouring [40]
 - Aimed at restoring the natural appearance of the eyelid while minimizing temporal flare
 - Upper eyelid peak: medial edge of the pupil
 - Lower eyelid trough: lateral limbus

References

1. Douglas RS, Gupta S. The pathophysiology of thyroid eye disease: implications for immunotherapy. *Curr Opin Ophthalmol* 2011;22(5):385-390. [PMID 21730841]
2. Bartley GB, Fatourechi V, Kadrmas EF, Jacobsen SJ, Ilstrup DM, Garrity JA, Gorman CA. Clinical features of Graves’ ophthalmopathy in an incidence cohort. *Am J Ophthalmol* 1996;121(3):284-290. [PMID 8597271]
3. Krassas GE, Wiersinga W. Smoking and autoimmune thyroid disease: the plot thickens. *Eur J Endocrinol* 2006;154(6):777-780. [PMID 16728534]
4. Kazim M, Goldberg RA, Smith TJ. Insights into the pathogenesis of thyroid-associated orbitopathy: evolving rationale for therapy. *Arch Ophthalmol* 2002;120(3):380-386. [PMID 11879144]
5. Smith TJ, Koumas L, Gagnon A, Bell A, Sempowski GD, Phipps RP, Sorisky A. Orbital fibroblast heterogeneity may determine the clinical presentation of thyroid-associated ophthalmopathy. *J Clin Endocrinol Metab* 2002;87(1):385-392. [PMID 11788681]

6. Tsui S, Naik V, Hoa N, Hwang CJ, Afifiyan NF, Sinha Hikim A, Gianoukakis AG, Douglas RS, Smith TJ. Evidence for an association between thyroid-stimulating hormone and insulin-like growth factor 1 receptors: a tale of two antigens implicated in Graves' disease. *J Immunol* 2008;181(6):4397-4405. [PMID 18768899]
7. Naik V, Khadavi N, Naik MN, Hwang C, Goldberg RA, Tsirbas A, Smith TJ, Douglas RS. Biologic therapeutics in thyroid-associated ophthalmopathy: translating disease mechanism into therapy. *Thyroid* 2008;18(9):967-971. [PMID 18713027]
8. Ponto KA, Zang S, Kahaly GJ. The tale of radioiodine and Graves' orbitopathy. *Thyroid* 2010;20(7):785-793. [PMID 20578895]
9. Holds JB, Buchanan AG. Graves orbitopathy. Focal Points: Clinical Modules for Ophthalmologists. Module 11. San Francisco: American Academy of Ophthalmology; 2010.
10. Bartalena L, Marcocci C, Bogazzi F, Manetti L, Tanda ML, Dell'Unto E, Bruno-Bossio G, Nardi M, Bartolomei MP, Lepri A, Rossi G, Martino E, Pinchera A. Relation between therapy for hyperthyroidism and the course of Graves' ophthalmopathy. *N Engl J Med* 1998;338(2):73-78. [PMID 9420337]
11. Talke LM, Murchison AP. Globe Subluxation: Review and Management. *Review of Ophthalmology* 2007;14 (www.reviewofophthalmology.com/article/globe-subluxation-review-and-management)
12. Dolman PJ, Cahill K, Czyz CN, Douglas RS, Elner VM, Feldon S, Kazim M, Lucarelli M, Sivak-Collcott J, Stacey AW, Strianese D, Uddin J. Reliability of estimating ductions in thyroid eye disease: an International Thyroid Eye Disease Society multicenter study. *Ophthalmology* 2012;119(2):382-389. [PMID 21959369]
13. Mourits MP, Prummel MF, Wiersinga WM, Koornneef L. Clinical activity score as a guide in the management of patients with Graves' ophthalmopathy. *Clin Endocrinol (Oxf)* 1997;47(1):9-14. [PMID 9302365]
14. Gerding MN, van der Meer JW, Broenink M, Bakker O, Wiersinga WM, Prummel MF. Association of thyrotrophin receptor antibodies with the clinical features of Graves' ophthalmopathy. *Clin Endocrinol (Oxf)* 2000;52(3):267-271. [PMID 10718823]
15. Bartalena L, Baldeschi L, Dickinson A, Eckstein A, Kendall-Taylor P, Marcocci C, Mourits M, Perros P, Boboridis K, Boschi A, Curro N, Daumerie C, Kahaly GJ, Krassas GE, Lane CM, Lazarus JH, Marino M, Nardi M, Neoh C, Orgiazzi J, Pearce S, Pinchera A, Pitz S, Salvi M, Sivelli P, Stahl M, von Arx G, Wiersinga WM, European Group on Graves O. Consensus statement of the European Group on Graves' orbitopathy (EUGOGO) on management of GO. *Eur J Endocrinol* 2008;158(3):273-285. [PMID 18299459]
16. Stan MN, Garrity JA, Bahn RS. The evaluation and treatment of graves ophthalmopathy. *Med Clin North Am* 2012;96(2):311-328. [PMID 22443978]
17. Cawood T, Moriarty P, O'Shea D. Recent developments in thyroid eye disease. *BMJ* 2004;329(7462):385-390. [PMID 15310608]
18. Marcocci C, Kahaly GJ, Krassas GE, Bartalena L, Prummel M, Stahl M, Altea MA, Nardi M, Pitz S, Boboridis K, Sivelli P, von Arx G, Mourits MP, Baldeschi L, Bencivelli W, Wiersinga W, European Group on Graves O. Selenium and the course of mild Graves' orbitopathy. *N Engl J Med* 2011;364(20):1920-1931. [PMID 21591944]
19. Bartalena L, Pinchera A, Marcocci C. Management of Graves' ophthalmopathy: reality and perspectives. *Endocr Rev* 2000;21(2):168-199. [PMID 10782363]
20. Prummel MF, et al. Amelioration of eye changes of Graves' ophthalmopathy by achieving euthyroidism. *Acta Endocrinology (Copenhagen)* 1989;121 (suppl 2):185-189
21. Kronenberg HM, Melmed S, Polonsky KS, Larsen PR, editors. *Williams Textbook of Endocrinology*. 11th ed. Philadelphia: Elsevier/Saunders, 2008.
22. Bahn RS, Burch HB, Cooper DS, Garber JR, Greenlee MC, Klein I, Laurberg P, McDougall IR, Montori VM, Rivkees SA, Ross DS, Sosa JA, Stan MN, American Thyroid Association, American Association of Clinical Endocrinologists. Hyperthyroidism and other causes of thyrotoxicosis: management guidelines of the American Thyroid Association and American Association of Clinical Endocrinologists. *Thyroid* 2011;21(6):593-646. [PMID 21510801]
23. Stan MN, Durski JM, Brito JP, Bhagra S, Thapa P, Bahn RS. Cohort study on radioactive iodine-induced hypothyroidism: implications for Graves' ophthalmopathy and optimal timing for thyroid hormone assessment. *Thyroid* 2013;23(5):620-625. [PMID 23205939]
24. Eckstein A, Quadbeck B, Mueller G, Rettenmeier AW, Hoermann R, Mann K, Steuhl P, Esser J. Impact of smoking on the response to treatment of thyroid associated ophthalmopathy. *Br J Ophthalmol* 2003;87(6):773-776. [PMID 12770979]
25. Vannucchi G, Covelli D, Campi I, Origo D, Curro N, Cirello V, Dazzi D, Beck-Peccoz P, Salvi M. The therapeutic outcome to intravenous steroid therapy for active Graves' orbitopathy is influenced by the time of response but not polymorphisms of the glucocorticoid receptor. *Eur J Endocrinol* 2014;170(1):55-61. [PMID 24128430]
26. Rajendram R, Bunce C, Lee RW, Morley AM. Orbital radiotherapy for adult thyroid eye disease. *Cochrane Database Syst Rev* 2012;10.1002/14651858.CD007114. pub2(7):CD007114. [PMID 22786503]
27. Shams PN, Ma R, Pickles T, Rootman J, Dolman PJ. Reduced risk of compressive optic neuropathy using orbital radiotherapy in patients with active thyroid eye disease. *Am J Ophthalmol* 2014;157(6):1299-1305. [PMID 24582992]
28. Kazim M. Perspective--Part II: radiotherapy for Graves Orbitopathy: the Columbia University experience.

- Ophthal Plast Reconstr Surg 2002;18(3):173-174. [PMID 12021645]
29. Wakelkamp IM, Tan H, Saeed P, Schlingemann RO, Verbraak FD, Blank LE, Prummel MF, Wiersinga WM. Orbital irradiation for Graves' ophthalmopathy: Is it safe? A long-term follow-up study. *Ophthalmology* 2004;111(8):1557-1562. [PMID 15288988]
 30. Stan MN, Garrity JA, Carranza Leon BG, Prabin T, Bradley EA, Bahn RS. Randomized controlled trial of rituximab in patients with Graves' orbitopathy. *J Clin Endocrinol Metab* 2015;100(2):432-441. [PMID 25343233]
 31. Rajendram R, Lee RW, Potts MJ, Rose GE, Jain R, Olver JM, Bremner F, Hurel S, Cook A, Gattamaneni R, Tomlinson M, Plowman N, Bunce C, Hollinghurst SP, Kingston L, Jackson S, Dick AD, Rumsey N, Morris OC, Dayan CM, Uddin JM. Protocol for the combined immunosuppression & radiotherapy in thyroid eye disease (CIRTED) trial: a multi-centre, double-masked, factorial randomised controlled trial. *Trials* 2008;9:6. [PMID 18237441]
 32. Silkiss RZ, Reier A, Coleman M, Lauer SA. Rituximab for thyroid eye disease. *Ophthal Plast Reconstr Surg* 2010;26(5):310-314. [PMID 20562667]
 33. Wakelkamp IM, Baldeschi L, Saeed P, Mourits MP, Prummel MF, Wiersinga WM. Surgical or medical decompression as a first-line treatment of optic neuropathy in Graves' ophthalmopathy? A randomized controlled trial. *Clin Endocrinol (Oxf)* 2005;63(3):323-328. [PMID 16117821]
 34. Prummel MF, Mourits MP, Blank L, Berghout A, Koornneef L, Wiersinga WM. Randomized double-blind trial of prednisone versus radiotherapy in Graves' ophthalmopathy. *Lancet* 1993;342(8877):949-954. [PMID 8105213]
 35. Fayers T, Barker LE, Verity DH, Rose GE. Oscillopsia after lateral wall orbital decompression. *Ophthalmology* 2013;120(9):1920-1923. [PMID 23618229]
 36. Trokel S, Kazim M, Moore S. Orbital fat removal. Decompression for Graves orbitopathy. *Ophthalmology* 1993;100(5):674-682. [PMID 8493010]
 37. Tse DT. A simple maneuver to reposit a subluxed globe. *Arch Ophthalmol* 2000;118(3):410-411. [PMID 10721966]
 38. Chang EL, Bernardino CR, Rubin PA. Normalization of upper eyelid height and contour after bony decompression in thyroid-related ophthalmopathy: a digital image analysis. *Arch Ophthalmol* 2004;122(12):1882-1885. [PMID 15596598]
 39. Thomas SM, Cruz OA. Comparison of two different surgical techniques for the treatment of strabismus in dysthyroid ophthalmopathy. *J AAPOS* 2007;11(3):258-261. [PMID 17572340]
 40. Nerad JA. *Oculoplastic Surgery: The Requisites in Ophthalmology*. St. Louis, MO: Mosby, 2001.
 41. Morgenstern KE, Evanchan J, Foster JA, Cahill KV, Burns JA, Holck DE, Perry JD, Wulc AE. Botulinum toxin type a for dysthyroid upper eyelid retraction. *Ophthal Plast Reconstr Surg* 2004;20(3):181-185. [PMID 15167723]

Citing this article

Liaboe CA, Clark TJ, Shriver EM, Carter KD. Thyroid Eye Disease: An Introductory Tutorial and Overview of Disease. EyeRounds.org. posted November 18, 2016; Available from: EyeRounds.org/tutorials/thyroid-eye-disease/

Nov 18, 2016

Nasolacrimal Stents: An Introductory Guide

Aaron M. Ricca, MD; Allison K. Kim, BS; Harinderpal S. Chahal, MD; Erin M. Shriver, MD, FACS

posted January 29, 2018

See related videos at EyeRounds.org/video/plastics/index.htm#lacrimal

Introduction

Nasolacrimal stents are small diameter tubes placed within the nasolacrimal system to maintain patency. The first described stent was made of silver wire and used by Graue in 1932.[1] Since that time, various materials have been used, including silk, nylon, polyethylene, and polypropylene.[2] Today, the tubes are typically composed of silicone, or another similar semi-rigid yet flexible material with an open central lumen. Intubation of the nasolacrimal system is generally done temporarily, with stents remaining in place for several months. In rare instances, however, intubation may be long term.[3] Nasolacrimal tubes are used primarily in cases of obstruction or laceration of one or more parts of the tear drainage system.[4]

The differential diagnosis of nasolacrimal obstruction is broad and includes trauma, infection, malignancy, thermal injury, chemotherapy, radiation, and iatrogenic causes.[3] Regardless of the specific etiology, patients with nasolacrimal obstruction typically present with epiphora, an

overflow of tears onto the cheek due to improper drainage through the nasolacrimal system.

Anatomy of the Nasolacrimal System

Normal tear drainage occurs with an intact nasolacrimal drainage system and a functioning lacrimal pump (Figure 1). Tears exit the ocular surface via the upper and lower puncta. They then enter the superior and inferior canaliculi, which coalesce to form a common canaliculus in 90% of people.[3] At the junction of the common canaliculus and the lacrimal sac is the valve of Rosenmueller, a small fold of mucous membrane. The sac narrows inferiorly, becoming the nasolacrimal duct, which opens beneath the inferior turbinate and into the inferior meatus of the nose. The valve of Hasner, located at the distal end of the nasolacrimal duct, prevents retrograde reflux of air, mucous, and food particles from the nose into the eye.

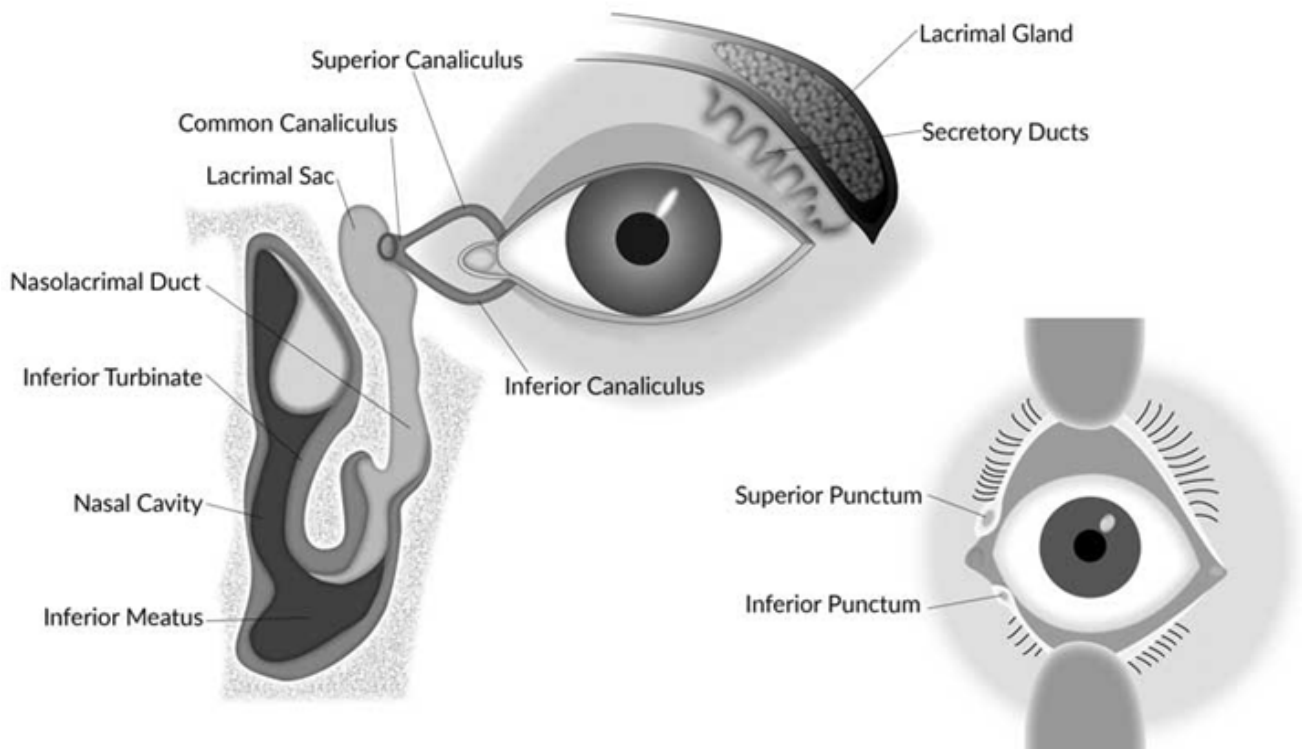


Figure 1. The nasolacrimal drainage system. Vaughan & Asbury's General Ophthalmology, 18ed. Chapter 1. "Anatomy & Embryology of the Eye" - Modified figure used with permission

Obstruction along any of the following sections of the nasolacrimal drainage system may be an indication for intubation:

1. Punctum (superior or inferior)
2. Proximal canaliculus (partial obstruction of the superior canaliculus, inferior canaliculus, or both)
3. Common canaliculus
4. Lacrimal sac
5. Nasolacrimal duct

Blockage of flow anywhere in the system can be idiopathic or secondary to numerous causes including infectious, malignant, traumatic, autoimmune or other inflammatory disorders. One of the most common indications for intubation is post-surgical, such as in a dacryocystorhinostomy to maintain a patent osteotomy.[5,6] This procedure was first described by Lester Jones in 1962 and has since had numerous advancements in techniques and materials.[7,8]

Types of Stents

Canalicular stents can be organized based on the different parts of the nasolacrimal drainage system they intubate. The two main divisions of stents are bicanalicular versus monocalicular. Bicanalicular stents pass through both the upper and lower canaliculus and typically create a closed circuit.[9] They can intubate the upper and lower canaliculi connecting via the common canaliculus or the lacrimal sac (Figure 2a). They can also intubate the entire nasolacrimal drainage system, including the lacrimal sac and nasolacrimal duct with the circuit being open or

closed in the nose (Figure 2b). Monocalicular stents do not provide a closed loop system, only intubating either the upper or lower canaliculus[4] (Figure 2c). A surgical procedure can create a new passageway for stents to be placed into the nose (Figure 2d) or completely bypass the entire canalicular system (Figure 2e). Several examples of both bicanalicular and monocalicular stents are presented below. This list is by no means meant to be exhaustive, as there are numerous types of both bicanalicular and monocalicular stents currently available on the market. Instead, this is merely representative of the major categories of stents currently utilized at the time of publication.

1. Bicanalicular Stents

Stenting of upper and lower canaliculi

Crawford stent. Involves the entire nasolacrimal drainage system (Figure 2a)

The Crawford stent is a bicanalicular stent attached to metal probes with bulbs on the distal ends of the probes. The probes and attached stents are passed through the superior and inferior canaliculi and retrieved in the nose via a retrieval hook or groove director that engage the bulbous tip of the probe (Figure 3b). The stents can be a full silicone rod or silicone tubing with an inner silk suture. The probes are subsequently cut and the stents are tied in the nose. When the stent contains a silk suture, the stent is stripped from the suture at the ends, and the silk is tied creating a loop of stent. This suture is barely visible once the stent is in place as the suture is white. To reduce risk of stent prolapse, some surgeons decrease the length of

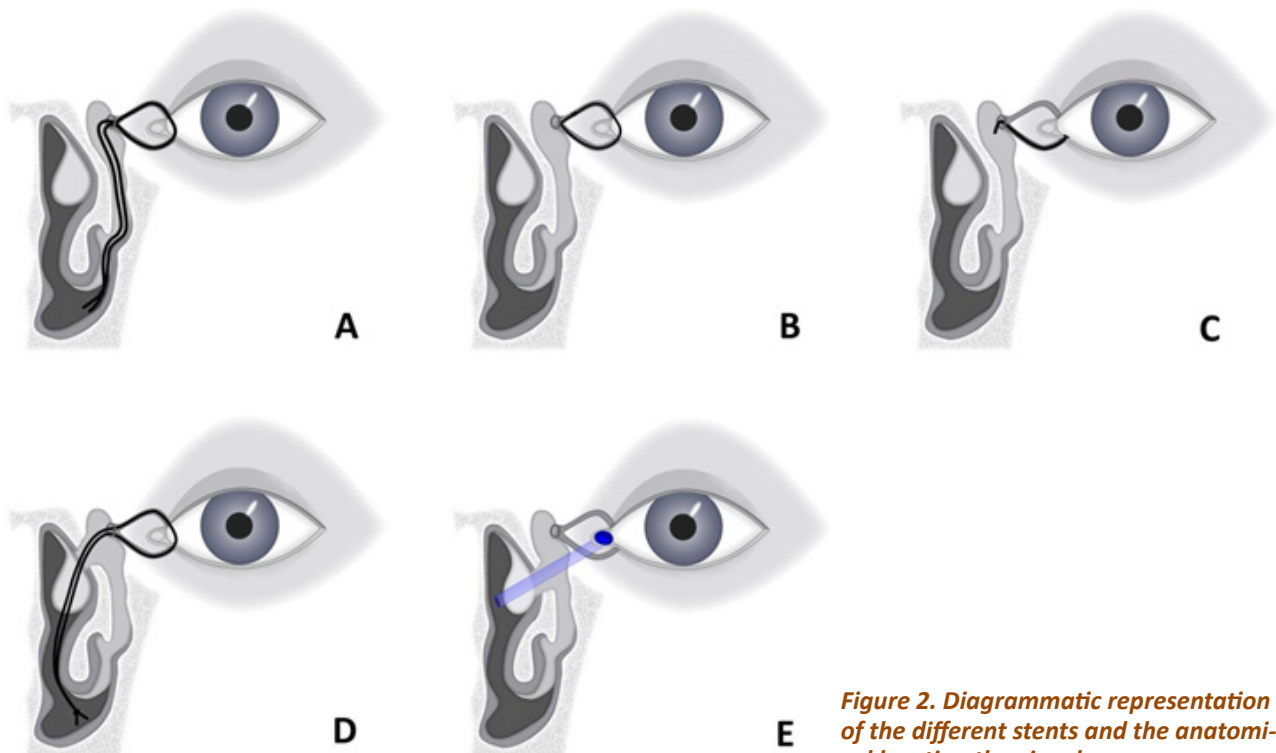


Figure 2. Diagrammatic representation of the different stents and the anatomical location they involve

the stent loop with a ligating suture around the loop within the nose. The stent is either left free-floating in the nasal cavity or fixated with a suture to the mucosa of the lateral nasal wall. The small silicone stent passing between the upper and lower puncta is visualized in Figure 3a below. This was placed after a dacryocystorhinostomy (DCR) from an external approach, as is evident by the incision. In this procedure, a surgical opening is created between the lacrimal sac and the nasopharynx allowing for passage of the stent (Figure 2d).

Ritleng Stent. Involves the entire canalicular system (Figure 2a)

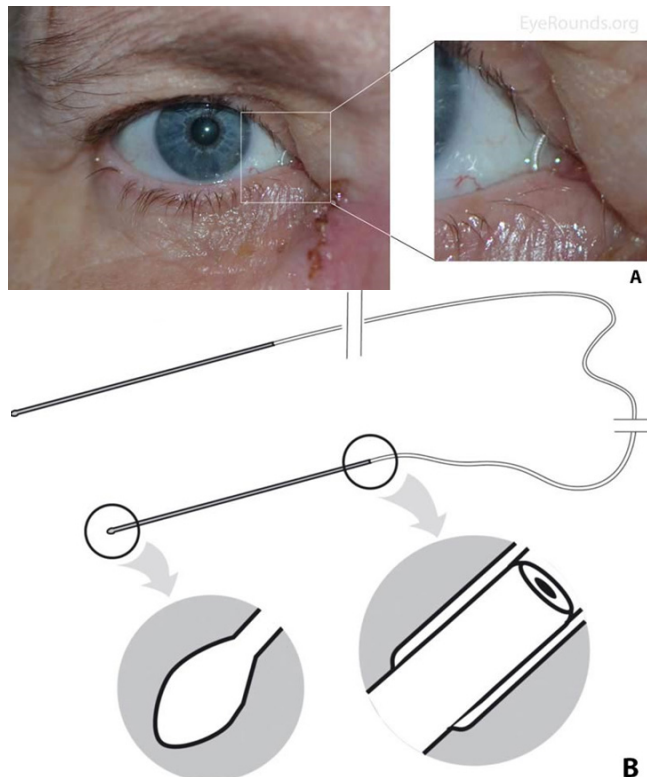


Figure 3. (A) Silicone tubing of the Crawford stent connecting the upper and lower puncta and a healing incision from DCR. (B) Diagram of Crawford stent attached to metal probe, compliments of FCI Ophthalmics

Designed by Dr. P. Ritleng, this system utilizes an introducer with a hollow lumen and stylette. The introducer, loaded with the stylette for rigidity, is used to enter the nasolacrimal system. Once inside, the stylette is removed and one end of a bicanalicular stent is advanced through the hollow lumen of the tube.[1] The procedure is repeated via the opposite punctum, and the stents are tied in the nose. The Ritleng stent is the bicanalicular stent of choice for some surgeons because the design minimizes manipulation inside the nose.

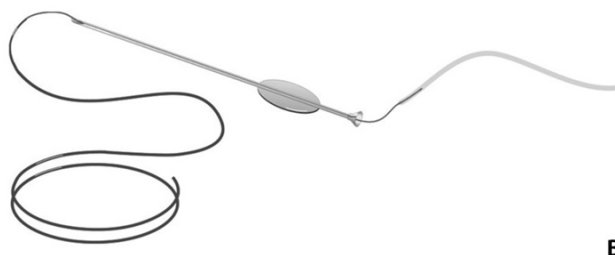
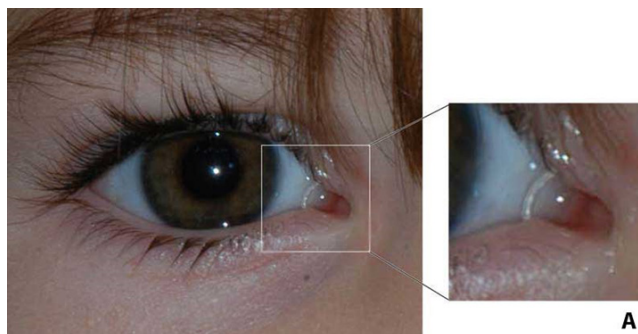


Figure 4. (A) Silicone tubing of the Ritleng stent connecting the upper and lower puncta. (B) Diagram of stent with stylette, compliments of FCI Ophthalmics

Pigtail/Donut stent. Involves the upper, lower, and common canaliculi (Figure 2b)

This stent is used for bicanalicular intubation. It is commonly used in traumatic canalicular laceration repairs where the patency of the nasolacrimal duct remains intact. One end of the pigtail-shaped probe is designed for insertion through the upper canalicular system, while the opposite end is designed for insertion through the lower canalicular system. The probe is passed through one puncta and rotated, following the natural curvature of can-



Figure 5. Pigtail probe used to pass the guide-wire suture through the canalicular system. Image compliments of Indiamart (www.indiamart.com/proddetail/lacrimal-pigtail-probe-14549996330.html)

alicular system, then retrieved via the opposite punctum. A small islet at the tip of the probe facilitates passage of a guide-wire suture (we prefer a 6-0 nylon suture) through the canalicular system. A piece of hollow silicone tubing, cut to approximately 25 mm in adults, is then passed over the guide wire to successfully intubate the canalicular system. The suture is then cut and tied and the stent rotated to bury the knot. When viewing only the stent between

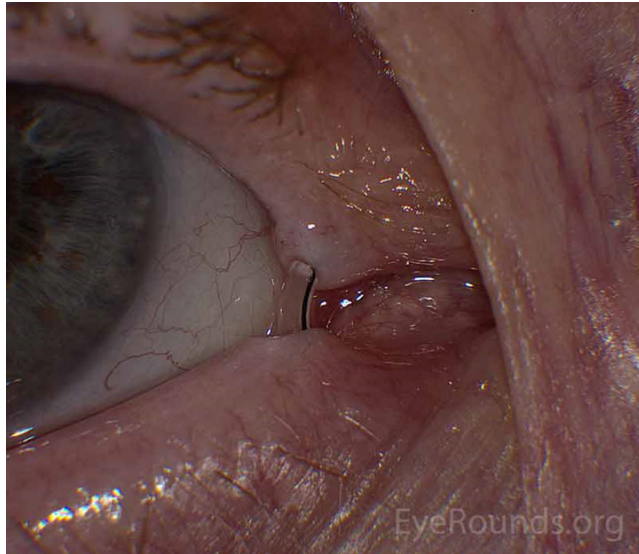


Figure 6. Pigtail stent with a black nylon suture visible within the stent lumen

the puncta, one can distinguish between a Crawford and a pigtail stent by the presence or absence of a black nylon or blue prolene suture within the stent lumen vs no suture or a white silk suture in the Crawford stent (Figure 6).

Kaneka Lacriflow stent. Involves the entire nasolacrimal system (Figure 2a)

The Kaneka Lacriflow stent is a new system that was approved for bicanalicular intubation by the FDA in 2012. [10] The stent is made of a central thin intra-canalicular portion with larger diameter tubing at either end that intubates the lacrimal sac and duct. The ends are attached to stainless steel bougies allowing for insertion (Figure 7). Once placed, the ends of the stent reside under the inferior turbinate without suture fixation. The benefit is that the stent is self-retaining with minimal intranasal manipulation allowing for placement under local anesthetic.

2. Monocanalicular Stents

Stenting of upper or lower canaliculi

Monoka Stent. Involves a single canaliculus (Figure 2c)

The Monoka silicone stent is anchored at the punctum by a plug/cap on one end. No suturing is necessary to keep it in place, although some surgeons prefer to secure the stent to the eyelid with a suture through the lip of the stent. This type of stent is used to treat nasolacrimal duct obstructions, canalicular stenosis, and it can be used for canalicular lacerations.[1]

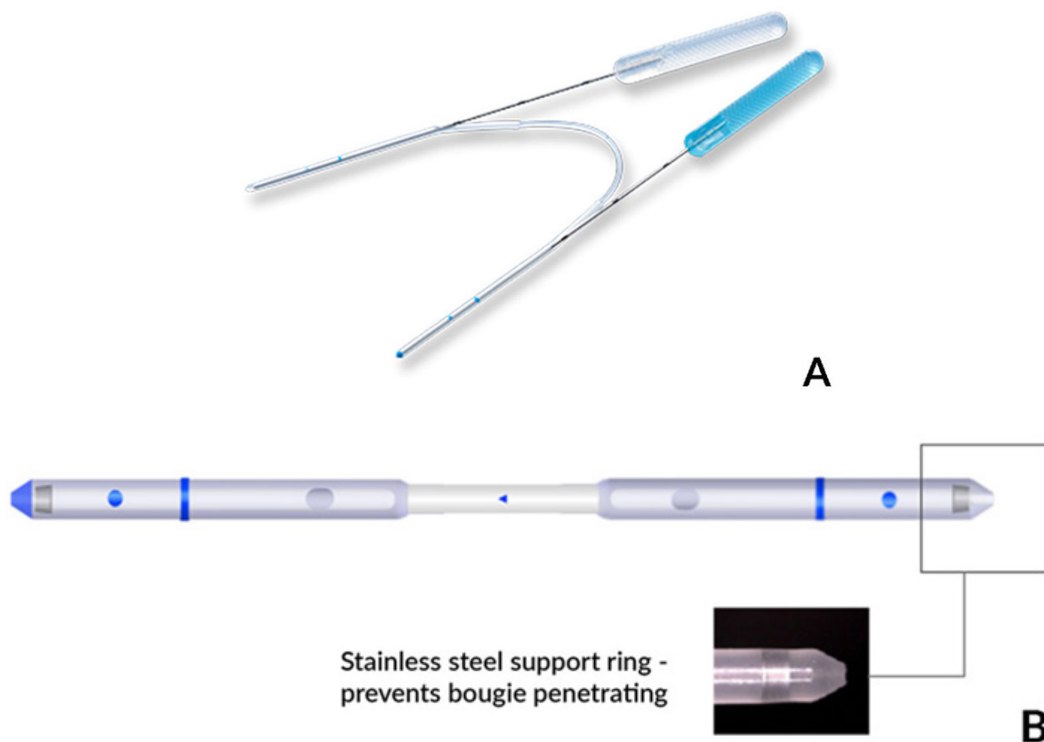


Figure 7. (A) Kaneka Lacriflow stent with attached bougies, (B) Schematic of the stent demonstrating variable diameter and openings in the system [10], images compliments of Kaneka Pharma America, Kaneka-eye.com

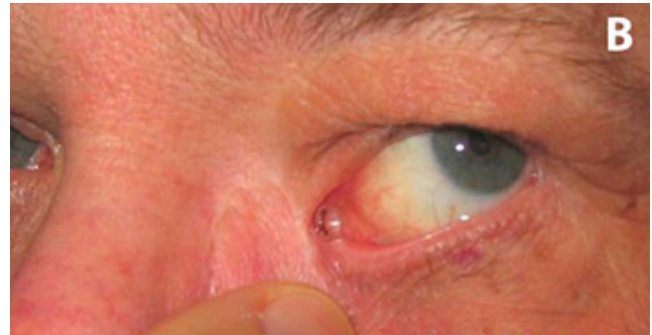
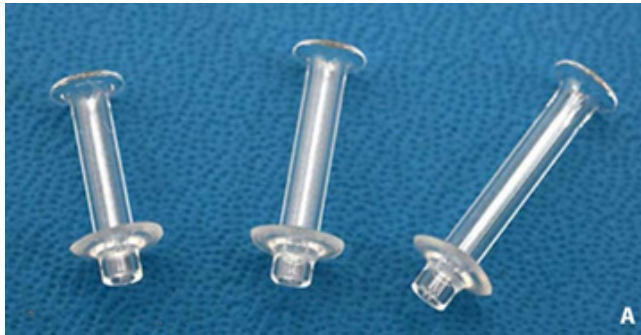
Figure 9. (A) Several different sizes of StopLoss Jones tubes. Image compliments of Lester Jones Tubes, www.lesterjonestube.com (B) Jones tube in place

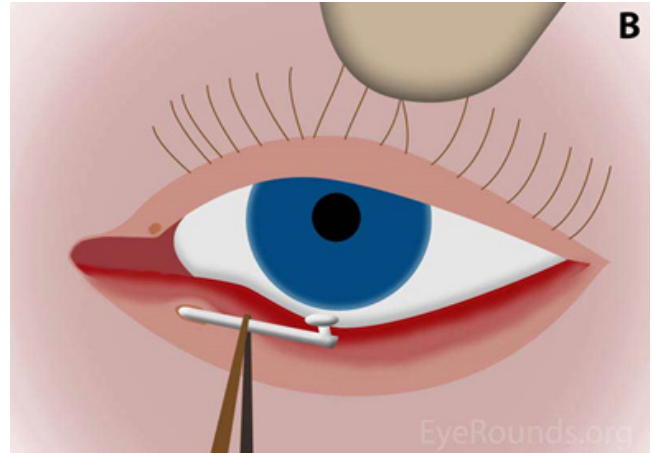
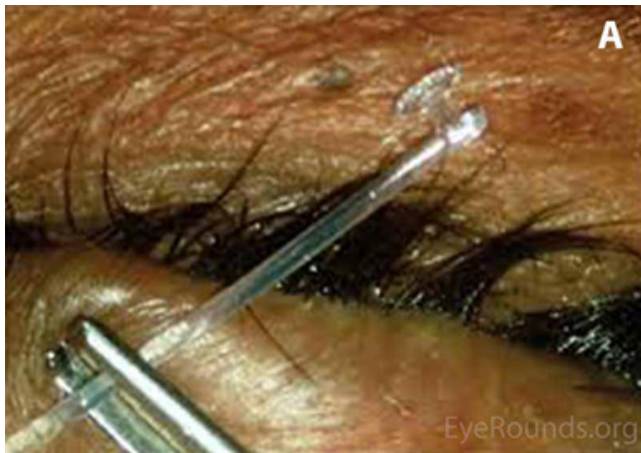

Figure 8. (A) Mini Monoka stent over a patient's eyelids prior to insertion[1]. (B) Diagram demonstrating insertion of the stent into the inferior punctum.

The mini Monoka stent is a smaller version and is used to treat lacerations or obstructions that occur in the canaliculus. Like the full-size version, it is anchored at the punctum of the eye by a plug on the end of the stent.[1]

Jones Tube. Does not involve the canaliculi

The Jones tube is a Pyrex glass tube that is used to bypass an obstruction of the canalicular system in order to drain tears from the eye. It is placed from the conjunctival cul-de-sac through a surgically created bony ostium, and exits into the nose (Figure 2e).[6] It can be secured into place with sutures on the conjunctival end of the tube (Figure 9b). Some Jones tubes have a flexible silicone internal flange to resist extrusion.[11]

Stent removal

The techniques for stent removal are individualized depending on the type of stent utilized. Crawford stents can be removed from either an endonasal approach or from the punctum. The endonasal approach is preferred to minimize risk of the stent breaking on removal. For the endonasal approach, the patient is asked to blow his or her nose with the head down. Once the nasal passages are cleared, the location of the stent is found within the nose,

and the knot is held in place while the stent is then cut at the exposed portion between the puncta. The knot is then pulled out the nose and the cut ends of the stent freely follow, exiting the canalicular system. The approach for removing the stent from the punctum is typically used when the stent is not visualized in the nose and the stent loop is free and able to be rotated. A drop of proparacaine is placed in the ipsilateral eye. A muscle hook, finger, or needle driver is used to grasp and prolapse the stent. The stent is then rotated until the knot is visualized with fingers, forceps, or needle drivers. Once the knot is visualized, the stent is removed taking care to hold onto the knot portion of the stent so that the part of the stent without the knot is pulled through the canaliculi.

Ritleng stents are removed in a similar fashion to Crawford stents. Pigtail stents are rotated so that the knot is externalized out a punctum, the suture is cut at the knot, and the stent and suture are pulled free. The Kaneka Lacriflow stent is removed by simply pulling on the exposed stent between the puncta. Monoka stents are removed by cutting any sutures that hold the stent in place and then pulling the stent out of the punctum with forceps. Jones tubes are removed by cutting the suture that is wrapped around the tube (if one is present) and then pulling out the tube with forceps.

Complications

While rare, placement of nasolacrimal stents can result in the following complications:

1. **Prolapse of the stent:** In some cases, the stent may prolapse from its position in the medial canthus resulting in a bothersome loop of stent material protruding from the puncta. In some cases the stent can be repositioned, though stent removal may be required. A temporary fix for this complication is to tape the prolapsed loop of stent to the side of the nose.
2. **Damage to the puncta:** Excess tension from stents may result in distortion or damage to the puncta.
3. **Granuloma formation**
4. **Trauma to the canalicular system with creation of a false passage:** This may be caused by probing of the canalicular system prior to stent placement or by the metal portion of the stent on insertion.
5. **Infection of the nasolacrimal drainage system:** Infection has been recently linked to biofilm production from organisms such as nontuberculous mycobacteria. [12]

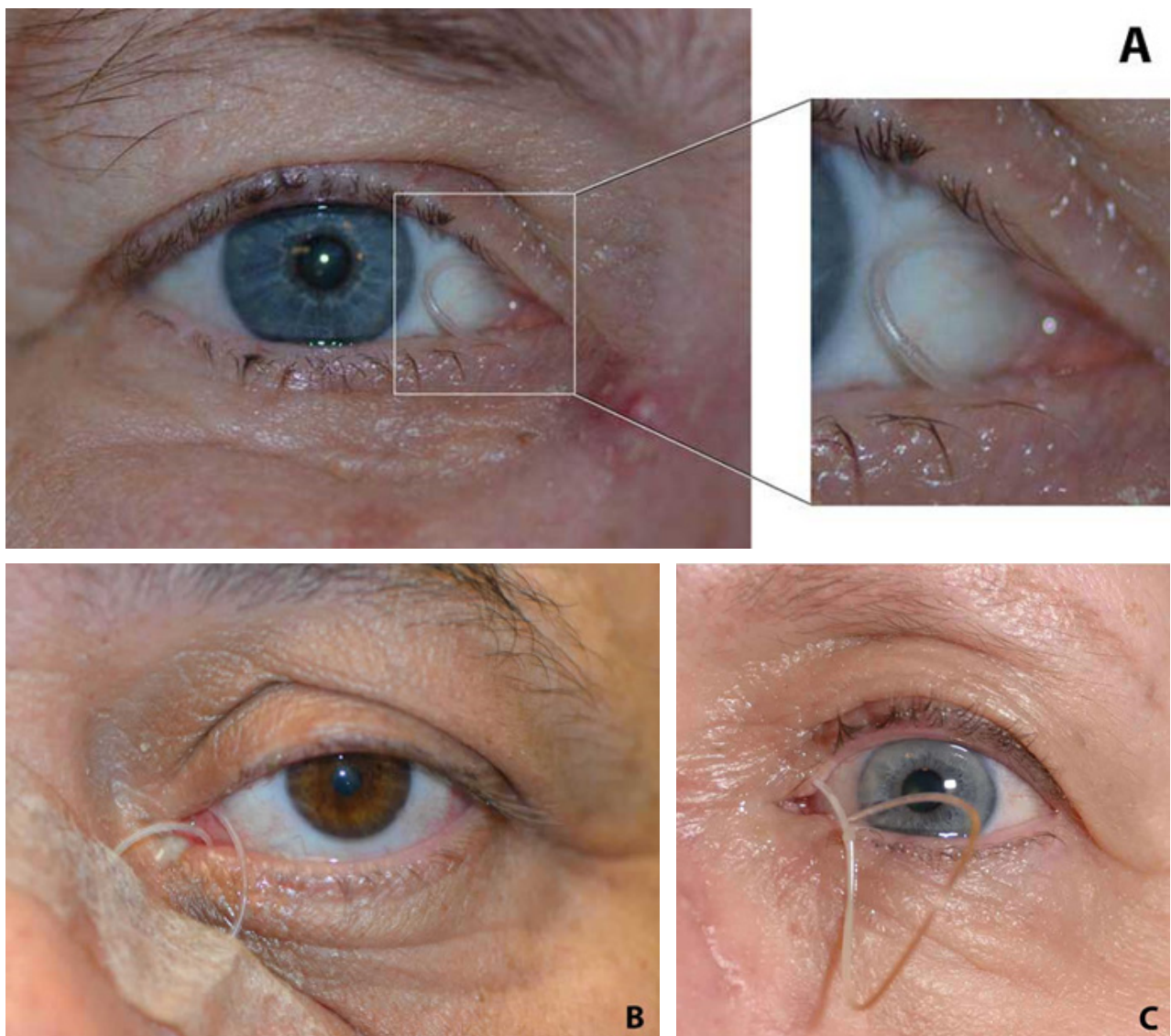


Figure 10. Various amounts of Crawford stent prolapse, (A) mild, (B) moderate, and (C) severe.

References

1. Singh M. Lacrimal Stents and Intubation Systems: An Insight. *Delhi Journal of Ophthalmology* 2015;26(1):14-19.
2. Henderson JW. Management of strictures of the lacrimal canaliculi with polyethylene tubes. *Arch Ophthalmol* 1950;44(2):198-203. [PubMed.gov/15433670](http://pubmed.gov/15433670)
3. Nerad JA. *Oculoplastic surgery (the requisites in ophthalmology)*. St. Louis: Mosby, 2001.
4. Zadeng Z, Singh M, Singh U. Role of Lacrimal Canalicular Trephination and Mini-Monoka Stent in the Management of Idiopathic Distal Canalicular Obstructions: Our Experience of 23 Cases. *Asia Pac J Ophthalmol (Phila)* 2014;3(1):27-31. [PubMed.gov/26107304](http://pubmed.gov/26107304)
5. Doucet TW, Hurwitz JJ. Canaliculodacryocystorhinostomy in the treatment of canalicular obstruction. *Arch Ophthalmol* 1982;100(2):306-309. [PubMed.gov/7065950](http://pubmed.gov/7065950)
6. Devoto MH, Bernardini FP, de Conciliis C. Minimally invasive conjunctivodacryocystorhinostomy with Jones tube. *Ophthalm Plast Reconstr Surg* 2006;22(4):253-255. [PubMed.gov/16855494](http://pubmed.gov/16855494)
7. Athanasiov PA, Madge S, Kakizaki H, Selva D. A review of bypass tubes for proximal lacrimal drainage obstruction. *Surv Ophthalmol* 2011;56(3):252-266. [PubMed.gov/21501738](http://pubmed.gov/21501738)
8. Jones LT. The cure of epiphora due to canalicular disorders, trauma and surgical failures on the lacrimal passages. *Trans Am Acad Ophthalmol Otolaryngol* 1962;66:506-524. [PubMed.gov/14452301](http://pubmed.gov/14452301)
9. Liarakos VS, Boboridis KG, Mavrikakis E, Mavrikakis I. Management of canalicular obstructions. *Curr Opin Ophthalmol* 2009;20(5):395-400. [PubMed.gov/19587600](http://pubmed.gov/19587600)
10. Silbert DI. Success rate of placement of a bicanalicular stent for partial nasolacrimal obstruction in adults under local, monitored anesthesia care and general anesthesia. *Saudi J Ophthalmol* 2017;31(3):140-144. pubmed.gov/28860910
11. Jones tubes - what are they, how do they work and what's the right tube for you? . [Online publication]: Lester Jones Tubes, 2013. [Last rev. on 10/28/2017; accessed, www.lesterjonestube.com/].
12. Samimi DB, Ediriwickrema LS, Bielory BP, Miller D, Lee W, Johnson TE. Microbiology and Biofilm Trends of Silicone Lacrimal Implants: Comparing Infected Versus Routinely Removed Stents. *Ophthalm Plast Reconstr Surg* 2016;32(6):452-457. [PubMed.gov/26588208](http://pubmed.gov/26588208)

Citing this article

Ricca AM, Kim AK, Chahal HS, Shriver EM. Nasolacrimal Stents: An Introductory Guide. *EyeRounds.org*. posted January 29, 2018; Available from: EyeRounds.org/tutorials/Stents/

last updated: 1/29/2018

Retrobulbar Block, Peribulbar Block, and Common Nerve Blocks Used by Ophthalmologists

Sudeep Pramanik, MD MBA, MD and Andrew Doan, MD, PhD

Illustrations by Sudeep Pramanik, MD

Edited and updated by Thomas A Oetting, MD, and Thomas A Weingeist, MD, PhD

February 27, 2005

ADMINISTERING LOCAL NERVE BLOCKS

The most common local anesthetic mixture is 2% lidocaine with 1:100,000 epinephrine to provide some hemoestasis. Addition of 0.5% bupivacaine will provide longer anesthesia (~6-8 hours) for lengthy procedures. The following diagrams illustrate common local nerve blocks used in ophthalmology.

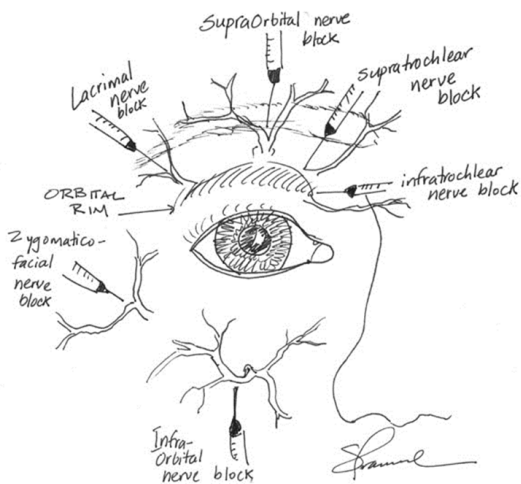


Diagram 1: Common Periorbital Nerve Blocks

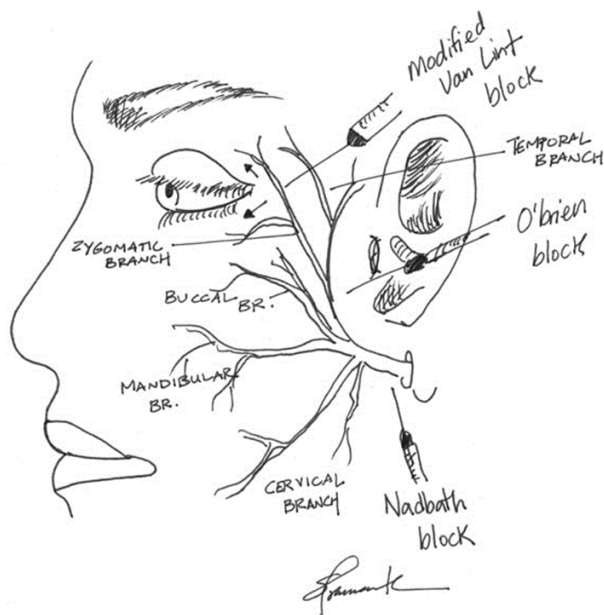


Diagram 2: Common Facial Nerve Blocks

ADMINISTERING THE RETROBULBAR BLOCK

Retrobulbar blocks are useful methods of achieving anesthesia for intraocular and orbital surgeries. Blocks are good alternatives to general anesthesia when general anesthesia is undesirable or contraindicated.

There are many techniques to administer a retrobulbar block. The method described here is what I prefer. Depending on the type of anesthetic, a block may last over four hours with a mixture of lidocaine 1% and bupivacaine 0.375%. Addition of hyaluronidase to the anesthetic mix improves penetration of anesthesia [1]. Clean the lower lid with an alcohol wipe.

- ◆ Have the patient look straight ahead.
- ◆ Use a 5 cc syringe and a 23 gauge, 1.5 inch flat grind needle.
- ◆ Start 2/3 lateral along the inferior orbital rim (inferior to the temporal limbus) with the needle tip pointing perpendicular to the plane of the patient's face. Place the index finger between the globe and the infraorbital rim, elevating the globe.
- ◆ Stabilize with the little finger and hypothenar eminence firmly on the bones of the patient's cheek.
- ◆ Enter just inferior to the globe and perpendicular to the plane of the face.

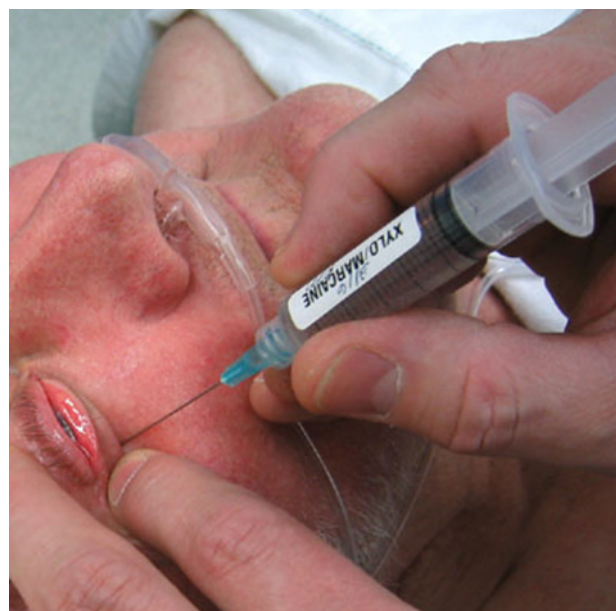

Figure 1: Retrobulbar Block - Step 1

- ◆ Once you feel the first pop through the orbital septum, angle 45 degrees medially and 45 degrees superiorly towards the apex of the orbit until the second pop through the muscle cone is felt.
- ◆ *Culver Boldt, MD (vitreoretinal surgeon) moves the needle gently side to side while advancing beneath the globe. If the needle begins to engage the globe, then the eye will start to move side to side. Hopefully, one can stop advancing before globe perforation occurs. This move is controversial, because some feel it leads to a higher rate of orbital hemorrhage.*
- ◆ *John Sutphin, MD (corneal specialist) suggests watching for globe movement. The globe should rotate downward when you engage the septum. As you go through, it should rotate back up. Failure to do so could suggest the needle is in the sclera.*

VIDEO: Retrobulbar Block vimeo.com/139277507 **Narration by Thomas Oetting, MD**

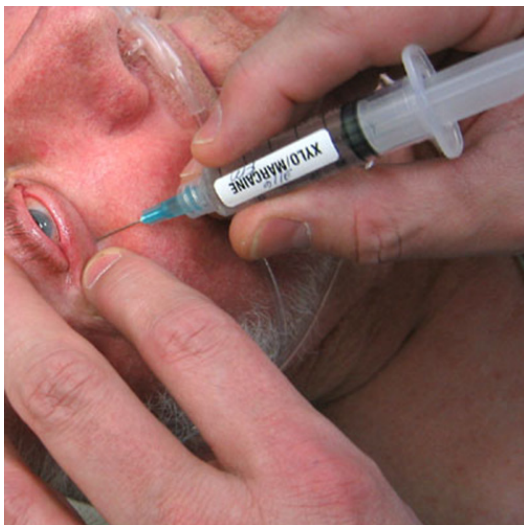

Figure 2: Retrobulbar Block - Step 2

- ◆ Pull back on the syringe to ensure the needle is not in a vessel, then inject 3-5 cc of anesthetic, palpating the globe to assess for posterior pressure.

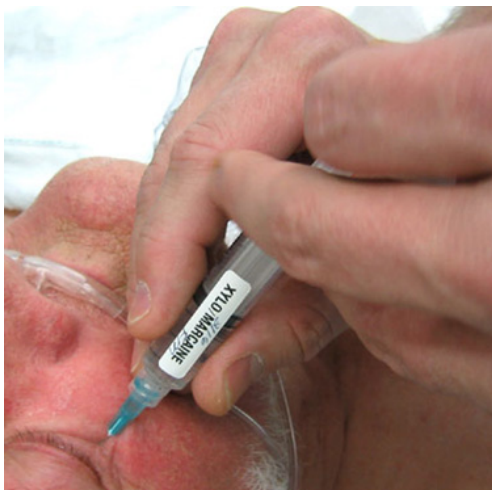

Figure 3: Retrobulbar Block - Injection

- ◆ After withdrawing the needle, apply firm pressure to the globe with a 4x4 gauze (enough to occlude the central retinal artery) to tamponade any possible retrobulbar hemorrhage. Provide firm pressure for 90-120 seconds. Some suggest alternating 10-15 seconds of firm pressure with release of the pressure to allow perfusion of the central retinal artery. Studies by Sohan Singh Hayreh, MD, PhD (vascular) demonstrate that the retina is able to tolerate up to 90 minutes of non-perfusion before permanent damage.

ADMINISTERING THE SUB-TENONS PERIBULBAR BLOCK

Video vimeo.com/139277507 : **Surgery & Narration by Thomas Oetting, MD**

- ◆ A peribulbar block is an alternative to the retrobulbar block and offers an effective way to provide anesthesia before ocular surgery [2].
- ◆ A small button hole is made in the conjunctivae and tenons using Westcott scissors and 0.12 forceps (Figure 4).

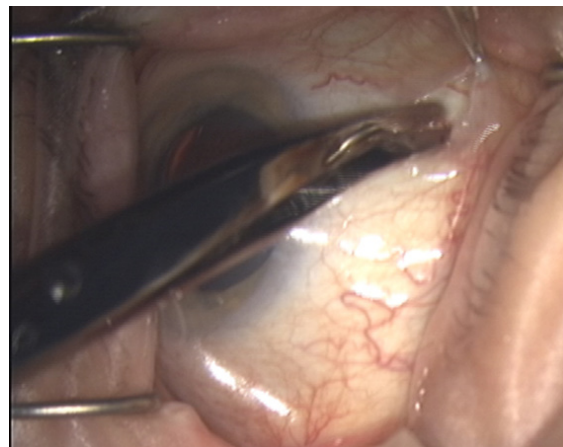


Figure 4: Button hole formed ~10 mm from the corneal limbus.

- ◆ The quadrant is freed using blunt dissection with Westcott scissors (Figure 5).

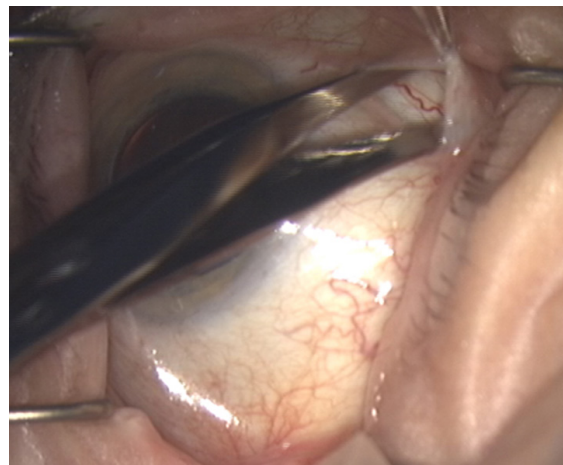


Figure 5: Freeing the Quadrant

- ◆ 1% lidocaine/0.375% bupivacaine is drawn up in a syringe attached to a blunt lacrimal cannula (Figure 6) and then inserted posteriorly under the sub-tenons space (Figure 7).

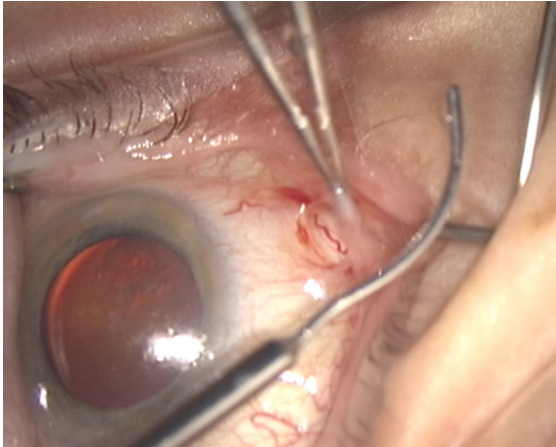


Figure 6: Lacrimal cannula

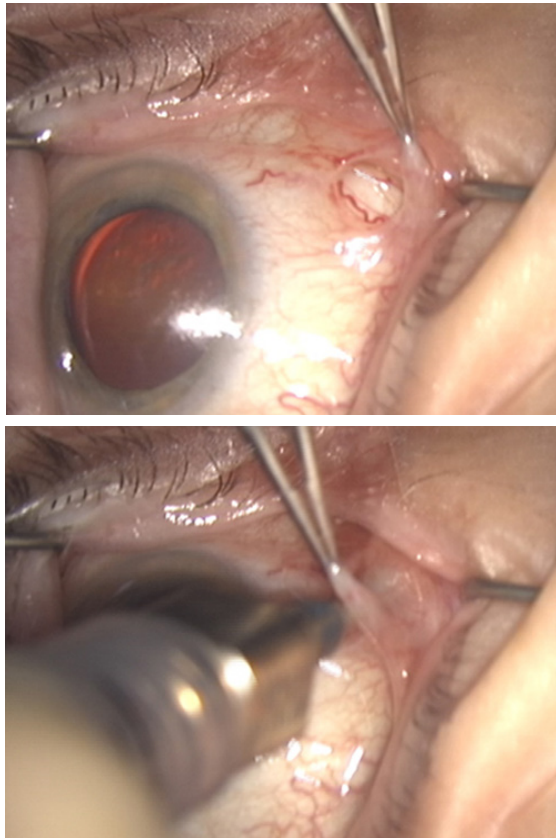


Figure 7: Insertion of cannula(top) and injection of anesthetic(bottom).

References

1. Kallio H, Paloheimo M, Maunuksela EL. Hyaluronidase as an adjuvant in bupivacaine-lidocaine mixture for retrobulbar/peribulbar block. *Anesth Analg* 2000;91(4):934-937. [PubMed.gov/11004052](http://pubmed.gov/11004052)
2. Roman SJ, Chong Sit DA, Boureau CM, Auclin FX, Ullern MM. Sub-Tenon's anaesthesia: an efficient and safe technique. *Br J Ophthalmol* 1997;81(8):673-676. [PubMed.gov/9349156](http://pubmed.gov/9349156)

Suggested citation format

Pramanik S, Doan A. Retrobulbar Block, Peribulbar Block, and Common Nerve Blocks Used by Ophthalmologists. February 27, 2005; Available from eyerounds.org/tutorials/retrobulbar-nerve-blocks.htm

last updated: 02-27-2005

Tutorials

Pediatric Ophthalmology & Strabismus

Pediatric Spectacle Prescription and Retinoscopy Made Simple: A Tutorial

Jacob Evans BS, Tyler Risma, MD, Alina Dumitrescu, MD

July 13, 2017

Introduction

This review covers simple optical principles of retinoscopy, describes an easily learned technique for retinoscopy with reliable results, and guides decisions based on those results through basic prescribing guidelines as they apply to children.

The estimated prevalence of refractive amblyopia varies widely by ethnic and socioeconomic groups but is estimated to be somewhere between 0.75% and 2.5% of children worldwide.[1-4] The economic impact of pediatric vision loss is difficult to estimate and is most evident only after a child reaches adulthood. However, a study from 2007 estimated 158.1 million global cases of visual impairment resulted from uncorrected or under-corrected refractive error; of these, 8.7 million were blind. This created an estimated economic productivity loss of \$268.8 billion.[5]

The pediatric population with refractive error needs regular assessment and prescription adjustment due to eye growth. The cornea reaches adult size by the age of 2 years, but the eye continues to grow in anteroposterior length until age 7-8 years old. The infant eye averages 16.6 mm in anteroposterior diameter (length), and grows to an adult size averaging 22.0-24.8 mm.[6,7] Since these two variables do not have parallel growth, refractive error changes as children age.

Determining and then correcting a child's refractive error can prevent or treat amblyopia which ultimately helps to avoid irreversible vision loss. Giving children the best possible vision, including correcting refractive error when needed, allows them to succeed scholastically. Visual deficits can also affect a child's daily function and normal play which may decrease his or her confidence. Children may be unaware of less severe vision problems, particularly if anisometropia is present.

In these situations where traditional subjective refraction methods are impossible, including in young children or patients of any age with limited ability to communicate or cooperate, a method for objective refraction is required. This is also useful in cases of atypical refractive error or implausible subjective refraction results. Since retinoscopy is the gold standard for objective refraction, mastering this skill is essential.

Retinoscopy allows the observer to accurately measure a patient's refractive error by determining the spherical power, cylindrical power, and cylindrical axis which focus the patient's eye at optical infinity. This is done by shining diverging light into the patient's eye from the retinoscope and finding the refraction which focuses that light on the patient's retina.

Retinoscopy results also provide information about risk factors for additional ocular morbidities. Patients with myopia have higher rates of other significant ocular disease, such as retinal detachment and glaucoma.[8,9] Patients with severe hyperopia are more likely to develop accommodative esotropia (see "Special Considerations for Spectacles in Children" section) and amblyopia.[10] A subgroup of children with crowded anterior segment and high hyperopia have an increased risk of angle closure glaucoma.

There are a few valuable trends to keep in mind when determining refractive error and prescribing spectacles for children. First, refractive error typically moves from hyperopia toward myopia as children age. Roughly 80% of children between 2 and 6 years old are hyperopic and about 10% of children need refractive correction before 8 years old.[11] Myopia then develops between 6 – 9 years old and frequently increases throughout adolescence.[11] Second, astigmatism is relatively common in babies but decreases in prevalence during the first few years of life.[11] The newborn eye averages a K value (diopters) of 51.2, while the adult eye averages a K value of 43.5 diopters.[12] Thus, although the focusing power of the eye decreases with age, there is a simultaneous trend away from hyperopia -- meaning the eye needs less additional corrective power -- because of simultaneous axial eye length increase as the patient ages.

Multiple methods of retinoscopy exist and have been extensively described. Here we aim to simply describe the basic concept and specifically one common method: *plus cylinder neutralization retinoscopy*. Please refer to other resources for a more exhaustive description of additional techniques and their applications.

Plus cylinder neutralization retinoscopy

1. Tools

- ◆ Lenses
 - Loose lenses: better tolerated by infants/toddlers
 - Retinoscopy paddles: quickest to use (Figure 1)
 - Phoropter: only for cooperative patients

Retinoscope types

- ◆ Figures 2 and 3, next page



Figure 1: Black convex lens ("plus power") and red concave lens ("minus power") retinoscopy paddles.



Figure 2: Welch Allyn retinoscope. Leaving the sleeve down on this retinoscope (and other non-Copeland retinoscopes) provides the plane mirror effect.



Figure 3: Copeland retinoscope. Putting the sleeve up provides the plane mirror effect.

2. Setup

- ◆ Cycloplegic retinoscopy ("wet") vs non-cycloplegic ("dry")
- ◆ Advantages of cycloplegia
 - Paralyzed accommodation, which prevents under-estimation (i.e. overly myopic/less hyperopic) of the patient's refractive error
 - Dilated pupil, making it easier to see the retinoscopic reflex
- ◆ Un-dilated retinoscopy can be performed in cooperative, presbyopic patients and is not recommended in children other than for dynamic purposes (e.g. to assess accommodative ability)
- ◆ Dark room
- ◆ Working distance
- ◆ Dependent on the examiner's arm length and preference
 - A common working distance is 67 cm which gives a working distance lens of +1.50 D.

3. The Basic Technique

The examiner should place himself aligned with the pupil while the patient is looking at a distant object. The examiner then obtains a red reflex with a "streak" of light and passes that streak of light perpendicular to the axis of the streak. By observing the pattern of "with" or "against" motion, the examiner can interchange a lens with more plus power or less plus power to the point where the retinoscopic reflex is "neutralized." At this point, instead

of moving against or with the movement of the streak, the reflex will appear as a diffuse, even light that changes very little as the examiner moves the retinoscope. For plus-cylinder refractions, the examiner starts by neutralizing the meridian with the lower hyperopic power, thereby leaving the meridian 90 degrees away with "with motion." The examiner then neutralizes this second meridian, noting the axis, and calculates the power difference between the two lenses needed for neutralization (plus cylinder power). The examiner then "takes out the working distance" from the lowest hyperopic power which gives the final spherical refraction.

4. Against motion vs. With motion

- ◆ "Against Motion": There is too much plus power in the combined optical system of the eye and the corrective lens, thus the light from the retinoscope is focused in front of the retina as seen by the intersection of the rays in Figure 4 on the left. Therefore, the retinoscopic light reflex seen by the examiner moves in the opposite direction of the retinoscope streak, as illustrated in Figure 4 on the right.
- ◆ "With Motion": There is not enough plus power (or, alternately, too much minus power), causing the retinoscopic light reflex to focus behind the retina as seen by the intersection of the rays in Figure 5 on the left. Therefore, the light reflex seen by the examiner will move in the same direction that the retinoscope streak is moved. This is called "with" motion and is demonstrated in Figure 5 on the right.

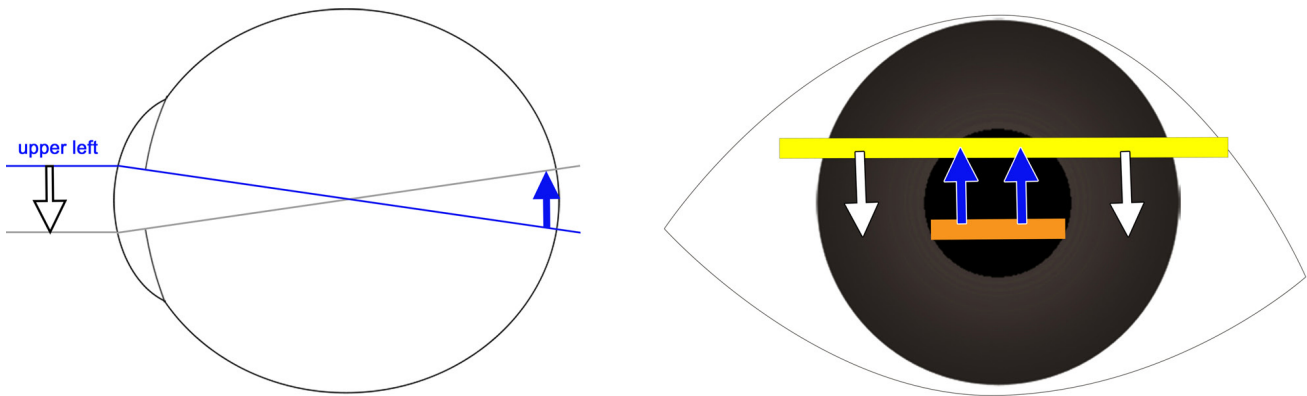


Figure 4: Left: Diagrammatic cross-section of a myopic eye, with rays of light entering the eye from the left and focusing anterior to the retina. The light that strikes the superior cornea is directed toward the inferior retina and the light that strikes the inferior cornea is directed toward the superior retina. Right: The light reflex visible in the pupil (illustrated by the orange bar) will move “against” the direction of the streak of light (illustrated by the yellow bar) from the retinoscope. Thus, as the streak moves downward, the pupillary reflex moves upward.

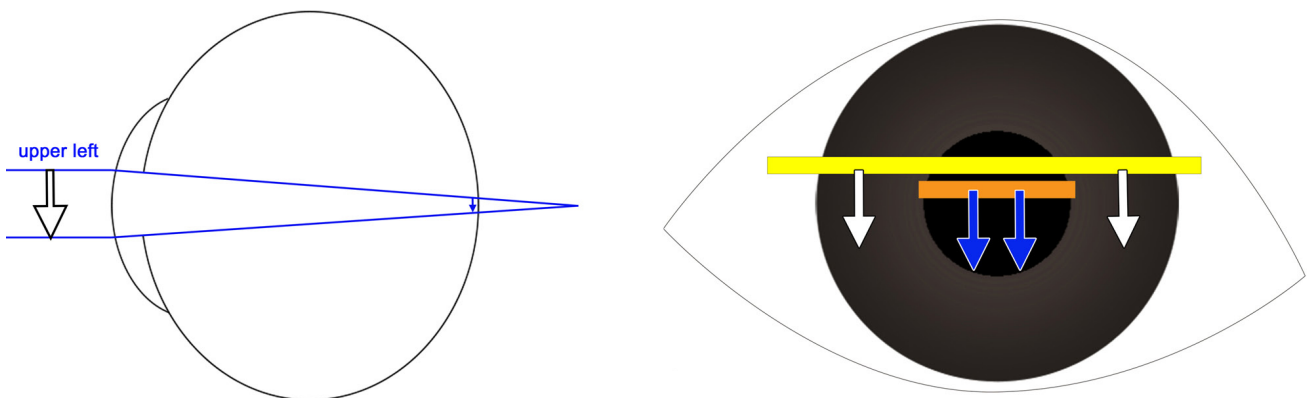


Figure 5: Left: Diagrammatic cross-section of a hyperopic eye, with rays of light entering the eye from the left and focusing posterior to the retina. The light that strikes the superior cornea is directed toward the superior retina and the light that strikes the inferior cornea is directed toward the inferior retina. Right: The light reflex visible in the pupil (illustrated by the orange bar) will move “with” the direction of the streak of light from the retinoscope (illustrated by the yellow bar). Thus, as the streak moves downward, the pupillary reflex also moves downward.

5. Examples: (all of the following examples assume a working distance of 67 cm, which correlates with a working distance lens of +1.50 D; in practice, this must be individualized for each examiner's arm length)

- ◆ **Emmetropia:** The simplest patient for conceptualizing retinoscopy is an emmetrope
 - With no lens in front of an emmetropic eye, an examiner would see “with” motion in all meridians
 - With a +1.50 D lens the light streak would be neutralized in all meridians.
 - With a +2.00 D lens the examiner sees against motion and by putting “less plus” and switching back to a +1.50 D lens the streak is again neutralized
 - After taking out the working distance (by subtracting +1.50), the examiner is left with a refraction of +0.00 D, or plano.

- ◆ **Hyperopia (+2.00)**

- With no lens in front of a hyperopic eye, the examiner would similarly see “with motion” in all meridians
- The examiner adds more plus power until the streak is neutralized with a +3.50 D lens in all meridians
- After taking out the working distance the final Rx is +2.00 D sphere (no astigmatism correction)

- ◆ **Mild Myopia (-1.00)**

- With no lens in front of a patient with mild myopia, the typical examiner would also see “with motion” in all meridians
- The examiner adds plus power until the streak is neutralized in all meridians with a +0.50 D lens
- After taking out the working distance the examiner determines a final Rx of -1.00 D sphere

- ◆ **Moderate Myopia (-4.00)**

- With no lens in front of a patient with moderate myopia, the examiner sees “against” motion in all meridians

- The examiner adds minus-powered lenses until the streak is neutralized in all meridians with a -2.50 D spherical lens
- After taking out the working distance the examiner determines a final Rx of -4.00 D sphere
- ◆ **"With the rule" astigmatism** (+1.00 +1.50 x 090)
 - In most cases of with the rule (WTR) astigmatism, the cornea is steeper in the vertical meridian and flatter in the horizontal meridian, which means more plus lens power will be required to neutralize the horizontal meridian than to neutralize the vertical
 - With no lens in front of this patient with WTR astigmatism, the examiner should first streak the vertical then the horizontal meridian
 1. The examiner "streaks the vertical meridian" by passing a *horizontal* streak of light up and down along the vertical meridian and would see "with motion," which would neutralize with a +2.50 D lens
 2. The examiner then moves on to "streak the horizontal meridian" by passing a *vertical* streak of light side to side along the horizontal meridian, which in this patient would neutralize with a +4.00 D lens
 3. This indicates that an additional +1.50 D is required to neutralize the horizontal meridian as compared to the vertical, which represents the cylindrical power
 4. In this case the streak was placed at exactly 90 degrees which indicates the axis; a cylindrical lens gives power in the axis 90 degrees away, ergo, a cylindrical lens of power +1.50 and axis 90, gives +1.50 D of power in the horizontal (180 degree) meridian
 5. Taking out the working distance (from +2.50) gives +1.00 D and the final Rx is +1.00 +1.50 x 090
- ◆ **Against the rule astigmatism** (+2.00 +1.00 x 180)
 - In most cases of against the rule (ATR) astigmatism, the cornea is steeper in the horizontal meridian and flatter in the vertical meridian, which means more plus lens power will be required to neutralize the vertical meridian than to neutralize the horizontal.
 - With no lens in front of this patient with ATR astigmatism, the examiner should first streak the horizontal and then the vertical meridian
 1. The examiner "streaks the horizontal meridian" by passing a *vertical* streak of light side to side along the horizontal meridian and would see "against motion," which would neutralize with a +3.50 D lens
 2. The examiner then moves on to "streak the vertical meridian" by passing a *horizontal* streak of light up and down along the vertical meridian, which in this patient would neutralize with a +4.50 D lens
 3. This indicates that an additional +1.00 D is required to neutralize the vertical meridian as

compared to the horizontal, which represents the cylindrical power

4. In this case the horizontal streak (for the vertical meridian) was placed at exactly 180 degrees which indicates the axis; a cylindrical lens gives power in the axis 90 degrees away, ergo, a cylindrical lens of power +1.00 and axis 180 gives +1.00 D of power in the vertical (90 degree) meridian
5. Taking out the working distance (from +3.50) gives +2.00 D and the final Rx is +2.00 +1.00 x 180

6. Tips and Hints

- ◆ Because most patients with astigmatism have the WTR type, most examiners begin by "streaking the vertical meridian" (with a horizontal streak of light). After noting the lens power required to neutralize the vertical meridian, the examiner then moves on to "streak the horizontal meridian" (with a vertical streak of light). If the examiner notes that the patient has ATR astigmatism, it is typically easier to neutralize the horizontal meridian first, and then the vertical meridian second. This keeps the refraction in plus-cylinder format and allows the examiner to simply note the orientation of the streak on the second neutralization and use that as the axis on the prescription.
- ◆ If against or with motion is not obvious, a high refractive error should be suspected and a high plus (+10) or minus (-10) lens can be used to attempt to clarify the reflex's movement, followed by neutralization retinoscopy as described in this guide.

Deciding when to prescribe corrective lenses

Once a child's refractive error has been determined, the next decision is whether or not to prescribe corrective lenses. When a child is less than 9 years old, considerations include whether the refractive error is normal for a child's age, and whether the uncorrected error will cause amblyopia or interfere with the child's visual function and alignment. Whether wearing corrective lenses will interfere with emmetropization is controversial. Some providers will prescribe a little less power than needed to encourage emmetropization of the eye, perhaps because the rate of emmetropization is related to the total initial refractive error in infants.[13] A recent study found that prescribing the smallest amount of hyperopic correction needed to allow near-focusing does not impede emmetropization.[14] In daily practice, for hyperopic patients, lower than full plus prescription seems to be better tolerated and accepted by children except in cases of accommodative esotropia, where the full cycloplegic correction is necessary to minimize or eliminate strabismus.

Suggested indications for prescribing spectacles in pediatric populations^[15,16]

The following guidelines come from the American Academy of Ophthalmology's preferred practice patterns. These guidelines represent the minimum values at which spectacle prescription is recommended for isolated refractive error, specifically in the absence of amblyopia or strabismus which should lower the threshold for spectacle prescription.

Isoametropia (Figure 6)

Myopia

- <1 year: > -5 D
- 1-2 years: > -4 D
- 2-3 years: > -3 D
- >4 years: > -1.5 D or if symptomatic [17]

Hyperopia

- <1 year: > +6 D
- 1-2 years: > +5 D
- 2-3 years: > +4.5 D
- >4 years: > +4 D or if symptomatic [17]

Hyperopia with esotropia

- <1 year: > +2.5 D
- 1-2 years: > +2 D
- 2-3 years: > +1.5 D

Astigmatism

- <1 year: >3 D
- 1-2 years: >2.5 D
- 2-3 years: >2 D
- >4 years: >1.5 D or if symptomatic[17]

Anisometropia

Myopia

- <1 year: > -4 D
- 1-2 years: > -3 D
- 2-3 years: > -3 D

Hyperopia

- <1 year: >2.5 D
- 1-2 years: >2 D
- 2-3 years: >1.5 D

Astigmatism

- <1 year: >2.5 D
- 1-2 years: >2 D
- 2-3 years: >2 D

Prescribe anisometric difference at any age if amblyopia is present

Special considerations for spectacles in children^[18-20]

Intermittent exotropia

Lens power may be reduced ("minus lens therapy") from the cycloplegic refraction, even for minor prescriptions, to induce accommodative convergence and reduce exotropia.[18]

Accommodative esotropia

1. Determine the accommodative convergence/accommodation ratio, or AC/A ratio.
 - The AC/A ratio describes the relationship between the amount of convergence (in-turning of the eyes) that is generated by a given amount of accommodation (focusing effort)
 - Either the gradient method or heterophoria method can be used to determine AC/A ratio; see link for instructions. bit.ly/2h1mhPi
2. In children with a normal AC/A ratio (<5:1), the full cycloplegic refraction is prescribed [19]
3. In children with a high (>5:1) AC/A ratio, prescribing the full cycloplegic distance correction can correct the distance deviation completely, but the near deviation may persist. These children may be prescribed bifocals to help correct the near deviation as well. It is important to ensure that the bifocals split the pupil in children. [19]

Aphakia or pseudophakia

Prescribe the full amount of correction with +2 to +3 D (retinoscopy will show -2 to -3D) to allow near activities, since infants are primarily interested in objects near them. At around 1.5-2 years of age, bifocals can be considered.

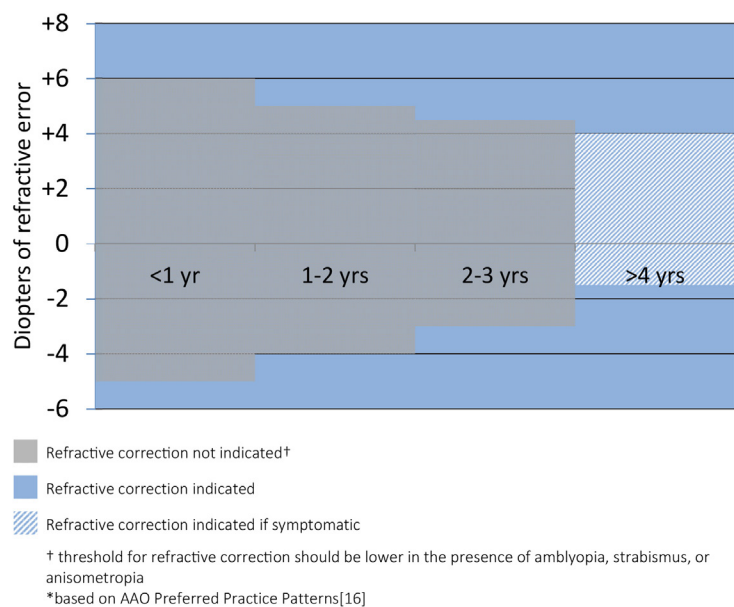


Figure 6. Guidelines For Spectacle Correction of Isolated Isoametropia in Young Children

Anisometropic or astigmatic amblyopia

Correct the full anisometropia, astigmatism, and myopia to cycloplegic refraction. Correct hyperopia that is >3 D to either full cycloplegic refraction, or to a level that is under corrected by as much as 1.5 D. Using this prescribing guideline (without the need for occlusion therapy or other therapies) has been shown to resolve anisometropic amblyopia in roughly one third of cases.[10-21]

References

1. Xiao O, Morgan IG, Ellwein LB, He M. Prevalence of amblyopia in school-aged children and variations by age, gender, and ethnicity in a multi-country refractive error study. *Ophthalmology* 2015;122:1924-31.
2. Wang Y, Liang YB, Sun LP, et al. Prevalence and causes of amblyopia in a rural adult population of chinese the handan eye study. *Ophthalmology* 2011;118:279-83.
3. Attebo K, Mitchell P, Cumming R, et al. Prevalence and causes of amblyopia in an adult population. *Ophthalmology* 1998;105:154-9.
4. Friedman DS, Repka MX, Katz J, et al. Prevalence of amblyopia and strabismus in white and african american children aged 6 through 71 months the baltimore pediatric eye disease study. *Ophthalmology* 2009;116:2128-34.e1-2.
5. Smith T, Frick K, Holden B, et al. Potential lost productivity resulting from the global burden of uncorrected refractive error. *Bull World Health Organ* 2009;87:431-37.
6. Riordan-Eva P. Chapter 1. Anatomy & embryology of the eye. In: Riordan-Eva P, Cunningham ET (eds). *Vaughan & asbury's general ophthalmology, 18e*. New York, NY: The McGraw-Hill Companies, 2011.
7. Bekerman I, Gottlieb P, Vaiman M. Variations in eyeball diameters of the healthy adults. *Journal of Ophthalmology* 2014;2014:5.
8. Lai TY. Retinal complications of high myopia. *Med Bull* 2007;12:18-20.
9. Mitchell P, Hourihan F, Sandbach J, Wang JJ. The relationship between glaucoma and myopia: The blue mountains eye study. *Ophthalmology* 1999;106:2010-5.
10. Blouza AJ, Loukil I, Mhenni A, et al. Prise en charge de l'hypermétropie de l'enfant. *J Fr Ophtalmol* 2007;30:255-59.
11. Fredrick DR. Chapter 17. Special subjects of pediatric interest. In: Riordan-Eva P, Cunningham ET (eds). *Vaughan & asbury's general ophthalmology, 18e*. New York, NY: The McGraw-Hill Companies, 2011.
12. Gordon RA, Donzis PB. Refractive development of the human eye. *Arch Ophthalmol* 1985;103:785-89.
13. Saunders KJ, Woodhouse JM, Westall CA. Emmetropization in human infancy: Rate of change is related to initial refractive error. *Vision Res* 1995;35:1325-8.
14. Somer D, Karabulut E, Cinar FG, et al. Emmetropization, visual acuity, and strabismus outcomes among hyperopic infants followed with partial hyperopic corrections given in accordance with dynamic retinoscopy. *Eye* 2014;28:1165-73.
15. Summers CG, et al. Preferred practice pattern guidelines. *Amblyopia*. San Francisco, CA: American Academy of Ophthalmology, 2012.
16. Summers CG, et al. Preferred practice pattern guidelines. *Pediatric Eye Evaluations*. San Francisco, CA: American Academy of Ophthalmology, 2012.
17. Miller JM, Harvey EM. Spectacle prescribing recommendations of aapos members. *Journal of pediatric ophthalmology and strabismus* 1998;35:51-2.
18. Caltrider N, Jampolsky A. Overcorrecting minus lens therapy for treatment of intermittent exotropia. *Ophthalmology* 1983;90:1160-5.
19. Rogers GM, Longmuir SQ. Refractive Accommodative Esotropia. EyeRounds.org. January 26, 2011; Available from: <http://EyeRounds.org/cases/129-accommodative-esotropia.htm>
20. Cotter SA, Edwards AR, Wallace DK, et al. Treatment of anisometropic amblyopia in children with refractive correction. *Ophthalmology* 2006;113:895-903.
21. Steele AL, Bradfield YS, Kushner BJ, et al. Successful treatment of anisometropic amblyopia with spectacles alone. *J AAPOS* 2006;10:37-43.

Suggested Citation Style

Evans J, Risma T, Dumitrescu A. Pediatric Spectacle Prescription and Retinoscopy Made Simple. EyeRounds. July 13, 2017. Available at EyeRounds.org/tutorials/pediatric-spectacle-prescription-and-retinoscopy

last updated: 07/13/2017

Binocular Vision

Rahul Bhola, MD

January 23, 2006; reviewed for accuracy January 6, 2013

Introduction

Binocular vision is one of the hallmarks of the human race that has bestowed on it the supremacy in the hierarchy of the animal kingdom. It is an asset with normal alignment of the two eyes, but becomes a liability when the alignment is lost.

Binocular Single Vision may be defined as the state of simultaneous vision, which is achieved by the coordinated use of both eyes, so that separate and slightly dissimilar images arising in each eye are appreciated as a single image by the process of fusion. Thus binocular vision implies fusion, the blending of sight from the two eyes to form a single percept.

Binocular Single Vision can be

1. Normal – Binocular Single vision can be classified as normal when it is bifoveal and there is no manifest deviation.
2. Anomalous - Binocular Single vision is anomalous when the images of the fixated object are projected from the fovea of one eye and an extrafoveal area of the other eye i.e. when the visual direction of the retinal elements has changed. A small manifest strabismus is therefore always present in anomalous Binocular Single vision.

Normal Binocular Single vision requires

1. **Clear Visual Axis** leading to a reasonably clear vision in both eyes
2. The ability of the retino-cortical elements to function in association with each other to promote the fusion of two slightly dissimilar images i.e. **Sensory fusion**.
3. The precise co-ordination of the two eyes for all direction of gazes, so that corresponding retino-cortical element are placed in a position to deal with two images i.e. **Motor fusion**.

The advantages of a Binocular vision are

1. The first and the foremost advantage of a binocular vision is single vision.
2. In addition to single vision it results in stereopsis – the most precise kind of depth perception
3. Enlargement of the field of vision
4. Compensation for blind spot and other differences

Sensory Aspects of Binocular vision

The objects in space are localized by us in two ways –one is relative to one another and is called relative localization and the other is in relation to ourselves and is called ego-centric localization.

Objective (Physical) & Subjective (Visual) space

Location of an object point in physical space was separated from its localization in visual space. The objective lines of direction determine which retinal area will be stimulated, their subjective counterpart, the visual direction determines the direction in which the object will be seen in visual space.

Retinal Element

It is defined as a retinocerebral apparatus engaged in elaborating a sensation in response to excitation of a unit area of retinal surface.

- ◆ The retinal area when stimulated by light entering the eye from an object is perceived not only as being of certain brightness, color and certain form, but also has a certain direction in visual space. This direction in which the visual object is localized is determined by the directional or spatial values of the stimulated retinal element called the Local signs of Lotze which is an intrinsic property inherent in the retinal element.
- ◆ Thus each retinal element when stimulated localizes the stimulus as a visual percept in a specific direction – a visual direction. This direction is relative to the visual direction of the fovea. Fovea, which is the area of the highest visual acuity, is the carrier of Principle Visual direction and is the center to which the secondary visual direction of the other retinal element relates.
- ◆ Fovea besides being the carrier of principle visual direction, is also the retinomotor center or retinomotor zero point i.e. once an image of the object of regard is on fovea there is no incentive for ocular movement.

Visual Axis (Line of direction or direction ray of Helmholtz)

It is the line which connects an object point with its image on the retina. If the visual axis of the two foveas also known as the principle visual axis intersects at the fixation point, it is said that there is binocular fixation.

If only one principle line of direction goes through the fixation point, then fixation is monocular.

All object points that simultaneously stimulates the two fovea appears in one and the same subjective visual direction coinciding with the median plane of the head. This is known as the common subjective visual direction of the fovea. It lies in an imaginary plane passing through the root of the nose known as third central imaginary eye or the binoculus or cyclopean eye.

Retinal Correspondence

Retinal elements of the two eyes that share a common subjective visual direction are called corresponding retinal points. All other retinal elements are non-corresponding or disparate with respect to a given retinal element in the fellow eye for a particular visual direction.

Law of Sensory Correspondence

The Law of Sensory Correspondence states that existence of corresponding retinal elements with their common relative subjective visual direction is the essence of binocular vision.

Retinal Correspondence can be of two types

1. Normal Retinal Correspondence

Retinal correspondence is called normal when both the fovea have a common visual direction and the retinal elements nasal to the fovea in one eye corresponds to the retinal elements temporal to the fovea in the other eye.

2. Abnormal Retinal Correspondence

Retinal correspondence is abnormal when the fovea of one eye has a common visual direction with an extrafoveal area in the other eye. This is generally seen if the angle of squint is small and the extrafoveal point is close to the fovea. It is an attempt to regain the binocular advantage, although anomalous (because it is foveo-extrafoveal and not foveo-foveal). This results in the eyes seeing binocularly single in spite of a manifest squint. In ARC under binocular conditions the fovea and the extrafoveal point share the common subjective visual direction. But when the normal eye is closed the extrafoveal element loses any advantage over the fovea of that eye, which retains its primary visual direction. Thus under monocular conditions the central fixation is retained by the fovea, this is the basis of the cover test.

The quality of binocular single vision obtained in ARC varies from patient to patient, in some there is useful gross stereopsis while in the others binocular vision is rudimentary. The quality of binocular vision is usually inversely proportional to the angle of deviation.

Concept of a Horopter

The term Horopter (the horizon of vision) was introduced in 1613 by Aguilonius. It is defined as the locus of all object points that are imaged on corresponding retinal elements

at a given fixation distance. Thus a line can be drawn through the object of regard such that all the points on the line are imaged on the corresponding retinal elements and are seen singly.

Geometric Vieth Muller horopter

According to this model of horopter if corresponding points have a regular horizontal distance from the retina the horopter would be a circle passing through the center of rotation of the two eyes and the fixation point. Thus the circle becomes smaller as the point of fixation gets nearer.

Empirical Horopter Curve

The empirical horopter curve or the longitudinal horopter is slightly flatter than Vieth Muller geometric horopter i.e. it has a greater radius of curvature. The deviation of the perceptual from the geometric horopter is known as the Hering-Hillebrand deviation. This deviation is felt to be due to both neural and optical factors. The nasal hemi-retina at any given eccentricity contains more photoreceptors per unit area than the temporal hemi retina producing a deviation in the horopter mapping in the visual cortex.

Thus all the points not lying on the horopter are imaged by disparate retinal elements and are seen as double. This diplopia elicited by object points off the horopter is called Physiological diplopia. However we normally do not always experience this diplopia. This can be explained on the basis of **Panum's Fusion Area**. It is defined as a narrow band around the horopter within which the objects stimulation disparate retinal elements transmit the impression of single vision.

Thus the range of horizontal disparities around the horopter within which the stimulus will continue to be perceived as single is known as Panum's fusional area.

Panum's area is narrowest at the fixation point and becomes broader in the periphery at a rate of 1-2 arc min per degree of visual field eccentricity. Thus the horizontal extent of this area is small at the center (6-10 arc min near the fovea) and increases towards the periphery (30-40 arc min at 12° from the fovea). The increase in the Panum's area towards the periphery may be related to anatomic and physiologic differences known to exist between the monosynaptic foveal cone system and the rod and cone system of the periphery.

The increase in the spatial extent of Panum's area in the peripheral visual field serves three useful purposes

- ◆ Increasing size of Panum's area matches increasing coarseness of peripheral vision. Receptive field size increases and the visual acuity decreases as a function of eccentricity.
- ◆ Increasing the thickness of Panum's area prevents bothersome peripheral diplopia when fixating flat targets held at close range.
- ◆ Increasing the extent of Panum's area peripherally makes cyclofusion possible despite cyclovergence errors of as much as 2 degrees between the two eyes.

Panum's area expands and contracts depending on the size, sharpness and speed of the stimuli. Panum's area for the stimuli that are fuzzy and slow moving is 20 times wider than it is for stimuli that are sharply focused and rapidly moving.

Fusion

Fusion is defined as the unification of visual excitations from the corresponding retinal images into a single visual percept.

Sensory Fusion

It is the ability to appreciate two similar images, one with each eye and interpret them as one. Single visual image is the hallmark of retinal correspondence. For sensory fusion to occur, the images not only must be located on corresponding retinal areas but also must be sufficiently similar in size, brightness and sharpness to permit sensory. Unequal images are a severe obstacle to fusion.

Motor Fusion

It is the ability to align the eyes in such a manner that sensory fusion can be maintained. The stimulus for these fusional eye movements is retinal disparity outside Panum's area and the eyes moving in opposite direction (vergence). Unlike sensory fusion, motor fusion is the exclusive function of the extrafoveal retinal periphery.

Fusion, whether sensory or motor, is always a central process i.e. it takes place in the visual cortex.

Diplopia

The simultaneous stimulation of non-corresponding or disparate retinal elements by an object point causes this point to be localized in two different subjective visual directions. An object point seen simultaneously in two directions appears double. Double vision is the hallmark of retinal disparity.

Retinal Rivalry / Binocular Rivalry

When dissimilar contours are presented to corresponding retinal areas fusion becomes impossible and retinal rivalry may be observed. Simultaneous excitation of corresponding retinal areas by dissimilar objects does not permit fusion and leads to confusion. In order to remove this confusion, image from one of the eyes is suppressed. This constant foveal suppression of one eye with cessation of rivalry leads to complete sensory dominance of the other eye, which is a major obstacle to binocular vision. Return of retinal rivalry is a requisite for re-establishment of binocular vision.

Suppression

It is a neuro-physiological active inhibitory mechanism in which when corresponding retinal areas are stimulated by dissimilar stimuli or when non-corresponding retinal areas are stimulated by similar stimuli, one or the other is temporarily inhibited or suppressed to prevent confusion or diplopia respectively. Suppression is foveal in order to tackle confusion and extrafoveal in order to avoid diplopia.

Suppression can be further of two types

- ◆ **Facultative-** Facultative suppression is only under binocular conditions with no persisting "hang over" under monocular conditions. Thus the visual acuity is not reduced under monocular conditions and there are no unocular scotomas in the visual field.
- ◆ **Obligatory-** Obligatory suppression is the effect which carries on even under monocular conditions resulting in diminution of visual acuity. Amblyopia is the fallout of this obligatory suppression.

Stereopsis (Disparity Sensitivity)

It is the ability to fuse images that stimulate horizontally disparate retinal elements within Panum's fusional area resulting in binocular appreciation of visual object in depth i.e. in the third dimension. The eyes are separated in the horizontal plane of the head and thus each eye has a slightly horizontally disparate view of the world. The sensory fusion of these horizontally disparate unequal retinal images results in a three dimensional percept. An object confined to the horopter is seen as flat because it projects to corresponding retinal regions, causing zero horizontal disparity.

Non-zero disparities giving rise to stereoscopic depth are divided into crossed and uncrossed.

- ◆ **Crossed disparities** are created by objects in front of the horopter (near objects). The disparity is termed "crossed" because the monocular image of the object when viewed by the right eye is displaced to the left, whereas that viewed by the left eye is displaced to the right.
- ◆ **Uncrossed disparities** are created by objects located behind the horopter (far objects). In this case the monocular image of the objects viewed by the right eye is displaced to the right and that viewed by the left eye is displaced to the left.

Stereoscopic acuity

It is the smallest binocular disparity that can be readily detected i.e. it is the minimum disparity beyond which no stereoscopic effect is produced. There are no standardized clinical stereoscopic acuity tests, but generally speaking, a threshold of 15–30 arc sec. can be regarded as excellent. Since there is a stereoscopic threshold, it follows that stereopsis cannot work beyond a certain critical distance. This distance has been computed to be between 125-200 meters. The stereoscopic acuity also varies depending on whether the target is stationary or moving, and whether

the eyes are stationary or moving. The stereoacuity threshold for static targets is in the range of 2-10 arc sec. For targets in motion towards and away from the observer the threshold increases to about 40 arc sec. Stereoacuity is maximal about 0.25 degrees off dead center in the foveola, and diminishes exponentially with increasing eccentricity along the x-axis. Stereopsis is nil beyond 15 degrees eccentricity. Stereoacuity diminishes in similar exponential fashion when the target is moved in front or behind the horopter along the y-axis.

Though stereopsis is essential for depth perception it is not the only mean for spatial orientation. The various monocular clues to spatial orientation can be

- ◆ Apparent size – Small retinal objects are interpreted as distant objects and large retinal objects as near objects. Objects progressively increase in size as they move towards us (looming).
- ◆ Interposition – relatively nearer objects tend to conceal or overlay more distant objects.
- ◆ Aerial perspective – water vapor, dust and smoke in the atmosphere scatter light and make distant objects indistinct and relatively color desaturated.
- ◆ Shading – light falling on solid objects causes shadows to be cast, and on curved surfaces causes a gradation in the intensity of shadow.
- ◆ Geometric perspective – physically parallel lines converge toward a vanishing point at the horizon, e.g. railroad tracks.
- ◆ Relative velocity – the image velocity of a moving target in the distance is lower than the image velocity of the same moving target when it is nearby.
- ◆ Motion parallax – translocation of the head cause the images of near objects to move opposite the head and the images of far objects to move with the head, assuming the fixation point is at an intermediate distance.

Development of Binocular Vision

During the first few years of life certain normal anatomical and physiological conditions are required for the development of binocular vision. The factors concerned in the development of Binocular vision and which enable the eyes to function in a coordinated manner are

Anatomical factors: The two eyes are so situated in the orbit that the visual axis is directed in the same direction. This is due to

- ◆ Shape of the orbit
- ◆ Presence of adjacent ligaments, muscles and connective tissues.

The extra-ocular muscles have an important role to play as they provide motor correspondence because of the reciprocal innervation of the extra-ocular muscles.

The aim of the motor correspondence is to-

- ◆ Enlarge the field of view by transforming the field of vision into the field of fixation.

- ◆ Bring back the object of attention on to the fovea and to maintain it.
- ◆ Position the two eyes in such a way that at all the times they are properly aligned.

Physiological factors: The development of binocular vision (BV) depends upon certain normal physiological binocular reflexes. The reflexes can either be inborn or acquired as a result of appropriate stimulation. The various binocular reflexes are

1. Fixation reflexes

- Compensatory fixation reflex (Gravitational reflex) - The function of this reflex is to keep the eyes in a fixed position i.e. looking in the required direction compensating for the movement of the body, head, limbs etc. In male it is due to the frontal direction of the eyes and the utricles and saccules presiding over the tone of the vertical recti and obliques, respectively.
- Orientation fixation reflex -It can be demonstrated by the eye following a moving object or panorama, thus exhibiting a comparatively slow movement of continued fixation and not a rapid jerk fixation. This reflex relates to horizontal axis.
- Accommodation convergence reflex- It is aimed at correctly aligning the eyes and keeping them focused on the object. It includes vergence fixation reflex, accommodation reflex and fusional vergence reflex.

2. The refixation reflex –It relates the eye back to the original orientation point or to the new orientation point.

3. The pupillary reflex

Fusion Reflex and its Development: Fusional reflexes are conditioned reflexes, acquired and maintained by cerebral activity. They are developed by the individual on the basis of experience. Once formed, with continued reinforcement it becomes an unconditioned reflex. Also known as psychoptical reflexes, it consists of all the activities mediated from the retina through the brain to maintain the images received on the two foveas with the ultimate aim of attaining a single binocular vision. The elements of fusion mechanism are

- ◆ Fixation reflex
- ◆ Refixation reflex
- ◆ Conjugate fusional reflexes – maintains the parallelism of the two eyes in all positions of gaze.
- ◆ Disjunctive reflexes convergence/divergence reflexes.

At birth the fixation reflex is poorly developed, with the child having only random, non-conjugate and aimless ocular movements. There is inability to carry out pursuit movements during the first few weeks of life. The development of optomotor reflex is essentially a post natal event, with the approximate time schedule being

- ◆ 2- 3 weeks –follows light unilaterally
- ◆ 6 weeks to 6 months - follows light binocularly

- ◆ Convergence which is absent at birth starts developing at 1 month of age and is well established by 6 months.
- ◆ The development of accommodation lags behind the development of convergence due to the delay in the development of ciliary muscles, parallels with the convergence by 6 months of age.

Electrophysiological studies have shown that infants can detect retinal disparities between 2-5 months of age but little is known about the development of stereoacuity between the ages of 6 months to 3 years, when the child may sufficiently be able to comprehend subjective tests. However, it is generally agreed that there is a gradual improvement in stereoacuity up to the age of 9 years.

Thus it can be said that in human beings the sensitive period of development of binocular vision begins at about 4 months of age, peaks at 2 years, is well developed by 4 years of age and slowly declines to cease by 9 years of age. These estimates assume that a single sensitive period during which the binocular function appears to be at a risk is during the first 2 years of life. Any obstacle in the reflex pathway is likely to hamper the development of binocular vision.

The obstacles can be in the form of

1. Sensory obstacles

- ◆ Diopteric obstacles – e.g. media opacities, uncorrected errors of refraction.
- ◆ Prolonged unocular activity- e.g. severe ptosis, anisometropia
- ◆ Retinoneural obstacles – lesions of retina, optic nerve
- ◆ Proprioceptive obstacle

2. Motor obstacles

- ◆ Congenital craniofacial malformations
- ◆ Conditions effecting extra-ocular muscles
- ◆ CNS lesions- involving the nerve trunks, root of nuclei

3. Central obstacles

The presence of these obstacles gives rise to various sensory adaptations to binocular dysfunction especially if the disruptive factor is present in the sensitive period. This can be in the form of

- ◆ ARC
- ◆ SUPPRESSION
- ◆ AMBLYOPIA

Theories of Binocular Vision

- ◆ **Correspondence and disparity theory:** According to this theory sensory binocular cooperation is based on system of correspondence and disparity. It assumes the presence of one to one retinocortical relationship between the two eyes. When stimulated simultaneously by one object point they transmit single visual impression with no depth quality. When stimulated simulta-

neously by two object points that differ in character – binocular rivalry occurs. When disparate elements are stimulated by one object point diplopia occurs. However if horizontal disparity remains within limits of Panum's area, a single visual impression is elicited with depth or stereopsis. The perceived depth increases with increasing disparity. However with increasing disparity quality of stereopsis decreases which may eventually lead to diplopia.

- ◆ **Neurophysiological theory of binocular vision and stereopsis:** Animal experiments of Hubel and Wiesel showed that roughly 80% of the neurons in the striate cortex can be driven from either eye in response to a visual stimulus from the retina, assuming that there exists a precise and orderly arrangement of connections along the entire retino-geniculate striate pathway. 25% of these binocularly driven cells were stimulated equally from each eye, while 75% represented graded response from either left or right eye. Cells that could be driven by stimulation of either eye had receptive fields of nearly equal size and in corresponding positions of visual field.

In normal Binocular Single Vision, optical stimulus will excite a cortical cell only if it is presented to its two receptive fields simultaneously. Although two receptive fields are involved, only one object feature is detected by each cortical cell and assigned by it to a single locus in space. The two receptive fields do not always occupy anatomically identical regions in the two retinas. At a given locus in the retino-optic cortical map there are cells whose fields have exactly corresponding points in the two retina and cells whose fields have slightly different position in the two eyes. This retinal field disparity which is caused by the difference in direction or distance of the fields in each retina forms the basis of Panum's fusion area and is detected by sensitive binocular neurons giving rise to binocular vision and stereopsis.

Grades of Binocular Vision

There are three grades of binocular vision as given by Worth's classification

Grade I: *Simultaneous macular perception* is the most elementary type of binocularity. It occurs when the visual cortex perceives separate stimuli to the two eyes at the same time and concerns itself essentially with the absence of suppression. SMP is not the same as superimposition, whereby the two different pictures are seen simultaneously in the same direction. SMP in the true sense just represents simple sensory fusion.

Grade II: It represents *true fusion* with some amplitude. Not only are the two images fused, but some effort is made to maintain this fusion in spite of difficulties. Thus the second grade implies a motor response added to simple sensory fusion.

Grade III: In the highest type of binocularity, not only are the images of the two eyes fused, but they are blended to

produce a *stereoscopic effect*. This involves a perceptual synthesis at a higher level.

These three grades are not necessarily mutually exclusive, since fusion in the periphery, even showing motor responses, may exist coincidentally with the total absence of simultaneous foveal perception.

Investigations for Binocular Vision

All the tests are aimed at assessing the presence or absence of

- ◆ Normal or abnormal retinal correspondence
- ◆ Suppression
- ◆ Simultaneous perception
- ◆ Fusion with some amplitude
- ◆ Stereopsis

Before any test is undertaken it is essential to assess the

- ◆ visual acuity
- ◆ fixation in the squinting eye
- ◆ direction and size of deviation

Test for Retinal Correspondence

Clinically the tests used can be based on either of the two principles

A) Assessment of relationship between the fovea of the fixing eye and the retinal area stimulated in the squinting eye. This includes

- ◆ Bagolini's striated glasses test
- ◆ red filter test
- ◆ Synaptophore using SMP slides for measuring the objective and subjective angles
- ◆ Worth's 4 dot test

B) Assessment of the visual directions of the two foveas. Included in this are

- ◆ After image test (Hering Bielschowsky)
- ◆ Coppers binocular visuoscopy test (foveo-foveal test of Coppers)

Bagolini's Striated Glasses Test: For this the patient fixates a small light, after being provided with plano lenses with narrow fine striations across one meridian (micro Maddox cylinders). These glasses do not affect the vision or the accommodation of the patient. The fixation light is seen as an elongated streak. The lenses are usually placed at 45 degree OS and 135 degree OD (cover the patients glasses, if he wears any) and the patient fixates for distance or near. The interpretation of this test is as follows-

- ◆ Crossing of the lines at right angles to each other
 - If cover test reveals no shift and fixation is central, the patient has NRC
 - If cover test reveals a shift, harmonious ARC is present

- ◆ Foveal suppression scotoma (fixation point scotoma) with peripheral fusion, if no shift occurs with cover test, NRC exists, if shift occurs, ARC exists
- ◆ Single line represents suppression

Red Filter Test: If one examines the visual field of a patient with heterophoria by placing a red filter in front of the habitually fixating eye while the patient is looking at a small light source, number of different responses can be elicited.

- ◆ The patient may report that two lights are seen, a red one and a white one. In esotropia the images appear in homonymous (uncrossed) diplopia, with the red light to the right of the white one when the red filter is in front of the right eye. In exotropia the images appear in heteronymous (crossed) diplopia, with the red light to the left of the white light when the red filter is in front of the right eye. This represents NRC.
- ◆ The patient may report that only one pinkish light in the position of the white fixation light is seen i.e. the red and white images appear to be superimposed. This is clearly an abnormal response in presence of heterophoria. This is termed Harmonious ARC.
- ◆ The patient may report that two lights in uncrossed or crossed diplopia are seen, depending upon the direction of deviation but the measured distance between the double images proves to be smaller than expected from the magnitude of deviation. This represents unharmonious ARC.
- ◆ Suppression is said to occur when the patient reports only a single light (usually the white light) but occasionally red depending upon the density of the red filter and the degree of the dominance of the fellow eye.

Measurement of Angle of Anomaly: The angle of anomaly denotes the degree of shift in visual direction. It is determined by calculating the difference between the objective and subjective angles of deviation.

Procedure of estimating the angle of anomaly -

For this the use of SMP slides is made. The arms of the synaptophore are set at zero. Both the arms of the instrument are moved by the examiner while alternately flashing the light behind each slide until there is no further fixation movement of the patient's eye (alternate cover test). The reading of both the arms is noted at this moment and the sum total of the reading of both the arms gives the objective angle of anomaly. The subjective angle of anomaly is the angle at which the visual targets are superimposed.

The interpretation of this test is as follows-

- ◆ Angle of Anomaly = Objective Angle – Subjective Angle
- ◆ If Subjective Angle = Objective Angle → NRC
- ◆ If Subjective Angle < Objective Angle → ARC
- ◆ If Angle of Anomaly = Objective Angle → Harmonious ARC (full sensory adaptation)
- ◆ If Angle of Anomaly < Objective Angle → Unharmonious ARC

Worth Four Dot Test: This is a simple test utilizing red-green color dissociation. It is more dissociating than the

bagolini glasses and so less physiological. The apparatus for this test consists of a box containing four panes of glass, arranged in diamond formation, which are illuminated internally. The two internal panes are green, the upper one is red and lower one is white. The patient wears red and green goggles (as a convention red in front of right and green in front of left). The test can be performed separately for distance and near vision. The interpretation of this test is as follows-

- A) The patient sees all the four dots.
- normal binocular response with no manifest deviation (NRC with no heterotropia)
 - Harmonious ARC with manifest squint.
- B) The patient sees five dots.
- uncrossed diplopia with esotropia, red dots appear to the right
 - crossed diplopia with exotropia, red dots appear to the left of the green dots.
- C) The patient sees three green dots, suppression of right eye.
- D) The patient sees two red dots, suppression of left eye.

Hering Bielschowsky After-Image Test: This is a highly dissociating orthoptic test in which battery- powered camera flash is used to produce a vertical after image in one eye and a horizontal after image in the other eye. The center of flash is covered with a black mark (serves as a point of fixation and protects the fovea). Once an afterimage is created in each eye, the position of the images in relation to each other no longer depends on whether the eyes are open, closed, straight or crossed. The interpretation of this test depends on the fixation behaviour.

Procedure -

Each eye fixates on the center black mark of a glowing filament, first presented horizontally to the eye with a better visual acuity and then vertically to the poorer eye for 20 sec in a darkened room while the fellow eye is occluded. The patient indicates the relative position of the two gaps in the center of each afterimage. The gaps correspond to the visual direction of each fovea if central fixation is present.

Interpretation of results -

- ◆ **Cross response:** A symmetrical cross with the central gaps superimposed indicates a normal bifoveal correspondence (if eccentric fixation is excluded). This is irrespective of any deviation between the two eyes, i.e. any eso or exo-deviation with NRC still gives a symmetrical cross response.
- ◆ **Asymmetrical crossing:** In case of ARC the horizontal and vertical lines have their center separated, the amount of separation dependent on the angle of anomaly. A patient with right esotropia sees the vertical afterimage displaced to the left and a case of right exotropia sees the vertical afterimage displaced to the right.
- ◆ **Single line with a gap:** A single line with a gap indicates suppression in the fellow eye.

Foveo-Foveal Test of Cuppers: Cuppers test for retinal correspondence determines whether the two foveas have common or different visual directions. It permits quantitative analysis of the angle of anomaly when eccentric fixation is present.

Procedure -

The patient fixates with the normal eye on the central light of a Maddox scale via a plano mirror, which for the convenience of the examiner is turned in such a manner that the amblyopic eye looks straight ahead. The visuoscope asterisk is projected by the examiner onto the fovea of the amblyopic eye. The figure of the Maddox scale on which the patient sees the asterisk indicated the angle of anomaly.

Modification -

To determine which parts of the peripheral retina in the deviating eye have acquired a common visual direction with the fovea of the fixating eye, the patient is asked to guide the Visuoscope until he sees the asterisk superimposed on the central light of the Maddox cross. The examiner views the fundus when this task is completed and notes the position of the asterisk, which indicates the location of retinal elements having a common visual direction with the fovea of the sound eye.

Suppression

Suppression is the active cortical inhibition of the unwanted stimuli, to avoid binocular diplopia and confusion. While the former is overcome by peripheral suppression, the latter is overcome by central/foveal suppression. Tests used to diagnose the suppression are

1. Worth's four dot test
2. Synaptophore
3. Friend test
4. Amsler Grid
5. 4 Δ prism base out test
6. Red filter test
7. Bagolini's striated glasses

Testing extent of suppression: The extent or the area of suppression can be charted under binocular conditions (fixating with one eye while the field of other eye is charted). This may be done by different methods

- ◆ Prisms to displace the central object peripherally till it can be visualized in different directions.
- ◆ Synaptophore: charting of one eye, while the other eye is used for fixation
- ◆ Lee's screen or Hess screen
- ◆ Polaroid Scotometer
- ◆ Phase difference haploscopy of Aulhorn

The various responses that can be observed are

- ◆ With more dissociating tests like prisms, Lee's etc. single large coarse scotomas are seen; these extend from fovea to the diplopia point.
- ◆ With less dissociating tests like Aulhorn phase difference haploscope and Polaroid scotometer, two discrete scotoma are seen. These are foveal scotoma about 2-3 degrees in size and diplopia point scotoma.

Depth of Scotoma - The depth or intensity of scotoma can be seen by using differential stimulation of the two eyes. The graded density filter bar of Bagolini is useful. As the denser filters are brought over the dominant eye, the relative scotoma of the amblyopic eye start disappearing or shrinking in size.

4 Δ prism base out test - Image displacement with a weak base out prism, while one observes the resulting binocular (version) and monocular (fusional) eye movements, is a quick, sensitive screening test to assess whether bifoveal fusion or suppression of one fovea is present. Sudden displacement of an image with a base out prism from one fovea onto the parafoveal temporal retina will elicit a refixation movement if the image has been shifted within a normally functioning retina, but no movement will occur if the image has been shifted within a nonfunctioning (that is, scotomatous) area. According to Hering's law the movement of the fellow eye will be biphic, that is, it will move outward simultaneously and symmetrically (version) when the eye under the prism refixates and then will perform a slow fusional movement (duction) in the opposite direction to correct for the image displacement. However if a central scotoma has impaired foveal function, the second phase (the fusional movement) does not occur, and the eye remains slightly turned out.

Simultaneous Macular Perception

This is the most elementary type of binocularity and is tested with the help of SMP slides on the synaptophore, which depicts objects which are dissimilar, but mutually agnostic (e.g. presenting a picture of a square to one eye and a circle to other). The commonly used slides are bird and cage, lion and cage, butterfly and net.

If superimposition occurs, it is necessary to make a more accurate assessment by using target slides of different sizes.

- ◆ Simultaneous foveal perception slide – subtend an angle of 1 degree at the nodal point
- ◆ Simultaneous parafoveal perception slides – subtend angle of 1-3 degree
- ◆ Simultaneous paramacular perception slides – subtend angle of 3-5 degree
- ◆ Simultaneous peripheral perception slides – subtend angle greater than 5 degrees

The term simultaneous perception does not necessarily mean bifoveal fixation as it can also occur in ARC. It merely indicates the presence or absence of suppression. This

term is erroneous as it embraces both foveal and parafoveal perception in the same definition.

Tests for Fusion: Fusion is demonstrated by using slides in which similar pictures with different controls are presented to the eyes simultaneously e.g. letter L and F fused into E, rabbit with a tail and rabbit with flower in hand, fused into one rabbit having tail and flower.

Normal fusion amplitudes are

- A) Horizontal vergences
 - Convergence → 35 Δ to 40 Δ
 - Divergence → 5 Δ to 7 Δ
- B) Vertical vergence
 - Supravergence → 3 Δ
 - Infravergence → 3 Δ
- C) Cyclovergence → 2-3 Δ

Fusion assessment is essential both for the prognosis and management of strabismus. Fusion is essential for the restoration of BSV. Various tests used to find out the presence of fusion are

- ◆ Worth's 4-dot test
- ◆ Bagolini's striated glasses
- ◆ Synaptophore

Tests for Stereopsis: Tests on stereopsis can be based on two principles-

- ◆ Using targets which lie in two planes, but are so constructed that they stimulate disparate retinal elements and give a three dimensional effect, for example
 - Circular perspective diagram such as the concentric rings
 - Titmus fly test, TNO test, Random dot stereograms, Polaroid test
 - Langs stereo test
 - Stereoscopic targets presented haploscopically in major amblyoscope
- ◆ Using 3 dimensional targets (e.g. Lang's two pencil test).
- ◆ Stereopsis tests may be qualitative or quantitative. Stereopsis is measured in seconds of arc.
 - Qualitative tests for Stereopsis
 - Lang's 2 pencil test
 - Synaptophore
 - Quantitative tests for Stereopsis
 - Random dot test
 - TNO Test
 - Lang's stereo test

Methods using Polarization: Targets are provided as vectographs and images seen by one eye is polarized at 90 degree using polarized glasses.

- ◆ Titmus stereo fly test
- ◆ Polaroid test
- ◆ Random dot stereograms
- ◆ TNO test

Stereograms: Stereogram with three concentric circles and a check dot for each eye is to be seen with both eyes together. Stereograms with three eccentric circles are to be seen with each eye separately. If the patient reports seeing concentric circles, it means stereopsis is present. If they are seen eccentrically one may ask whether the inner circles are closer to the right or left of the outer circle. It determines whether the disparate elements are suppressed in the right or the left eye.

Vectographs: Consists of Polaroid material on which the two targets are imprinted so that each target is polarized at 90 degrees with respect to the other. Patient is provided with Polaroid spectacles so that each target is seen separately with the two eyes.

Titmus stereo test – A gross stereoscopic pattern representing a housefly is provided to orient the patient and check for gross stereopsis (threshold 3000 sec of arc). Can be used in young children. Disadvantage of this test is that it can test only near stereopsis.

Polaroid test – Two common types

1. Contain three rows of animals, one animal in each row imaged disparately (threshold 100, 200 and 400 sec. of arc respectively). The child is asked which one of the animals stands out. The animal figures contain a misleading clue. In each row one of the animals correspondingly imaged in two eyes is printed heavily black. A child without stereopsis will name this animal as the one that stands out.
2. Contains nine sets of four circles arranged in the form of a diamond. In this sequence the upper, lower, left or right are disparately imaged at random with thresholds ranging from 800 to 40 sec of arc. The child is now asked to push down the circle that stands out, beginning with the first set. A child with limited stereopsis will make mistakes or find no circle to push down.

E- Random Dot Test - This test consists of two cards, one with an 'E' stereo figure and the other stereoblank. A model of the figure is shown to the child before the test. The child is provided with Polaroid glasses and seated at 50 cms from the cards is required to point out the card which contains the "E".

Random Dot Stereogram of Julesz - Random dot stereogram, when viewed monocularly, convey no visual information and is seen as scattered random dots. When viewed binocularly, a square pattern appears in vivid depth above or below the level of the page. This test exposes the child to visual demands that are more difficult than those that occur under more casual conditions of seeing.

References

1. Kaufman FL, Alm A, Adler FH: *Adler's physiology of eye: clinical application*, 10th Ed. St Louis: Mosby, 2003.
2. Noorden GK von. *Binocular vision and ocular motility: theory and management of strabismus*, 5th Ed. St Louis: Mosby, 1996.
3. *Duane's Clinical Ophthalmology*. New York: Lippincott Williams & Wilkins, 2005.

Suggested Citation Format

Bhola R. Binocular Vision. EyeRounds.org. Jan 23, 2006; Available from <http://eyerounds.org/tutorials/Bhola-BinocularVision.htm>

last updated: 01-23-2006, reviewed for accuracy January 6, 2013

Tutorials

Retina & Vitreous

Intravitreal Injection Technique

A Primer for Ophthalmology Residents and Fellows

Lorraine Myers (Provencher), MD, David Almeida, MD, PhD, Michael D. Abràmoff, MD, PhD

January 6, 2015

Purpose

Treatment of retinal disease by intravitreal injection (IVI) has revolutionized the field of ophthalmology. It is estimated that over four million IVIs were performed in the United States in 2013, a number that is expected to continue to increase [1]. This procedure, considered a subspecialty skill, is increasingly performed in the office of comprehensive ophthalmologists, especially for the treatment of common eye diseases like choroidal neovascularization in age-related macular degeneration. Given the risk of complications, especially endophthalmitis and suprachoroidal hemorrhage, and the need to handle these complications, IVI by generalists is controversial and even opposed by some vitreoretinal specialists [2]. While this "scope of practice" debate continues on, ophthalmology residency programs are now training their residents to properly perform IVIs as part of a comprehensive curriculum. Unfortunately, a wide variety of IVI protocols exist in terms of aseptic technique, anesthetics, use of prophylactic antibiotics, and post-injection monitoring.

This article is intended to be a resource and primer for ophthalmology residents learning IVI. We aim to present a helpful, concise review of recent evidence surrounding IVI technique and describe IVI protocols at the Iowa City Veterans Affairs hospital and the University of Iowa.

IVI Complications: Why we debate protocol in the first place...

Common complications of IVI are injection site discomfort, subconjunctival (SC) hemorrhage, vitreous reflux, and transient elevation of intraocular pressure (IOP). Patients may also develop floaters, vitreous or retinal hemorrhage, and retinal detachment. The most dreaded complication of IVI, though rare, is endophthalmitis (EO), and much of IVI protocol is designed to minimize, or eliminate, EO due to human error. EO rates reported in large multi-center randomized controlled trials of anti-vascular endothelial growth factor (anti-VEGF) IVI range from 0.019% [3] to 0.09% [4] per injection.

Close examination of the events surrounding historical large outbreaks of infectious EO suggest that these outbreaks were not a result of the drug or the injection technique, but rather of the pharmacological compounding procedures used to prepare the syringes containing the drug. Noncompliance with standards and poor aseptic technique were the most likely cause, and implementation of and strict adherence to United States Pharmacopoeia requirements has since been emphasized [5]. "Areas for improvement" that remain are much of what this article will discuss.

Location: Where should IVI be performed?

IVIs are generally performed in the office. In fact, many papers on IVI do not mention the setting, as in-office IVI is assumed. However, performing IVI in the operating room (OR), a more controlled and sterile environment, may decrease EO incidence... but at considerable cost.

EO rates after IVI performed in the OR are very low. In 2014, a retrospective study of two Swiss eye hospitals of 40,011 IVIs, all performed in the OR, reported just three cases of EO for a rate of 0.0075% [6]. The only major procedural difference between the two hospitals was the use of post-operative antibiotics at one hospital, accounting for approximately 13,337 IVIs and two of the three EO cases. This study was limited by its lack of a control group. These EO rates for IVI performed in the OR could be loosely compared to the prospective and randomized CATT 2-year results of 12,886 office-based injections where EO rates were approximately 0.09% [7]. A retrospective series of 14,895 office-based IVIs, by Cheung *et al.*, reported EO rates of 0.057% [8]. Another retrospective study of 10,254 office-based IVIs, by Pilli *et al.*, reported 0.029% [9].

A 2012 report of a single-surgeon cohort study from Australia of 12,249 IVIs showed a statistically significant difference in EO incidence rates for IVIs performed in the office procedure room (0.12%) versus OR (0%) [10]. However, results were limited by a lack of randomization.

A more recent 2014 retrospective review by Tabandeh *et al.* compared EO rates for all patients who underwent IVI from 2009-2011 by two ophthalmologists (retinal specialists), one who performed IVI in the office and the other in the OR [11]. They included 11,710 IVI: 8,647 office-based and 3,063 performed in the OR. Of note, office-based IVI were done without a mask and with no limitation on conversation. There was no significant difference in the rate of EO between the office-based (0.035%) and OR (0.065%).

Based on the most recent data, OR-based injections have very low rates of EO. These rates, however, do not appear to be significantly less than rates for office-based injections. A large, randomized controlled trial comparing the two settings has yet to be published. Moving IVI to the OR would increase running costs, time per patient treated, and overall inconvenience to the patient. With so many patients requiring IVIs, the need to treat the underlying disease may outweigh the additional risk profile of in-office injections. For now, the majority of IVIs are performed in the office.

Lid Retraction Technique

The main goal of lid retraction is to avoid needle contamination by the lashes via involuntary/reflex lid closure during needle insertion. The first anti-VEGF study clearly showed an increase in complications when no retractor was used [12]. Sterility, ease of use, exposure, and patient comfort are all considerations. The majority of ophthalmologists use metal lid retractors [13], but several other mechanisms have been proposed, such as bimanual assisted eyelid retraction [14], conjunctival mold [15], upper lid retraction using a Desmarres retractor [16] and most recently, cotton-tipped applicator lid retraction [17]. No literature compares various retraction techniques and post-IVI complications, particularly EO.

Anesthesia

The primary goals of anesthesia are 1) prevent patient movement and involuntary lid closure during needle insertion and 2) increase patient comfort and patient compliance for a procedure that needs to be repeated frequently. Many approaches to ocular surface anesthesia have been reported and include topical drops, anesthetic-soaked applicators, gels, and SC injection of anesthetics. Most reported data show: 1) Topical anesthesia and SC anesthesia are no different, but SC anesthesia may have more side effects like SC hemorrhage. 2) Various forms of topical anesthesia are no different.

A study by Blaha *et al.* demonstrated no difference in pain score between proparacaine drops, tetracaine drops, lidocaine-soaked, cotton-tipped swabs, and SC lidocaine. SC lidocaine had the most side effects [18]. Another study found IVI to be less painful with SC injection, but when the pain from the SC injection was included, pain scores were no different than with topical anesthesia [19]. A study comparing proparacaine 0.5% drops, proparacaine + 4% lidocaine-soaked, cotton-tipped swabs, and 3.5% lidocaine gel found no difference in pain or burning scores [20].

One concern is that gel anesthetic may reduce the efficacy of ocular surface antisepsis (discussed in the next section). When povidone-iodine (PI) and lidocaine gel are inocu-

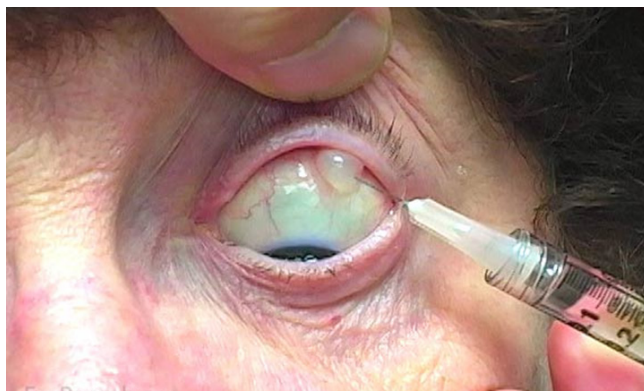

Figure 1: Subconjunctival injection, showing the injection of 0.2-0.4 mL of SC lidocaine in the superotemporal quadrant using a 1 mL syringe with a 30-gauge needle.

lated into culture media with bacteria, the same amount of bacteria grow as with lidocaine gel alone [21]. Another similar study confirmed these results but also found that PI applied for 5-30 seconds prior to lidocaine gel is as effective as PI alone [22]. Meaning, if gel is used, it should be applied after PI.

Topical Antisepsis

In a 2011 survey of 765 retinal specialists, > 99% use PI prior to IVI [13]. It is cheap, has broad-spectrum coverage over a range of concentrations, a fast kill-time (15-120 seconds), no reported resistance, and no reports of anaphylaxis [23]. If it is inadvertently "pushed" into the eye during injection, it should cause no harm to the eye [24].

- ◆ **Concentration:** A prospective, randomized study of 131 eyes by Friedman *et al.* showed that 5% PI for 30 seconds achieves a significant reduction in bacterial colonies formed [25].
- ◆ **Instillation vs Irrigation:** The Royal College of Ophthalmologists recommends irrigation of 5% PI in the conjunctival sac prior to cataract surgery [26]. The American Academy of Ophthalmology recommends 5% PI drops by instillation [27]. In a prospective controlled trial of 200 eyes undergoing anterior segment intraocular surgery, irrigation of the fornices with 5% PI was associated with significantly fewer positive conjunctival cultures compared to application of two drops on the conjunctiva [28].

While chlorhexidine may be more effective than PI when used in other settings, alcoholic chlorhexidine is toxic to the corneal epithelium. Aqueous chlorhexidine is safe and could be used in the setting of PI allergy [29].

To Mask or Not to Mask

Streptococci are reported to comprise 7% of the conjunctival flora [30]. In a report of 52 cases of EO, occurring in 105,536 IVIs, Staphylococci were responsible for 65% of cases and streptococci 31% [31]. A 2011 meta-analysis of most major US studies from 2005-2010 of EO after IVI of anti-VEGF agents reported streptococcal species were approximately three times more commonly the cause of post-IVI EO than post-intraocular surgery, where masks are worn [31]. This over-representation of streptococcus is believed to come from the oral cavity of either healthcare providers or the patient.

Wen *et al.* simulated an IVI under different conditions and found significantly more colony-forming bacteria are dispersed onto an agar plate when patients were speaking without a face mask compared with when wearing a face mask or remaining silent. They also found that speaking in a reclined position (in an ophthalmic exam chair, reclined so that the patient's face is parallel to the floor) results in significantly MORE colony-forming bacteria on the culture plate (placed on the forehead) than on the background control plate [32]. This indicates that a fully reclined, unmasked patient may disperse bacteria towards the eyes. There is currently no published data on masked

and reclined patients and whether this would increase or decrease contamination. In the OR, a patient's nasopharyngeal area is typically covered by an adhesive drape to isolate the eye and periorbital region. It is unlikely that a simple surgical mask would be as efficacious.

A study of ten surgeons reciting a 30-second script in four different scenarios compared bacterial growth on a blood agar plate with no facemask, the use of a standard surgical facemask, no mask but 5% PI pre-treated plate, and no mask but silence. There was significantly less bacterial growth for the facemask group and silence group compared to no mask, but pre-treated PI plates, even without facemask, demonstrated the least bacterial growth overall [33]. Conversely, a study of needle contamination between unmasked talking versus silent breathing over a sterile needle for 30 seconds found no significant difference between needle cultures, suggesting there may be no need for silence during IVI [34]. This study, however, was limited by a very small sample size.

Shimada *et al.* published an efficacy report for IVI protocol at a single university hospital, where all anti-VEGF IVIs over 3 years (15,144 injections) were done with doctors and nurses wearing surgical masks, eyelid skin disinfected with 10% PI and conjunctiva with 0.25% PI, patients' faces were draped, and the conjunctival surface was washed with 5 ml of 0.25% PI, waiting 30 seconds before IVI. Post-IVI site was washed again and patients received three days of levofloxacin. EO rates were zero. Without a control group, unfortunately, it is impossible to know if results are related to masks, draping, antibiotics, or some other variable [35].

Despite simulation studies demonstrating reduced contamination of culture plates with masking and silence, wearing a facemask is still not considered a uniform standard in the ophthalmology community. Because of the sheer volume of IVI annually, the addition of facemasks for physicians and staff assisting in IVI would amount to an astounding increase in healthcare costs, up to \$1.5 million annually [35].

Needle Size and Injection Technique: What needle to use...and how to use it.

A variety of options exist. The needle gauge used for IVI, the angle of needle insertion (or "incision"), the depth of insertion, and the speed of insertion and how these variables affect drug reflux, needle contamination, vitreous incarceration, pain, scleral damage, and drug delivery have all been reported.

Several comparative studies of human eyes undergoing IVI report that vitreous reflux (measured by the size of post-IVI subconjunctival bleb) is significantly lower in tunneled scleral injection when compared to straight injection techniques [36-39]. There appears to be no difference in patient discomfort between tunneled and straight techniques [36,38], and there was no difference in IOP spike at 5 minutes after injection [38]. A more recent prospective study, by Özkaya *et al.*, compared the effects of straight, oblique, and double-plane tunnel scleral IVI, on short-term

IOP changes, vitreous reflux, and other complications [40]. They found that double-plane tunneled IVI prevents VR from the injection site and has no more complications than alternative techniques (Figure 2).

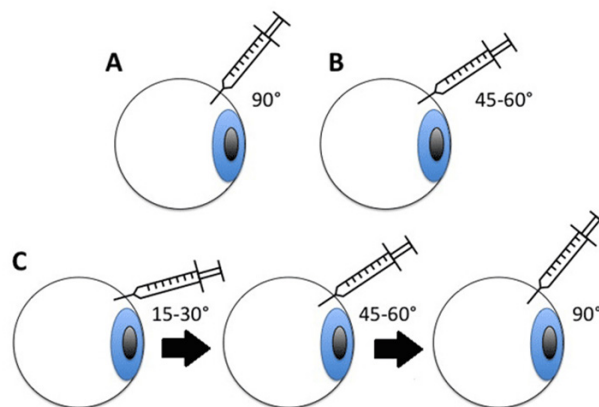


Figure 2: Schematic illustration of three different needle path penetration techniques—(A) perpendicular or straight, (B) oblique, and (C) double-plane tunnel, where the sclera is penetrated at 15-30°, then the needle is repositioned to a 45-60° angle while sclera is still engaged (this creates a tunnel in two separate planes). The drug is delivered and then the needle is withdrawn at 90°.

Larger 26- and 27-gauge needles are reported to cause greater vitreous reflux in comparison to 29- and 30-gauge needles. However, the width of the needle significantly affected the degree of reflux only when using the non-beveled incision [36]. Another study of IVI on porcine eyes found that 30-gauge needles showed less drug reflux than 32-gauge or 27-gauge. Thirty-two-gauge needles demonstrated less incarceration of vitreous at the tract site, but all needle tracts showed some internal vitreous incarceration (Figure 3). Deep IVI showed less reflux than superficial, but vitreous incarceration did not differ. Speed of injection did not modify the reflux or the vitreous incarceration [41]. Patients injected with the 26- or 27-gauge needle experienced more pain matched to the 29- and 30-gauge needles [36].

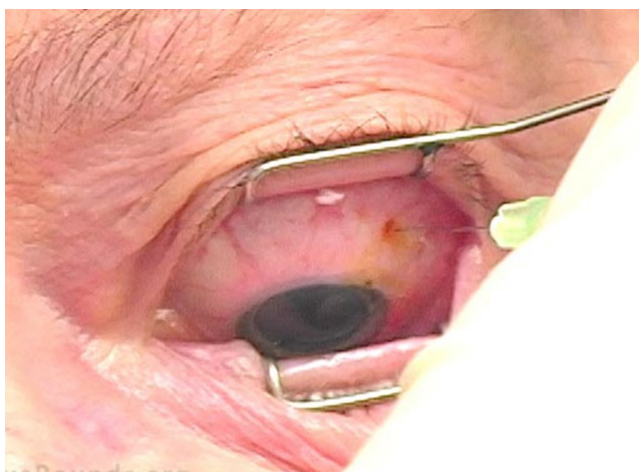

Figure 3: Intravitreal injection using straight technique and a 32-gauge needle.

A study analyzing the effects of various needles on porcine eyes found less ocular damage and smaller scleral holes with increased needle gauge for both perpendicular (or straight) and tunneled injection. Statistical analysis of data showed higher probability of scleral opening reduction when a tunneled incision was used [39]. The same study found that residual drug volume was lower in small syringes of 0.3 mL connected to long 12.7-mm needles, implying that the popular use of 1-mL syringes may not be most appropriate. Needle size appears not to be a risk factor for contamination during IVT injection [42].

The IOP Spike

The mechanism of post-IVI elevation in IOP is likely due to increased volume of intraocular contents [43]. The spike is usually transient. Gismondi *et al.* found a significant difference in pre-IVI IOP and post-IVI IOP after five seconds to 30 minutes but not after one hour or one day [44]. Several other studies report similar findings, with most patients measuring increased IOP compared to baseline at 30 minutes post-IVI and then normal IOP by one week of follow-up [45]. Interestingly, there appears to be no difference in IOP for the type of medication injected, which often vary in volume [46]. There may be a relationship between axial length and very transient post-IVI spike in IOP, but data are conflicting. Gismondi *et al.* found a significant relationship between shorter axial length and post-ranibizumab IOP after five seconds but not one hour [44]. A more recent study using bevacizumab showed shorter eyes had a higher IOP at one and 15 minutes post-IVI [47]. Goktas *et al.*, however, found no relationship between axial length or anterior chamber depth and post-ranibizumab IOP [48].

Strategies to prevent the IOP spike, temporary artery occlusion, and loss of vision

- ◆ Prophylactic IOP-lowering medications are ineffective at preventing IOP spikes post-pegaptanib, ranibizumab, and bevacizumab, as increased IOP persists in the setting of pre-IVI IOP-lowering drops [49].
- ◆ A few studies have investigated use of the Honan Intraocular Pressure Reducer (HIPR) to prevent post-IVI pressure spikes. A prospective, controlled, investigator-blinded, randomized clinical study of 60 eyes showed that HIPR effectively decreased pre-IVI IOP but post-IVI IOP was not significantly different in eyes that underwent pre-IVI HIPR compared to controls. Pre-IVI use of HIPR did appear to reduce vitreous reflux [50]. Conversely, an earlier prospective, controlled, non-randomized study of 60 eyes showed lower post-IVI IOP in the HIPR group at 10 minutes compared to a non-HIPR group. HIPR did NOT appear to reduce vitreous reflux in this report [51].
- ◆ Ocular digital massage is a technique often employed in the management of glaucoma. A small non-randomized study showed that eyes receiving pre-IVI, intermittent

digital massage for 5 minutes had significantly lower IOP immediately following and 10 minutes after IVI compared to eyes that did not receive ocular massage [52].

Occasionally, post-IVI IOP remains elevated. The exact mechanism of sustained ocular hypertension is controversial. Though sustained elevation in IOP is reported to occur in patients with no prior history of glaucoma, glaucoma suspect, or ocular hypertension (OHT), some studies suggest that patients with glaucoma may experience sustained IOP elevation at a greater rate than those without an existing diagnosis of glaucoma or OHT [45].

As with any other cause (or unknown cause) of elevated IOP, concern surrounds potential damage to the optic nerve resulting from decreased perfusion. Post-IVI temporary occlusion of central retinal artery, which quickly resolved with anterior paracentesis, has been reported [53]. In a 2011 survey of United States retinal specialists, nearly three-fourths of survey respondents (72%) routinely assess post-IVI optic nerve perfusion in some way. Of these, 32% perform a gross visual acuity examination by finger counting (Figure 4) or hand motion assessment, 21% visualize the optic nerve by indirect ophthalmoscopy, 15% measure the IOP, and 31% use a combination of these techniques [13].

Post IVI Antibiotics

The use of topical antibiotics is standard after ocular surgery. This principle was carried over to IVI, and logically so. In a 2011 survey of AAO retinal specialists, 81% (608/753) of respondents reported using post-IVI prophylactic antibiotics [13]. Topical antibiotics do reduce conjunctival bacterial growth [30], but no randomized controlled trials show a reduction in EO with post-IVI antibiotic use.

A low rate of EO can be achieved without topical antibiotics. Bhavsar *et al.* reported EO rates based on protocol requiring topical PI, sterile lid speculum, and topical anesthetic across four DRCR.net randomized trials. No topical antibiotics, sterile gloves, or sterile drapes were used. Of 8,027 IVIs, seven cases of EO occurred, and six of these seven received antibiotics [4].

A retrospective case control study of 117,171 IVI with or without antibiotics, reported that antibiotics do not seem to reduce EO but are actually associated with a trend toward higher incidence of EO, though the increased risk (odds ratio 1.54) was not statistically significant [54].

In a retrospective review of 15,895 IVIs of ranibizumab, bevacizumab, triamcinolone acetonide, or pegaptanib sodium where 9 eyes of 9 patients developed suspected EO (only 3 were culture positive), the incidence per injection was 0.06% for patients who were given 5 days of post-IVI antibiotics, 0.08% for those who received antibiotics immediately after IVI, and 0.04% for those receiving no antibiotics. However, statistical significance was not demonstrated [8].

Use of topical antibiotics may lead to increase in resistant organisms. Dave *et al.* demonstrated that eyes treated with

post-IVI topical fluoroquinolones develop multi-drug resistant conjunctival flora (90% *S. epidermidis*) compared to controls (69% *S. epidermidis*) after just four IVIs ($p < 0.02$) [55]. Similarly, Milder *et al.* found that treated eyes had 87.5% resistance to fluoroquinolones compared to 25% in controls ($P = 0.04$) [56]. In a non-randomized, prospective cohort study by Vin *et al.*, the group receiving three days of post-IVI topical moxifloxacin had a higher culture-positive rate at one, two, and three months compared to the control group. MIC levels increased by 20% in the intervention group compared to a 5% decrease in the control group, and resistant isolates and MIC90 were approximately four times higher in the intervention group [57].

In a prospective, controlled longitudinal study of 24 patients (48 eyes), Dave *et al.* reported *S. epidermidis* and *S. aureus* comprise 54.5% and 18.2% of cultured isolates, respectively, prior to azithromycin exposure, and 90.9% ($P < 0.01$) and 4.5% ($P < 0.01$), respectively, after azithromycin exposure. In another group, 45.7% and 6.5% of isolates are *S. epidermidis* and *S. aureus*, respectively, at baseline, then 63.4% ($P < 0.03$) and 13% ($P = 0.24$) after fluoroquinolone exposure [55].

The good news? Ocular surface preparation for IVI using PI 5% alone in the absence of post-injection topical antibiotics does not appear to promote bacterial resistance or a discernible change in conjunctival flora [58].

The Safety of Bilateral Injections

Many patients with bilateral disease, like choroidal neovascularization from age-related macular degeneration and diabetic macular edema, require IVI of both eyes. Same-day IVI is more convenient and cost-effective for patients, and many patients prefer bilateral injections [59]. Ophthalmologists must carefully weigh the risks and benefits of bilateral IVI. The most dreaded result of bilateral, same-day IVI is described in a 2013 case report of two patients who developed acute, bilateral EO following bilateral IVI [60].

A recent editorial by Chao *et al.* summarizes previous studies reporting bilateral, same-day IVI and associated EO incidence: From the University of Iowa, 102 patients, 452 injections, no EO [59]; From Bascom Palmer Eye Institute, 127 patients, 1,322 injections, no EO [61]; From a cohort in Korea, 135 patients, 574 injections, no EO [62]; From New York City cohort, 367 patients, 1,552 injections, one case of unilateral, culture-negative EO (0.033%) and two cases of culture-proven, unilateral EO (0.065%) [63]. They also give data from retina clinics at the Miami Veterans Affairs Hospital, where bilateral, same-day IVI are often performed, and performed by residents and fellows. From October 2007 to May 2014, 660 same-day, bilateral and 3,570 unilateral IVI were delivered. Patients undergoing same-day injections had each eye performed without reuse of any instruments or medications, meaning each eye was treated as though it belonged to a separate patient. There were zero cases of EO, and 438 of the 660 bilateral injections were delivered without topical antibiotics, as they discontinued use of topical antibiotics in August 2011. Masks, sterile gloves, and drapes were not used. They concluded,

based on the data presented and data reviewed, that bilateral, same-day injections are safe [64].

Our Protocol

The protocol described below is used at the Iowa City Veterans Affairs Medical Center (VAMC). There is minor variation in protocol at University of Iowa Hospitals and Clinics (UIHC), based primarily on specialist preference.

UIHC variation is shown in italics and portrayed in Video 1

Video: UIHC technique for intravitreal injection.
vimeo.com/116066821.

1. Put the patient in an exam chair reclined at 30 degrees.
2. Verify the correct patient, correct eye, and correct medication. If bilateral injections are to occur, make sure drug lot numbers are different, i.e. different compounding.
3. Draw up the medication in a 1 mL syringe with an 18-gauge filter needle, using sterile technique.
4. Exchange the needle for a 30-gauge, *or 32-gauge*, 0.5 inch needle.
5. Set up a sterile field on tray table.
6. Place 1 drop of proparacaine in the eye to be injected
7. Anesthesia:
 - a. Take two cotton swabs, soaked in 4% lidocaine, and hold over injection site for 60 seconds, repeat two more times.
 - b. Inject 0.2-0.4 mL of SC lidocaine in the superotemporal or inferotemporal quadrant using a 1 mL syringe with a 30-gauge needle.*
8. All medical personnel in the room should wear a mask, and the patient is asked not to speak during the procedure.
 - a. The patient is also asked to wear a mask for simultaneous, bilateral injections at the VAMC.
9. Put on sterile gloves.
10. Insert the lid speculum.
11. Drench the conjunctiva with PI using soaked cotton-tipped applicators. Massage the anterior chamber at the limbus with the cotton-tipped applicator when administering PI. Similar to ocular digital massage, this may evacuate the anterior chamber and reduce IOP, both pre-IVI and post-IVI. *Limbal massage is not done at UIHC.*
12. Mark a superotemporal injection site 3.5 mm from limbus using calipers, taking care to avoid trabeculec-tomy blebs if necessary.
13. Apply one drop of 5% PI to the injection site, and wait 30 seconds.

14. Apply one final drop of 5% PI to injection site, immediately followed by:
15. Injection by scleral tunnel technique, ensuring a smooth and gradual insertion of the needle.
 - a. *Inject directly into the eye (no scleral tunnel). Immediately cover the wound with a cotton-tipped applicator for 5 seconds after the medicine has been injected.*
16. Cover opposite eye and assess whether the patient can count fingers held directly in front of them.
17. Remove the eyelid speculum.
18. Verify the absence of central retinal artery pulsations by indirect ophthalmoscopy. If there are pulsations or reduced vision, check IOP with a Tonopen. *Post-IVI monitoring is not routinely performed at UIHC.*
19. Rinse the eye with 3 mL 0.9% sodium chloride, repeat two more times.

References

1. Williams GA. IVT Injections: Health Policy Implications, 2014. [rev. Jun 5, 2014; Accessed Oct 13, 2014] www.reviewofophthalmology.com/content/d/retinal_insider/c/48732/.
2. Karmel M. Community Eye M.D.s Tackle The Intravitreal Injection. *EyeNet Magazine* 2008;12(3):39-43.
3. Mason JO, 3rd, White MF, Feist RM, Thomley ML, Albert MA, Persaud TO, Yunker JJ, Vail RS. Incidence of acute onset endophthalmitis following intravitreal bevacizumab (Avastin) injection. *Retina* 2008;28(4):564-7.
4. Bhavsar AR, Stockdale CR, Ferris FL, 3rd, Brucker AJ, Bressler NM, Glassman AR, Diabetic Retinopathy Clinical Research N. Update on risk of endophthalmitis after intravitreal drug injections and potential impact of elimination of topical antibiotics. *Arch Ophthalmol* 2012;130(6):809-10.
5. Gonzalez S, Rosenfeld PJ, Stewart MW, Brown J, Murphy SP. Avastin doesn't blind people, people blind people. *Am J Ophthalmol* 2012;153(2):196-203 e1.
6. Casparis H, Wolfensberger TJ, Becker M, Eich G, Graf N, Ambresin A, Mantel I, Michels S. Incidence of presumed endophthalmitis after intravitreal injection performed in the operating room: a retrospective multicenter study. *Retina* 2014;34(1):12-7.
7. Comparison of Age-related Macular Degeneration Treatments Trials Research G, Martin DF, Maguire MG, Fine SL, Ying GS, Jaffe GJ, Grunwald JE, Toth C, Redford M, Ferris FL, 3rd. Ranibizumab and bevacizumab for treatment of neovascular age-related macular degeneration: two-year results. *Ophthalmology* 2012;119(7):1388-98.
8. Cheung CS, Wong AW, Lui A, Kertes PJ, Devenyi RG, Lam WC. Incidence of endophthalmitis and use of antibiotic prophylaxis after intravitreal injections. *Ophthalmology* 2012;119(8):1609-14.
9. Pilli S, Kotsolis A, Spaide RF, Slakter J, Freund KB, Sorenson J, Klanchnik J, Cooney M. Endophthalmitis associated with intravitreal anti-vascular endothelial growth factor therapy injections in an office setting. *Am J Ophthalmol* 2008;145(5):879-82.
10. Abell RG, Kerr NM, Allen P, Vote BJ. Intravitreal injections: is there benefit for a theatre setting? *Br J Ophthalmol* 2012;96(12):1474-8.
11. Tabandeh H, Boscia F, Sborgia A, Ciraci L, Dayani P, Mariotti C, Furino C, Flynn HW, Jr. Endophthalmitis associated with intravitreal injections: office-based setting and operating room setting. *Retina* 2014;34(1):18-23.
12. Gragoudas ES, Adamis AP, Cunningham ET, Jr., Feinsod M, Guyer DR, Group VISiONCT. Pegaptanib for neovascular age-related macular degeneration. *N Engl J Med* 2004;351(27):2805-16.
13. Green-Simms AE, Ekdawi NS, Bakri SJ. Survey of intravitreal injection techniques among retinal specialists in the United States. *Am J Ophthalmol* 2011;151(2):329-32.
14. Fineman MS, Hsu J, Spirn MJ, Kaiser RS. Bimanual assisted eyelid retraction technique for intravitreal injections. *Retina* 2013;33(9):1968-70.
15. Ratnarajan G, Nath R, Appaswamy S, Watson SL. Intravitreal injections using a novel conjunctival mould: a comparison with a conventional technique. *Br J Ophthalmol* 2013;97(4):395-7.
16. Mason RW. Use of a Desmarres retractor for upper lid and lash isolation during intravitreal injections. *Retina* 2013;33(10):2175-6.
17. Shrier EM. Cotton-tip applicator lid retraction technique for controlled intravitreal injection. *Retina* 2014;34(6):1244-6.
18. Blaha GR, Tilton EP, Barouch FC, Marx JL. Randomized trial of anesthetic methods for intravitreal injections. *Retina* 2011;31(3):535-9.
19. Kaderli B, Avci R. Comparison of topical and subconjunctival anesthesia in intravitreal injection administrations. *Eur J Ophthalmol* 2006;16(5):718-21.
20. Davis MJ, Pollack JS, Shott S. Comparison of topical anesthetics for intravitreal injections : a randomized clinical trial. *Retina* 2012;32(4):701-5.
21. Boden JH, Myers ML, Lee T, Bushley DM, Torres MF. Effect of lidocaine gel on povidone-iodine antisepsis and microbial survival. *J Cataract Refract Surg* 2008;34(10):1773-5.
22. Doshi RR, Leng T, Fung AE. Povidone-iodine before lidocaine gel anesthesia achieves surface antisepsis. *Ophthalmic Surg Lasers Imaging* 2011;42(4):346-9.
23. Wykoff CC, Flynn HW, Jr., Rosenfeld PJ. Prophylaxis for endophthalmitis following intravitreal injection: antisepsis and antibiotics. *Am J Ophthalmol* 2011;152(5):717-9 e2.

24. Whitacre MM, Crockett RS. Tolerance of intravitreal povidone-iodine in rabbit eyes. *Curr Eye Res* 1990;9(8):725-32.
25. Friedman DA, Mason JO, 3rd, Emond T, McGwin G, Jr. Povidone-iodine contact time and lid speculum use during intravitreal injection. *Retina* 2013;33(5):975-81.
26. *Cataract Surgery Guidelines*. London, England: The Royal College of Ophthalmologists, Scientific Department, 2010.
27. American Academy of Ophthalmology Cataract and Anterior Segment Panel. *Preferred Practice Pattern Guidelines: Cataract in the adult eye*. San Francisco, CA: American Academy of Ophthalmology, 2011.
28. Mino de Kaspar H, Chang RT, Singh K, Egbert PR, Blumenkranz MS, Ta CN. Prospective randomized comparison of 2 different methods of 5% povidone-iodine applications for anterior segment intraocular surgery. *Arch Ophthalmol* 2005;123(2):161-5.
29. Hamill MB, Osato MS, Wilhelmus KR. Experimental evaluation of chlorhexidine gluconate for ocular antisepsis. *Antimicrob Agents Chemother* 1984;26(6):793-6.
30. Moss JM, Sanislo SR, Ta CN. A prospective randomized evaluation of topical gatifloxacin on conjunctival flora in patients undergoing intravitreal injections. *Ophthalmology* 2009;116(8):1498-501.
31. McCannel CA. Meta-analysis of endophthalmitis after intravitreal injection of anti-vascular endothelial growth factor agents: causative organisms and possible prevention strategies. *Retina* 2011;31(4):654-61.
32. Wen JC, McCannel CA, Mochon AB, Garner OB. Bacterial dispersal associated with speech in the setting of intravitreal injections. *Arch Ophthalmol* 2011;129(12):1551-4.
33. Doshi RR, Leng T, Fung AE. Reducing oral flora contamination of intravitreal injections with face mask or silence. *Retina* 2012;32(3):473-6.
34. Friedman DA, Lindquist TP, Mason JO, 3rd, McGwin G. Needle contamination in the setting of intravitreal injections. *Retina* 2014;34(5):929-34.
35. Schimel AM, Scott IU, Flynn HW, Jr. Endophthalmitis after intravitreal injections: should the use of face masks be the standard of care? *Arch Ophthalmol* 2011;129(12):1607-9.
36. Rodrigues EB, Grumann A, Jr., Penha FM, Shiroma H, Rossi E, Meyer CH, Stefano V, Maia M, Magalhaes O, Jr., Farah ME. Effect of needle type and injection technique on pain level and vitreal reflux in intravitreal injection. *J Ocul Pharmacol Ther* 2011;27(2):197-203.
37. Rodrigues EB, Meyer CH, Grumann A, Jr., Shiroma H, Aguni JS, Farah ME. Tunneled scleral incision to prevent vitreal reflux after intravitreal injection. *Am J Ophthalmol* 2007;143(6):1035-7.
38. Knecht PB, Michels S, Sturm V, Bosch MM, Menke MN. Tunnelled versus straight intravitreal injection: intraocular pressure changes, vitreous reflux, and patient discomfort. *Retina* 2009;29(8):1175-81.
39. De Stefano VS, Abechain JJ, de Almeida LF, Verginassi DM, Rodrigues EB, Freymuller E, Maia M, Magalhaes O, Nguyen QD, Farah ME. Experimental investigation of needles, syringes and techniques for intravitreal injections. *Clin Experiment Ophthalmol* 2011;39(3):236-42.
40. Ozkaya A, Alkin Z, Celik U, Yuksel K, Ozgurhan EB, Agca A, Yazici AT, Demirok A. Comparing the effects of three different intravitreal injection techniques on vitreous reflux and intraocular pressure. *J Ocul Pharmacol Ther* 2013;29(3):325-9.
41. Hubschman JP, Coffee RE, Bourges JL, Yu F, Schwartz SD. Experimental model of intravitreal injection techniques. *Retina* 2010;30(1):167-73.
42. Tufan HA, Vural A, Gencer B, Kara S, Arikan S, Yuksel E. Bacterial contamination of needles used for intravitreal injections: comparison between 27-gauge and 30-gauge needles. *Ocul Immunol Inflamm* 2013;21(5):366-70.
43. Kotliar K, Maier M, Bauer S, Feucht N, Lohmann C, Lanzl I. Effect of intravitreal injections and volume changes on intraocular pressure: clinical results and biomechanical model. *Acta Ophthalmol Scand* 2007;85(7):777-81.
44. Gismondi M, Salati C, Salvetat ML, Zeppieri M, Brusini P. Short-term effect of intravitreal injection of Ranibizumab (Lucentis) on intraocular pressure. *J Glaucoma* 2009;18(9):658-61.
45. SooHoo JR, Seibold LK, Kahook MY. The link between intravitreal antivascular endothelial growth factor injections and glaucoma. *Curr Opin Ophthalmol* 2014;25(2):127-33.
46. Bakri SJ, Pulido JS, McCannel CA, Hodge DO, Diehl N, Hillemeier J. Immediate intraocular pressure changes following intravitreal injections of triamcinolone, pegaptanib, and bevacizumab. *Eye (Lond)* 2009;23(1):181-5.
47. Cacciamani A, Oddone F, Parravano M, Scarinci F, Di Nicola M, Lofoco G. Intravitreal injection of bevacizumab: changes in intraocular pressure related to ocular axial length. *Jpn J Ophthalmol* 2013;57(1):63-7.
48. Goktas A, Goktas S, Atas M, Demircan S, Yurtsever Y. Short-term impact of intravitreal ranibizumab injection on axial ocular dimension and intraocular pressure. *Cutan Ocul Toxicol* 2013;32(1):23-6.
49. Frenkel MP, Haji SA, Frenkel RE. Effect of prophylactic intraocular pressure-lowering medication on intraocular pressure spikes after intravitreal injections. *Arch Ophthalmol* 2010;128(12):1523-7.
50. Hong SW, Jee D. Effect of the Honan intraocular pressure reducer to prevent vitreous reflux after intravitreal bevacizumab injection. *Eur J Ophthalmol* 2012;22(4):615-9.
51. Kim KS, Jee D. Effect of the Honan intraocular pressure reducer on intraocular pressure increase following intravitreal injection using the tunneled scleral technique. *Jpn J Ophthalmol* 2011;55(6):632-7.

52. Lee J, Hwang JH, Park YS, Lee YJ, Lee BR. Preoperative ocular massage to lower the immediate intraocular pressure spike following intravitreal triamcinolone acetonide injection. *Investigative Ophthalmology & Visual Science* 2005;46(5):1454.
53. Baath J, Ells AL, Crichton A, Kherani A, Williams RG. Safety profile of intravitreal triamcinolone acetonide. *J Ocul Pharmacol Ther* 2007;23(3):304-10.
54. Storey P, Dollin M, Pitcher J, Reddy S, Vojtko J, Vander J, Hsu J, Garg SJ, Post-Injection Endophthalmitis Study T. The role of topical antibiotic prophylaxis to prevent endophthalmitis after intravitreal injection. *Ophthalmology* 2014;121(1):283-9.
55. Dave SB, Toma HS, Kim SJ. Changes in ocular flora in eyes exposed to ophthalmic antibiotics. *Ophthalmology* 2013;120(5):937-41.
56. Milder E, Vander J, Shah C, Garg S. Changes in antibiotic resistance patterns of conjunctival flora due to repeated use of topical antibiotics after intravitreal injection. *Ophthalmology* 2012;119(7):1420-4.
57. Yin VT, Weisbrod DJ, Eng KT, Schwartz C, Kohly R, Mandelcorn E, Lam WC, Daneman N, Simor A, Kertes PJ. Antibiotic resistance of ocular surface flora with repeated use of a topical antibiotic after intravitreal injection. *JAMA Ophthalmol* 2013;131(4):456-61.
58. Hsu J, Gerstenblith AT, Garg SJ, Vander JF. Conjunctival flora antibiotic resistance patterns after serial intravitreal injections without postinjection topical antibiotics. *Am J Ophthalmol* 2014;157(3):514-8 e1.
59. Mahajan VB, Elkins KA, Russell SR, Boldt HC, Gehrs KM, Weingeist TA, Stone EM, Abramoff MD, Liu D, Folk JC. Bilateral intravitreal injection of antivascular endothelial growth factor therapy. *Retina* 2011;31(1):31-5.
60. Tabatabaie A, Ahmadraji A, Khodabande A, Mansouri M. Acute bilateral endophthalmitis following bilateral intravitreal bevacizumab (avastin) injection. *Middle East Afr J Ophthalmol* 2013;20(1):87-8.
61. Davis RP, Scheffler AC, Murray TG. Concomitant bilateral intravitreal anti-VEGF injections for the treatment of exudative age-related macular degeneration. *Clin Ophthalmol* 2010;4:703-7.
62. Woo SJ, Han JM, Ahn J, Heo JW, Yu HG, Chung H, Song J, Park KU, Park KH. Bilateral same-day intravitreal injections using a single vial and molecular bacterial screening for safety surveillance. *Retina* 2012;32(4):667-71.
63. Lima LH, Zweifel SA, Engelbert M, Sorenson JA, Slakter JS, Cooney MJ, Klancknik JM, Yannuzzi LA, Freund KB. Evaluation of safety for bilateral same-day intravitreal injections of antivascular endothelial growth factor therapy. *Retina* 2009;29(9):1213-7.
64. Chao DL, Gregori NZ, Khandji J, Goldhardt R. Safety of bilateral intravitreal injections delivered in a teaching institution. *Expert Opin Drug Deliv* 2014;11(7):991-3.

Citing this article

Myers (Provencher) LA, Almeida D, Abramoff MD. Intravitreal Injection Technique: A Primer for Ophthalmology Residents and Fellows. EyeRounds.org. January 6, 2015; Available from: EyeRounds.org/tutorials/intravitreal-injection/

last updated: 01/06/2015

Full-Thickness Macular Hole (FTMH)

Ben J. Janson, MD and Ian C. Han, MD

posted November 22, 2017

CASE PRESENTATION

Chief Complaint

"My vision is blurry and distorted."

History of Present Illness

The patient is a 68-year-old female with a history of non-exudative macular degeneration referred for vision changes. She began to notice increased difficulty reading due to blurry vision and distortion of vision in the right eye (OD) about 6 months prior to presentation. The left eye (OS) was unchanged. She had no previous history of exudative macular degeneration.

Past Ocular History

Non-exudative macular degeneration of both eyes (OU), nuclear sclerosis cataracts OU

Past Medical History

Hypertension, gastroesophageal reflux disease (GERD), hemifacial spasm with facial nerve release, carpal tunnel syndrome, bilateral knee replacements

Medications

AREDS vitamins, hydrochlorothiazide, propranolol, ranitidine

Allergies

Non-steroidal anti-inflammatory drugs (NSAIDs)

Family History

Non-contributory

Social History

Non-contributory

Review of Systems

Negative except for what is detailed in the history of present illness

OCULAR EXAMINATION

Visual Acuity with correction by Snellen chart

- ◆ OD: 20/80-1 eccentrically (pinhole no improvement)
- ◆ OS: 20/20-2 (pinhole no improvement)

Ocular Motility/Alignment

- ◆ Full ocular motility OU, orthophoria in primary gaze

Intraocular Pressure (by Tonopen)

- ◆ OD: 17 mmHg
- ◆ OS: 17 mmHg

Pupils

- ◆ OD: 4 mm in dark, 3 mm in light, no relative afferent pupillary defect (RAPD)
- ◆ OS: 4 mm in dark, 3 mm in light, no RAPD

External

Normal

Slit lamp exam

- ◆ Lids/lashes: Normal OU
- ◆ Conjunctiva/sclera: Clear and quiet OU
- ◆ Cornea: Clear OU
- ◆ Anterior chamber: Deep and quiet OU
- ◆ Iris: Normal architecture OU
- ◆ Lens: 2+ nuclear sclerosis OU

Dilated fundus examination (DFE)

- ◆ Vitreous: No posterior vitreous detachment (PVD) OU
- ◆ Disc: Normal OU
- ◆ Cup-to-disc ratio: 0.2 OU
- ◆ Macula: 400 micron full-thickness macular hole OD. Pigment mottling and fine drusen OS.
- ◆ Vessels: Normal OU
- ◆ Periphery: Reticular pigment change OU

Additional Testing

- ◆ Spectralis ocular coherence tomography (OCT) OD: presence of full-thickness macular hole with interstitial and subretinal fluid. (Figure 1, next page)

Differential Diagnosis

- ◆ Full-thickness macular hole (primary or secondary)
- ◆ Lamellar macular hole
- ◆ Pseudohole

DIAGNOSIS

Full-thickness macular hole (FTMH) OD

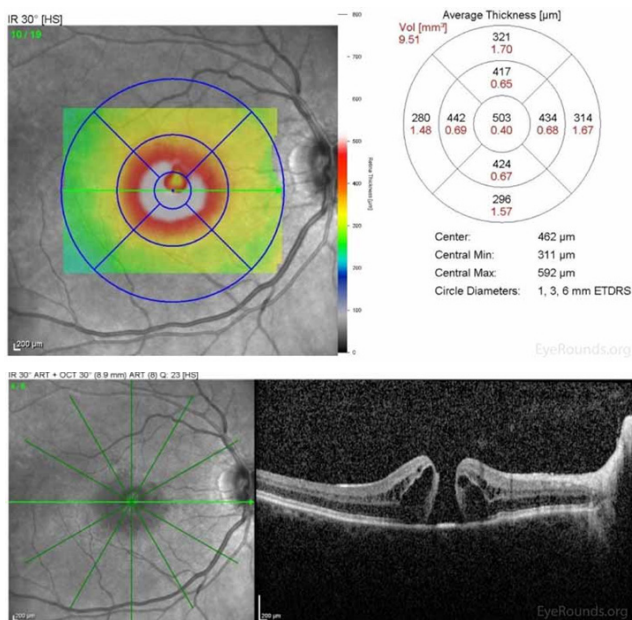


Figure 1: Spectralis ocular coherence tomography (OCT) of the macula OD on initial presentation demonstrating the presence of a full-thickness macular hole with interstitial and subretinal fluid.

CLINICAL COURSE

The patient underwent 23-gauge pars plana vitrectomy, epiretinal membrane (ERM) peel, fluid-air exchange, 25% sulfur hexafluoride (SF6) OD. At the one-month post-operative visit, the patient's vision with correction had improved from 20/80-1 eccentrically to 20/60-2 eccentrically. On OCT images there was interval closure of the macular hole (Image Set 2). Vision ultimately returned to 20/30 over six months and was stable five years later.

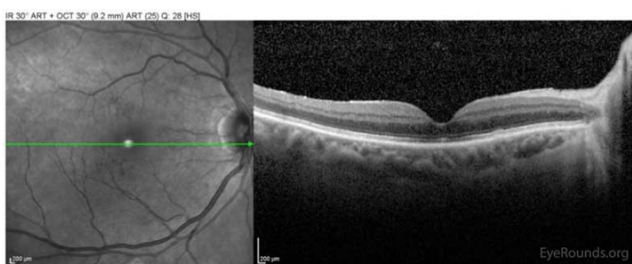

Figure 2: Spectralis OCT of the macula OD at the one-month post-operative visit demonstrating interval closure of the macular hole.

DISCUSSION

Etiology/Epidemiology

FTMHs are a relatively uncommon problem of the retina with a reported prevalence of 0.2 per 1000 persons in the Blue Mountains Study and to up to 3.3 per 1000 persons in the Baltimore Eye Study.[1] Incidence is 8 per 100,000 persons per year.[2] There is bilateral involvement in 5-20% of cases, but FTMHs rarely present simultaneously.[1-3]

FTMHs occur most in the 6th and 7th decades of life and have a female:male incidence of 2:1.[2,3] It is unknown why females are more likely to have a FTMH in this age-related, idiopathic disease.

Pathophysiology

FTMHs were first described in 1869 by Knapp.[1] Initially, the pathophysiology was believed to be degenerative, and hence the early name by Kuhnt was "retinitis atrophicansive rarificans centralis." [4] The understanding of the pathophysiology has expanded as examination techniques improved and with the advent of OCT.[1] FTMHs are currently divided into primary and secondary macular holes based on etiology.[1]

Vitreomacular traction plays a major role in the formation of primary FTMHs.[1,4,5] Gass, in his descriptions of the stages of macular holes, hypothesized that the shrinking of prefoveal vitreous cortex leads to anterior traction on the retina.[5] As the vitreous continues to detach, tangential traction from the prefoveal vitreous forms the hole within the fovea.[5] OCT has helped further our understanding of the vitreoretinal interface, showing that the process of PVD tends to begin peripherally, leading to persistent adherence at the fovea.[4] This detachment of the vitreous can begin early in life.[1]

The following points further illustrate the role of the vitreous detachment in the pathophysiology of FTMH. In patients with a FTMH, if the fellow eye has already undergone PVD, there is a very low risk of FTMH in the fellow eye.[4,5] In a study by Niwa, the fellow eyes of 201 patients with FTMHs were observed for two years. Of the fellow eyes of 201 patients, 58 still had vitreofoveal attachments. Of those 58 patients with vitreofoveal attachments, three patients developed a FTMH in the fellow eye, 24 had PVD over the fovea without macular hole, and 31 eyes did not have any changes in the vitreofoveal relationship over the two years.[6] Notably, macular holes developed only in those patients with changes in the vitreofoveal relationship.[6] In a series by Johnson, 96% of 26 eyes with Stage 1 or 2 idiopathic macular holes had a shallow, localized perifoveal vitreous detachment.[7] The vitreous often separates from the fovea last because of firm adherence to the areas of thinnest internal limiting membrane (ILM), including the 500 microns of the fovea. It is hypothesized that vitreous motion due to eye movement may exert localized forces on the fovea at the points of adherence.[7]

While the role of the vitreous is important in the pathophysiology of primary macular holes, retinal degeneration may also play a role. For example, some patients have developed macular holes after extended periods following vitrectomy, where vitreous has been previously removed.[8] Retinal thinning and degeneration may cause small holes to develop, which may close spontaneously via glial proliferation, and this hypothesis would explain the predominance of glial cells and Muller cells in the operculum.[8] Vitreous that is present may prevent closure due to the traction and chemical inhibition of cell migration.[8] It is likely that both degenerative and vitreous traction mechanisms are contributing to the pathophysiology.

In contrast to primary macular holes, FTMH can also be secondary, for example after trauma and sudden axial compression.[1] This leads to retinal rupture of the fovea in addition to other traumatic injuries including sclopetaria, peripheral retinal breaks, and commotio retinae. One major distinguishing feature of secondary macular holes is that the vitreous may not be detached and is a far less common etiology of macular holes than primary macular holes.[1]

Symptoms/Signs

Patients with macular holes may present with painless decreased central vision with a central scotoma and/or metamorphopsia.[3] In some cases, patients may not notice vision loss unless the other eye is occluded, especially for Stage 1 macular holes.[3] Visual acuity is not only decreased due to the central retinal tissue defect but also worsened by the surrounding retinal detachment and cystic changes that can be present.[3]

The clinical signs of macular holes depend on the stages as first defined by Gass.[5] Clinically, these stages were revised by Gass in 1995 and represented in Figure 1.[9] In Stage 1 macular holes, there is cystic foveal change that appears clinically as a yellow spot (Stage 1a) or a yellow foveal ring (Stage 1b). Stage 2 is a full-thickness retinal defect that has a pseudo-operculum and appears as an eccentric oval or crescent shaped defect on a yellow ring. Stage 2 often has an irreversible progression to Stage 3, which is a >400 micron full-thickness retinal defect with a persistent hyaloid attachment, often with a small ring of subretinal fluid. The presence of a Weiss ring suggesting the presence of a complete PVD qualifies as a Stage 4, and yellow deposits are often visible in the defect. The Watzke-Allen test is a useful clinical test for confirming a FTMH. In the Watzke-Allen test, a thin slit beam is projected over the suspected hole, and patients are asked to report if they see a break in the light beam, which confirms a full-thickness retinal defect.

Testing

Optical coherence tomography (OCT) is very useful in diagnosing a FTMH and distinguishing it from other similar-appearing diagnoses. Lamellar macular holes have missing inner retinal tissue, but the RPE and photoreceptor layers are intact on OCT and often have a tri- or bilobulated appearance on fundus exam/photos.[1] Lamellar macular holes often lack the thickening, subretinal fluid, or cystic changes common to FTMHs.[3] Pseudoholes are due to centripetal contraction of an ERM resulting in the appearance of a hole on clinical examination, but pseudoholes do not have loss of retinal tissue on OCT.[1, 3] OCT can also help distinguish FTMHs from other similar-appearing conditions such as solar retinopathy, central serous chorioretinopathy, macular druse, pattern dystrophy, and pseudo-operculum.[3, 4] Macular holes can be sized on OCT and are classified as small <250 microns, medium 250-400 microns, or large >400 microns.[2] These are sized based on using the narrowest point in the mid retina in a plane parallel to the retina.[1]

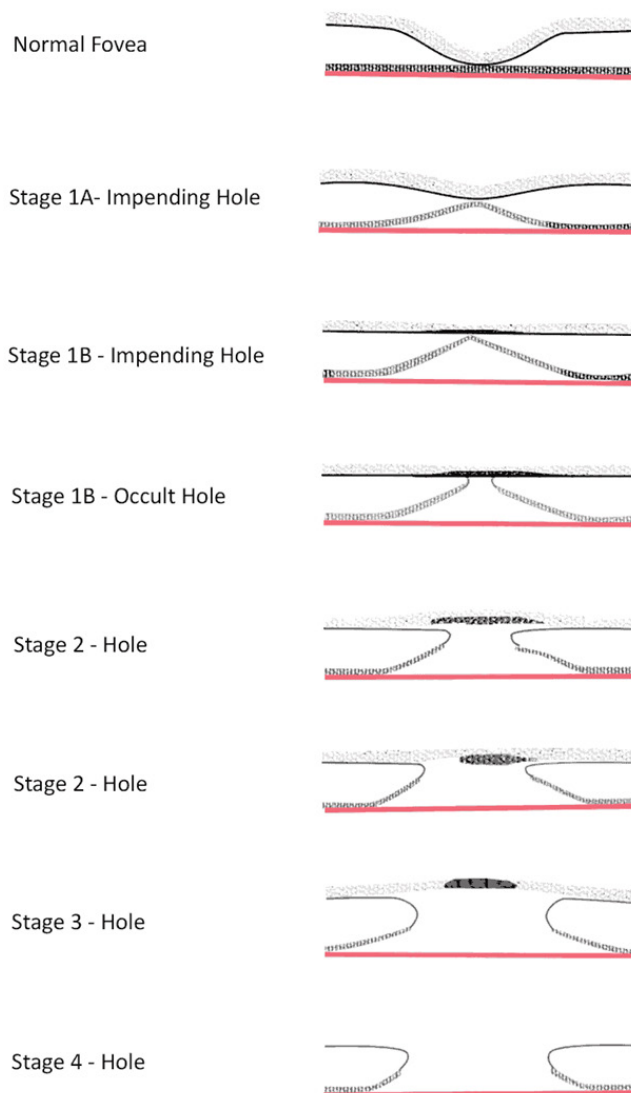


Figure 3: This figure demonstrates the stages of macular holes based on the 1995 paper by J. Donald M. Gass.[9] This figure shows the range of pathology between cystic changes (Stage 1) to full thickness defects with a complete posterior vitreous detachment (Stage 4)

Treatment/Management/Guidelines

Treatment of FTMHs was initially proposed by Kelly and Wendel in 1991, and in their early series of 52 patients, pars plana vitrectomy with vitreous cortex detachment and fluid-gas exchange was successful in closing 58% of macular holes.[10] In those who had closure, 73% had improvement in visual acuity by two lines or better.[10] The proposed mechanism in which this procedure closes holes is the release of vitreomacular traction, then gas to dehydrate the hole edges, occlude fluid, and allow glial cells to proliferate and close the hole.[1] With modern surgical techniques, the successful anatomical closure rates approach 100%.[1] Complications of the surgery include iatrogenic retinal tears (10%), ocular hypertension, endophthalmitis, cataract (50% at two-year follow up) and visual field loss.[1-3] The addition of ILM peeling has the

additional complications of ganglion cell layer loss and dissociation of the nerve fiber layer.[1] The treatment and prognosis is often dependent on the stage. Stage 1 holes will spontaneously resolve in about 50% of eyes.[2] If they do progress, it is usually early and the Vitrectomy for Prevention of Macular Hole Study Group reported that 40% of eyes with Stage 1 holes progressed over 4.1 months.[4] Once the hole is Stage 2 or more, the spontaneous closure rate is low (2-4%), and surgery is indicated to close the hole and restore vision. [3] The size of the hole is important, as holes <250 microns have a 98% surgical closure rate, while holes >400 microns have a lower closure rate at about 90%.[1] By 2-4 weeks after surgery, the successful closure is apparent on OCT with reapproximation of the retinal tissue.(3) Final vision after treatment is quite good, with 2/3 of patients 20/50 or better.[3]

Despite the relatively high success rate of repair, many controversies in macular hole surgery remain. This includes the utility of adjuvant therapies including TGF-b, autologous serum, whole blood, and autologous concentrated platelets to aid in the closure of chronic or large holes. Another controversy is the benefit of ILM removal for improved closure rates versus posterior hyaloid removal and/or ERM removal alone.[1] In one study of FTMHs >400 microns, the closure rate was 73.3%

without peel and 100% with ILM peel.(1) In FTMHs <400 microns, the closure rates were 100% for both groups (with and without ILM peel), arguing against the need for ILM peel in small FTMHs.[1]

Post-operative face down positioning has been recommended since the invention of the surgery, but its necessity is becoming less clear. Often, face down positioning for one week is recommended to provide maximum gas tamponade.[2] More recent studies have found comparable success rates with no face-down positioning after surgery, or assuming a less-strict "reading" position.[3] This is especially true if enough gas is present to isolate the hole from the vitreous over the 3-7 days required for closure.[1] Additionally, the role of gas tamponade itself is unclear. Vitreous release without gas has successfully closed some holes.[8] The release of vitreomacular traction may be the mostportant factor in allowing the hole to close and reparative gliosis to occur.[8]

Pharmacologic therapy has been developed, and intravitreal ocriplasmin is FDA-approved for the treatment of macular holes. There remains controversy about the utility of ocriplasmin, and success rates are best in the treatment of small holes with persistent vitreomacular traction.[1] In phase 3 clinical trials, small holes <250 microns had a closure rate of 58.3%.[2]

EPIDEMIOLOGY OR ETIOLOGY

- ◆ Bilateral involvement in 5-20%
- ◆ 6th and 7th decades of life
- ◆ Female to male incidence of 2:1

SIGNS

Gass Stages:

- ◆ Stage 1 - cystic foveal change
- ◆ Stage 2 - 100-300 micron full-thickness retinal defect with pseudo-operculum
- ◆ Stage 3 - 250-600 micron full-thickness retinal defect with a persistent hyaloid attachment
- ◆ Stage 4 - stage 3 with complete PVD

SYMPTOMS

- ◆ Central scotoma
- ◆ Painless central vision loss
- ◆ Metamorphopsia
- ◆ Central blurred vision

TREATMENT/MANAGEMENT

- ◆ Observation of Stage 1 holes often is appropriate
- ◆ Pars plana vitrectomy with vitreous cortex detachment, epiretinal/internal limiting membrane peel, and fluid-gas exchange
- ◆ Intravitreal ocriplasmin in select cases

References

1. Guadric, A and Tadayoni, R. Macular Hole. Ryan's Retina. Atlanta: Elsevier; 2018; p. 2213-2232.
2. McCannel, CA. Diseases of the vitreous and vitreoretinal interface. Section 12: Retina and Vitreous. San Francisco: American Academy of Ophthalmology; 2016-2017; Chapter 16, p. 294-297.
3. Moshfeghi, AA and Duker, JS. Macular hole. Ophthalmology. Edinburgh: Mosby/Elsevier; 2009; Chapter 6.31, p. 610-613.
4. Gottlieb, JL. Idiopathic macular hole. Albert & Jakobiec's Principles and Practice of Ophthalmology. Atlanta: Elsevier; 2008; p. 2029-2037.
5. Gass, JD. Idiopathic senile macular hole. Its early stages and pathogenesis. Arch Ophthalmol 1988;106(5):629-39.
6. Niwa, H, Terasaki, H, Ito, Y and Miyake, Y. Macular hole development in fellow eyes of patients with unilateral macular hole. Am J Ophthalmol 2005;140(3):370-5.

7. Johnson, MW, Van Newkirk, MR and Meyer, KA. Perifoveal vitreous detachment is the primary pathogenic event in idiopathic macular hole formation. Arch Ophthalmol 2001;119(2):215-22.
8. Smiddy, WE and Flynn, HW, Jr. Pathogenesis of macular holes and therapeutic implications. Am J Ophthalmol 2004;137(3):525-37.
9. Gass, JD. Reappraisal of biomicroscopic classification of stages of development of a macular hole. Am J Ophthalmol 1995;119(6):752-9.
10. Kelly, NE and Wendel, RT. Vitreous surgery for idiopathic macular holes. Results of a pilot study. Arch Ophthalmol 1991;109(5):654-9.

Suggested Citation Format

Janson BJ, Han IC. Full-Thickness Macular Hole (FTMH). EyeRounds.org. November 22, 2017. Available from EyeRounds.org/cases/261-FTMH.htm

last updated: 12/03/2017

Tutorials

On-Call and Trauma

The Bedside Ocular Examination

Jesse Vislisel, MD and Nasreen Syed, MD

October 26, 2012

Introduction

Ophthalmology clinics are filled with technical devices that are routinely used in patient exams. After becoming accustomed to these tools, seeing patients outside the comfortable confines of the clinic can be awkward and even challenging. For this reason, ophthalmologists should become familiar with the different tools and techniques of the bedside ocular examination.

History

Most inpatients examined by ophthalmology are seen in consultation at the request of another medical specialty. The consulting team should provide you with specific questions or concerns they would like you to address. If they have not, you should request this information from them.

Focus your history on the concerns of the requesting service. From a billing perspective, lack of a documented order from the requesting service in the medical record could result in denial of payment for the consult.

Acquire a past ocular history, paying particular attention to things such as history of eye diseases, past ocular surgeries, refractive error, history of ocular trauma, and ophthalmic medications.

For relevant cases, such as acute ocular trauma, ascertain the mechanism of injury, whether the patient was wearing glasses or eye protection, and the time and location of the incident.

Determine if the patient has family history of ocular disorders.

Also obtain relevant past medical and surgical history, social history, and review of systems (often required for consultation billing codes).

If the patient is unable to communicate, attempt to acquire information from family members, if available. If this information cannot be obtained, document this in your note. Occasionally, the patient's outside eye care provider must be contacted for additional information.

Examination

The bedside exam differs from the clinic exam in several ways.

- ◆ Typically, if you are seeing a patient at the bedside it is because he or she is physically unable to come to clinic. This may be because he or she is very ill or recovering from a recent operation. The patient may even be comatose.

- ◆ Often these patients will have a lower tolerance for the exam.
- ◆ Patients may only be able to position themselves in certain ways, and in some instances, they may not be awake or able to participate in the exam at all.
- ◆ What you are able to accomplish is highly dependent on how much the patient can cooperate.

As in clinic, always **wash your hands** before entering and when leaving each patient room.

Use **universal precautions** if there is any evidence of blood or an open wound. This is especially important for inpatients, as they may be particularly susceptible to infection, depending on their medical condition.

Make sure your instruments are clean. They usually do not need to be sterile but should not be a vector for spreading infection.

If the eyelids are exceptionally swollen, you may need to utilize one or two Desmarres retractors to assist in the exam.

Measure **visual acuity** using a near card. Always assess whether the patient normally wears refractive correction and have him or her wear it if available. Occasionally you will receive a consult for a patient with blurry vision only to discover that the vision is blurred because he or she is not wearing his or her spectacles.

Carry a few loose trial lenses (e.g. +2.00 and +3.00 diopters) with you as patients over 40 years of age may require near assistance if they do not have their usual reading correction with them. Pinhole can be used at near just as it is when measuring distance acuity if the patient can position properly.

If you plan to have serial visual acuity checks performed, remember that mydriasis and cycloplegia can have a significant impact on acuity at near, particularly in a young patient.

Confrontational visual fields are highly reliant on patient cooperation. Try to obtain them if you are able. Using two red objects, such as the bottle tops of dilating drops, usually yields better results than fingers alone.

Motility also depends on cooperation. This is critically important in facial trauma patients to assess for extraocular muscle entrapment. If a patient is unable to cooperate with this portion of the exam and there is concern for entrapment, forced ductions can be performed using toothed forceps under topical anesthesia.

The **pupil exam** is critical, especially in comatose patients. Assess pupil size, reactivity, and whether there is an afferent pupillary defect. The pupil exam can be performed

using a Finhoff illuminator, a bright pen light, or an indirect lamp on maximum brightness. If you cannot hold open both eyelids at the same time, ask for assistance from the nurse or other staff.

Intraocular pressure is usually measured using a Tono-Pen. This device requires careful technique and can be quite inaccurate in the wrong hands. If you are unsure of your result, repeat the measurement multiple times. Try to avoid pressure on the globes while holding open the eyelids as this may give a falsely elevated measurement.

The **external exam** is especially important in trauma patients. Look for evidence of fractures and lacerations. Make sure the lacrimal drainage system appears intact. Palpate for crepitus which could suggest an orbital fracture communicating with a paranasal sinus. Measure ocular position using a Hertel exophthalmometer in patients with facial trauma or proptosis.

The **anterior segment exam** is limited when compared to the detail available under the slit lamp in clinic. Portable slit lamps can be helpful, but the amount of detail is still significantly diminished compared to the full-sized models. Be careful to document only things you can reliably assess given the limitations of your equipment. For instance, do not state the anterior chamber is quiet if you cannot confidently assess for cell or flare. Instead, make more general statements such as the anterior chamber is formed. Portable slit lamps are expensive and not available everywhere. Alternatively, the anterior chamber may be assessed using the magnification from a 20-diopter binocular indirect ophthalmoscopy lens and the illumination from a Finhoff illuminator, penlight, or indirect headset.

The **fundus** may be examined by indirect or direct ophthalmoscopy, similar to what one would perform in clinic. Always check with the primary service before dilating a patient with neurologic issues, as they may be monitoring neurologic status via pupil exam. Sometimes dilation must be deferred to a later date when the patient is more stable. If it is imperative that you perform a dilated exam on an eye in a neurologically unstable patient, you may be able to dilate only that eye while leaving the other eye undilated for neurologic evaluation. It is always a good idea to notify the patient's nurse when you have dilated a patient, specifying approximately how long the drops should be expected to last. Additionally, you may wish to leave this information on a note at the patient's bedside to prevent any confusion other care providers may have after noticing the acute change in pupillary status. For patients in whom you do not need to perform a peripheral fundus exam, such as an assessment for papilledema, you can use a direct ophthalmoscope to visualize the optic nerve head and posterior pole.

Even when **dilation** is absolutely contraindicated, limited information may be gained by examining any imaging studies (computed tomography or magnetic resonance imaging) for signs of disruption in the posterior pole. In cases where there may be concern for posterior segment pathology, B-scan echography may be indicated at the bedside.

Orders

In general, if the patient needs ophthalmic medications to treat their condition, these are best written by the ophthalmologist, who is most familiar with these medications. If systemic medications are needed for treatment, discuss this with the primary team and decide who should write the orders. Be clear in your note about whether medications should be continued after discharge.

Documentation

When writing your consult note, focus on the specific questions or concerns the primary team has proposed. Your note is meant to convey information to healthcare providers in other medical fields, thus you should write in a fashion that they can read and understand. The assessment and plan should be written without abbreviations or jargon. Avoid even routine ophthalmology abbreviations such as OD or OS, instead stating right eye or left eye to avoid potential confusion. It is also good practice to leave your pager number or other contact information in the note, encouraging the primary team to contact you if they have any additional questions or concerns.

In addition to your consult note, you may need to contact the consult team directly, depending on the urgency of your findings.

Follow-up

Assess whether the patient requires further ophthalmology follow-up. You may need to perform serial bedside exams during the patient's inpatient stay or it may be appropriate to arrange ophthalmology follow-up after discharge. Include follow-up recommendations in your consult note and send a letter to the patient's eye care provider if appropriate. If follow-up is particularly important, it is often helpful to secure the patient's contact information so you may call them at a later date to assure an appointment has been scheduled.

Citing this article

Vislisel J, Syed N. The Bedside Ocular Examination. EyeRounds.org. October, 26, 2012; Available from: EyeRounds.org/tutorials/bedside-ocular-exam.htm

last updated: 10/26/2012

Ocular Ultrasound

A Quick Reference Guide for the On-Call Physician

Aaron Fairbanks BS, Lorraine Myers (Provencher) MD, William Flanary MD, Laura Warner, H. Culver Boldt MD

February 4, 2016

Ocular ultrasound, also known as ocular echography, “echo,” or a B-scan, is a quick, non-invasive test routinely used in clinical practice to assess the structural integrity and pathology of the eye. It can provide additional information not readily obtained by direct visualization of ocular tissues, and it is particularly useful in patients with pathology that prevents or obscures ophthalmoscopy (e.g., large corneal opacities, dense cataracts, or vitreous hemorrhage) (1).

Some academic centers employ a highly trained ocular ultrasonographer to perform ocular ultrasound during regular business hours. Consequently, ophthalmology residents may lack technical and practical experience in ocular ultrasound. These deficiencies are highlighted when seeing patients after hours, while on-call. Proficiency in performing ocular ultrasound is an invaluable tool to the on-call physician who seeks to quickly, safely, and inexpensively examine the globe and properly triage a patient. Please note, in the setting of a suspected open globe injury, echography should only be performed by an experienced echographer, as pressure on the eye can cause further damage. Here, we present a simple, introductory “on-call survival guide” for ophthalmology residents using ocular ultrasound.

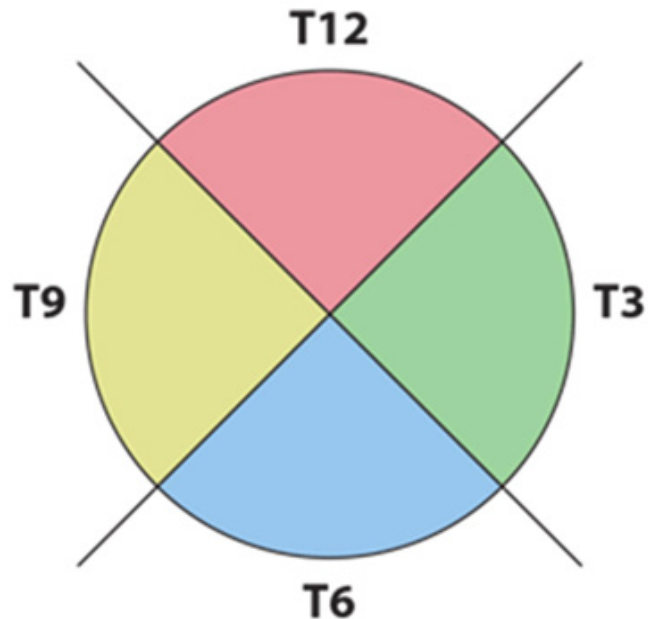


Figure 1: Schematic diagram of ultrasound quadrants

Ocular Ultrasound Technique

One can examine the entire globe in just **five** maneuvers, i.e. four dynamic quadrant views and one more static slice through the macula and optic disc, also known as longitudinal macula (LMAC). The quadrant views are designated T12, T3, T6, and T9. These numbered quadrants correspond to a clock face superimposed on the eye. For example, T12 is a view through the superior quadrant of the eye, T3 the nasal quadrant of the right eye (temporal quadrant of the left eye), and so on (Figure 1) (2).

Ultrasound images can be obtained through the patient’s eyelids (as depicted in this tutorial) or with the probe directly on the surface of the eye with appropriate topical anesthesia. Begin with the gain on high. The patient should look in the direction of the quadrant to be evaluated. The marker on the probe is always oriented superiorly or nasally by convention. Use a limbus-to-fornix rocking, rotational motion so that the tip of the probe moves a small distance, while the base of the probe moves a larger distance (Figure 2) (3). The probe rotates around the globe so that the sound waves always pass through the center of the eye. This rotational motion will maximize the amount of retina visualized during the scan. See the “Additional Information” section for more detail.

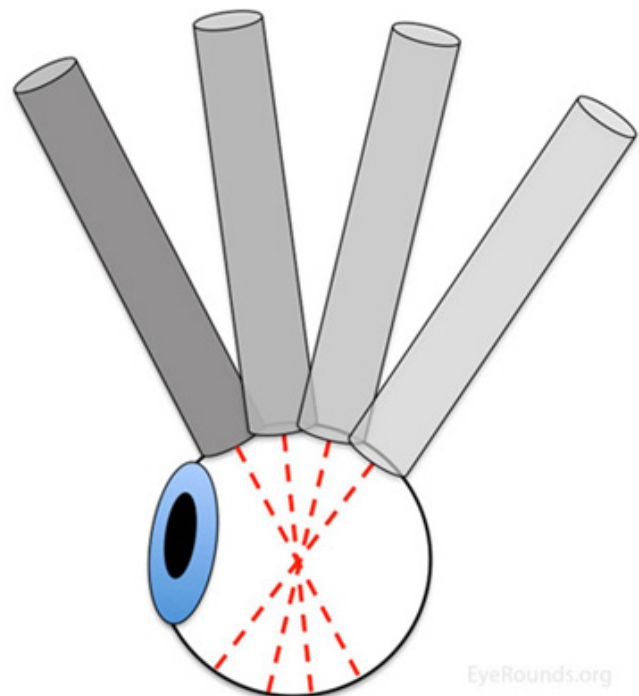


Figure 2: Limbus-to-fornix rotational motion

A Step-Wise Approach

Transverse View 1: T12 (quadrant centered at 12 o'clock)

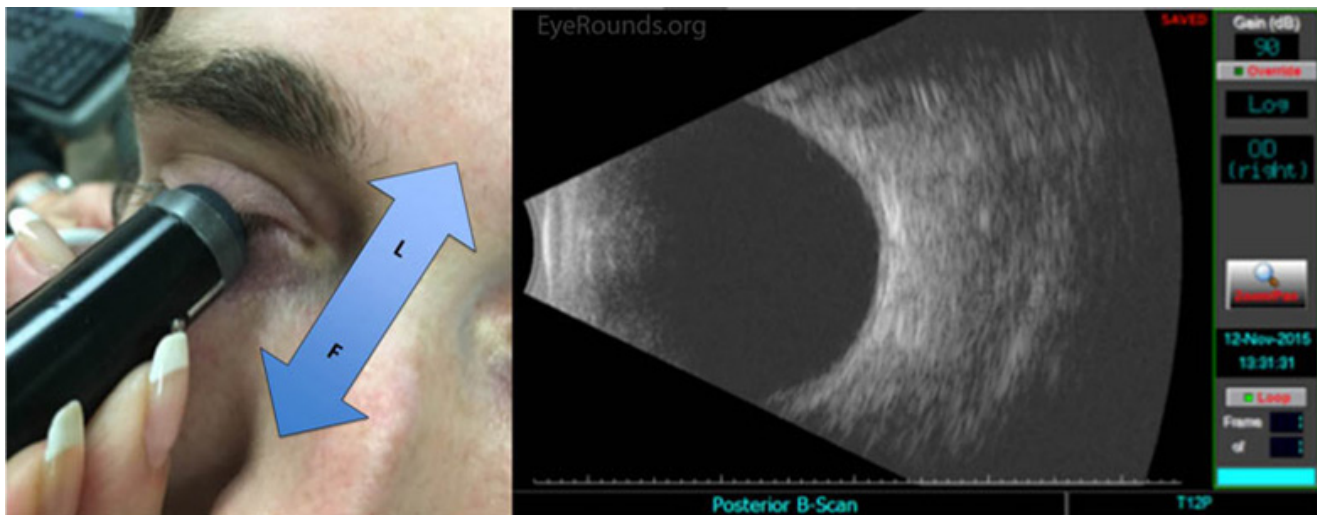


Figure 3: Ask the patient to look up. Place your probe on the inferior aspect of the globe with the marker oriented nasally. Begin at the limbus (L) and locate the optic nerve shadow, both to orient yourself and assure you are imaging the posterior segment. Slowly sweep your probe toward the inferior fornix (F) until visualization of the T12 quadrant is complete. Repeat if necessary. Remember to center any pathology along the equatorial plane of the image for the best resolution.

Transverse View 2: T6 (quadrant centered at 6 o'clock)

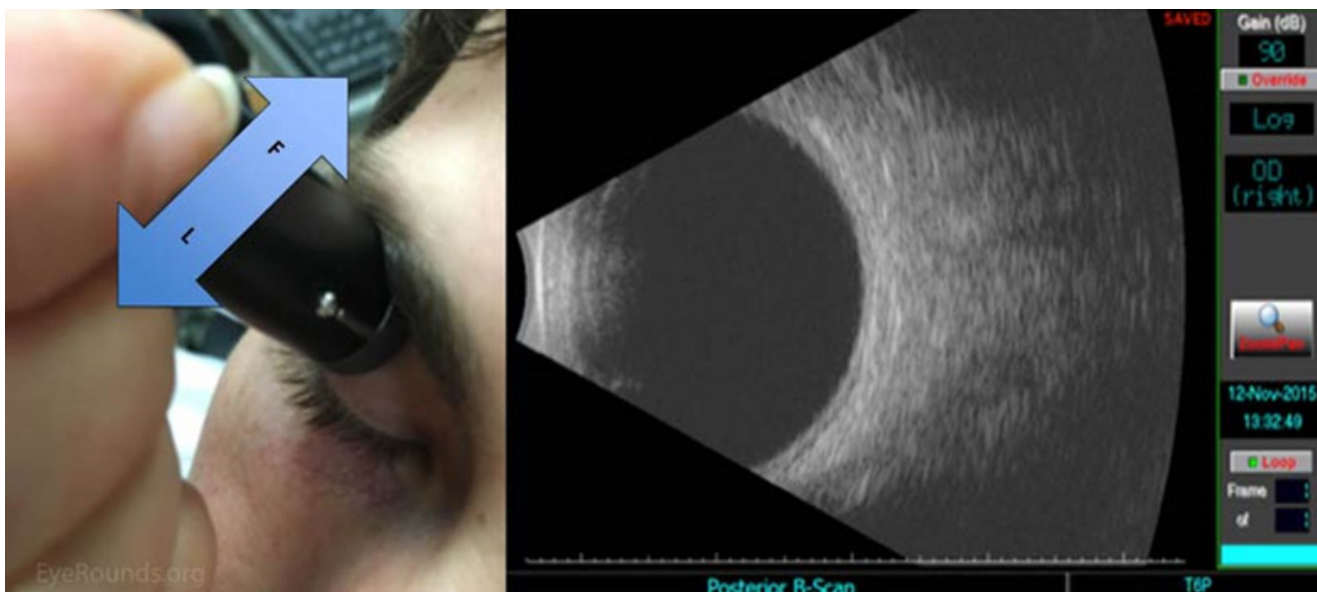


Figure 4: Ask the patient to look down. Place your probe on the superior aspect of the globe with the marker aimed nasally. Again, begin at the limbus (L). Ensure you have an image of the retina and optic nerve before sweeping the probe toward the superior fornix (F). Repeat if necessary, centering any pathology.

Transverse View 3: T3 (quadrant centered at 3 o'clock)

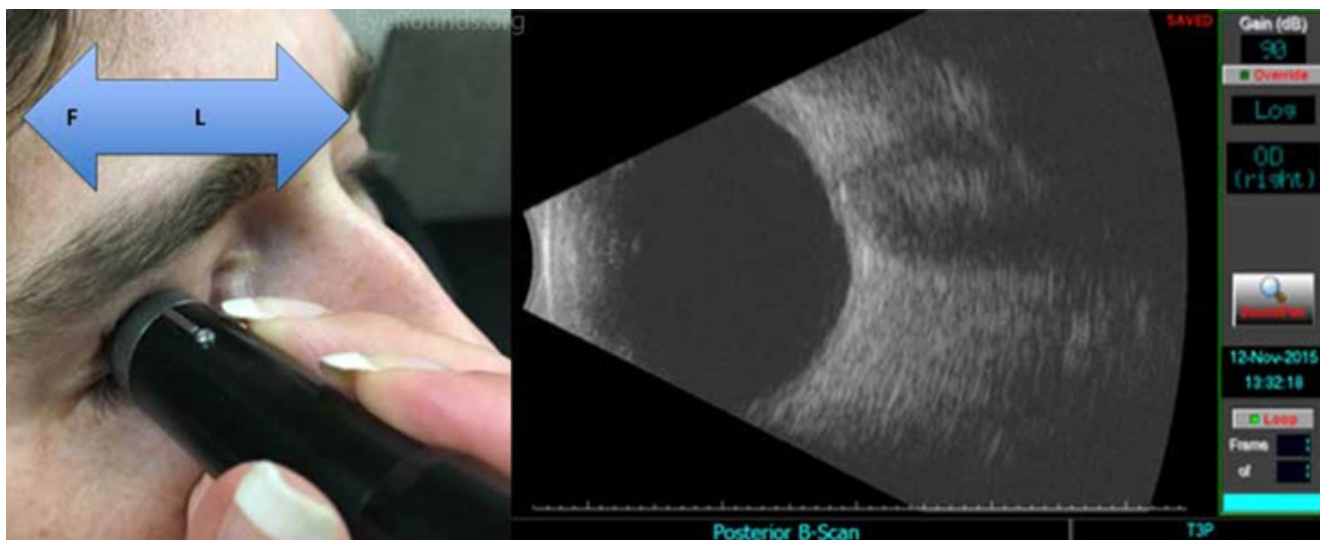


Figure 5: Remember, to scan the medial and lateral quadrants of the eye, the probe marker should point superiorly. For the T3 quadrant of the patient's right eye, instruct the patient to look left. Place the probe on the temporal limbus (L). After obtaining an image of the retina and optic nerve, gently sweep the probe to the fornix (F) to complete evaluation of this quadrant. To view the T3 quadrant of the left eye, the patient should still gaze to the left, but the probe will be placed at the medial limbus, with the marker oriented superiorly.

Transverse View 4: T9 View (quadrant centered at 9 o'clock)

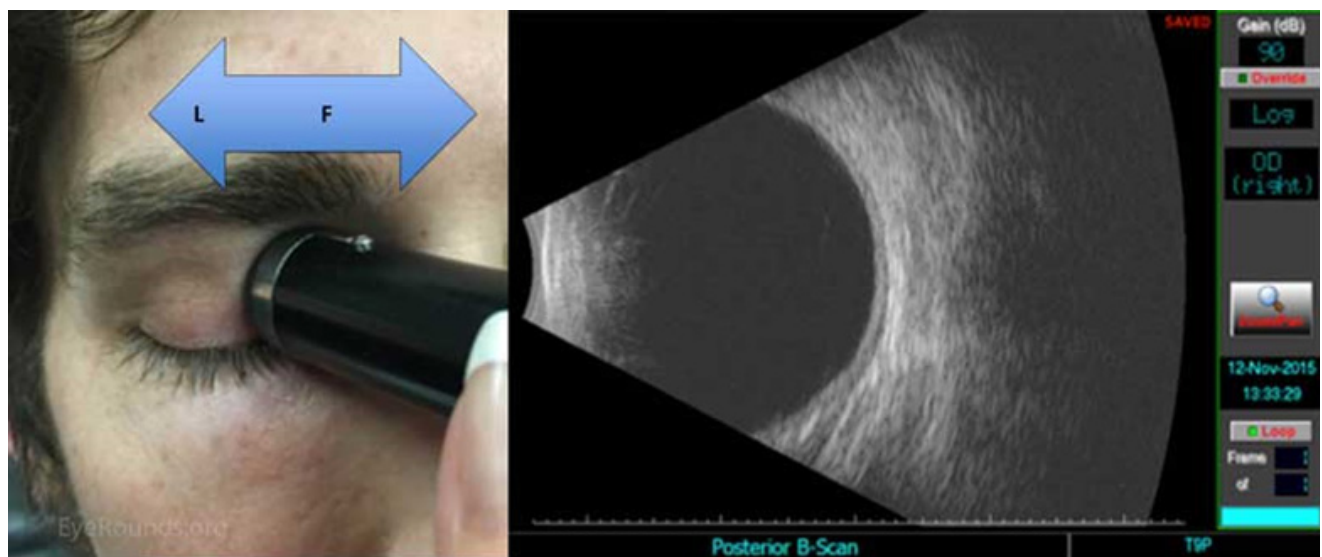


Figure 6: Scanning the T9 quadrant of the right eye is simply the reverse scan of the T3 quadrant. With the probe marker oriented superiorly, instruct the patient to direct their gaze to the right. Place the probe on the globe at the nasal limbus (L). For the T9 quadrant of the left eye, place the probe at the temporal limbus. Proceed, again with a limbus-to-fornix (F) rotational sweeping movement.

Longitudinal Macula (LMAC) View

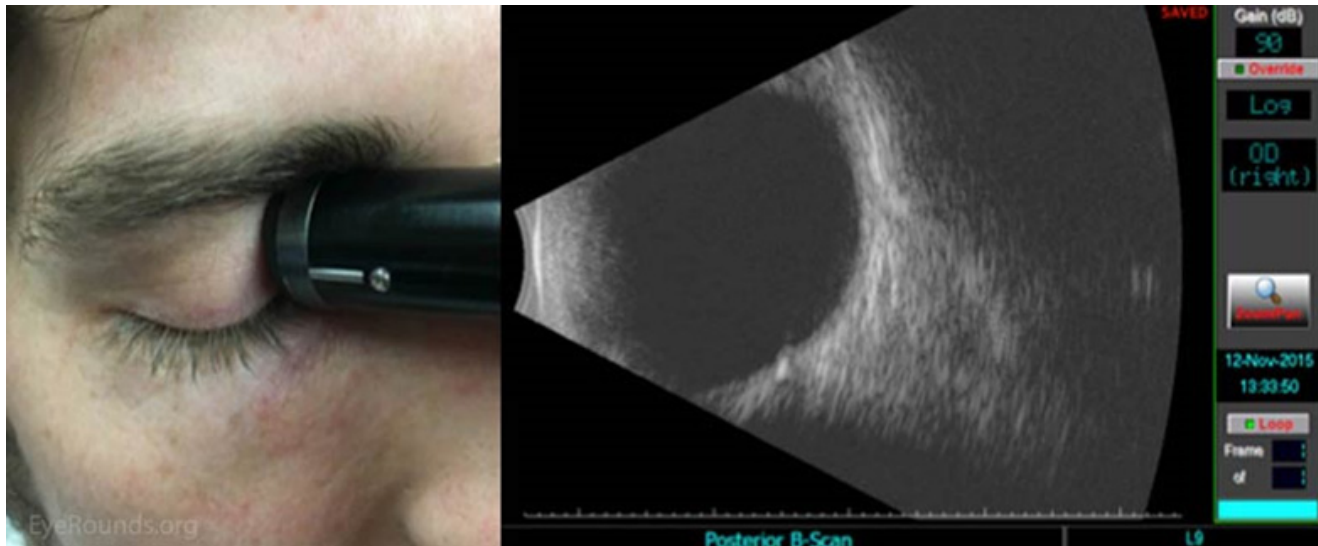


Figure 7: The LMAC view allows for proper visualization of the macula and optic nerve. Gently place the probe on the nasal aspect of the eye with the patient's gaze directed temporally. Note: For this position, the marker of the probe should be directed toward the pupil, instead of superiorly. A longitudinal scan is the only scan where this occurs! In this view, the optic nerve will be below the macula. Maneuver the probe to bring the macula into the center of the image to obtain the best resolution.

Summary

The on-call ophthalmologist must be proficient at ocular ultrasound, as it is an indispensable tool for the diagnosis and triage of ophthalmic emergencies. One can systematically examine the entire globe with just five maneuvers, i.e. four dynamic quadrant views and one longitudinal cut through the macula and disc. One must always remember that this is simply a starting point, and a more detailed, comprehensive ultrasound examination should be guided by additional clinical data and preliminary ultrasonographic findings.

Supplemental information on ocular ultrasonography (2)

1. High frequencies (approximately 10Mhz) are used in ocular echography because they produce an image with greater resolution than low frequencies. While this comes at the expense of poorer tissue penetration, high frequencies retain enough penetration to properly examine the delicate ocular structures.
2. The B-scan creates a two dimensional image from a very thin slice of tissue oriented perpendicular to the cylinder of the probe.
3. The area of best resolution is along the center axis of the probe, parallel to the probe itself. Thus, the area of interest should be placed along the equatorial line of the image. In ocular ultrasound, the retina will appear on the right hand side of the image;

this is where any pathology should be focused.

4. The denser the tissue, the brighter (hyperechoic) it will appear and vice versa. If the tissue is dense enough, it will cast a "shadow" directly behind it, preventing that tissue from being evaluated.
5. As the gain is adjusted higher, weaker signals are more easily visualized (vitreous opacities, posterior vitreous detachment, small foreign bodies, etc.). As the gain is adjusted lower, stronger signals are more easily visualized (masses, tumors, etc.) and the weaker signals may be absent.
6. For transverse images, the marker on the probe is always oriented superiorly or nasally by convention. This allows any reader to interpret your images given the stated cut (e.g. T12).
7. The most effective method to examine the extent of the retina during a B-scan is to use the limbus-to-fornix technique. To perform this technique, the ultrasonographer should gently glide the probe from the limbus of the eye to the fornix in a sweeping motion to maximize the amount of retina visualized during the scan.
8. By convention, a clock face is superimposed on each eye to identify the quadrants to be scanned, similar to the method used to describe fundus lesions. While the T12 and T6 remain superiorly and inferiorly (respectively) on each eye, the T3 quadrant on the patient's right eye is located nasally, while on their left it is the temporal quadrant. The same is true for the T9 quadrant, which is located temporally on the right eye and nasally on the left eye.

References

1. Byrne SF, Green RL. Ultrasound of the eye and orbit. 2nd ed. St. Louis: Mosby Year Book; 2002.
2. Boldt HC, Ossoinig KC, Warner LL, Fuhrmesiter L. Echography. medicine.uiowa.edu/eye/pathology/eye/node/266. Accessed Nov. 25, 2015.
3. Waldron RG. Contact B-Scan Ultrasonography. Emory Eye Center. 2003:1-9.

Suggested Citation Format

Fairbanks A, Myers (Provencher) L, Flanary W, Warner L, Boldt HC. Ocular Ultrasound: A Quick Reference Guide for the On-Call Physician. EyeRounds.org. posted February 4, 2016; Available from: www.EyeRounds.org/tutorials/ultrasound/

last updated: 2/4/2016

Emergent Evaluation of Eyelid Lacerations

A guide for ophthalmology residents

Thomas J.E. Clark, MD; Erin M. Shriver, MD, FACS
January 4, 2016

Step 1: ALWAYS clear the globe

Step 2: History

- A. Patient age
- B. Mechanism of injury
 - 1. What type of object inflicted the injury?
 - a. Dog bites:
 - i. Recommend the dog be put down as the second bite is many times worse than the first
 - ii. Give antibiotics covering mixed flora (e.g. Streptococcal spp., Anaerobes, Pasteurella, and gram negative rods (GNR))[1]:
 - o Ampicillin/Sulbactam (Unasyn®): 1.5-3gm IV q6h [adults], 150- 300mg/kg/d IV divided q6h [pediatrics]
 - o Amoxicillin/Clavulanate (Augmentin®): 875mg/125mg PO bid [adults], 25mg/kg/d PO divided bid [pediatrics]
 - o Meropenem: 500mg IV q8h [adults] with dose adjustment for CrCl <51mL/min, 10mg/kg (max dose: 500mg) IV q8h [pediatrics]
 - o Moxifloxacin: 400mg IV or PO qd [adults], contraindicated in pediatrics
 - o Clindamycin (misses GNR and Pasteurella): 600-900mg IV q8h or 300- 450mg PO q6h [adults], 20-40mg/kg/d IV or 8-16mg/kg/d divided in 3 or 4 equal doses [pediatrics]
 - 2. Is there a potential for retained foreign body (metal vs organic material)?
- C. Time lapse since injury occurred
- D. Last oral intake
- E. Last Tetanus shot (see Tetanus Vaccination Protocol below)

Step 3: Exam

- A. Take a picture
- B. Look for **RED FLAGS** that warrant Oculoplastic involvement
 - 1. Visible orbital fat (signifies septal violation concerning for damage to deeper structures)
 - 2. Laceration of the eyelid margin (requires meticulous closure to avoid long-term sequelae from lid margin notching)
 - 3. Damage to the lacrimal system (shearing forces commonly damage the medial canthal structures) – may need to probe and irrigate to rule out canalicular involvement
 - a. Supplies needed for lacrimal system probing and irrigation:
 - i. 4% topical lidocaine
 - ii. Cotton-tipped applicator
 - iii. Punctal dilator
 - iv. Bowman probe (size 00 or 0)
 - v. 23-gauge curved lacrimal cannula on a 3cc syringe filled with fluorescein- infused saline (*this can be created with saline and a standard fluorescein strip*)

Step 4: Repair

- A. Obtain consent
- B. Take a photo
- C. Obtain necessary materials:
 - 1. Lidocaine (1% or 2% with 1:100,000 epinephrine)
 - 2. 20- and 27- or 30-gauge needles [draw with 20-gauge, administer with 27- or 30- gauge]
 - 3. 3mL or 5mL syringe
 - 4. Sterile saline with irrigation tip
 - 5. 5% Betadine (Povidone-iodine)
 - 6. 0.5% topical proparacaine drops
 - 7. Castroviejo needle holder
 - 8. Paufigue forceps
 - 9. Suture (5-0 or 6-0 Fast vs 7-0 Vicryl vs 7-0 nylon)
 - 10. Straight scissors
 - 11. Sterile gloves
 - 12. Mask
 - 13. Erythromycin ointment
 - 14. Sterile eye drape
 - 15. Sterile gauze and cotton-tipped applicators
 - 16. Mayo stand and sterile drop cloths, if available (if not, can set instruments and supplies on the opened sterile gloves wrapper)
- D. Anesthetize
- E. Explore
- F. Irrigate with copious amounts of sterile saline
- G. Anti-sepsis: prep with 5% Betadine *until the tissue bleeds*
- H. Prepare a sterile surgical field utilizing a Mayo stand with sterile drop cloths (can then open and arrange instruments and suture), sterile gloves, mask, and sterile drape
- I. Close the wound
 - 1. General principles [2]
 - a. Tissue is almost never missing
 - b. Strive for tension-free closure to avoid lagophthalmos/exposure keratopathy
 - c. Unless completely unavoidable, avoid making vertically-oriented suture passes as closing a horizontally-oriented wound with vertically-oriented suture passes can cause vertical cicatrization resulting in ectropion/lagophthalmos/exposure keratopathy
 - d. Cicatricial changes pull the lower lid down—attempt to elevate the lower lid as much as possible during repair (in cases of unavoidable vertical tension, a frost suture or temporary tarsorrhaphy may need to be placed)
 - e. *NEVER* suture the orbital septum
 - 2. Suture selection considerations
 - a. Patient expectations regarding scarring
 - o If aesthetics are important to the patient and the patient is able to return to clinic in order to have the sutures removed, non-absorbable monofilament sutures (e.g. nylon or Prolene) are preferable

- b. Patient reliability for follow-up
 - o Avoid non-absorbable sutures in patients unlikely to return for removal
 - c. Amount of tension
 - o Braided sutures are superior for wound closure under tension
 - d. Complexity of laceration/necessity of both deep and cutaneous closures
 - o Use 5-0 or 6-0 Vicryl for deep closures
3. Suturing technique
- a. Simple, interrupted closure is sufficient and preferable in most cases
 - o Divide the wound in half with the first suture pass, then continue to halve the remaining unclosed wound segments
 - a. For extensive lacerations, a running closure is more expedient
 - b. Can use a combination of interrupted and running closures, with interrupted sutures placed at points of tension and locations where the laceration changes direction

J. Apply erythromycin ophthalmic ointment to the wound

1. If the patient has an erythromycin allergy, can use bacitracin ointment or Polysporin® (bacitracin + polymyxin B) ointment

Suture	Absorbability	Filament Type	Advantages	Disadvantages
5-0 Fast Gut	Absorbable (1 week)	Mono	Infection less likely	More difficult to handle
				Highly inflammatory
7-0 Vicryl	Absorbable (4-6 weeks)	Braided	Easy to handle	Infection and suture gran- uloma more likely
			least inflammatory of absorbable sutures	
7-0 Nylon	Non-absorbable	Mono	Least inflammatory	Requires follow-up for removal
			Best aesthetic outcomes	
			Infection less likely	

**Table adapted from Lee & Carter, 2006 [3]*

Step 5: Post-closure cares/follow-up

- A. Apply erythromycin (vs bacitracin vs Polysporin®) ophthalmic ointment to the wound TID
- B. Arrange follow-up in Oculoplastics clinic within 10 days
- C. Remove sutures (if Vicryl or nylon were used) 6-10 days post-operatively

Step 6: Wound management/scar maintenance

- A. Avoid direct sunlight exposure for at least 6 months
- B. *Once wound is healed...* MASSAGE, MASSAGE, MASSAGE
 1. 20 strokes TID
 2. Topical vitamin E or Mederma®

Tetanus Vaccination Protocol

	Clean knife wound		All other wounds	
History	Tet Vac	Tet Ig	Tet Vac	Tet Ig
< 3 doses	Y	N	Y	Y
≥ 3 doses	If ≥ 10 yrs since last Tet Vac	N	If ≥ 5 yrs since last Tet Vac	N

***Tet Vac**

- o if < 7 years old, give DTap
- o if > 7 years old with no prior Tdap, give Tdap
- o if > 7 years old with prior Tdap, give Td

^Tet Ig

- o give 250 Units IM at site away from Tet Vac site
- o if no Tet Ig available, give Tet IVIg

Table adapted from CDC, 2011 [4]

References

1. Stevens DL, Bisno AL, Chamber HF, et al. Practice guidelines for the diagnosis and management of skin and soft tissue infections: 2014 update by the Infectious Disease Society of America. *Clin Infect Dis.* 2014;59:e10-52.
2. Nerad JA. Chapter 13. Eyelid and Orbital Trauma. IN: *Techniques in Ophthalmic Plastic Surgery— A Personal Tutorial.* Elsevier, 2010; pp 355-369.
3. Lee J, Carter KD. Chapter 6. Suture Materials and Needle. IN: *Basic Principles of Ophthalmic Surgery*, TA Oetting (Second Ed.) American Academy of Ophthalmology, 2006, 2011; pp 83-89.
4. Centers for Disease Control and Prevention (CDC). Updated recommendations for use of tetanus toxoid, reduced diphtheria toxoid and acellular pertussis (Tdap) vaccine from the Advisory Committee on Immunization Practices 2010. *MMWR Morb Mortal Wkly Rep.* 2011;60:13.

Citing this document

Clark TJE, Shriver EM. Emergent Evaluation of Eyelid Lacerations: A guide for ophthalmology residents. EyeRounds.org. December 17, 2015; Available from: EyeRounds.org/tutorials/eyelid-lacerations

Index

- Aphakic Glaucoma 35-39
- Apraxia of Eyelid Opening 84-86
- Aqueous Misdirection 45-49
- Bedside Ocular Exam 321-322
- Bell's Palsy 96-102
- Benign Lesions, External Periocular Tissues 246-253
- Binocular Vision 297-308
- Blepharospasm 84-86
- Carotid Cavernous Fistula 87-90
- Cataract 19-222, 188-193
- Chalazion 91-95
- Congenital dacryocystocele 112-114
- Cornea 1-18, 143-187
- Corneal Degeneration, Salzmann's Nodular 2-8
- Corneal Dystrophies 168-176
- Corneal Hydrops 14-18
- Corneal Imaging 144-155
- Corneal Transplantation 156-167
- Dacryocystocele 112-114
- Dystrophy, Corneal 168-176
- Endophthalmitis 136-142
- Epithelial Basement Membrane Dystrophy 9-13
- Ethambutol Toxicity 71-76
- Exfoliation Syndrome 29-33
- External Disease 1-18, 143-198
- Eye Injury 120-123
- Eyelid Lacerations 328-331
- Facial Nerve Decompression 96-102
- Fistula, Carotid Cavernous 87-90
- Functional Visual Loss 61-65
- Fungal endophthalmitis 136-142
- Glaucoma Surgery 201-214
- Glaucoma 34-59, 194-214
- Glaucoma, Medical Management 195-200
- Glaucomatocyclitic Crisis 56-59
- Hydrops, Corneal 14-18
- Hypotony 50-55
- Idiopathic Intracranial Hypertension 224-235
- Idiopathic Juxtafoveal Telangiectasia Type II 124-130
- Imaging, Cornea 144-155
- Injection Technique 307-314
- Intraocular Foreign Body 120-123
- Intravitreal Injection Technique 307-314
- Iris Prolapse 192-193
- Keratotomy 9-13
- Keratoconjunctivitis, Phlyctenular 115-118
- Lesions, Benign, External Periocular Tissues 246-253
- Lesions, Malignant, External Periocular Tissues 256-261
- Macular Hole 315-319
- Macular Telangiectasia type 2 124-130
- Maculopathy, hypotony 50-55
- Malignant Lesions, External Periocular Tissues 256-261
- Marfan Syndrome 20-23
- MIGS 201-214
- Myokymia, Superior Oblique 103-106
- Nasolacrimal Stents 280-286
- Nerve Blocks 287-289
- Neuro-Ophthalmology 60-82, 215-244
- Nystagmus 236-244
- Ocular Exam, Bedside 321-322
- Ocular Surface Tumors 177-187
- Ocular Tilt Reaction 66-70
- Ocular Ultrasound 323-327
- Oculoplastic Surgery 83-106, 245-289
- On-Call and Trauma 320-331
- Optic Neuritis 77-82
- Optic Neuropathy, Ethambutol 71-76
- Orbital Cellulitis 108-111
- Patient Communication 189-191
- Pediatric Ophthalmology 107-118
- Pediatric Spectacle Prescription 291-296
- Peribulbar Block 287-289
- Phlyctenular Keratoconjunctivitis 115-118
- Posner-Schlossman Syndrome 56-59
- Posterior Polar Cataract 24-28
- Posterior Vitreous Detachment, Impending 131-135
- Prescription, Pediatric Spectacle 291-296
- Prolapse, Iris 192-193
- Pseudotumor Cerebri 224-235
- Retina and Vitreous 119-142, 306-319
- Retinoscopy 291-296
- Retrobulbar Block 287-289
- Saccadic Oscillations 236-244
- Salzmann's Nodular Corneal Degeneration 2-8
- Staphylococcal Blepharitis 115-118
- Strabismus 290-305
- Thyroid Eye Disease 262-279
- Trabeculectomy 50-55
- Transplantation, Cornea 156-167
- Tumors, Ocular Surface 177-187
- Uveitis Glaucoma Hyphema (UGH) Syndrome 40-44
- Vertical Oscillopsia 103-106
- Visual Field Testing 216-223
- Visual Loss, Functional 61-65
- Vitreous Syneresis 131-135

