

## Pseudostreaks (Senile Atrophic Lines)

**Category(ies):** Retina, Vitreous

**Contributor:** [Eric Chin, MD](#)

**Photographer:** Carol Chan, CRA




Pseudostreaks are also known as 'senile atrophic lines'. They are mild peripapillary streaks that are a separate entity than angioid streaks. They have a benign course and a slightly different clinical appearance (i.e. peripapillary heliocoidal choroidal atrophy).

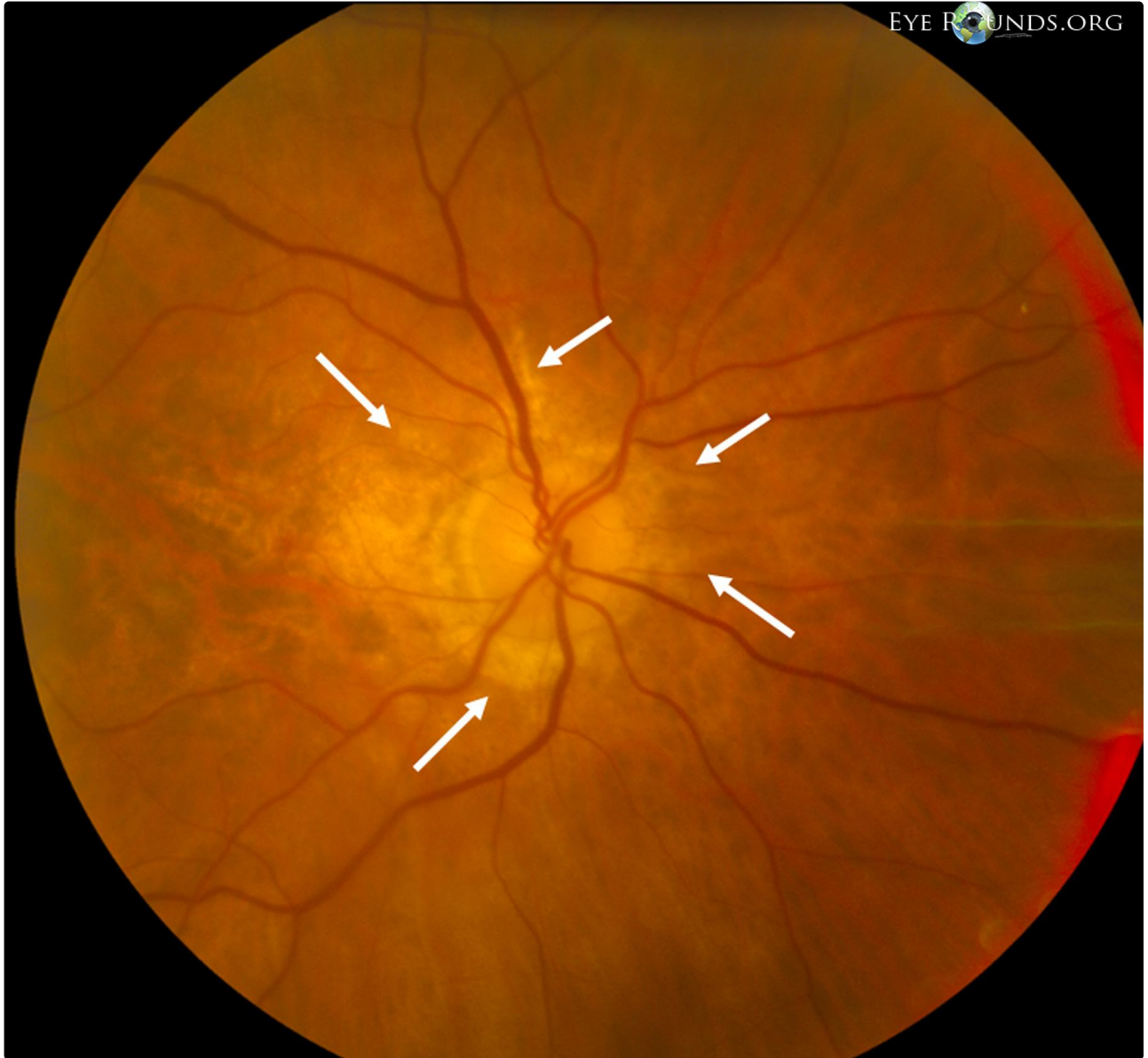
Pseudostreaks are unlikely to cause choroidal neovascularization, but may be associated with retinal telangiectasis.

This 83-year-old female presented for age-related macular degeneration evaluation. She had noticed gradual decreased vision in her right eye worse than her left, but denied any acute changes.

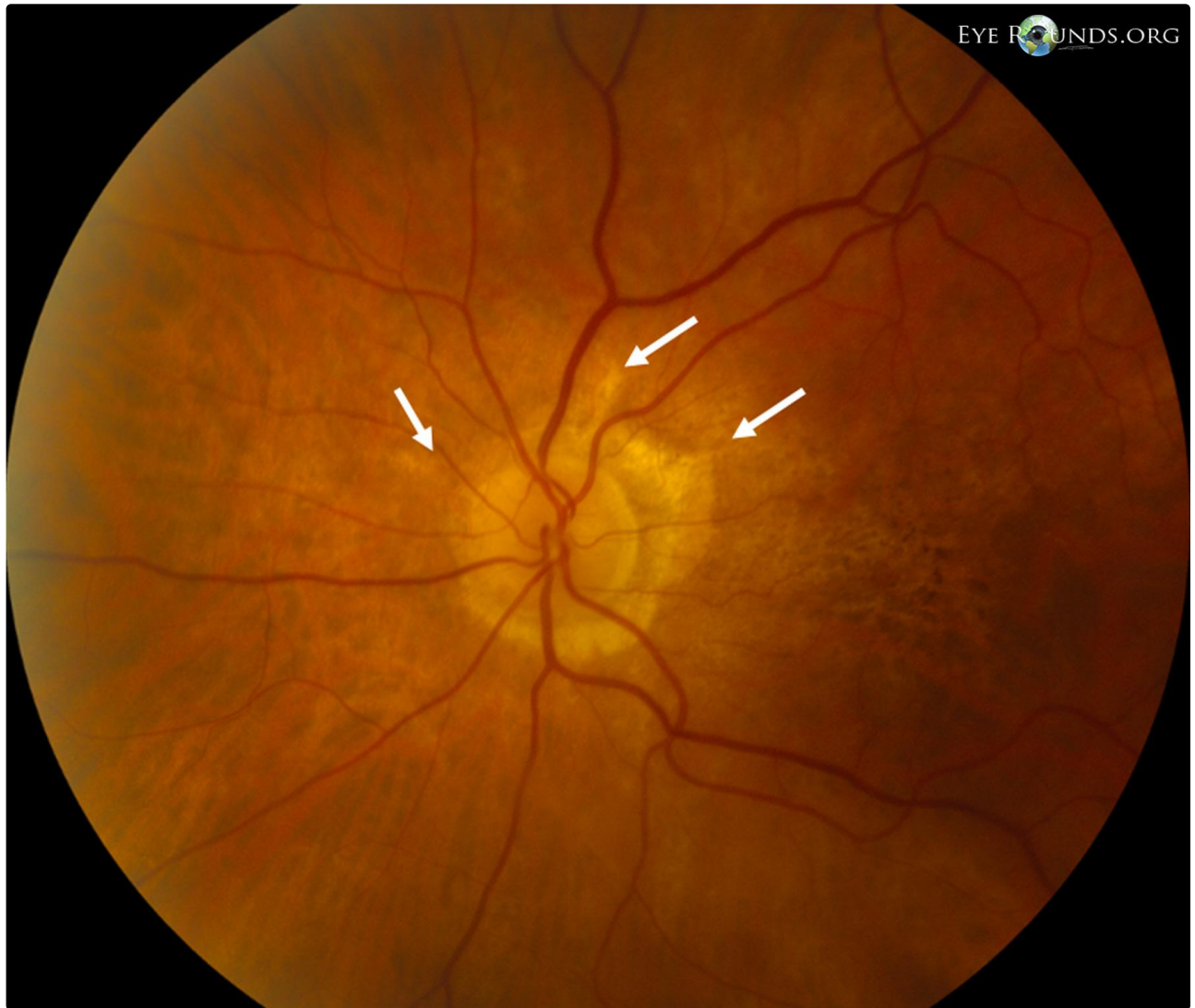
Her best corrected visual acuity was 20/200 in the right eye and 20/25 in the left eye.

Fundus exam revealed bilateral helicoid peripapillary atrophy with senile streaks (arrows) emanating from the optic nerves. The macula of the right eye had atrophy and mild subretinal fibrosis, and the left eye had atrophy and mild pigmentary mottling.





[Enlarge](#) [Download](#)



[Enlarge](#) [Download](#)

#### References:

1. Gandorfer A, Ulbig M, Bechmann M, et al. Retianl telangiectasis and angioid streaks. Br J Ophthalmol. 2000;84:1327-8.
2. Quaranta M, Cohen SY, Krott R, et al. Indocyanine green videoangiography of angioid streaks. Am J Ophthalmol 1995;119:136-142.

#### Image Permissions:



Ophthalmic Atlas Images by [EyeRounds.org](http://EyeRounds.org), [The University of Iowa](http://The University of Iowa) are licensed under a [Creative Commons Attribution-NonCommercial-NoDerivs 3.0 Unported License](http://creativecommons.org/licenses/by-nc-nd/3.0/).

## Address

University of Iowa  
Roy J. and Lucille A. Carver College  
of Medicine  
Department of Ophthalmology and  
Visual Sciences  
200 Hawkins Drive  
Iowa City, IA 52242

[Support Us](#)

## Legal

Copyright © 2019 The University of  
Iowa. All Rights Reserved  
[Report an issue with this page](#)  
[Web Privacy Policy I](#)  
[Nondiscrimination Statement](#)

## Related Links

[Cataract Surgery for Greenhorns](#)  
[EyeTransillumination](#)  
[Gonioscopy.org](#)  
[Iowa Glaucoma Curriculum](#)  
[Iowa Wet Lab](#)  
[Patient Information](#)  
[Stone Rounds](#)  
[The Best Hits Bookshelf](#)

## EyeRounds Social Media

Follow



Receive notification of new cases,  
[sign up here](#)  
[Contact Us](#)  
[Submit a Suggestion](#)